

Rotational Composite Flap Technique for Primary Incomplete Cleft Nose Deformity

Percy Rossell-Perry, MD, PhD,
FACS

Background: Nasal deformities accompanying unilateral incomplete cleft lip have minor skeletal and soft tissue deficiencies compared with deformities associated with unilateral complete cleft lip. Extended dissection and surgical incisions (often required for nasal deformities in complete cleft lip) are not recommended to address deformities accompanying incomplete cleft lip. The purpose of this study is to describe an innovative method involving a rotational composite flap for nasal repair in patients with unilateral cleft lip.

Methods: Since 2016, 49 consecutive patients with unilateral incomplete cleft lip have undergone primary anatomical repair of accompanying nasal deformities. The technique involves a skin incision along the marginal and intercartilaginous borders to create a V-shaped composite flap consisting of vestibular skin and alar cartilage. Rotational mobilization of the composite flap creates a triangular raw surface laterally, which is closed by advancement of the vestibular skin.

Results: This innovative method, which is based on the use of a rotational composite vestibular flap, achieves proper symmetry of the repaired nose.

Conclusion: The herein described composite flap rhinoplasty is a good surgical option, which provides a good overall nasal symmetry in patients with nasal deformities accompanying unilateral incomplete cleft lip. (*Plast Reconstr Surg Glob Open* 2020;8:e2870; doi: [10.1097/GOX.0000000000002870](https://doi.org/10.1097/GOX.0000000000002870); Published online 24 June 2020.)

INTRODUCTION

Nasal deformities accompanying unilateral incomplete cleft lip are less pronounced than those associated with a complete cleft lip. These deformities arise from soft tissue and skeletal deficiencies, which are relatively minor because skeletal structures of the maxilla and nose are usually minimally affected in the incomplete cleft lip. Nevertheless, the extent of skeletal and soft-tissue deficiencies is often underestimated, resulting in inadequate treatment and undesirable surgical outcomes.

Nasal deformities associated with incomplete cleft lip are characterized by alar cartilage malposition with nostril asymmetry, loss of tip projection, abnormal muscle insertion, septal deviation, and retracted columella. The alar cartilage lies caudal and lateral to the contralateral side, resting on an underdeveloped maxilla, which accounts for alar base lowering. The degree of

septal deviation varies but is usually less than that seen with a complete unilateral cleft lip.

Yuzuriha and Mulliken¹ described unilateral incomplete cleft lip as consisting of these components: notched lip extending ≥ 3 mm above the normal Cupid's bow peak; deficient vermilion on the medial side of the cleft; upper lip muscles not in continuity; the presence of Simonart's band (a strip of tissue partially filling the gap between the medial and lateral portions of the cleft); and nasal deformity.

Numerous authors have described techniques for repairing cleft lip nasal deformities (Yuzuriha and Mulliken,¹ McComb,² Salyer,³ and others). I previously reported an innovative V-Y-Z technique for repairing nasal deformities associated with a complete cleft lip.⁴ The current study describes an innovative method for the primary repair of nasal deformities accompanying unilateral incomplete cleft lip. This technique is based on the V-Y composite flap described by Potter⁵ for secondary correction of nasal deformities associated with cleft lip. However, instead of Potter's⁵ advancement flap, which involves incisions along the entire vestibule, the new technique uses a rotational composite flap that preserves the lateral portion of the nasal vestibule.

From the School of Medicine, Post Graduate Studies, San Martin de Porres University, Peru; and Edgardo Rebagliatti Hospital, Plastic Surgery Service, Lima, Peru.

Received for publication January 26, 2020; accepted April 9, 2020.

Copyright © 2020 The Author. Published by Wolters Kluwer Health, Inc. on behalf of The American Society of Plastic Surgeons. This is an open-access article distributed under the terms of the [Creative Commons Attribution-Non Commercial-No Derivatives License 4.0 \(CCBY-NC-ND\)](https://creativecommons.org/licenses/by-nc-nd/4.0/), where it is permissible to download and share the work provided it is properly cited. The work cannot be changed in any way or used commercially without permission from the journal.

DOI: [10.1097/GOX.0000000000002870](https://doi.org/10.1097/GOX.0000000000002870)

Disclosure: *The author has no financial interest to declare in relation to the content of this article.*

Related Digital Media are available in the full-text version of the article on www.PRSGlobalOpen.com.

Table 1. Operative Characteristics of the Studied Patients with Unilateral Incomplete Cleft Lip Nose (n = 49)

Characteristic	Value
Gender	
Female	20 (59.18%)
Male	29 (40.82%)
Affected side	
Left	33 (67.34%)
Right	16 (32.66%)
Age at the time of surgery (mean)	5.1 (range, 3–6 mo)
Time of postoperative evaluation (mean)	1.7 (range, 1–2.1 y)

The purpose of this study is to describe an innovative method for primary unilateral incomplete cleft lip nasal deformities. This is a case series of a surgeon's outcome of 49 consecutive unilateral incomplete cleft lip nasal deformity repairs (Table 1).

SURGICAL TECHNIQUE

Nasal correction is performed before lip repair to allow better access to the relevant structures. A skin incision is made along the marginal and intercartilaginous borders, creating a composite flap containing vestibular skin and alar cartilage in the shape of a “V” (Fig. 1). A small piece of vestibular skin is removed from the lateral tip of the flap to facilitate vestibular skin closure. The cartilaginous structures of the nose are dissected through the incision. After elevating the composite flap, it is displaced medially using two 5/0 polydioxanone transfixion sutures. The first suture is located posteriorly, between the nasal septum and the upper border of the alar cartilage from each side, at the level of the internal nasal valve. The second transfixion suture is located anteriorly, between the lower border of the alar cartilage and skin border from each side.

The rotational mobilization of the composite flap creates a triangular raw surface laterally, which is closed by the advancement of the vestibular skin (Fig. 2). The incisions are then closed using transcutaneous stitches. Specifically, 5-0 polyglycolic acid sutures are placed through the skin, starting from inside the nose and then exiting the skin at the level of the supra-alar crease; the needle then returns through the same hole and finally enters the inside of the nose, where the sutures are tied.

The nasal floor is then repaired, placing the ala in the proper location and reducing the nasal base width. This involves the use of 2 flaps: a medial flap lateral to the base of the columella at the cleft border, which is a small (1 × 1 cm) cutaneous flap based medially, and a lateral flap, which is composed of the base of the ala. During cheiloplasty, the levator labii superioris alaeque nasi and orbicularis oris muscles are identified and repositioned.

DISCUSSION

The described innovative technique, in combination with lip repair, achieves these objectives (Figs. 3 and 4) (See figure, Supplemental Digital Content 1, which displays the preoperative view of a 3-month-old patient with incomplete unilateral cleft lip nose deformity, <http://links.lww.com/PRSGO/B395>.) (See figure, Supplemental Digital

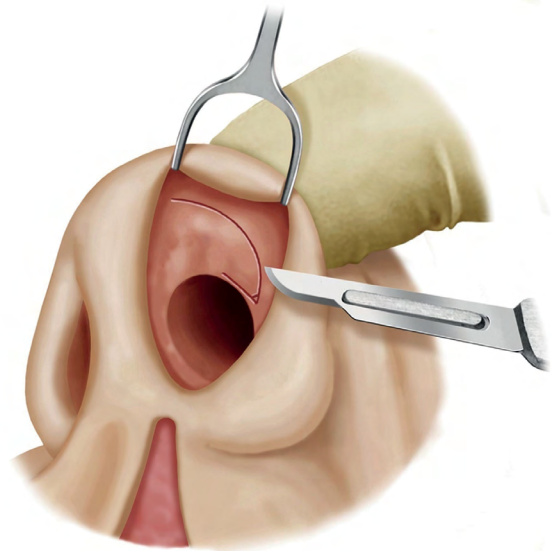


Fig. 1. The rotational composite flap technique for incomplete unilateral cleft lip nose deformity: preoperative view.

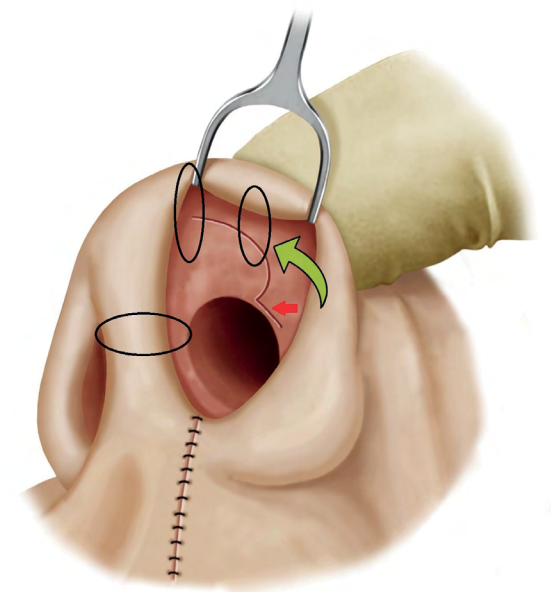


Fig. 2. The rotational composite flap technique for incomplete unilateral cleft lip nose deformity: postoperative view.

Content 2, which displays the postoperative front view of the patient after surgery, illustrating cosmetic improvement of the lip and nose using rotational composite flap technique after 1 year, <http://links.lww.com/PRSGO/B396>.)

1. Repositioned alar cartilage and lengthened columella on the cleft side, with good symmetry of the repaired nose;
2. Preservation of the lateral portion of the nasal vestibule, preventing scar contracture and synechia formation; and
3. Nasal floor repair, with good nostril symmetry and alar base position.

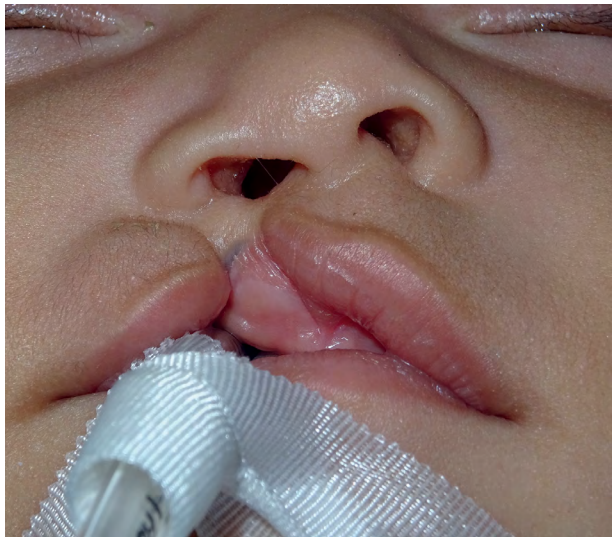

Fig. 3. Preoperative view of a 3-month-old patient with incomplete unilateral cleft lip nose deformity.

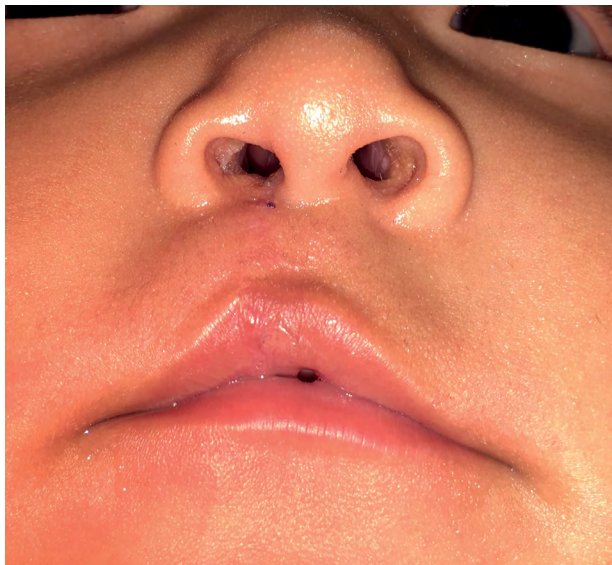

Fig. 4. Postoperative front view of the patient after surgery, illustrating cosmetic improvement of the lip and nose using the proposed method after 1 year.

Complete and incomplete cleft lips are accompanied by different nasal deformities and thereby require different management. Noses in a complete cleft lip necessitate total detachment of the alae, leaving a lateral straight scar. This is associated with a higher risk of scar contracture (a common complication after primary rhinoplasty), which can be avoided using a lateral Z plasty. Furthermore, the

position of the alar cartilage is displaced more in the complete cleft lip than in the incomplete cleft lip. In my experience, nasal deformities in the complete cleft lip require more advancement of the alar cartilage than can be accomplished with a rotational composite flap; thus, use of a V-Y advancement flap plus lateral Z plasty is recommended.

Nasal deformities with incomplete cleft lip are minor and can be corrected by preserving the lateral segment of the vestibule (which prevents lateral scar contracture) and performing less rotation to move the alar cartilage to its correct position. Good results are achieved, as shown in the figures. In all cases, nasal packing is placed inside the operated nostril to prevent postoperative bleeding and is removed the day after surgery.

Most complications of the described technique are associated with using transcutaneous resorbing sutures. These complications include temporary skin dimples, granulomas, ulceration, scarring, and infection. In a recent study, the most common complication of the technique was foreign body granuloma, which occurred in 13% of procedures.⁶ Skin dimples and granulomas resolve when the sutures resorb, leaving scar tissue in their place.

CONCLUSIONS

Rotational composite rhinoplasty may enhance nasal symmetry after primary repair of nasal deformities in patients with a unilateral incomplete cleft lip. Additional studies are required to evaluate the functional impact and long-term outcomes of this technique.

Percy Rossell-Perry, MD, PhD, FACS
 San Martin de Porres University
 School of Medicine
 Post Graduate Studies

Alameda del Corregidor Av 1531 La Molina 15024 Lima Perú
 E-mail: prossellperry@hotmail.com; prossellperry@gmail.com

REFERENCES

1. Yuzuriha S, Mulliken J. Minor-form, microforma and mini-micro-form cleft lip: anatomical features, operative techniques and revisions. *Plast Reconstr Surg*. 2008;122:1485–1493.
2. Mc Comb H. Primary correction of unilateral cleft lip nasal deformity: a 10-year review. *Plast Reconstr Surg*. 1985;75:791–799.
3. Salyer KE. Primary correction of the unilateral cleft lip nose: a 15-year experience. *Plast Reconstr Surg*. 1986;77:558–568.
4. Rossell-Perry P. Primary unilateral cleft lip nasal deformity repair using V-Y-Z plasty: an anthropometric study. *Indian J Plast Surg*. 2017;50:180–186.
5. Potter J. Some nasal tip deformities due to alar cartilage abnormalities. *Plast Reconstr Surg* (1946). 1954;13:358–366.
6. Rossell-Perry P. Primary cleft rhinoplasty: surgical outcomes and complications using three techniques for unilateral cleft lip nose repair. *J Craniofac Surg*. 2019 [E-pub ahead of print].