



Traumatic Ulnar Carpal Translocation, Distal Radioulnar Joint Subluxation with Occult Perilunate Injury

Timothy Visser, MD, MBA¹ Mikayla Borusiewicz, MD² Alexander Payatakes, MD¹

¹ Department of Orthopaedics and Rehabilitation, Penn State Health Milton S. Hershey Medical Center, Hershey, Pennsylvania

² Division of Plastic Surgery, Penn State Health Milton S. Hershey Medical Center, Hershey, Pennsylvania

Address for correspondence Alexander Payatakes, MD, Penn State Health Milton S. Hershey Medical Center, 500 University Drive, Hershey, PA 17033 (e-mail: apayatakes@pennstatehealth.psu.edu).

J Wrist Surg 2025;14:165–169.

Abstract

Background Perilunate injuries pose a significant treatment challenge, particularly when initially missed or underestimated. These injuries have a multitude of variations as propagation of the injury may be through ligaments and/or bone, with more recent appreciation given to nondislocated perilunate injuries.

Case Description We present a new variant of perilunate injuries, not dislocated (PLIND). This occult ligamentous perilunate injury was associated with ulnar carpal translocation, radiocarpal subluxation, and distal radioulnar subluxation. The extent of injury was fully appreciated intraoperatively, with only subtle clues present on preoperative exam and imaging, emphasizing the high index of suspicion required to identify these injuries. Clinical outcome at 1-year follow-up was very satisfactory.

Literature Review PLIND consist a distinct subset within the spectrum of perilunate injuries in which there is no observed disruption of the capitulunate relationship. Based on few cases reported in the literature (attributable to their rare occurrence and likely additional lack of awareness surrounding the injury pattern), current recommendations for surgical management include arthroscopic or open approach to appropriately address osseous and ligamentous injuries.

Clinical Relevance Recognition of PLIND injuries is challenging given the lack of frank dislocation of the capitate head on the lunate, as observed in classic perilunate injuries. Heightened clinical suspicion in patients with consistent mechanism and presentation, followed by timely surgical management, may limit sequelae of persistent instability and arthritis. Our case contributed to relevant literature by presenting a previously undescribed PLIND variant combined with radiocarpal instability, ulnar carpal translocation, and distal radioulnar subluxation.

Keywords

- ▶ perilunate injuries
- ▶ radiocarpal instability
- ▶ carpal instability
- ▶ PLIND

Perilunate dislocations (PLDs) and fracture dislocations occur following high-energy trauma to the wrist or falls onto an outstretched hand and are a rare though well-documented entity.¹ Variability in presentation is best represented by

progressive ligamentous injury and a spectrum of osseous findings, wherein the severity of injury is related to baseline carpal disease, anatomical variations within the carpus, and direction and amplitude of the deforming forces.¹ These injury

received
November 29, 2023
accepted
March 27, 2024
article published online
April 24, 2024

DOI <https://doi.org/10.1055/s-0044-1786160>.
ISSN 2163-3916.

© 2024. The Author(s).

This is an open access article published by Thieme under the terms of the Creative Commons Attribution-NonDerivative-NonCommercial-License, permitting copying and reproduction so long as the original work is given appropriate credit. Contents may not be used for commercial purposes, or adapted, remixed, transformed or built upon. (<https://creativecommons.org/licenses/by-nc-nd/4.0/>)

Thieme Medical Publishers, Inc., 333 Seventh Avenue, 18th Floor, New York, NY 10001, USA

patterns are characteristically defined by dissociation between the distal surface of the lunate and the head of the capitate, most often in a dorsal direction, notable on imaging and clinical examination.

Arising within the literature, however, is a subcategory of nondislocated injuries in the setting of transcarpal trauma.² This includes a subset of perilunate injuries without frank dislocation of the capitate head from the lunate on posttraumatic imaging, designated “perilunate injury, not dislocated” (PLIND). Reports of these injuries throughout the literature include all categories within the distribution of perilunate injuries—including purely ligamentous, trans-radial styloid, transscaphoid, transcapitate, and translunate injuries—all sharing a maintained interface between the capitate and lunate.² Whereas a true dislocation may be detected on imaging and via recognition of obvious deformity or acute compressive median neuropathies upon examination, PLIND injuries are more likely to be overlooked, even by experienced surgeons. As such, though few reported cases appear within the literature, the occult nature of PLIND injuries may skew the incidence toward underestimation. Nevertheless, these entities do require osseous and/or ligamentous repair and pose the risk of persistent instability and posttraumatic arthritis should they remain undetected or untreated.³

As documented throughout previous case studies and that which follows, PLIND injuries will share a history of high-energy trauma accompanied by marked edema about the wrist and diffuse tenderness throughout the carpus. Plain radiographs and wrist computed tomography (CT) imaging are the mainstays of characterization of these injuries, and may demonstrate osseous injuries of one or more carpal bones, midcarpal osteochondral fractures, and evidence of ligamentous dissociation. Diagnostic confirmation is made via arthroscopic evaluation or mini-dorsal capsulotomy when index of suspicion is high. Surgical management, then, is achieved through osseous and ligamentous fixation, followed by a period of immobilization.²

We present the following case to contribute to the burgeoning body of literature on this injury pattern, as this case consisted of an occult ligamentous pattern that has not been previously described in conjunction with ulnar carpal translocation and radiocarpal subluxation.

Case Report

The patient is a 60-year-old right-handed male who presented to clinic 2 days following a right wrist injury sustained while hiking an icy path. He slammed his hand into a tree under his own and wife's combined body weight. He was splinted without reduction by a remote facility. External imaging (radiographs, CT) showed ulnar carpal translocation, radiocarpal volar subluxation, dorsal subluxation of the distal ulna at the distal radioulnar joint (DRUJ), and dorsal radial fleck avulsions (►Fig. 1, ►Fig. 2).

Examination revealed significant volar and dorsal wrist swelling, pain with attempted motion, diminished median nerve sensation (which had improved since his injury), and no

open wounds. Intraoperative fluoroscopic evaluation the following day confirmed ulnar carpal translocation and gross bidirectional radiocarpal instability, but also previously unappreciated perilunate injury, as evidenced by disruption of Gilula's arcs at both the scapholunate (SL) and lunotriquetral (LT) joints (►Fig. 3A–C). Exploration confirmed radioscapoph-capitate and radiolunate ligament avulsions, complete SL and LT dissociation, and lax but maintained capitollunate relationship. Volar radiocarpal ligament repair (with anchors), intrinsic (capsuloligamentous) repairs, and pinning were performed through a combined dorsal/volar approach (►Fig. 3D–F). The carpal tunnel was prophylactically released. The forearm was splinted in position of DRUJ stability (60° supination).

Postoperatively the patient was transitioned to cock-up splint (weeks 2–6) with subsequent mobilization and therapy. Pins were removed at 3 months (►Fig. 4). At 1-year follow-up, despite radiographic evidence of significant posttraumatic arthritis, ulnocarpal translation, SL widening, and DISI (dorsal intercalated segment instability) deformity, he was recreationally active and reported only mild night-time wrist pain. He had 50% wrist flexion/extension, near full pronation/supination, and 70% grip strength. Possible future salvage procedures were discussed but deferred given his very satisfactory functional level.

Discussion

This case represents a new subtype of perilunate injury with extensive disruption of both extrinsic and intrinsic wrist ligaments resulting in gross ulnar translocation of the carpus and radiocarpal instability, but without radiographically evident dissociation between the distal surface of the lunate and capitate. In the case detailed above, the patient presents with the characteristic triad described by Herzberg in his 2013 review of PLIND pattern perilunate injuries, specifically a history of high-energy trauma, significant soft tissue edema over the volar and dorsal aspect of the wrist, and pain to palpation over the carpus.²

Unlike most previous reports of presenting symptoms in patients with nondislocated perilunate injuries, our patient did present with progressively improving paresthesias in the median nerve distribution. While acute carpal tunnel syndrome is a common feature observed with frank PLD, our patient's median neurapraxia may be attributable to the radiocarpal subluxation and ulnar carpal translocation, or alternatively to spontaneously reduced transient PLD.² In accordance with these preoperative and intraoperative findings, the carpal tunnel was surgically released.

Furthermore, though the patient highlighted in this case did not specifically sustain carpal fractures requiring osseous fixation, initial plain radiographs did reveal a series of bony flecks and midcarpal osteochondral loose bodies, which have previously been described in imaging of PLIND injuries and which should raise diagnostic suspicion for possible ligamentous injury in a patient whose history and clinical findings are consistent.²

In his 2013 paper highlighting a series of patients with nondislocated perilunate injuries, Herzberg further

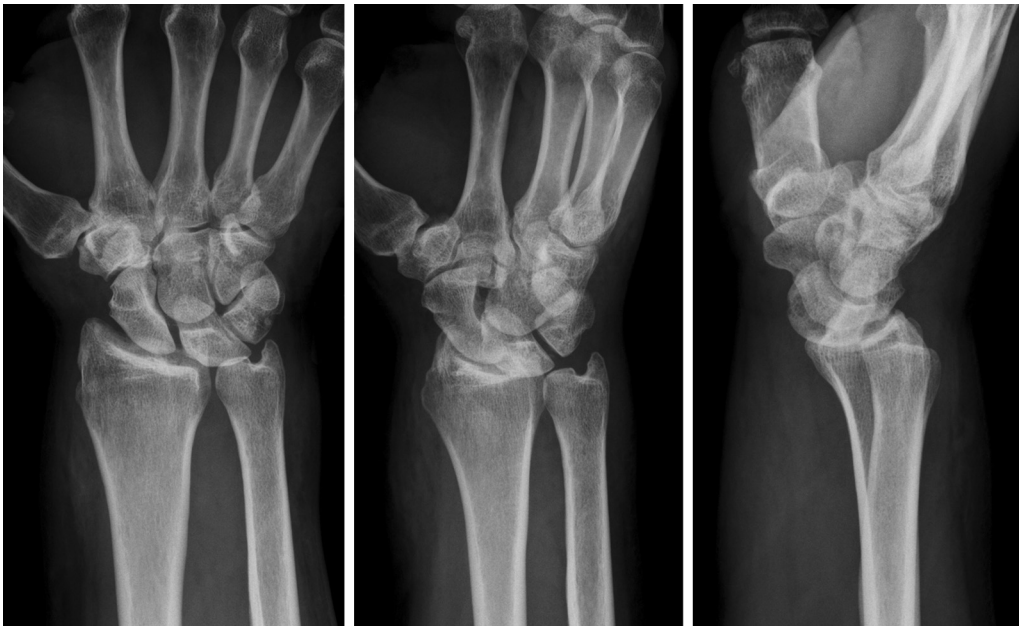

Fig. 1 Radiographs of the initial injury (PA, oblique, and lateral views), demonstrating ulnar carpal translocation and volar radiocarpal subluxation. The capitulunate relationship is grossly maintained with no obvious intercarpal disruption. PA, posteroanterior.

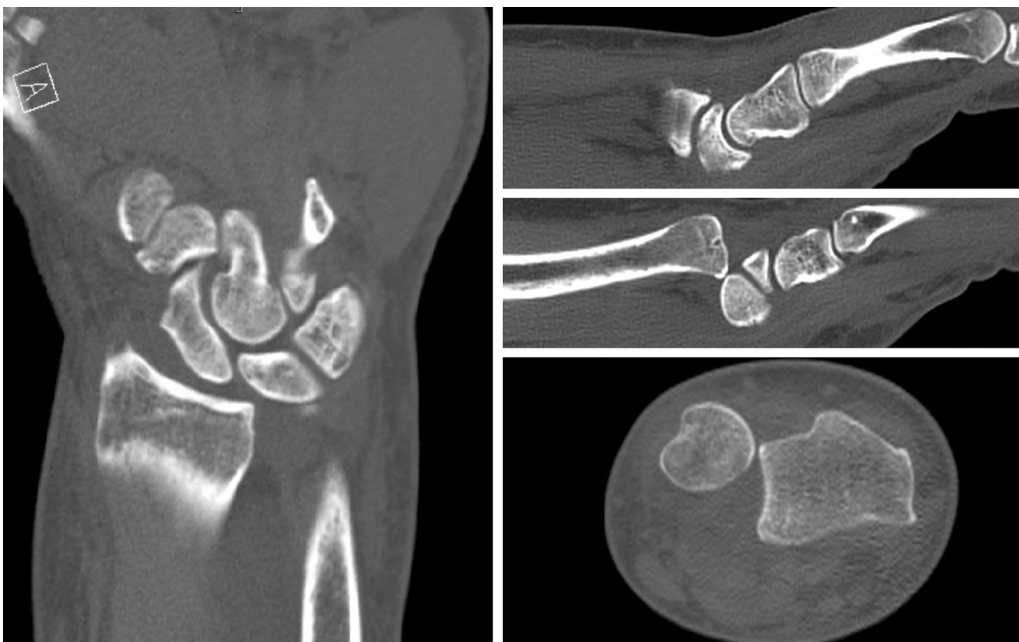


Fig. 2 Selected CT images of the initial injury: coronal, sagittal (radiocarpal), sagittal (ulnocarpal), and axial reconstructions (left to right and clockwise). Evidence of ulnar carpal translocation, volar radiocarpal subluxation, and dorsal distal ulna subluxation. CT, computed tomography.

characterized these cases by injury pattern, and found that the distribution included all previously described paths—including purely ligamentous, trans-radial styloid, transscaphoid, transcapitate, and translunate.² Additionally, the concepts of “greater” and “lesser arc” injuries have been applied to perilunate injuries, where the presence of carpal fractures is consistent with a “greater arc” injury, and purely ligamentous injuries are consistent with “lesser arc” injuries.^{1–3} These descriptors, however, are often not versatile enough to capture the multiplanar displacement seen in many perilunate injuries. Herzberg et al described a classification

system based upon the direction of displacement of the capitate relative to the lunate in order to more comprehensively capture sagittal and coronal translation. In a follow-up article specifically describing nondislocated variant injuries in 2013, Herzberg offered an expanded classification system, which includes PLIND pattern injuries in order to capture this emerging subcategory of injuries and to raise index of suspicion for this complex injury pattern.^{1,2,4}

The updated algorithm championed by Herzberg provides a useful framework for assessment of possible PLIND injuries in which—after the identification of consistent clinical features

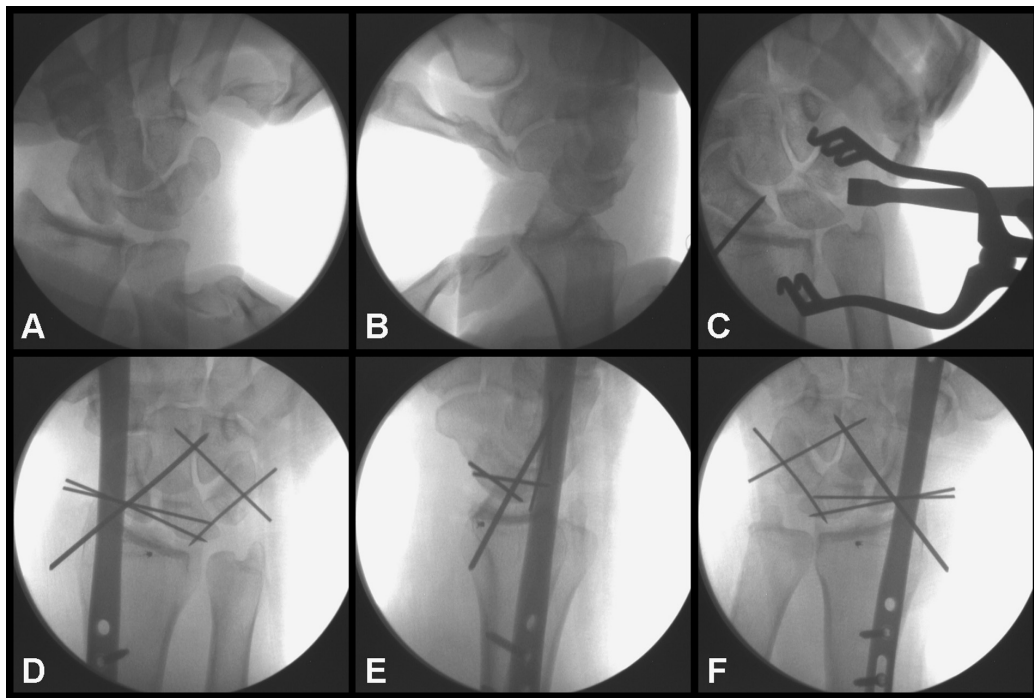


Fig. 3 Selected intraoperative fluoroscopic images demonstrate: (A) significant ulnar carpal translocation, (B) bidirectional radiocarpal instability with stressing, (C) perilunate injury as evidenced by disruption of Gilula's arcs at both the SL and LT joints (appreciated on fluoroscopy and confirmed with arthrotomy) with associated widening of the midcarpal joint, (D, E) final radiographs (pronated PA and lateral views) following repairs showing subtle widening of the DRUJ, dorsal distal ulna subluxation, and (F) reduction of the DRUJ with supination (supinated AP view). AP, anteroposterior; DRUJ, distal radioulnar joint; LT, lunotriquetral; PA, posteroanterior; SL, scapholunate.

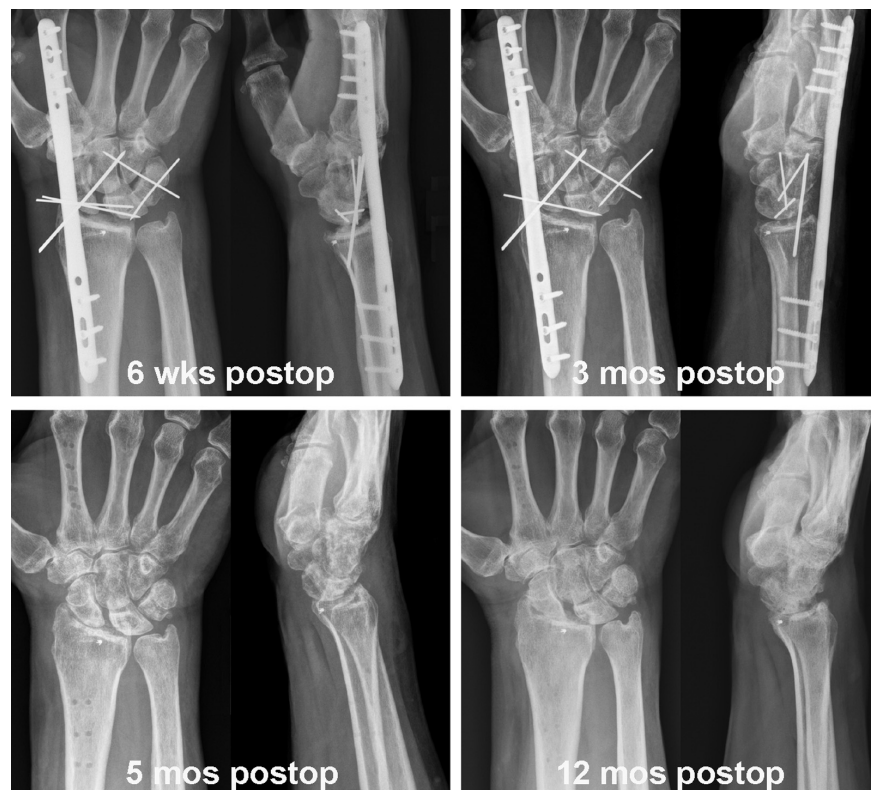


Fig. 4 Postoperative radiographs (PA and lateral views) with associated time frame labels. One of the SL pins migrated and was removed between 6 weeks and 3 months. At 12 months, there was evidence of posttraumatic arthritis, mild ulnocarpal translation, and SL widening with DISI deformity. The DRUJ remained stable. Despite radiographic findings, functional outcome was satisfactory. DISI, dorsal intercalated segment instability; DRUJ, distal radioulnar joint; PA, posteroanterior; SL, scapholunate.

and suspicion based on plain radiographic findings—higher resolution imaging via CT or magnetic resonance imaging is recommended, followed by wrist arthroscopy versus open dorsal approach for diagnosis and fixation.² This case, however, required an additional volar approach to address the grossly disrupted volar extrinsic ligaments, allowing identification and surgical repair of the avulsed radioscapaphocapitate and radiolunate ligaments. The application of a dorsal spanning plate served to further stabilize the wrist in the setting of gross radiocarpal and ulnar carpal translocation.

A 2022 review by Fisher et al of current management of perilunate injuries distinguishes acute and chronic injuries to highlight the utility and superior outcomes seen with early open reduction and fixation to restore native anatomy and ligamentous attachments.^{5,6} Major benefits include restoration of intercarpal dynamics prior to soft tissue contracture and fibrosis which develop with chronic injuries, as well as avascular necrosis of the scaphoid and lunate that may develop when capsular attachments are avulsed.⁷ This highlights the significance of early identification and proper management of occult perilunate injuries. Of note, no prospective trials were identified in the literature comparing various open treatment options for acute injuries, likely due to rarity and heterogeneity of presentations, particularly in the case of nondislocated variants.⁵

Future areas for discussion and study include development of a systematic approach to fixation of bony and

ligamentous injuries seen with nondislocated perilunate injuries, as well as protocols for rehabilitation. Overall, this case of atypical carpal instability furthers our knowledge of nondislocated perilunate injury variants and serves to underscore the need for a high index of suspicion in patients with a consistent mechanism and presentation, allowing prompt surgical restoration of carpal stability.

Conflict of Interest

None declared.

References

- 1 Herzberg G, Comtet JJ, Linscheid RL, Amadio PC, Cooney WP, Stalder J. Perilunate dislocations and fracture-dislocations: a multicenter study. *J Hand Surg Am* 1993;18(05):768–779
- 2 Herzberg G. Perilunate injuries, not dislocated (PLIND). *J Wrist Surg* 2013;2(04):337–345
- 3 Kozin SH. Perilunate injuries: diagnosis and treatment. *J Am Acad Orthop Surg* 1998;6(02):114–120
- 4 Fisher ND, Bi AS, De Tolla JE. Perilunate dislocations: current treatment options. *JBJS Rev* 2022;10(09):
- 5 Johnson RP. The acutely injured wrist and its residuals. *Clin Orthop Relat Res* 1980;149(149):33–44
- 6 Kailu L, Zhou X, Fuguo H. Chronic perilunate dislocations treated with open reduction and internal fixation: results of medium-term follow-up. *Int Orthop* 2010;34(08):1315–1320
- 7 Herzberg G. Perilunate and axial carpal dislocations and fracture-dislocations. *J Hand Surg Am* 2008;33(09):1659–1668