

Combined thrombin-collagen injection for the management of an iatrogenic pseudoaneurysm in the popliteal region

Eoghan McCarthy, Niamh O'Mahony, Mark Ryan, Michael Guiney

Department of Radiology, St. James's Hospital, James's Street, Dublin-8, Ireland

Correspondence: Dr. Eoghan McCarthy, Department of Radiology, St. James's Hospital, James's Street, Dublin-8, Ireland.
E-mail: ejmccarthy@stjames.ie

Abstract

Pseudoaneurysm formation is a rare but recognized complication of total knee arthroplasty (TKR), with fewer than 20 cases described in the literature. Multiple management techniques have been described for such pseudoaneurysms. As thrombin injection is an established technique, we report a case of a post-TKR tibioperoneal pseudoaneurysm successfully occluded via percutaneous injection of a dual thrombin-collagen preparation.

Key words: Pseudoaneurysm; thrombin-collagen injection; total knee arthroplasty

Introduction

Iatrogenic pseudoaneurysm formation is a recognized complication of virtually any procedure that is performed via or in the vicinity of arteries. As such, medical professionals must be conscious of this complication. A myriad of management strategies have been described for pseudoaneurysms and in this short case report we describe a new spin on an established technique.

Case Report

A 66-year-old female, 5 days post-elective total knee replacement was noted on clinical exam to have a pulsatile swelling in the popliteal fossa. Angiography confirmed the presence of a 1.9 cm pseudoaneurysm arising from the proximal left tibioperoneal trunk, with a 3.3 mm neck [Figure 1]. Under real-time ultrasound (US) guidance and using sterile techniques, a 20 gauge 2.75 inch needle was

introduced percutaneously into the pseudoaneurysm cavity and 1.5 ml of a mixture of 5,000 US units of thrombin and 200 mg of microfibrillar bovine collagen (D-Stat flowable Hemostat, Vascular Solutions Inc., Minneapolis, Minnesota) was injected [Figure 2]. This resulted in complete occlusion of the pseudoaneurysm within seconds which was confirmed via US. A further check US was performed on day 6, post-operatively, which once again confirmed no flow within the thrombosed pseudoaneurysm cavity [Figure 3].

Arterial complications post-total knee arthroplasty (TKR) are a rare but recognized entity. In a large single-center study incorporating 13618 TKR's, 0.17% of the cases had arterial complications.^[1] Pseudoaneurysms are much rarer, with fewer than 20 cases reported in the literature. The proximity of the popliteal artery to the operative site during TKR exposes it to potential injury. Parvizi *et al.* found that indirect trauma, such as vessel stretching during dislocation of the knee joint was responsible for the majority of vessel injuries rather than direct arterial trauma.^[2] Techniques previously described in the literature for management of pseudoaneurysms post-TKR included percutaneous bland thrombin injection, endovascular stenting, endovascular coiling, and open surgical ligation. This is the first reported case of a popliteal pseudoaneurysm managed with a combined thrombin-collagen percutaneous injection (D-Stat Flowable®). This product was designed to accelerate

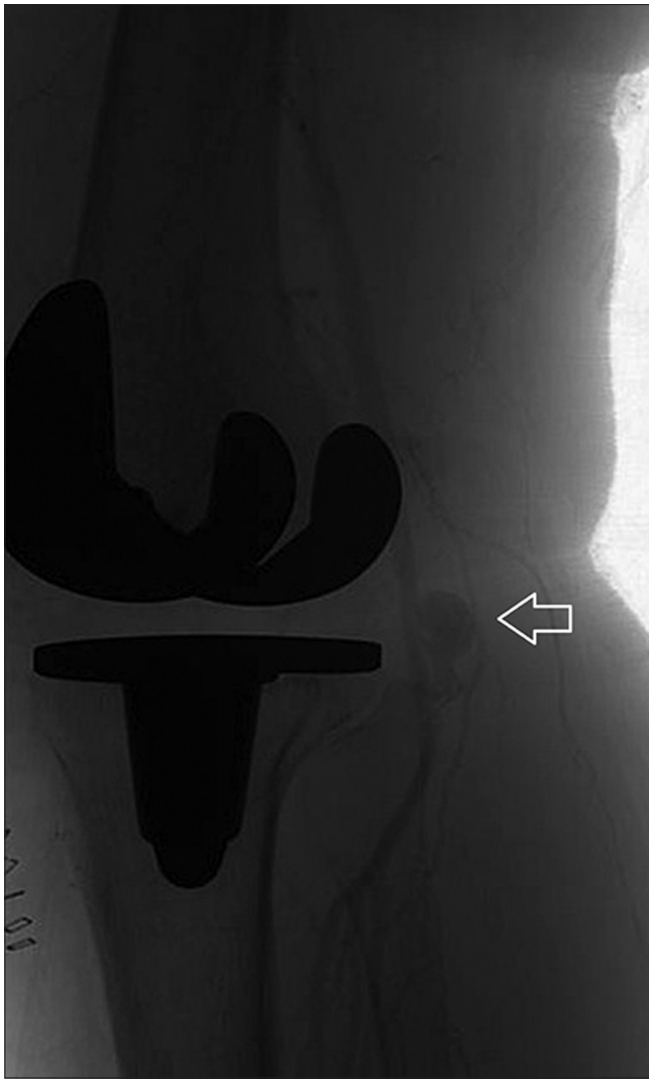Access this article online

Quick Response Code:



Website:
www.ijri.org

DOI:
10.4103/0971-3026.111474



Figures 1: Formal angiogram showing a 1.9 cm pseudoaneurysm (arrow) of the left tibioperoneal trunk

the blood clotting process by facilitating conversion of fibrinogen to fibrin. It is approved for management and control of bleeding from vascular access sites, percutaneous drains, and tissue tracts and has been used successfully in the past to percutaneously occlude a giant splenic artery pseudoaneurysm.^[3] In our experience, the high viscosity of this preparation allows greater control of the injection, potentially decreasing the risk of intra-arterial thrombotic events which have complicated a very small proportion of thrombin injections.^[4] The avoidance of arterial access such as is required for endovascular stenting and coiling decreases the risk of concurrent arterial access site injury. Furthermore, many authors discourage the use of covered stents across mobile joints due to high occlusion rates (up to 21%) at 24 months.^[5] As the patency rates of stents are improving as newer generation stents are developed, there is the ongoing requirement for patients to be medicated with aspirin and/or clopidogrel, both of which carry their own inherent risks. Lastly, with this technique, the general

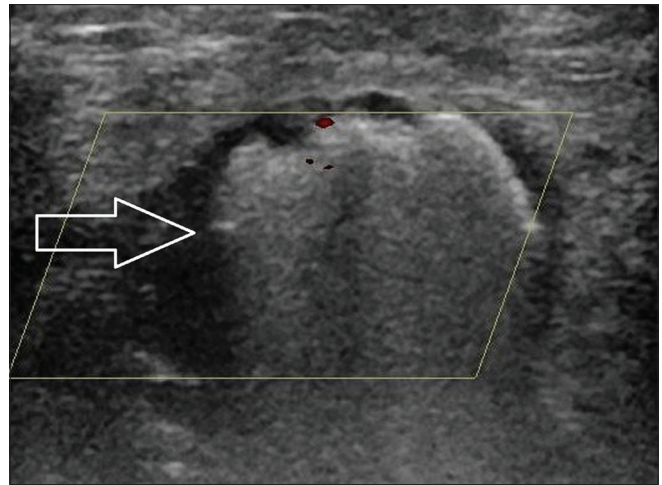


Figure 2: The 'snow-storm'effect (arrow) visualized on ultrasound during injection of the thrombin-collagen compound

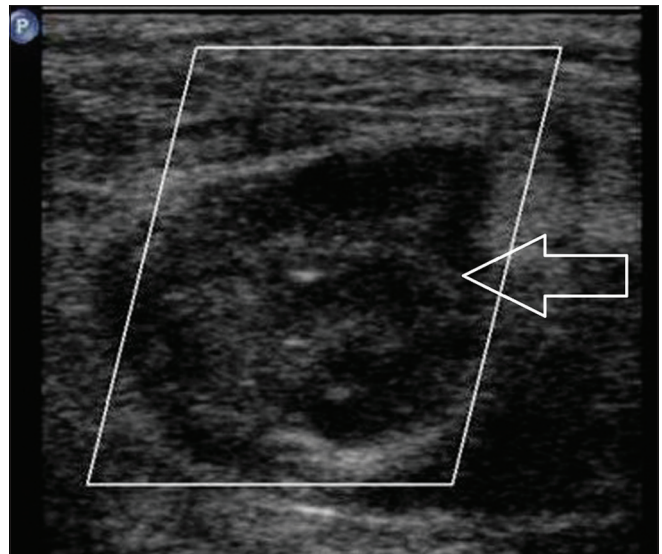


Figure 3: Satisfactory thrombosis (arrow) of the pseudoaneurysm at check ultrasound

anesthetic required for surgical repair is also avoided and, consequently the associated complications.

It is important to note that this compound is not routinely used for pseudoaneurysm management and even though our own limited experience with this product has been favorable, randomized trials comparing it with other treatments are required before it becomes an established therapeutic strategy. In practice, it is important to aim the needle away from the neck of the pseudoaneurysm when injecting the drug and to only inject small amounts at a time as we have found that the "snow storm" effect [Figure 2] can limit visualization of the pseudoaneurysm neck. A final note of caution is the possible development of factor V deficiency secondary to the development of bovine thrombin-induced antibodies which can cross-react with human factor V. This risk is also seen in the use of bland thrombin.

Conclusion

Pseudoaneurysm formation post-TKR is a rare but recognized complication. The percutaneous injection of a thrombin-collagen mix under US guidance into such pseudoaneurysms is a new spin on an established treatment technique. In the hands of an experience operator, this approach allows for rapid thrombosis with greater control while obviating the risks associated with endovascular or surgical repair.

References

1. Calligaro KD, Dougherty MJ, Ryan S, Booth RE. Acute arterial complications associated with total hip and knee arthroplasty. *J Vasc Surg* 2003;38:1170-7.
2. Parvizi J, Pulido L, Slenker N, Macgibeny M, Purtill JJ, Rothman RH.

Vascular injuries after total joint arthroplasty. *J Arthroplasty* 2008;23:1115-21.

3. Huang IH, Zuckerman DA, Matthews JB. Occlusion of a giant splenic artery pseudoaneurysm with percutaneous thrombin-collagen injection. *J Vasc Surg* 2004;40:574-7.
4. Hofmann I, Wunderlich N, Robertson G, Kieback A, Haller C, Pfeil W, *et al.* Percutaneous injection of thrombin for the treatment of pseudoaneurysms: The German multicentre registry. *EuroIntervention* 2007;3:321-6.
5. Tielliu IF, Verhoeven EL, Zeebregts CJ, Prins TR, Span MM, van den Dungen JJ. Endovascular treatment of popliteal artery aneurysms: Results of a prospective cohort study. *J Vasc Surg* 2005;41:561-7.

Cite this article as: McCarthy E, O'Mahony N, Ryan M, Guiney M. Combined thrombin-collagen injection for the management of an iatrogenic pseudoaneurysm in the popliteal region. *Indian J Radiol Imaging* 2012;22:257-9.

Source of Support: Nil, **Conflict of Interest:** No.

Announcement

"Quick Response Code" link for full text articles

The journal issue has a unique new feature for reaching to the journal's website without typing a single letter. Each article on its first page has a "Quick Response Code". Using any mobile or other hand-held device with camera and GPRS/other internet source, one can reach to the full text of that particular article on the journal's website. Start a QR-code reading software (see list of free applications from <http://tinyurl.com/yzlh2tc>) and point the camera to the QR-code printed in the journal. It will automatically take you to the HTML full text of that article. One can also use a desktop or laptop with web camera for similar functionality. See <http://tinyurl.com/2bw7fn3> or <http://tinyurl.com/3ysr3me> for the free applications.