

Utility of negative oral contrast (milk with 4% fat) in PET-CT studies

Samuel Aban Meyer, Sachin Gawde

Department of Nuclear Medicine Centre, Institute of Functional Imaging and Research, Mangal Anand Hospital, Chembur, Mumbai, India

ABSTRACT

Aims: The aim of this study was to evaluate whether low-attenuation oral contrast agent (milk with 4% fat) in PET-CT gastrointestinal studies (GIT) improves the diagnostic accuracy. **Justification for the Study:** Traditional high-contrast oral agents like iodine solutions, and barium suspensions which due to overcorrection problems in PET-CT interpretation lowers the accuracy of diagnosis. Traditional low-attenuation oral contrast agents are water, air, fat containing agents used with 12.5% corn oil and polyethylene glycol. Volumen is a 0.1% barium suspension and has found favor in visualization of mural features as well as for GIT distension. Milk with 4% fat content has also been tested out in radiological studies and found to be as effective as Volumen. As the former is more easily available, palatable, and acceptable especially, by children it needed to be tested in the visualization of the GIT in the PET-CT scenario. **Materials and Methods:** Total of 112 patients were divided into 3 groups. Group I: No intervention (18 subjects) Group II: Water (55 subjects): All these patients had 500-750 ml of water 5-10 min before PET examination. Group III: Milk (39 subjects) 500 ml of milk (4% fat content with no additives) was given 40-45 min after 18F-Fluorodeoxyglucose (FDG) injection and another 500 ml 5 min before scan was started. For patients intolerant to milk the same procedure was carried out with soya milk. Group IV comparison with data with Volumen. **Results:** Criteria for evaluation of Gut distension on CT images: (0) No distension, (1) 1 cm distension, (2) 1-2 cm distension, (3) > 2 cm distension. For the study analysis, % of patients with criteria 2 and 3 were considered as good visualization. Stomach distension was 16%, 47%, 88%, 75% in Gr1-4 respectively, Duodenum-11%, 27%, 88%, 86%, Jejunum-33%, 49%, 89%, 76%* Ileum-40%, 77%, 82%, 80%* and Colon-55%, 58%, 74%. Visualization of bowel wall with enhancement of stomach, duodenum, jejunum, and ileum and proximal colon was significantly better with milk than with water or no intervention. Intensity of FDG uptake was mild to moderate with no overcorrection in normal bowel loops and in patients with GIT lesions. Gaseous distension was not increased with milk as an oral contrast agent. Images of patients with bowel tumor was well-delineated with milk administration as the FDG uptake ratio of tumor to gut was high. **Conclusion:** Distension and visualization of the stomach, duodenum, jejunum, and proximal bowel was significantly improved with milk as a low-attenuation contrast agent. Intensity of FDG uptake was not significantly increased in normal gut and delineation of tumor with increased FDG uptake was improved as overcorrection was minimal.

Keywords: Low attenuation gastrointestinal contrast, milk with 4% fat, PET-CT of the gut

INTRODUCTION

To improve PET image quality CT data are used for the purpose of the PET attenuation correction in combined PET-CT

Typical CT-based attenuation-correction algorithms are based on a two-step scaling method in which a threshold is set to separate soft-tissue from bone. To obtain the corresponding attenuation map at 511 keV, CT values are scaled with a scaling factor for either soft-tissue or bone. In comparison to the PET annihilation quanta of 511 keV, however, CT X-rays with energies of 70-140 keV are attenuated substantially more by structures that contain elements with high-atomic numbers, such as iodine and barium. If these differences in attenuation are not accounted for, contrast agents may lead to biases in the estimated attenuation co-efficients, which may lead to artifacts in the corrected PET images.

Access this article online

Quick Response Code:



Website:
www.ijnm.in

DOI:
10.4103/0972-3919.112719

Address for correspondence:

Dr. Samuel Aban Meyer, ELNOR Flat 21, Corner of Main Avenue and V. P. Road, Santacruz (W), Mumbai 400054, India.
E-mail: ams23840mrs@hotmail.com

It has been shown that after administration of positive oral contrast agents (iodine and barium) the increase in intraluminal attenuation may lead to overestimation of PET activity concentration up to 20%. While the qualitative effect of this overestimation on the PET data is negligible in most cases, local accumulation of oral contrast agents caused either by ingestion of highly concentrated iodine or barium or by a delay in the intestinal passage can introduce significant PET artifacts. These artifacts appear as areas of apparent focal tracer uptake in co-registration with a contrast material – enhanced stomach or bowel loop and may cause interpretation errors. Furthermore, as a result of the time interval between performance of the CT and PET components of the combined scanning procedure, bowel loops may shift in the abdomen. Increased glucose metabolism may be seen in the area where the contrast material – enhanced bowel loop was originally located during the CT acquisition. Because all positive oral contrast agents are implicitly associated with overcorrection due to high-density material, poor mural discrimination, and interference of 2D and 3D multi-planar reformation in attenuation, interpretation in the presence of artifacts are problematic.

A negative oral contrast agent has the potential to completely avoid high-attenuation artifacts. Traditional negative contrast agents include water, air, 12.5% corn oil, fatty foods, polyethylene glycol (PEG), barium and methylcellulose – water mixture, Volumen, (a commercially available product with 0.1% barium suspension), and whole milk with 4% fat content.^[1-9]

Some of the drawbacks of the negative contrast agents are the need for giving additional drugs such as muscle relaxants for water, metochlorpropamide for agents with a high-fat content, poor palatability, and diarrhea with PEG. Volumen has been the recommended agent as a good negative contrast for the gut but it is not readily available and is expensive. Milk with 4% fat has been evaluated for radiological studies and has been found to have comparable results as Volumen. The 4% fat content in milk slows upper GIT motility, obviates use of muscle relaxant or metochlorpropamide, shows good mural visualization, and discrimination of pancreas, duodenum, jejunum, and small bowel, there are no side-effects and it is palatable and also reduces the fasting period of the study. The objectives in the present study was to evaluate the use of whole milk as a negative contrast agent for PET-CT studies firstly because it has not been reported in PET-CT milieu and Volumen is not readily available and is expensive.

MATERIALS AND METHODS

A total of 112 patients were divided into 3 groups. All patients were fasting at least 6 h prior to PET-CT scans.

The three groups were as follows:

- No intervention (18 subjects)
- Water (55 subjects)
- Milk (39 subjects)

Procedures

Patient continued to fast before the scan study in the first group. 500 ml of water was given 40 min after FDG injection and 500 ml, 5-10 min before scanning in the second group. 500 ml of milk (4% fat content with no additives) was given 40 min after FDG injection and another 500 ml or quantity tolerated by the patient 5 min before scan was started. For patients intolerant to milk the same procedure was done with soya milk. This procedure was adopted in the third group of patients. Volumen was not available for the study.

The study was done in sequence with non-intervention in a group of patients first, followed by next batch of patients given water orally and last group were given milk. Patients were not selected but were taken into the study as referred for PET-CT scans.

PET-CT study was carried out on a GE general electric Hawkeye system using 2mA for the CT. Three bed positions covered whole body with 10 min acquisition for CT and 10 min for the PET data.

Three observations were made to assess the effect of the contrast agent. The first was to see whether the contrast agent could distend the gut and make it better visualized as evidenced on the CT images. The second was to see the effect of the contrast agent on the ¹⁸F-FDG (Fluorodeoxyglucose) uptake by the gut with respect to increase in focal or general FDG concentration in the gut resulting from attenuation correction. The third was to see whether the contrast agent increased the gaseous content of the gut.

Criteria for evaluation of gut distension were dependant on the CT images. This was done to assess the usefulness of the contrast invisualization of the gut effectively.

- 0 no distension
- 1 minimal = 1 cm distension
- 2 good 1-2 cm distension
- excellent > 2 cm distension

Visualization of distension of stomach, (stomach distension was evaluated by visual evaluation and measurement) segments which showed the largest distension for duodenum, jejunum, ileum and proximal large bowel were measured while visual distension of distal large bowel were evaluated. For the study analysis, patients with criteria 2 and 3 were considered as good visualization.

On the PET images the intensity of FDG uptake was, + Minimal FDG gut uptake, (SUV < 1.0 and FDG activity less than the liver), ++, Moderate FDG uptake, (SUV < 2 and FDG activity same as the liver), +++ Intense FDG uptake (SUV 2-2.5 and FDG uptake more than the liver). Those who showed high-grade (+++) intensity were considered for the analysis. tandard uptake values with negative contrast in the normal gut var from 1.7 ± 0.5 . This was to see the effect of contrast on the uptake of tracer by the gut. In other words, whether the contrast tends to increase the gut metabolic activity.

Gaseous distension was graded as, + Minimal gas in the abdomen,

++ Moderate gas in abdomen, +++ Large amount of gas in the abdomen. Analysis included patients with large gaseous content in the abdomen. The intent was to see whether more gas was produced by the gut as a resultant of the contrast agents.

RESULTS

Visualization of the stomach, duodenum, jejunum, and ileum and proximal colon was significantly improved with milk. Large bowel was unchanged. Values were % of patients showing good visualization of the various segments of the gut. $P < 0.005$ (stomach distension with water and milk from no intervention), P values 0.05-0.025 (for duodenum, jejunum, and proximal colon for milk) no significance for the three groups for large bowel. Comparison with reported data on volume showed no significant difference with milk and Volumen (*AJR 190:1307-1313, 2008) Intensity of FDG uptake was not significantly increased. Gaseous distension was reduced marginally as less air swallowing was seen with water and milk ingestion. Neither FDG uptake was increased by water and milk nor was there an increased accumulation of gas in the abdomen [Figures 1 and 2].

Figure 3 shows a, b, d, easy detectability of mesenteric, stomach, and colon masses with low background gut uptake due to absence of overcorrection with negative contrast agent, milk. In contrast (c) shows overcorrection effects of barium in the large bowel in a normal person.

The high Tumor to gut ratio improves the detectability of the tumor from the background activity as there is no overcorrection with low attenuation milk contrast. This increases the accuracy of detection of abnormal 18FFDG uptake with greater confidence.

DISCUSSION

CT attenuation correction algorithms are typically based on thresholds in the histograms of the CT attenuation values, followed by scaling of the segmented classes of pixel values.^[3] Therefore, the use of a negative oral contrast agent may be

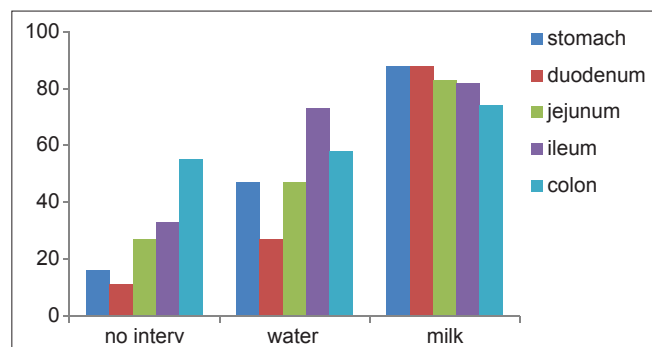


Figure 1: The distension criteria of the segments of the gut (% of patients with criteria 2 and 3). (Stomach 16%, 47%, 88%, 75%* [No intervention-18 patients, water-55 patients, milk-39 patients, Volumen – 100 patients*], Duodenum 11%, 27% 88%, 86%*, Jejunum 33%, 49%, 89%, 76%*, Ileum 40%, 77%, 82%, 80%*, Colon 55%, 58%, 74%, Volumen values were compared from the reference *AJR 190:1307-1313, 2008)

beneficial with the currently implemented attenuation-correction techniques in PET-CT scanners because they avoid contrast material-induced artifacts, while at the same time offering excellent intestinal distention for optimum CT diagnosis. Barium and iodine are known to have similar atomic numbers (barium, 56; iodine, 53), which causes very similar linear attenuation for each substance density.^[5] Barium and iodine are, therefore, expected to have analogous effects on CT-based PET attenuation correction. In- patients who had ingested barium, apparently increased tracer uptake was co-registered with the contrast-enhanced bowel lumen. The latter reflects increased attenuation in the bowel lumen, which results in apparently increased tracer uptake. Hence, the development of artifacts is common.

Negative contrast agents such as water, (0.2% Locust bean gum [LBG]) may reflect increased glucose utilization of the bowel wall as a result of increased fluid absorption (water) or secretion (mannitol-LBG).^[10-11] Water resorption is prevented by the osmotic property of mannitol and the thickening property of LBG, avoids an early diuretic urge. annitol alone, however, is known to induce watery diarrhea. LBG provides mitigating action based on its thickening properties.^[10] In addition to favorable PET-CT scanning characteristics, excellent bowel distention, and minimal effect on patient comfort, the mannitol-LBG containing 0.2% LBG solution is not expensive.^[12,13] Intestinal distention with mannitol-LBG proved superior to that with water or barium.

A diuretic urge complicated the examination of patients who ingested 2L of water. Induced by extensive water resorption during the 30 min whole-body PET-CT examination, the diuretic urge required the interruption of the examination. In addition, several patients felt uncomfortable. However, the use of water requires the additional use of an upper gastrointestinal smooth muscle relaxant and does not provide adequate evaluation of the distal small bowel.^[14]

Investigations of fat-containing oral contrast agents such as one comprising 12.5% corn oil showed excellent gastrointestinal

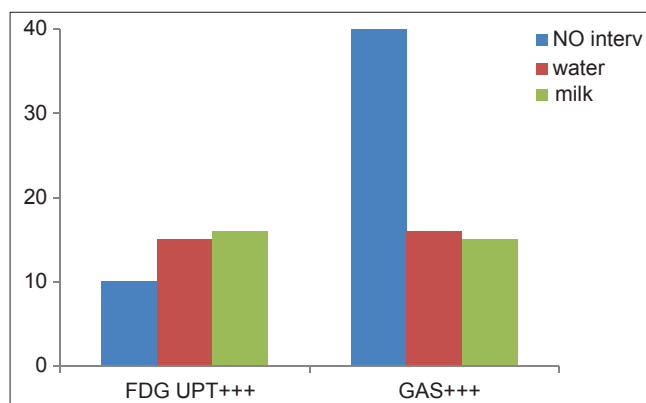


Figure 2: The effect of contrast on the 18FFDG uptake on the gut and gaseous distension (% of patients showing intense intestinal uptake +++ or SUV >2.5 and <3.5). Gaseous distension was analyzed as % of patients with large +++ amount of gas in the abdomen. (FDG uptake +++ SUV >2.5 and <3.5), no intervention-18 patients, water-55 patients, and milk-39 patients was 10%, 12% and 15% respectively, Colonic distension with gas +++ was 35%, 10%, and 12%)

tract discrimination and mural visualization without a significant difference in-patient tolerance as compared with barium suspension and iodine solutions.^[15] In addition, metoclopramide hydrochloride was required to promote gastrointestinal peristalsis inhibited by the high-fat content.

PEG provides better small-bowel distention and reaches the colon more readily than a full-strength fiber mixture and water the high-cost per examination and patients' dissatisfaction with this unpalatable mixture and its abdominal side-effects such as diarrhea prevented the wide-spread adoption of PEG preparations.

A study to assess the suitability of simethecone coated cellulose used in sonography was rated better than that of water.^[16]

Whole milk (4%) has been shown to be cost-effective,^[17] The fat contained in whole milk effectively slows upper gastrointestinal tract motility, obviating the use of either smooth muscle relaxants or metoclopramide hydrochloride. Whole milk provides superior mural visualization and discrimination of the pancreas and duodenum compared with barium-based contrast material and water. In addition, gastrointestinal tract distention and small-bowel discrimination were comparable to those in studies using a barium suspension and superior to imaging performed with water. Whole milk showed excellent distention of the stomach, duodenum, and jejunum compared with the small bowel. This phenomenon is probably because a portion of the oral contrast material was consumed immediately before scanning and it did not have sufficient time to exit the stomach. This situation is ideal for and is often used in pancreatic and biliary studies. The slightly decreased distention in the distal duodenum is likely secondary to peristalsis propelling the contrast material that was administered 45-60 mins before scanning into the distal small bowel, whereas, the contrast material administered immediately before scanning had not yet reached the distal duodenum. Distention of the duodenum, especially, the third portion, is further compromised by its anatomic situation between solid organs and vascular structures.

Similar to the distention results, visualization of the antral,

jejunal, and ileal walls was slightly better than visualization of the duodenal wall. The visualization results paralleling the distention data support the general observation that better bowel distention imparts better bowel wall visualization.

More recently, a newly developed low-attenuation 0.1% barium suspension (Volumen, E-Z-EM Inc.) has been shown to provide excellent gastrointestinal tract distention and superb visualization of mural features compared with barium suspension and a methylcellulose – water mixture. Increasing use of MDCT [multidetector CT] and the rising popularity of volume imaging have renewed a need for efficacious low-attenuation oral contrast agents because traditional high-attenuation contrast agents interfere with image processing techniques.

There was no statistically significant difference between whole milk and Volumen with respect to degree of bowel distention and mural visualization among all segments of bowel studied were observed. However, whole milk had better patient acceptance, fewer abdominal symptoms, and lower cost than Volumen. Moreover, patient satisfaction and willingness to ingest milk may lead to higher patient compliance especially, in the pediatric patients in undergoing CT examinations, which may lead to earlier detection and treatment of diseases.^[18]

In our own study, it was observed that there was no overcorrection of FDG in the gut with negative contrasts used such as water and milk and whereas, overcorrection is often observed in patients given positive contrast agents. Gaseous distention was not greater in patients given oral milk, which again would interfere in CT images due to air in the gut. It is therefore, suggested that a negative oral contrast is preferred in PET-CT studies and milk is a better agent than the other dark contrast agents used earlier. There are few studies using negative or dark contrast agents for PET-CT in contrast to those reported for CT imaging.^[20]

No study using milk as a contrast agent has been reported for PET-CT and we have been now using this procedure routinely for all our whole body PET-studies.

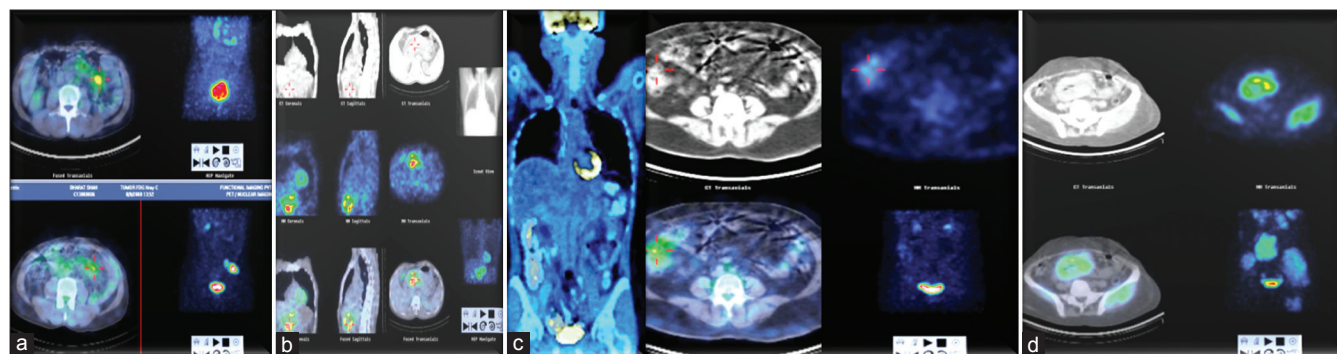


Figure 3: (a) Mesenteric metastasis, (b) stomach wall, (c) normal patient with positive oral contrast with over correction of normal. 18F FDG activity in the colon, (d) Colon mass with negative oral contrast (milk). Pelvic metastasis is also seen. Standard uptake values with negative contrast in the normal gut varies from 1.7 ± 0.5 while barium based. Oral contrast agents show SUVs of 2.5 ± 0.6

CONCLUSION

Negative oral contrast agents used for evaluation of F18FDG (F18Fluorodeoxyglucose) uptake in intramural lesions of the gut can be better delineated due to distension of the gut, which can show the dark distended loop with increased FDG uptake in the lesion of the thickened wall. High-density contrast agents due to overcorrection of the data would mask the lesion, which is not so easily distinguished from the contrast uptake of FDG.

Of the many negative contrast agents used the present usage of low-density contrast agent Volumen with 0.1% barium sulphate suspension is being recommended. However, there are some drawbacks such as cost, limited availability, and some patient discomfort such as nausea and vomiting as well as poor palatability.

Hence, the replacement with whole milk with 4% fat content has been shown to be as effective in distension of the gut so as to improve tumor distinction resulting from no overcorrection faults and also takes care of the disadvantages of Volumen. It is also a preferred agent in pediatric cases. A larger study needs to further corroborate these observations.

REFERENCES

1. Townsend DW. A combined PET/CT scanner: The choices. *J Nucl Med* 2001;42:533-4.
2. Beyer T, Townsend DW, Brun T, Kinahan PE, Charron M, Roddy R, *et al.* A combined PET/CT scanner for clinical oncology. *J Nucl Med* 2000;41:1369-79.
3. Kinahan PE, Townsend DW, Beyer T, Sashin D. Attenuation correction for a combined 3D PET/CT scanner. *Med Phys* 1998;25:2046-53.
4. von Schulthess GK. Cost considerations regarding an integrated CT-PET system. *Eur Radiol* 2000;10:S377-80.
5. Hubbell JH. Photon mass attenuation and energy-absorption coefficients from 1 keV to 20 MeV. *Int J Appl Radiat Isot* 1982;33:1269-90.
6. Carney J, Beyer T, Yap JT, Brass D, Townsend W. CT-based attenuation correction of PET/CT scanners. Presented at the IEEE Annual Meeting, San Diego, Calif 2001;November:11-5.
7. Franquiz JM, Ziffer JA, Vuong H, Young L, Lasso J. The effect of radiographic contrast on PET attenuation correction using a hybrid PET-CT device (abstr). *J Nucl Med* 2002;43:217.
8. Dizendorf EV, Treyer V, Von Schulthess GK, Hany TF. Application of oral contrast media in coregistered positron emission tomography-CT. *AJR Am J Roentgenol* 2002;179:477-81.
9. Cohade C, Osman M, Nakamoto Y, Marshall LT, Links JM, Fishman EK, *et al.* Initial experience with oral contrast in PET/CT: Phantom and clinical studies. *J Nucl Med* 2003;44:412-6.
10. Nakada K, Brown RS, Fisher SJ, Higashi T, Walter GL, Wahl RL. *et al.* Histological localization of tritiated FDG in the GI tract: An autoradiographic study (abstr). *J Nucl Med* 2001; (Supplement 1)42:25.
11. Antoch G, Kuehl H, Kanja J, Lauenstein TC, Schneemann H, Hauth E, *et al.* Dual-modality PET/CT scanning with negative oral contrast agent to avoid artifacts: Introduction and evaluation. *Radiology* 2004;230:879-85.
12. Schunk K, Kersjes W, Schadmand-Fischer S, Grebe P, Kauczor HU, Thelen M. A mannitol solution as an oral contrast medium in pelvic MRT. *Rofo* 1995;163:60-6.
13. Laniado M, Kornmesser W, Hamm B, Clauss W, Weinmann HJ, Felix R. MR imaging of the gastrointestinal tract: Value of Gd-DTPA. *AJR Am J Roentgenol* 1988;150:817-21.
14. Winter TC, Ager JD, Nghiem HV, Hill RS, Harrison SD, Freeny PC. Upper gastrointestinal tract and abdomen: Water as an orally administered contrast agent for helical CT. *Radiology* 1996;201:365-70.
15. Raptopoulos V, Davis MA, Davidoff A, Karellas A, Hays D, D'Orsi CJ, *et al.* Fat-density oral contrast agent for abdominal CT. *Radiology* 1987;164:653-6.
16. Sahani DV, Jhaveri KS, D'souza RV, Varghese JC, Halpern E, Harisinghani MG, *et al.* Evaluation of simethicone-coated cellulose as a negative oral contrast agent for abdominal CT. *Acad Radiol* 2003;10:491-6.
17. Thompson SE, Raptopoulos V, Sheiman RL, McNicholas MM, Prassopoulos P. Abdominal helical CT: Milk as a low-attenuation oral contrast agent. *Radiology* 1999;211:870-5.
18. Koo CW, Shah-Patel LR, Baer JW, Frager DH. Cost-effectiveness and patient tolerance of low-attenuation oral contrast material: Milk versus VoLumen. *AJR Am J Roentgenol* 2008;190:1307-13.
19. Blake MA, Setty BN, Cronin CG, Kalra M, Holalkere NS, Fischman AJ, *et al.* Evaluation of the effects of oral water and low-density barium sulphate suspension on bowel appearance on FDG-PET/CT. *Eur Radiol* 2010;20:157-64.
20. Sun XG, Huang G, Zhang C, Chen Y, Xue H, Zheng P, *et al.* Comparison of the effect of positive and negative oral contrast agent in FDG PET/CT scan. *J Nucl Med*. 2006;47:149P.

How to cite this article: Meyer SA, Gawde S. Utility of negative oral contrast (milk with 4% fat) in PET-CT studies. *Indian J Nucl Med* 2012;27:151-5.

Source of Support: Nil. **Conflict of Interest:** None declared.