

## CASE REPORT

## Spontaneous Isolated Bilateral Iliac Artery Dissection in a Patient with Relapsing Polychondritis

Astrid Rycx<sup>\*</sup>, Gilles Uijterhaegen, Eva-Line Decoster, Jan De Letter

Department of Vascular Surgery, AZ Sint-Jan Brugge, Brugge, Belgium

**Introduction:** Isolated iliac artery dissection (IAD) is a rare form of arterial dissection. The most commonly known causes of non-traumatic isolated iliac dissection are connective tissue diseases. Relapsing polychondritis (RP) is a rare inflammatory and multisystemic disease, typically affecting cartilage and connective tissue. Cardiovascular complications occur in approximately 25% of patients with RP.

**Case description:** The first case of spontaneous isolated bilateral iliac artery dissection in a patient with RP is reported. A 48-year-old woman presented with a two year history of severe right leg intermittent claudication (Rutherford category 3). The complaints were initially attributed to joint pathology associated with RP. However, clinical examination and computed tomography angiography led to a diagnosis of bilateral IAD. A dissection in the left common iliac artery (CIA) began at its origin and ended at the origin of the internal iliac artery, with the true and false lumen both comprising half of the entire lumen. The right CIA was completely occluded from its origin to the origin of the right internal iliac artery. The patient was treated endovascularly by bilateral CIA stent placement with covered stent grafts (Bentley BeGraft), 8 × 57 mm on the right side and 8 × 37 mm on the left. The patient recovered pedal pulses, the stent remained patent, and the patient was asymptomatic at the one month follow-up.

**Discussion:** Early identification of intermittent claudication is necessary to prevent the progression of complications in patients with RP. Vascular surgeons should be aware of IAD as the potential first presentation of underlying systemic disease. Internists should also keep vascular complications in mind in patients with systemic diseases like RP suffering from unexplained complaints in the lower limbs, undertake a basic vascular examination, and make a vascular referral where appropriate.

© 2022 The Authors. Published by Elsevier Ltd on behalf of European Society for Vascular Surgery. This is an open access article under the CC BY-NC-ND license (<http://creativecommons.org/licenses/by-nc-nd/4.0/>).

Article history: Received 27 May 2021, Revised 23 November 2021, Accepted 14 January 2022,

**Abbreviations:** ABI Ankle brachial index, CIA Common iliac artery, CTA Computed tomography angiography, IC Intermittent claudication, IIAD Isolated iliac artery dissection, PET-CT Positron emission tomography computed tomography, RP Relapsing polychondritis, SEM Standard Error of Mean

**Keywords:** Claudication, Iliac artery dissection, Inflammatory disease, Relapsing polychondritis

### INTRODUCTION

Isolated iliac artery dissection (IIAD) is a rare form of arterial dissection. The aorta and the carotid artery are the two most common sites for artery dissection. The most commonly known causes of non-traumatic isolated iliac artery dissection are connective tissue diseases such as Marfan syndrome, Ehlers–Danlos syndrome, fibromuscular dysplasia and cystic medial degeneration, and Erdheim-Gsell syndrome.<sup>1–5</sup> Exertion has also been described as a possible cause for spontaneous iliac artery dissection.<sup>6</sup>

Relapsing polychondritis (RP) is a rare multisystemic disease of inflammatory origin that typically affects the cartilage and connective tissue. The prevalence of this disease is unknown; the incidence is estimated at 1/285 000 per year. It is characterised by recurrent episodes of acute inflammation in several anatomical regions, including proteoglycans, which are the core elements of cartilage and connective tissue. Typically involved are the nose, ears, tracheobronchial tree cartilage, and peripheral joints, but the cardiovascular system can also be affected. Cardiovascular complications have been reported in about 25% of patients with RP. Cardiovascular complications have the second highest share of cause of death, after pneumonia, in patients with RP. Examples of these complications are aortic dissection, aortic aneurysm, valvular heart disease, and systemic vasculitis.<sup>7,8</sup>

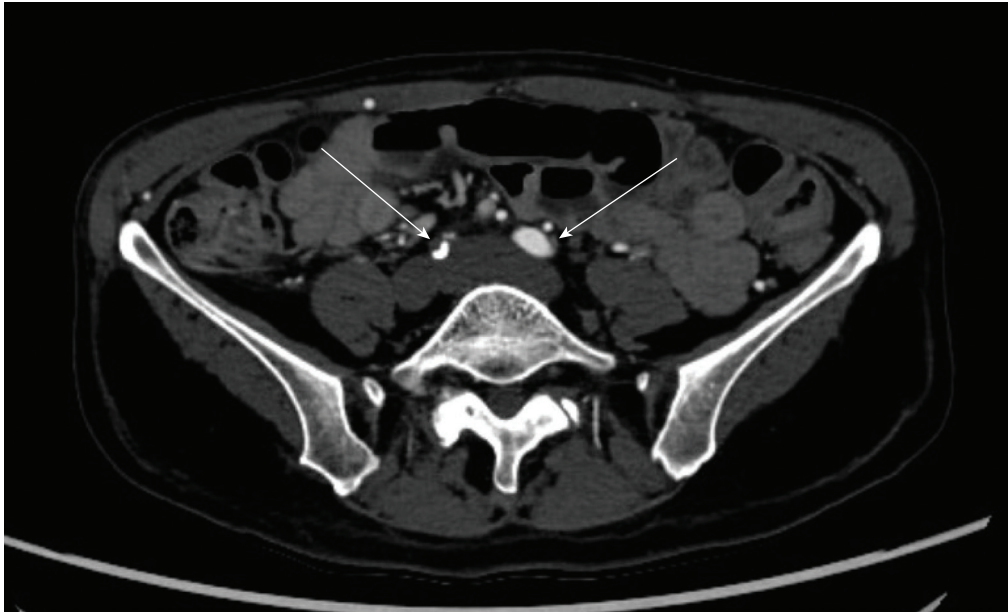IIAD in patients with RP has not yet been described.

<sup>\*</sup> Corresponding author. Department of Vascular Surgery, AZ Sint-Jan Brugge, Ruddershove 10, 8000 Brugge, Belgium.

E-mail address: [astrid.rycx@ugent.be](mailto:astrid.rycx@ugent.be) (Astrid Rycx).

2666-688X/© 2022 The Authors. Published by Elsevier Ltd on behalf of European Society for Vascular Surgery. This is an open access article under the CC BY-NC-ND license (<http://creativecommons.org/licenses/by-nc-nd/4.0/>).

<https://doi.org/10.1016/j.ejvsf.2022.01.011>



**Figure 1.** Computed tomography angiography image showing dissection of the left common iliac artery (CIA) and occlusion of the right CIA.

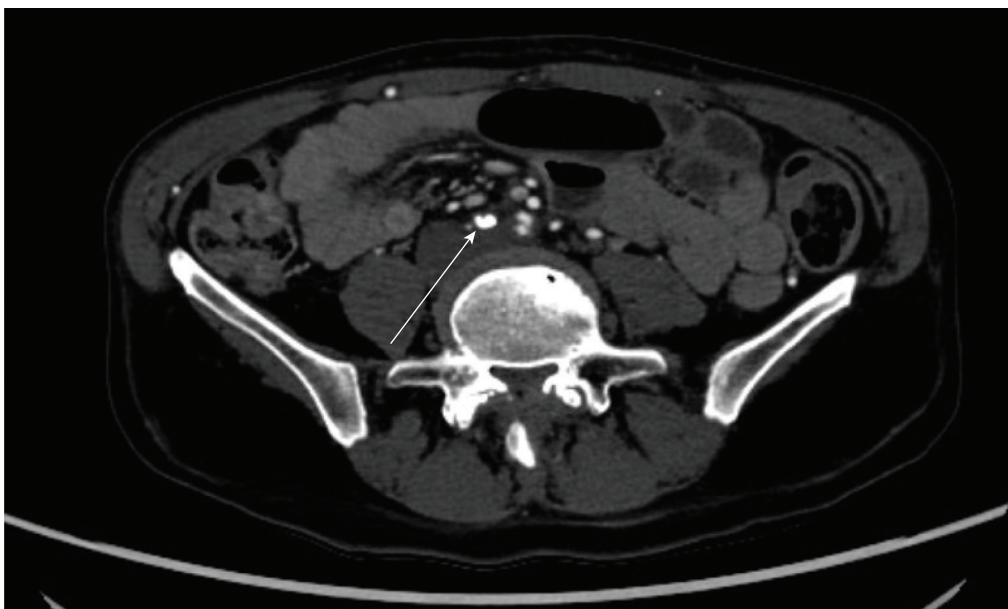
This paper reports a case of isolated bilateral common iliac artery (CIA) dissection in a patient with RP whose complaints were resolved after successful endovascular treatment.

#### **CASE REPORT**

A 48-year-old woman presented to the vascular surgery department with a two year history of severe intermittent claudication (IC) of the right leg (Rutherford category 3). The

IC was disabling for the patient but had been stable without further deterioration.

Five years earlier the patient experienced an acute inflammatory episode with involvement of multiple anatomical regions. In the eyes, the inflammation presented as panscleritis, episcleritis, uveitis, and impending retinal detachment. In the skin there were patchy lesions and lymphocytic vasculitis. Further, she suffered from polyarthralgia, with the costochondral and sternoclavicular junctions as most pronounced locations. Blood analysis



**Figure 2.** Computed tomography angiography showing the dissection of the left common iliac artery (CIA) and a calcified occlusion of the right CIA.

showed leukocytosis ( $12.9 \times 10^9/L$ ), and an elevated C reactive protein (121.8 mg/L) and sedimentation rate (51 mm/hour). Autoimmune serology was negative and fluorodeoxyglucose positron emission tomography computed tomography (PET-CT) showed no pathological tracer capture. Based on the multiple combined clinical manifestations, the diagnosis of RP was made. The patient was initially treated with high dose corticosteroids, later in combination with azathioprine, and, finally, she was treated with dapsone monotherapy.

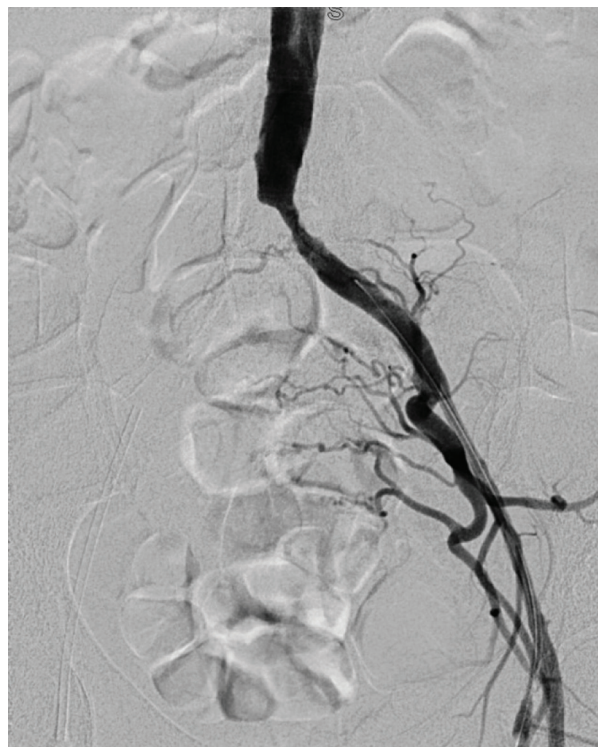
The cardiovascular history of this patient was negative and the cardiovascular risk factors were smoking and arterial hypertension. Hypertension was treated with ramipril 5 mg once daily.

Initially, the pain in the right leg was attributed to joint pathology. A whole body bone scan showed a maxillary sinusitis and degeneration of the L4–L5 facet joint. PET-CT revealed the same results, but a vascular origin of her complaints was not initially investigated. Approximately two years passed before the possibility of a vascular problem was considered.

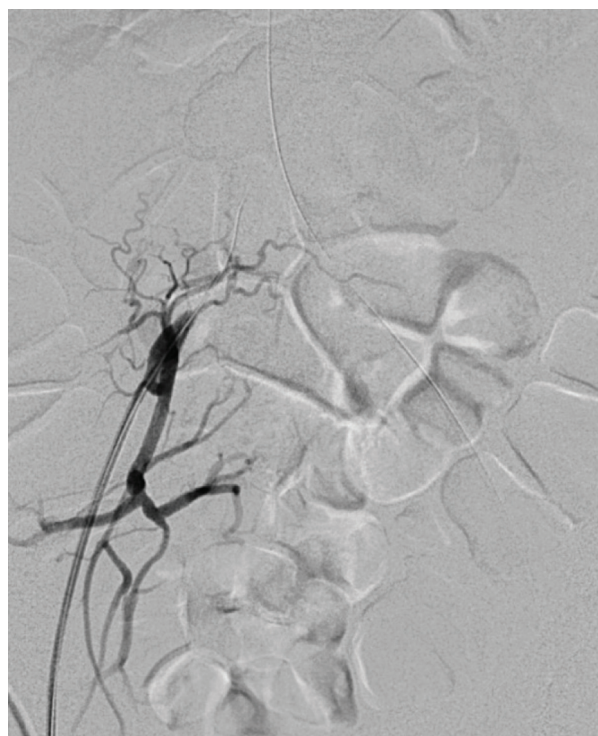On physical examination, neither leg was ischaemic, however, femoral pulses were absent. The ankle brachial index (ABI) was 0.4 on the right side and 0.5 on the left. Computed tomography angiography (CTA) showed an occlusion of the right CIA, a dissection of the left CIA, and remarkably little atherosclerosis in the other vascular segments (Figs. 1 and 2). Endovascular treatment was scheduled.

Bilateral retrograde common femoral artery access was obtained, but it was not possible to advance the 0.035" wire into the aorta through the right CIA, because it was not possible to get into the true lumen. The wire spontaneously crossed over through the false lumen into the false lumen of the left CIA. Through the left common femoral artery, a second wire was inserted and moved through the true lumen up into the aorta. With a wire in the false lumen from the right to the left CIA (crossover) and another wire in the true lumen on the left side a  $4 \times 40$  mm balloon was inserted on each side and inflated simultaneously in the left CIA. By this manoeuvre, the dissection flap was "cracked". Subsequently, the wire on the right side was advanced from the false lumen in the right CIA to the true lumen in the distal aorta. Bilateral common iliac stent placement was performed with covered stent grafts (Bentley BeGraft),  $8 \times 57$  mm on the right side and  $8 \times 37$  mm on the left. The stents were placed in the terminal aorta proximally and did not reach the external iliac arteries. The internal iliac arteries remained patent (Figs. 3–6).

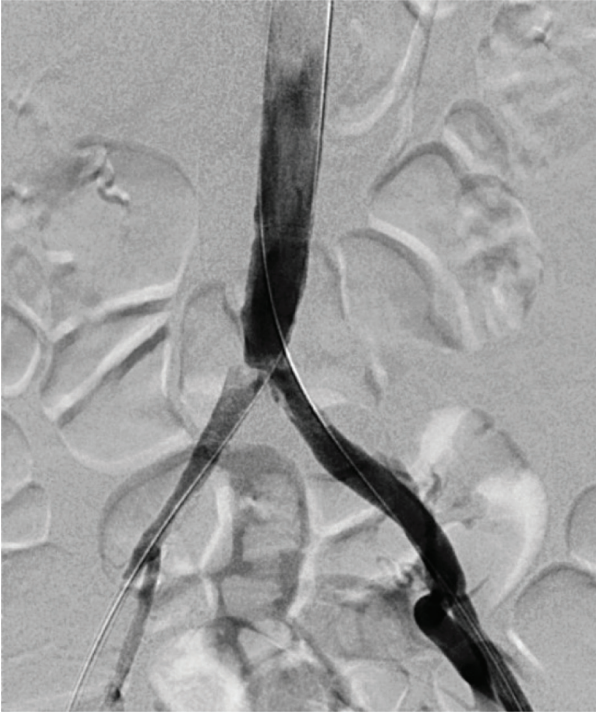
The post-operative course was uneventful; the patient had bilateral femoral and pedal pulses. She was discharged on the first post-operative day with medical treatment consisting of acetylsalicylic acid 80 mg once daily lifelong and clopidogrel 75 mg once daily for three months. Additional primary thrombolysis prophylaxis with nadroparin 3800 IU was prescribed for 10 days. At the one month follow-up, the patient remained asymptomatic. She had good distal pulses and an ABI of 1.1 on both sides.



**Figure 3.** Peri-operative angiography of the true lumen of the left common iliac artery.



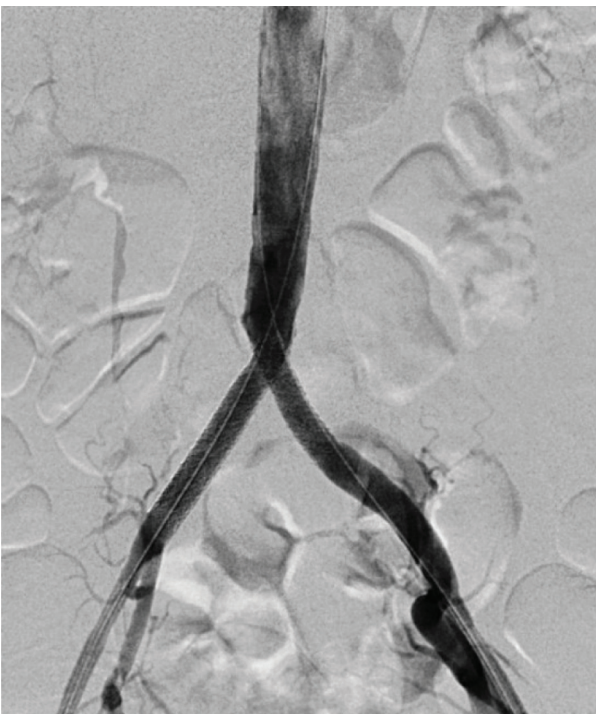
**Figure 4.** Peri-operative angiography showing an occlusion of the right common iliac artery.



**Figure 5.** Peri-operative angiography showing a recanalised right common iliac artery with visible dissection flaps in both common iliac arteries.

## DISCUSSION

Vascular complications are not well known in the context of RP.



**Figure 6.** Peri-operative angiography after bilateral stent placement in both common iliac arteries.

Although there was no awareness of the connection between RP and vascular disease, an explanation was sought for the presentation of an atypical IAD in a 48-year-old woman with little atherosclerosis on CTA.

Several aetiological factors can be identified for this presentation of atypical dissection. IAD has previously been associated with systemic disorders.<sup>4</sup> The pathogenesis of RP consists of connective tissue destruction and replacement by fibrous tissue. This can cause weakening of the arterial wall and progression to dissection.<sup>7</sup> An important causal factor for IAD is atherosclerosis.<sup>4,9,10</sup> Although this patient was a smoker and suffered from arterial hypertension, remarkably little atherosclerosis was detected on CTA. Further, she had been treated with corticosteroids and immunosuppressants for several years to control the RP. Lengthy administration of these drugs is known to affect tissue strength adversely and increase the risk of dissection.<sup>7</sup>

There are several treatment options for IAD. Some cases of spontaneous resolution have been reported. Conservative treatment is an option in asymptomatic patients with a normal ABI. The risk of complications such as rupture, occlusion, dissection, and the formation of (pseudo) aneurysms have to be weighed when this treatment option is chosen.<sup>6,10</sup> Endovascular treatment is mostly applied in elective IAD cases, when patients have symptoms but no evidence of rupture. Also, in very ill patients, who are not fit for open surgery, endovascular treatment is a feasible option. Endovascular treatment with percutaneous transluminal angioplasty alone has been reported to be effective and less expensive than stenting. However, in most cases of IAD, covered stents were used with continuing false lumen exclusion during long term follow up.<sup>4,6,9</sup> Open surgery with distal dissection flap repair is preferred in urgent cases complicated by rupture and when endovascular treatment has failed.<sup>4,6,9</sup> This paper reports IAD that had existed for several months in a symptomatic patient with underlying RP. This patient met the conditions for endovascular treatment. Bilateral common iliac stent placement with covered stents was performed. Follow-up showed an asymptomatic patient with good pedal pulses.

The limitations of this report are mainly the lack of long-term follow-up, and the inability to demonstrate a causal relationship between the systemic disease and the dissection. In addition, there are the intrinsic limitations of a case report, such as not being able to extrapolate the results to a larger group since it concerns only one case.

## CONCLUSION

This is the first case report of a spontaneous IAD as a rare vascular complication in a patient with RP. Increased awareness of IAD as the first presentation of an underlying systemic disease such as RP is important for vascular surgeons.

Raised awareness is necessary especially in patients not at risk, based on sex, medical history, or risk factors. However, it is also important for internists to keep vascular complications in mind in patients with systemic diseases like RP who are suffering from unexplained complaints in the

lower limbs. Early referral to a vascular surgeon can lead to early treatment, resolution of the symptoms, and increased quality of life. Endovascular surgery is a suitable treatment option for elective IAD cases and has shown a good short-term outcome.

#### FUNDING

None.

#### CONFLICT OF INTEREST

None.

#### APPENDIX A. SUPPLEMENTARY DATA

Supplementary data related to this article can be found at <https://doi.org/10.1016/j.ejvsf.2022.01.011>.

#### REFERENCES

- 1 Barker SG, Burnand KG. Retrograde iliac artery dissection in Marfan's syndrome. A case report. *J Cardiovasc Surg (Torino)* 1989;**30**:953–4.
- 2 Abayazeed A, Hayman E, Moghadamfalahi M, Cain D. Vascular type Ehlers-Danlos syndrome with fatal spontaneous rupture of a right common iliac artery dissection: case report and review of literature. *J Radiol Case Rep* 2014;**8**:63–9.
- 3 Lück I, Hanschke D, Geissler C, Gruss JD. Spontaneous dissection of the external iliac artery due to fibromuscular dysplasia. *Vasa* 2002;**31**:115–21.
- 4 Honjo O, Yamada Y, Kuroko Y, Kushida Y, Une D, Hioki K. Spontaneous dissection and rupture of common iliac artery in a patient with fibromuscular dysplasia: a case report and review of the literature on iliac artery dissections secondary to fibromuscular dysplasia. *J Vasc Surg* 2004;**40**:1032–6.
- 5 Dueppers P, Jankowiak S, Schelzig H, Wagenhäuser MU, Oberhuber A. Spontaneous rupture of an isolated iliac artery dissection in a young man because of cystic medial degeneration Erdheim-Gsell. *Ann Vasc Surg* 2015;**29**:596.
- 6 Cook PS, Erdoes LS, Selzer PM, Rivera FJ, Palmaz JC. Dissection of the external iliac artery in highly trained athletes. *J Vasc Surg* 1995;**22**:173–7.
- 7 Iida M, Orime Y, Umeda T, Ishii Y, Shiono M. Emergency repair of acute aortic dissection in a patient with relapsing polychondritis. *Ann Thorac Cardiovasc Surg* 2013;**19**:158–61.
- 8 Selim AG, Fulford LG, Mohiaddin RH, Sheppard MN. Active aortitis in relapsing polychondritis. *J Clin Pathol* 2001;**54**:890–2.
- 9 Spinella G, Pane B, Perfumo MC, Palombo D. Spontaneous iliac artery dissection treated with a combination of covered and self-expandable stents to preserve hypogastric patency. *J Vasc Surg Cases* 2016;**2**:14–7.
- 10 Engin C, Calkavur T, Apaydin AZ, Durmaz I. Bilateral spontaneous and isolated dissection of the external iliac arteries: report of a case. *EJVES Extra* 2005;**9**:19–21.