


Case Report

Robot-assisted radical cystectomy in a patient with muscle-invasive bladder cancer following radiotherapy for prostate cancer

Yuka Kubota,¹ Shingo Hatakeyama,¹  Takuya Hashimoto,¹ Naoki Fujita,¹ Teppei Okamoto,¹ Yuichiro Suzuki,¹ Hayato Yamamoto,¹ Atsushi Imai,¹ Takahiro Yoneyama,² Yasuhiro Hashimoto,¹ Takuya Koie³ and Chikara Ohyama^{1,2}

¹Department of Urology, and ²Department of Advanced Transplant and Regenerative Medicine, Hirosaki University Graduate School of Medicine, Hirosaki, and ³Department of Urology, Gifu University Graduate School of Medicine, Gifu, Japan

Abbreviations & Acronyms

GCb = gemcitabine plus carboplatin
 IMRT = intensity-modulated radiation therapy
 MIBC = muscle-invasive bladder cancer
 NAC = neoadjuvant chemotherapy
 PC = prostate cancer
 POD = postoperative day
 QOL = quality of life
 RARC = robot-assisted radical cystectomy
 RARP = robotic-assisted radical prostatectomy
 RC = radical cystectomy
 RT = radiotherapy

Introduction: Muscle-invasive bladder cancer following radiotherapy for prostate cancer is rare. We reported a case of muscle-invasive bladder cancer who underwent robot-assisted radical cystectomy following radiotherapy for prostate cancer.

Case presentation: A 72-year-old man was referred to our division with a muscle-invasive bladder cancer. He had a history of intensity-modulated radiation therapy for localized prostate cancer. After three courses of platinum-based neoadjuvant chemotherapy, he obtained a radiologic complete response. He elected for robot-assisted radical cystectomy, standard lymph node dissection, and intracorporeal ileal conduit urinary diversion. Pathological findings revealed no residual tumor within the bladder and residual tumor in the prostate. He had discharged without any complications; and quality of life had improved.

Conclusion: A robot-assisted approach might be a potential option for well-selected patients with muscle-invasive bladder cancer who have previously received radiotherapy for localized prostate cancer.

Key words: muscle-invasive bladder cancer, prostate cancer, radiotherapy, risk, robot-assisted radical cystectomy.

Correspondence: Shingo Hatakeyama M.D., Ph.D., Department of Urology, Hirosaki University Graduate School of Medicine, 5 Zaifu-cho, Hirosaki 036-8562, Japan. Email: shingoh@hirosaki-u.ac.jp

This is an open access article under the terms of the Creative Commons Attribution-NonCommercial License, which permits use, distribution and reproduction in any medium, provided the original work is properly cited and is not used for commercial purposes.

Received 15 April 2019;
 accepted 21 May 2019.
 Online publication 13 June 2019

Keynote message

Although surgical treatment for patients with MIBC who have previously received RT for PC is challenging, this report indicates a robot-assisted approach might be a potential option for well-selected patients with MIBC who have previously received RT for localized PC.

Introduction

The incidence of MIBC following RT for PC is rare. RT for PC increases the risk for secondary bladder cancer with a risk ratio of 1.5.^{1,2} With the increasing use of RT as a primary treatment for PC, the increasing risk of bladder cancer after RT for PC requires attention. Although RC remains the gold standard treatment for MIBC, a surgical treatment for these patients is challenging. RARC might be an option to reduce the surgical risk including complication. However, few cases of RARC have been reported in patients with PC after RT.^{3,4} Herein, we reported a case of a patient with MIBC who underwent RARC following RT for PC.

Case presentation

A 72-year-old man received 76 Gy of IMRT for localized PC (initial prostate-specific antigen level, 8.16 ng/mL; clinical stage, T1cN0M0; the Gleason score, 3 + 4; intermediate risk group). Two years after IMRT, he had macroscopic hematuria. Contrast-enhanced computed tomography revealed the presence of MIBC cT3N0M0 (Fig. 1a). Transurethral resection of the bladder tumor revealed a high-grade urothelial carcinoma. Subsequently, he received carboplatin-based NAC (GCb) because of the renal impairment. Three courses after neoadjuvant GCb, he obtained a complete response (Fig. 1b). He was elected for RARC with nerve-sparing procedure,

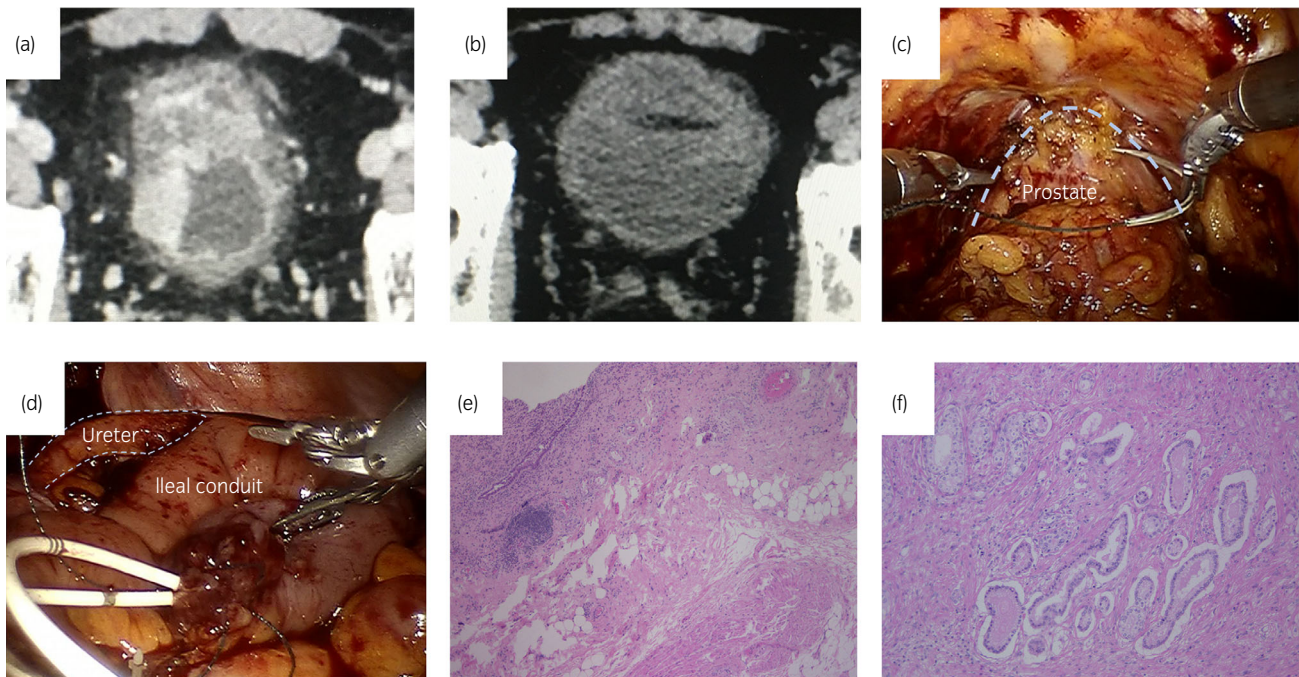


Fig. 1 Treatment outcomes. (a) Contrast-enhanced computed tomography shows a well-enhanced tumor of the bladder, invading all layers of the bladder. (b) Complete radiological response following three courses of NAC. Intraoperative finding of RARC. (c) Mild fibrous adhesion around periprostatic lesions. (d) Ileal conduit urinary diversion with the Wallace ureteroenteric anastomoses was performed as an intracorporeal urinary diversion. (e) Histopathological findings reveal no residual tumor in the urinary bladder, diagnosed as pT0. (f) Residual tumor (Gleason score 3 + 3, pT2a) detected within the prostate.

standard lymph node dissection, and ileal conduit urinary diversion. Mild fibrous adhesion was observed around periprostatic lesions (Fig. 1c). As no tight adhesion was observed between the prostate and rectum, the separation of denonvilliers fascia was not challenging. Intracorporeal ileal conduit urinary diversion was performed (Fig. 1d). The operative duration and blood loss were 448 min and 210 g, respectively. The operative duration and blood loss were 448 min and 210 g, respectively. Although postoperative hemoglobin concentration was temporarily decreased from 9.9 to 7.8 g/dL, it was improved without perioperative blood transfusion. Pathological findings revealed no residual tumor (pT0) (Fig. 1e) and no lymph node metastasis (pN0). The residual tumor (Gleason score 3 + 3, pT2a) was detected within the prostate (Fig. 1f). The patient resumed peroral intake at POD 3, removed drainage tube and stent at POD 8 and POD 16, respectively.

The patient was discharged without any complications at POD 30. We evaluated his QOL before and 6 months following RARC using the European Organization for Research Treatment of Cancer QLQ-30 ver. 3.0. Global functional (Fig. 2a) and symptom QOL (Fig. 2b) scores had improved 6 months following RARC from those before MIBC treatment.

Discussion

We reported a case of RARC in a patient irradiated for PC, which showed the feasibility and safety of RARC in such a challenging case. RT for PC has been associated with a consistent increase in other pelvic malignancies, and bladder cancer risk has been reported in several studies.^{1,2,5} As patients who previously received RT for PC are not eligible for bladder preservation

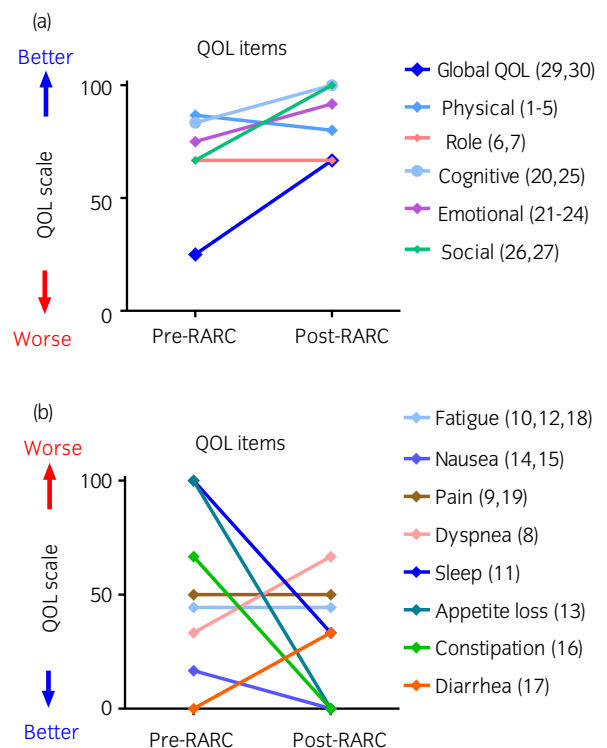


Fig. 2 QOL outcomes. (a) Comparison results of the QOL score before and 6 months following RARC showed improvement in global, physical, cognitive, emotional, and social QOL. (b) In the symptom QOL, nausea, sleep, appetite loss, and constipation showed improvement, whereas fatigue, pain, dyspnea, and diarrhea did not. A comparative change between constipation and diarrhea might have been caused by intestinal resection accompanying urinary diversion.

strategies, treatment options for patients with MIBC who have previously received RT for PC are limited. In addition, RC would be challenging due to fibrotic changes in the pelvis induced by radiation. An increased risk of complications was reported following pelvic radiation in open cystectomy.⁶ However, a previous study that investigated the safety of RARC in patients with previous history of pelvic irradiation concluded that complication rates were not differ between the patients with and without pelvic radiation.³ In addition, recent study for salvage RARP after radiation therapy suggested low complications rates including rectal injuries (<2%).^{7–9} A robotic procedure can overcome the difficulty of separation between the prostate and rectum. Based on this report, we selected RARC as definitive therapy for MIBC. As RARC can provide a fine and detailed view of the surgical field,^{10–12} we performed precision operation including the nerve-sparing procedure, exfoliation of fibrotic tissues around the prostate, bladder, and rectum. Therefore, RARC is one of the options in selected patients with a previous history of pelvic irradiation.

MIBC patients with a history of pelvic irradiation have been reported with more advanced disease than *de novo* MIBC.^{1,4,5} Cisplatin-based NAC improves survival outcomes in patients with MIBC.^{12–16} However, the efficacy of NAC for irradiation-related MIBC remains unclear. Although a cisplatin-based regimen is suggested as NAC, this patient was ineligible for cisplatin due to renal impairment. We selected three courses of neoadjuvant GCb and this patient obtained the pathological complete response. Although inferior efficacy of a carboplatin-based regimen has been suggested, our previous study showed a low toxicity GCb regimen facilitated in completion of NAC, prevention of the delay in RC, and resulted in a favorable oncological and QOL outcome.^{12,14–20} Therefore, neoadjuvant GCb might be an alternative option for MIBC patients with renal impairment. Further studies are necessary to identify the ideal regimens for NAC including oncological and QOL outcomes.

Radiation treatment modality is a key point for patient selection for a surgical approach. As IMRT made radiation field reduction on the peri-prostate and reduction in fibrotic change and adhesion around the prostate tissue possible, we neither had any difficulty performing RARC nor observed any postoperative complications. Although not many case series of salvage RARP after brachytherapy or proton therapy were reported, several studies suggested feasible outcomes in complications and functional outcomes.^{7–9} Moreover, the patient achieved QOL improvement 6 months following RARC in the global, physical, cognitive, emotional, social nausea, sleep, appetite loss, and constipation. Negative influence on diarrhea might be related to ileal conduit urinary diversion.

Conclusion

This case highlights a potential benefit of RARC for well-selected patients with MIBC who have previously received RT for localized PC. The benefit of RARC in those patients needs further investigations.

Acknowledgments

This work was supported by the Japan Society for the Promotion of Science (No. 17K11119, 17K16768, 17K16770, and

17K16771). The authors would like to thank Daisuke Noro, Masaki Momota, and Yuki Fujita for their invaluable support.

Ethical statement

This study was approved by the institutional ethics committee of Hirosaki University School of Medicine (No. 2018-062).

Conflict of interest

The authors declare no conflict of interest.

References

- Bostrom PJ, Soloway MS, Manoharan M, Ayyathurai R, Samavedi S. Bladder cancer after radiotherapy for prostate cancer: detailed analysis of pathological features and outcome after radical cystectomy. *J. Urol.* 2008; **179**: 91–5.
- Wallis CJ, Mahar AL, Choo R *et al.* Second malignancies after radiotherapy for prostate cancer: systematic review and meta-analysis. *BMJ* 2016; **352**: i851.
- Al Hussein Al Awamlh B, Nguyen DP, Otto B *et al.* The safety of robot-assisted cystectomy in patients with previous history of pelvic irradiation. *BJU Int.* 2016; **118**: 437–43.
- Nguyen DP, Al Hussein Al Awamlh B, Faltas BM *et al.* Radical cystectomy for bladder cancer in patients with and without a history of pelvic irradiation: survival outcomes and diversion-related complications. *Urology* 2015; **86**: 99–106.
- Sandhu JS, Vickers AJ, Bochner B, Donat SM, Herr HW, Dalbagni G. Clinical characteristics of bladder cancer in patients previously treated with radiation for prostate cancer. *BJU Int.* 2006; **98**: 59–62.
- Kim HL, Steinberg GD. Complications of cystectomy in patients with a history of pelvic radiation. *Urology* 2001; **58**: 557–60.
- Eandi JA, Link BA, Nelson RA *et al.* Robotic assisted laparoscopic salvage prostatectomy for radiation resistant prostate cancer. *J. Urol.* 2010; **183**: 133–7.
- Orre M, Piechaut T, Sargos P, Richaud P, Roubaud G, Thomas L. Oncological and functional results of robotic salvage radical prostatectomy after permanent brachytherapy implants. *Cancer Radiother.* 2017; **21**: 119–23.
- Gontero P, Marra G, Alessio P *et al.* Salvage radical prostatectomy for recurrent prostate cancer: morbidity and functional outcomes from a large multicenter series of open versus robotic approaches. *J. Urol.* 2019; <https://doi.org/10.1097/JU.0000000000000327>.
- Koie T, Ohyama C, Yoneyama T *et al.* Robotic cross-folded U-configuration intracorporeal ileal neobladder for muscle-invasive bladder cancer: initial experience and functional outcomes. *Int. J. Med. Robot.* 2018; **14**: e1955.
- Tyritzis SI, Wiklund NP. Is the open cystectomy era over? An update on the available evidence. *Int. J. Urol.* 2018; **25**: 187–95.
- Koie T, Ohyama C, Makiyama K *et al.* Utility of robot-assisted radical cystectomy with intracorporeal urinary diversion for muscle-invasive bladder cancer. *Int. J. Urol.* 2019; **26**: 334–40.
- Yin M, Joshi M, Meijer RP *et al.* Neoadjuvant chemotherapy for muscle-invasive bladder cancer: a systematic review and two-step meta-analysis. *Oncologist* 2016; **21**: 708–15.
- Anan G, Hatakeyama S, Fujita N *et al.* Trends in neoadjuvant chemotherapy use and oncological outcomes for muscle-invasive bladder cancer in Japan: a multicenter study. *Oncotarget* 2017; **8**: 86130–42.
- Fukushi K, Narita T, Hatakeyama S *et al.* Quality-of-life evaluation during platinum-based neoadjuvant chemotherapies for urothelial carcinoma. *Int. J. Clin. Oncol.* 2017; **22**: 366–72.
- Fukushi K, Narita T, Hatakeyama S *et al.* Difference in toxicity reporting between patients and clinicians during systemic chemotherapy in patients with urothelial carcinoma. *Int. J. Urol.* 2017; **24**: 361–6.
- Koie T, Ohyama C, Yamamoto H *et al.* The feasibility and effectiveness of robot-assisted radical cystectomy after neoadjuvant chemotherapy in patients with muscle-invasive bladder cancer. *Jpn. J. Clin. Oncol.* 2017; **47**: 252–6.
- Murasawa H, Koie T, Ohyama C *et al.* The utility of neoadjuvant gemcitabine plus carboplatin followed by immediate radical cystectomy in patients with muscle-invasive bladder cancer who are ineligible for cisplatin-based chemotherapy. *Int. J. Clin. Oncol.* 2017; **22**: 159–65.

- 19 Hosogoe S, Hatakeyama S, Kusaka A *et al.* Platinum-based neoadjuvant chemotherapy improves oncological outcomes in patients with locally advanced upper tract urothelial carcinoma. *Eur. Urol. Focus.* 2017; **4**: 231–40.
- 20 Momota M, Hatakeyama S, Tokui N *et al.* The impact of preoperative severe renal insufficiency on poor postsurgical oncological prognosis in patients with urothelial carcinoma. *Eur. Urol. Focus.* 2018; <https://doi.org/10.1016/j.euf.2018.03.003>.