

## Open Access

# Evaluation and Management of Caustic Injuries from Ingestion of Acid or Alkaline Substances

Kyung Sik Park

Department of Internal Medicine, Keimyung University School of Medicine, Daegu, Korea

Although the numbers have decreased compared with in the past, cases of patients who ingest caustic substances and visit the emergency room are not rare. However, well-summarized data about caustic injuries are insufficient. Therefore, in this article, I will discuss the etiologic causative agents, injury mechanism, and clinical characteristics, as well as the endoscopic evaluation of the degree of injury and proper management of the patient, in gastrointestinal caustic injury.

**Key Words:** Caustic injury; Acids; Alkalies

## INTRODUCTION

Ingestion of acid or alkaline caustic substances may cause serious injuries in the esophagus and stomach.<sup>1</sup> The degree of injury is determined by the nature of the substance (the degree to which it could cause corrosion), the amount consumed or its concentration and state (solid or liquid), and the time of contact with the gastrointestinal (GI) mucosa. In the United States, >5,000 cases of ingestion of caustic substances are reported annually. Although most cases occur in pediatric patients, some cases involve adults who attempt suicide, psychiatric patients, and alcoholic patients. More severe injuries to the esophagus and stomach occur if large quantities of substances are ingested, particularly in persons who attempt suicide.<sup>2</sup> However, worldwide estimates report that about 80% of cases are in pediatric patients.<sup>3</sup> Although precise data are scant, in Korea, 60% of cases were caused by ingesting caustic substances with the intention of committing suicide, and another 40% of cases were accidental.<sup>4,5</sup> Most of the cases involving the intent to commit suicide occur especially among young per-

sons in their teens and 20s.<sup>4,5</sup> Also, many of the reported patients who ingested caustic substances have accompanying psychiatric disorders including depression, schizophrenia, adjustment problems, and personality disorders.<sup>4,5</sup> Although the numbers have decreased compared with in the past, cases of patients who ingest caustic substances and visit the emergency room are not rare. Therefore, in this article, I will discuss the etiologic causative agents, injury mechanism, and clinical characteristics, as well as the endoscopic evaluation of the degree of injury and proper management of the patient, in GI caustic injury. As the focus of this discussion is the evaluation and management of patients under emergency settings, the discussion about chronic complications has been omitted.

## SUBSTANCES CAUSING CAUSTIC INJURY

In pediatric patients younger than 5 years, consuming caustic substances occurs accidentally; however, in teens and adults, it is mostly intentional with the goal of committing suicide.<sup>2</sup> Although many kinds of substances cause caustic injury,<sup>6,7</sup> the most common agent is a strong alkaline substance such as sodium hydroxide (NaOH) or potassium hydroxide (KOH), which usually includes disinfectants used in the home or laundry facilities, and discoid batteries.<sup>8</sup> The term "lye" refers to the liquid obtained from the leaching of ashes, including NaOH or KOH. Highly acidic substances, such as hydrochloric acid, sulfuric acid, and phosphoric acid, are used frequently to remove rust in bathrooms or swimming pools and may be

**Received:** March 21, 2014 **Revised:** April 13, 2014

**Accepted:** April 14, 2014

**Correspondence:** Kyung Sik Park

Department of Internal Medicine, Keimyung University Dongsan Medical Center, Keimyung University School of Medicine, 56 Dalseong-ro, Jung-gu, Daegu 700-712, Korea

**Tel:** +82-53-250-7088, **Fax:** +82-53-250-7088, **E-mail:** seenae99@dsmc.or.kr

© This is an Open Access article distributed under the terms of the Creative Commons Attribution Non-Commercial License (<http://creativecommons.org/licenses/by-nc/3.0>) which permits unrestricted non-commercial use, distribution, and reproduction in any medium, provided the original work is properly cited.

included in car batteries. These acidic materials are used less frequently than alkaline substances as a tool for suicide because they can induce severe pain.<sup>1</sup>

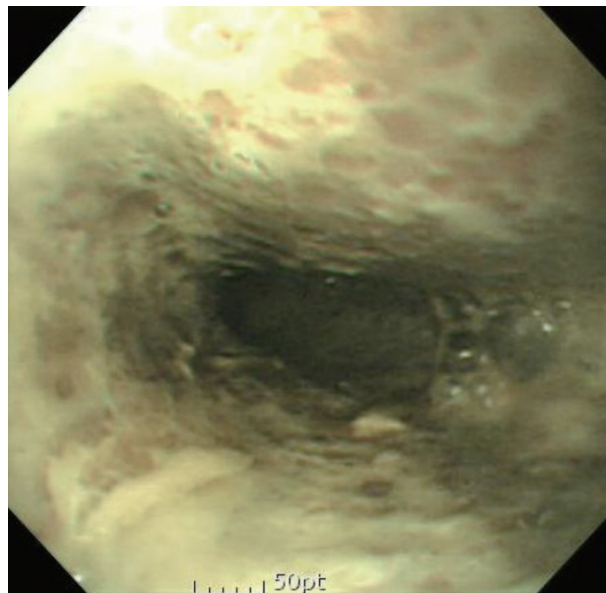In Korea, ingestion of alkaline substances was more common in the past; however, recently, cases of ingestion of acidic material have been increasing. This is thought to be due to a rapid decrease in the use of lye owing to the development of synthetic detergents, and at the same time, a relative increase in the use of acetic acid, which can be purchased easily.<sup>4,5,9</sup>

A solution of 5% sodium hypochlorite, which is used as bleach, is commonly known as “Rox.” This agent is frequently reported to be ingested, but it rarely injures the esophagus or stomach.<sup>10</sup> Button-type batteries contain highly alkaline substances, and if swallowed, serious tissue injury secondary to local current or pressure necrosis may occur. When these batteries are trapped in the esophagus, burns may occur within 4 hours and perforation may occur within 6 hours.<sup>8</sup> Therefore, in those cases, the batteries should be removed through emergent endoscopy.

## PATHOPHYSIOLOGY

Ingestion of alkaline substances is known to mainly injure the esophagus rather than the stomach or duodenum, whereas acidic materials injure mainly the stomach rather than the esophagus.<sup>1,11</sup> However, recent reports indicating that extensive esophageal injury or even perforation is not uncommon after ingestion of acids are putting this traditional notion into question.<sup>12</sup> In addition, both acidic and alkaline substances can injure the larynx, trachea, and bronchi.<sup>8</sup>

Ingestion of alkaline substances leads to liquefaction necrosis due to bonding with tissue protein (Fig. 1).<sup>1,8</sup> Therefore, it causes rapid injuries outside the esophagus toward the mediastinal wall. These responses continue until the alkaline substance is neutralized by the tissue fluids. In addition, alkaline fluid has a stronger surface tension and stays in the tissue for a longer period, thereby worsening the injury. Within the stomach, injuries are limited by the partially neutralizing mechanism of gastric acid.<sup>13</sup> In the case of extensive injury to the intestinal wall, complications such as perforation, mediastinitis, and peritonitis may occur and result in death. Liquid materials, rather than solid batteries, result in more extensive injuries.<sup>8</sup> Liquefaction necrosis occurs for 3 to 4 days and causes intravascular thrombus and mucosal inflammation, in addition to causing local or extensive putrefaction and ulceration. Over a period of 2 weeks, the esophageal wall is thinned with tissue putrefaction, granulation, and fibrosis; the process of reepithelialization takes 1 to 3 months. Therefore, endoscopic procedures should be avoided from 5 to 15 days after the ingestion of alkaline substances.<sup>14</sup> Stricture for-



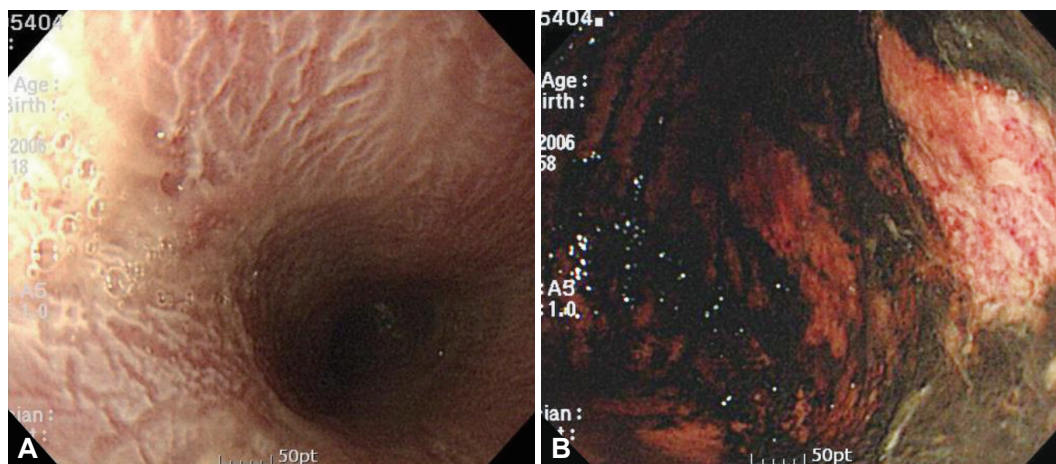
**Fig. 1.** Diffuse liquefaction necrosis of the entire esophagus is noted after the ingestion of alkaline substances.

mation, as a chronic complication, is ultimately affected by the depth of the esophageal injury and the degree of collagen accumulation. Therefore, the subsequent possibility of chronic complications or death increases in second- or third-degree injuries.<sup>13</sup>

Ingestion of acids usually causes superficial coagulation necrosis, in which formation of thrombi within the vessels and bundling of connective tissue lead to the formation of scar tissue. Therefore, very deep injuries that extend through all layers of the GI wall do not commonly develop after the ingestion of acidic substances.<sup>15</sup>

Upon swallowing, acids cause severe oropharyngeal pain; thus, they are usually consumed in small volumes compared with the alkaline substances. Acidic substances have less surface tension; therefore, they pass rapidly through the esophagus, resulting in a less frequency and a lower degree of esophageal injuries (Fig. 2A).<sup>1,8</sup> The ingested acidic substance flows rapidly to the pylorus through the lesser curvature of the stomach, causing widespread injury in the antrum (Fig. 2B). If there is some amount of food inside the stomach, injury can be prevented because of a neutralization effect. Despite this, if large quantities are consumed, esophageal or gastric perforation may occur.

Although, as stated above, caustic injury caused by alkaline substances is more severe, a comparative study revealed that the prognosis was less favorable for those who swallowed a strong acid.<sup>16</sup> In this study, the acid ingestion group showed a high frequency of severe complications such as perforation or death, a high degree of mucosal injury, and a high frequency of intensive care unit (ICU) admission. This is thought to be



**Fig. 2.** Caustic injury after the ingestion of acid material. Mild esophageal injury (A) is noted compared with widespread severe injury (B) in the stomach.

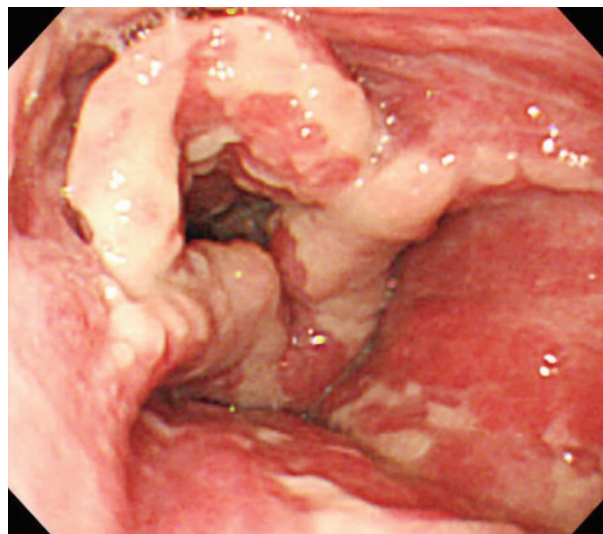
because the prognosis of caustic injury is influenced by the quantity ingested and the types of complication after ingestion rather than by the type of the ingested substance (acid or alkaline).

## GRADING OF THE CAUSTIC INJURY

The degree of injury from caustic substances can be categorized similarly to that of skin burns.<sup>14</sup> First-degree injuries are confined to the mucosal surface, and can show diffuse or localized erythema, edema, and bleeding. Scar formation does not ultimately occur. Second-degree injuries involve the mucosa and submucosa. Endoscopic examination can show various findings such as exudates or blister formation. Ultimately, scar changes can develop through the formation of granulation and fibrosis. Third-degree injuries include the entire wall layer, and are characterized by deep penetrating ulcers, black discoloration, or perforation of the intestinal wall.

## CLINICAL PRESENTATIONS

The clinical presentations of caustic injuries are very diverse, and initial symptoms do not show deep correlations with the ultimate degree of the injury.<sup>17</sup> Crystal or other solid materials easily adhere to the oral mucosa; therefore, they cause more severe injuries to the pharynx and upper airway rather than to the esophagus or stomach. In contrast, liquids can easily pass through the esophagus and stomach; therefore, they can cause extensive injury. The degree of injury is proportional to the mortality. Furthermore, the morbidity of chronic complication is also related to the degree of injury.<sup>18,19</sup> Depending on the injured area, pain may arise in the oropharynx, retrosternum, or epigastrium. Dysphagia, odynophagia, and excessive salivation may also occur. Continuous severe retro-



**Fig. 3.** Injury to the larynx and epiglottis after the ingestion of alkaline material. Vocal hoarseness, wheezing, and shortness of breath may occur upon injury to these areas.

sternal or back pain may indicate esophageal perforation or mediastinitis. Perforation may occur up to 2 weeks after ingestion; therefore, strict monitoring is essential.<sup>3</sup> In addition, depending on the extent of injury, vomiting, hematemesis, abdominal tenderness, and rebound tenderness may suddenly occur. Although rare, vocal hoarseness, wheezing, and shortness of breath may also occur upon injury to the larynx and epiglottis (Fig. 3). Fever, palpitations, and shock indicate extensive damages.

## DIAGNOSIS AND EVALUATION OF THE EXTENT OF INJURY

### Laboratory tests

Although the results of laboratory tests are not well corre-

lated with the degree of injury, a study suggests that white blood cell counts  $>20,000$  cells/mm<sup>3</sup>, increase in the C-reactive protein level, old age, and the presence of esophageal ulcers are predictive factors that are correlated with mortality.<sup>20</sup> Some reports state that an arterial pH  $<7.22$  may indicate esophageal injury requiring surgical management.<sup>21</sup> Usually, laboratory results contribute toward setting the direction of monitoring and management of the patient, rather than predicting the mortality.<sup>22</sup>

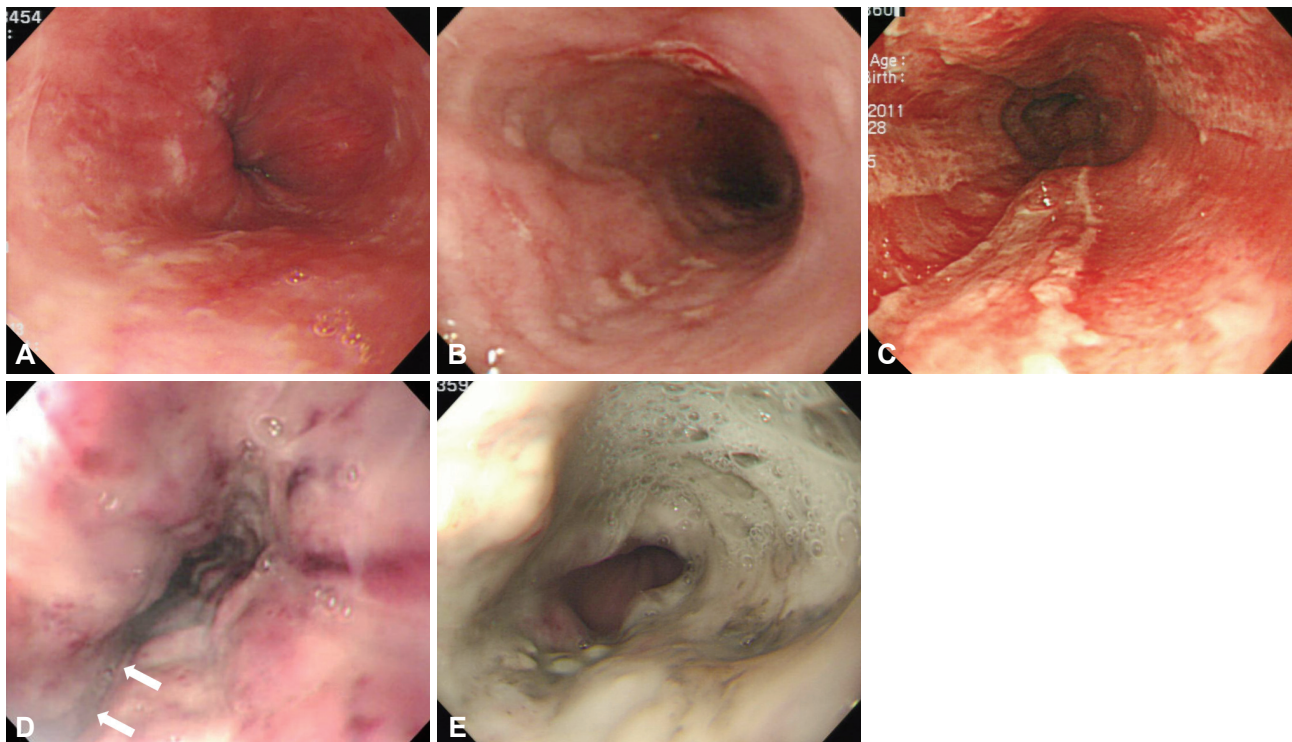
### Endoscopy

Some reports suggest that nonsymptomatic pediatric patients who have ingested low-potency substances do not require endoscopy. However, for adult patients who have ingested caustic substances with the intent to commit suicide, most of those substances are very potent, and therefore, emergent endoscopy is recommended for all patients.<sup>23</sup>

As an intact-looking oral cavity or pharynx cannot be used to exclude the possibility of esophageal or gastric injury, upper GI endoscopy should be performed within 24 hours of ingestion of caustic substances; however, several reports indicate that it can be safely done up to 96 hours after ingestion.<sup>16,24</sup> Upper GI endoscopy can be used to evaluate esophageal and gastric injuries, as well as to predict prognosis and establish a management plan.<sup>16,25</sup> However, it is contraindi-

cated in several patients, such as hemodynamically unstable patients, those suspected to have a perforation, those in severe respiratory distress, and patients with severe laryngo-pharyngeal edema or necrosis. For patients whose injury is focused around the lips and oral cavity, esophageal or gastric injury usually does not exceed the first-degree grading.<sup>26</sup>

To predict the treatment outcome and prognosis of patients with caustic injuries, endoscopic categorization of 81 patients was performed, and the subsequent categorization is widely used.<sup>14</sup> Grade 0 indicates a normal mucosa; grade 1 indicates only slight swelling and redness of the mucosa (Fig. 4A); grade 2A indicates the presence of superficial ulcers, bleeding, and exudates (Fig. 4B); grade 2B indicates local or encircling deep ulceration (Fig. 4C); grade 3A indicates focal necrosis (Fig. 4D); and grade 3B indicates extensive necrosis (Fig. 4E). Although further studies are needed to evaluate the validity of this endoscopic categorization, most patients with grade 1 or 2A injuries have good prognoses without sudden deaths, and they do not develop outlet obstruction or stricture of the esophagus. Approximately 70% to 100% of patients with grade 2B and 3A injuries develop stricture. For patients with grade 3B injuries, a mortality of 65% has been reported, and in the majority of cases, esophagectomy and colonic or jejunal replacement surgeries are required. However, several reports have indicated that 12% of gastrectomies and 15% of esopha-



**Fig. 4.** Endoscopic grading of the caustic gastrointestinal injury. (A) Grade 1 indicates only slight swelling and redness of the mucosa. (B) Grade 2A indicates the presence of superficial ulcers, bleeding, and exudates. (C) Grade 2B indicates local or encircling deep ulceration. (D) Grade 3A indicates focal necrosis. White arrows indicate focal necrosis. (E) Grade 3B indicates extensive necrosis.

gectomies are unnecessary; therefore, a more accurate standard is required.<sup>27</sup>

### Endoscopic ultrasound

Miniprobe endoscopic ultrasound (EUS) can be used safely, and compared with conventional endoscopy, no differences have been reported for their use in predicting the development of early complications.<sup>28</sup> However, a study had indicated that no strictures form later if the muscle layer is intact in EUS.<sup>29</sup> In addition, several studies with radial EUS indicated that if the proper muscle layer is included, the treatment response to balloon dilatation decreases, and subsequent repeated procedures are required; however, additional studies are needed to investigate the role of EUS in evaluating caustic esophageal injuries.

### Radiologic examinations

A simple chest X-ray may be done to observe if there is a gas shadow in the mediastinum or under the diaphragm, indicating esophageal or gastric perforation, respectively. For confirmation, esophagography or upper GI series with a water-soluble contrast medium may be attempted carefully.

The diagnostic efficacy of computed tomography (CT) is slightly higher than endoscopy in terms of assessing the depth and boundary of esophageal or gastric injury, and it is effective in diagnosing impending perforation. In a retrospective analysis of 49 patients who underwent CT, a scoring system for the degree of esophageal causticity and injury of peripheral tissues was attempted, and in terms of predicting the degree of stricture, CT showed better results than endoscopy.<sup>30</sup>

## MANAGEMENT OF PATIENTS

No randomized trial has compared various models for the management of caustic esophageal injury in humans. Instead, most of the currently used management procedures are based on animal experiments.

### General management

If a person is suspected to have ingested large quantities of acidic or alkaline substances according to history taking, physical examination, and upper endoscopy (higher than grade 2B), admission to a medical or surgical ICU is mandatory. By using this management approach, the development of serious complications, if any, can be rapidly treated, and the formation of strictures after recovery can be reduced. However, clinical signs may vary between patients; therefore, strict individual evaluation is necessary. It should be considered that the presence of a symptom or sign alone cannot be used to predict the degree of injury.

Endoscopy is not necessary if there are no symptoms and if unintentional ingestion of small volumes of acid or alkaline substances can be confirmed on the basis of history taking. The patient can be followed at the outpatient clinic after discharge.<sup>8</sup>

Other patients should be admitted and kept nil per os, and chest and abdominal X-ray scans should be taken to assess for perforation. In addition, an intravenous (IV) line must be kept for fluid resuscitation in patients with hypotension. To prevent stress ulcers and additional damage to the esophagus from the regurgitated gastric acid, IV proton pump inhibitors can be administered.<sup>31</sup> If patients experience pain, it should be controlled with adequate administration of narcotic anesthetics. Perforation, mediastinitis, and peritonitis are indications for emergent surgery. For the treatment of patients with injuries higher than grade 3 that are observed by using endoscopy or those suspected to have esophageal perforation, broad-spectrum IV antibiotics such as third-generation cephalosporins should be administered. In patients with respiratory difficulties, laryngoscopic observation is required to evaluate for the need for a tracheostomy. In patients with accompanying oropharyngeal injury, careful management considering airway obstruction is necessary. If there is swelling of the larynx or epiglottis, the airway should be maintained by performing tracheotomy rather than tracheal intubation.

Several methods for the management of caustic esophageal injuries must be avoided before their evaluation, which include administering drugs that may induce vomiting. This is because such methods may reexpose the esophagus to the caustic substances residing in the stomach. Neutralizers must also be avoided because the heat generated from the neutralization reaction may worsen the tissue injury. Furthermore, nasogastric tubes must also be avoided, as they may induce vomiting and reexpose the esophagus to the caustic substances; the pressure generated during vomiting may also increase the risk of perforation.

### Upper GI endoscopy

As described above, upper GI endoscopy to evaluate the degree of injury must be performed within 24 hours. Patients with grade 0 injuries can be discharged immediately, and those with grade 1 or 2A injuries do not require specific treatment. Patients can consume liquids, and advance to regular food within 24 to 48 hours. Patients with grade 2B or 3 injuries can be given liquids through a nasogastric tube 24 hours after the ingestion of caustic substances, and may drink water if they are able to swallow saliva after 48 hours. Patients with grade 3 injuries must be carefully observed for perforation symptoms for at least 1 to 2 weeks after the ingestion.

## Surgery

Esophagectomy is required for patients with severe stricture;<sup>32</sup> however, this may result in negative long-term consequences concerning the survival rate or functional capacity.<sup>27</sup> Emergent surgery is required for patients with perforation, mediastinitis, and peritonitis. If performed by an experienced surgeon, minimally invasive thoracoscopic and laparoscopic procedures result in better outcomes than conventional methods.<sup>33</sup> The most important factors to ensure successful recovery include vascular supply and low tension of the anastomotic site. In patients with damage to both the esophagus and stomach, the colon is usually used as a source of replacement tissue. On the other hand, in patients with damage to only the esophagus, the stomach is pulled up toward the mediastinum to replace the esophagus.

## Prevention of strictures

The use of corticosteroids to prevent the formation of strictures is controversial. Usually, it is not recommended because corticosteroids increase the adverse effects without actually preventing stricture formation, as stricture formation is determined by the initial depth of the injury.<sup>34,35</sup> Grade 3 injuries especially are not affected by the use of corticosteroids. Intralesional injection of triamcinolone has been attempted; however, there are no clear data on the effectiveness, appropriate dosage, and frequency of administration that is required to prevent stricture formation.<sup>36</sup>

There is an old study that has shown that antibiotic use significantly helps in preventing strictures.<sup>37</sup> However, the efficacy has not been proven in patients without infection. Currently, the use of antibiotics is not recommended for preventing strictures in patients who are not being treated with corticosteroids.

Nasogastric tube insertion can cause infection, acid reflux, and long strictures; therefore, its unique use is not currently recommended. However, a report suggested that nasogastric tube insertion can be used to provide enteral nutrition; therefore, it can be used selectively.<sup>38</sup>

Several reports stated that intramucosal injection of mitomycin-C, a chemotherapeutic agent with DNA cross-linking activity, was helpful to prevent strictures;<sup>39,40</sup> however, patients should be observed carefully because systemic absorptions can cause serious adverse effects. A recent meta-analysis indicated positive long-term results; however, additional prospective studies are needed to determine the appropriate concentration, administration period, and frequency of administration,<sup>39</sup> as theoretically, malignant tumors can develop. Therefore, this therapeutic method should be used with caution.

Several reports have shown the usefulness of a specially designed stent (silicone rubber;<sup>41</sup> Polyflex stent;<sup>42</sup> Boston Scien-

tific, Natick, MA, USA) for preventing stricture formation. However, their low efficacy (<50%) and high expulsion rate (>25%) were problematic. Recently, researchers of a study on the use of a polytetrafluoroethylene stent reported an efficacy of 72% during a period of 9 to 14 months, and researchers of another study on a biodegradable stent reported a 45% efficacy during 53 months, indicating the development of various stent models with varying efficacies. Bougie dilatation has been recommended; however, its efficacy is unclear and additional studies are required.

Apart from the treatment models described above, antioxidants (such as 5-fluorouracil and vitamin E), phosphatidylcholine, octreotide, and interferon- $\alpha$ -2b are being studied for their utility in preventing stricture formation in animal models; however, they are not yet at a stage where they can be used to treat humans. More time may be needed before antioxidants could be used for treatment.

Once a stricture develops, balloon dilatation can be attempted carefully.<sup>43,44</sup>

## PROGNOSIS

The most important prognostic factors include the degree of tissue injury and the underlying condition of the patient. Most deaths occur because of complications such as mediastinitis and peritonitis; therefore, strict management in the initial stage is crucial to avoid the occurrence of complications. This article does not address the complications of tissue injury; however, the most representative chronic complications include stricture, squamous cell carcinoma, and a decrease in lower esophageal sphincter pressure, which leads to reflux esophagitis, esophageal motility disorder, intractable pain, gastric outlet obstruction, acidity, and protein losing enteropathy. Acid reflux may be an aggravating factor that cause refractory stricture of the esophagus; therefore, regular observation and aggressive anti-acid therapy is necessary in patients with corrosive esophagitis.<sup>28</sup>

## CONCLUSIONS

In this article, I have reviewed the etiologic causes of caustic GI injury, mechanisms of injury, clinical signs, endoscopic evaluation, and management of patients who have ingested caustic substances. The degree of caustic tissue injury is determined by the nature of the swallowed substance and time the substance spent in contact with the mucosa.

In most adult patients, it may be beneficial to perform an upper GI endoscopy within 24 hours to evaluate the degree of tissue injury. It can help determine the treatment options and to predict prognosis. However, endoscopy is usually con-

trailed in patients with hemodynamic instability, possible perforation, severe respiratory insufficiency, and severe swelling of the larynx or oropharynx. Patients with a moderate to severe level of injury should be admitted to the ICU while strictly monitoring for any life-threatening complications. In addition, if complication such as mediastinitis, peritonitis, and other signs indicative of perforations is observed, emergent surgery is required.

### Conflicts of Interest

The author has no financial conflicts of interest.

### REFERENCES

- Goldman LP, Weigert JM. Corrosive substance ingestion: a review. *Am J Gastroenterol* 1984;79:85-90.
- Riffat F, Cheng A. Pediatric caustic ingestion: 50 consecutive cases and a review of the literature. *Dis Esophagus* 2009;22:89-94.
- Gumaste VV, Dave PB. Ingestion of corrosive substances by adults. *Am J Gastroenterol* 1992;87:1-5.
- Yeom HJ, Shim KN, Kim SE, et al. Clinical characteristics and predisposing factors for complication of caustic injury of the upper digestive tract. *Korean J Med* 2006;70:371-377.
- Yoon KW, Park MH, Park GS, et al. A clinical study on the upper gastrointestinal tract injury caused by corrosive agent. *Korean J Gastrointest Endosc* 2001;23:82-87.
- Jung IS, Kim JS. A case of corrosive gastritis caused by salt-fermented Northern Sand Lance. *Korean J Gastrointest Endosc* 2011;42:366-368.
- Joo HR, Park J, Kim TGS, E H, et al. A case of corrosive esophagogastritis after copper sulfate ingestion. *Korean J Gastrointest Endosc* 2011;43:30-32.
- Contini S, Scarpignato C. Caustic injury of the upper gastrointestinal tract: a comprehensive review. *World J Gastroenterol* 2013;19:3918-3930.
- Sohn YT, Kim JG, Song DW, Lee SS. Clinical study of corrosive esophagitis. *Korean J Otolaryngol-Head Neck Surg* 1992;35:346-353.
- Wasserman RL, Ginsburg CM. Caustic substance injuries. *J Pediatr* 1985;107:169-174.
- Kim HG, Han KH, Lee SI, et al. A case of corrosive gastritis caused by hydrochloric acid. *Korean J Gastrointest Endosc* 1988;8:19-23.
- Arévalo-Silva C, Eliashar R, Wohlgeleirter J, Elidan J, Gross M. Ingestion of caustic substances: a 15-year experience. *Laryngoscope* 2006;116:1422-1426.
- Zargar SA, Kochhar R, Nagi B, Mehta S, Mehta SK. Ingestion of strong corrosive alkalis: spectrum of injury to upper gastrointestinal tract and natural history. *Am J Gastroenterol* 1992;87:337-341.
- Zargar SA, Kochhar R, Mehta S, Mehta SK. The role of fiberoptic endoscopy in the management of corrosive ingestion and modified endoscopic classification of burns. *Gastrointest Endosc* 1991;37:165-169.
- Fisher RA, Eckhauser ML, Radivoyevitch M. Acid ingestion in an experimental model. *Surg Gynecol Obstet* 1985;161:91-99.
- Poley JW, Steyerberg EW, Kuipers EJ, et al. Ingestion of acid and alkaline agents: outcome and prognostic value of early upper endoscopy. *Gastrointest Endosc* 2004;60:372-377.
- Gaudreault P, Parent M, McGuigan MA, Chicoine L, Lovejoy FH Jr. Predictability of esophageal injury from signs and symptoms: a study of caustic ingestion in 378 children. *Pediatrics* 1983;71:767-770.
- Salzman M, O'Malley RN. Updates on the evaluation and management of caustic exposures. *Emerg Med Clin North Am* 2007;25:459-476.
- Hoffman RS, Howland MA, Kamerow HN, Goldfrank LR. Comparison of titratable acid/alkaline reserve and pH in potentially caustic household products. *J Toxicol Clin Toxicol* 1989;27:241-246.
- Rigo GP, Camellini L, Azzolini F, et al. What is the utility of selected clinical and endoscopic parameters in predicting the risk of death after caustic ingestion? *Endoscopy* 2002;34:304-310.
- Cheng YJ, Kao EL. Arterial blood gas analysis in acute caustic ingestion injuries. *Surg Today* 2003;33:483-485.
- Katzka DA. Caustic injury to the esophagus. *Curr Treat Options Gastroenterol* 2001;4:59-66.
- Celik B, Nadir A, Sahin E, Kaptanoglu M. Is esophagoscopy necessary for corrosive ingestion in adults? *Dis Esophagus* 2009;22:638-641.
- Previtera C, Giusti F, Guglielmi M. Predictive value of visible lesions (cheeks, lips, oropharynx) in suspected caustic ingestion: may endoscopy reasonably be omitted in completely negative pediatric patients? *Pediatr Emerg Care* 1990;6:176-178.
- Cabral C, Chirica M, de Chaisemartin C, et al. Caustic injuries of the upper digestive tract: a population observational study. *Surg Endosc* 2012;26:214-221.
- Aronow SP, Aronow HD, Blanchard T, Czinn S, Chelimsky G. Hair relaxers: a benign caustic ingestion? *J Pediatr Gastroenterol Nutr* 2003;36:120-125.
- Chirica M, Resche-Rigon M, Bongrand NM, et al. Surgery for caustic injuries of the upper gastrointestinal tract. *Ann Surg* 2012;256:994-1001.
- Chiu HM, Lin JT, Huang SP, Chen CH, Yang CS, Wang HP. Prediction of bleeding and stricture formation after corrosive ingestion by EUS concurrent with upper endoscopy. *Gastrointest Endosc* 2004;60:827-833.
- Kamijo Y, Kondo I, Kokuto M, Kataoka Y, Soma K. Miniprobe ultrasonography for determining prognosis in corrosive esophagitis. *Am J Gastroenterol* 2004;99:851-854.
- Ryu HH, Jeung KW, Lee BK, et al. Caustic injury: can CT grading system enable prediction of esophageal stricture? *Clin Toxicol (Phila)* 2010;48:137-142.
- Cakal B, Akbal E, Köklü S, Babali A, Koçak E, Taş A. Acute therapy with intravenous omeprazole on caustic esophageal injury: a prospective case series. *Dis Esophagus* 2013;26:22-26.
- Bothreau H, Munoz-Bongrand N, Lambert B, Montemagno S, Cattan P, Sarfati E. Esophageal reconstruction after caustic injury: is there still a place for right coloplasty? *Am J Surg* 2007;193:660-664.
- Zhou JH, Jiang YG, Wang RW, et al. Management of corrosive esophageal burns in 149 cases. *J Thorac Cardiovasc Surg* 2005;130:449-455.
- Fulton JA, Hoffman RS. Steroids in second degree caustic burns of the esophagus: a systematic pooled analysis of fifty years of human data: 1956-2006. *Clin Toxicol (Phila)* 2007;45:402-408.
- Anderson KD, Rouse TM, Randolph JG. A controlled trial of corticosteroids in children with corrosive injury of the esophagus. *N Engl J Med* 1990;323:637-640.
- Siersema PD, de Wijkerslooth LR. Dilation of refractory benign esophageal strictures. *Gastrointest Endosc* 2009;70:1000-1012.
- Krey H. On the treatment of corrosive lesions in the oesophagus; an experimental study. *Acta Otolaryngol Suppl* 1952;102:1-49.
- Kochhar R, Poornachandra KS, Puri P, et al. Comparative evaluation of nasoenteral feeding and jejunostomy feeding in acute corrosive injury: a retrospective analysis. *Gastrointest Endosc* 2009;70:874-880.
- Berger M, Ure B, Lacher M. Mitomycin C in the therapy of recurrent esophageal strictures: hype or hope? *Eur J Pediatr Surg* 2012;22:109-116.
- Uhlen S, Fayoux P, Vachin F, et al. Mitomycin C: an alternative conservative treatment for refractory esophageal stricture in children? *Endoscopy* 2006;38:404-407.
- De Peppo F, Zaccara A, Dall'Oglio L, et al. Stenting for caustic strictures: esophageal replacement replaced. *J Pediatr Surg* 1998;33:54-57.
- Broto J, Asensio M, Vernet JM. Results of a new technique in the treatment of severe esophageal stenosis in children: poliflex stents. *J Pediatr Gastroenterol Nutr* 2003;37:203-206.
- Lee SI, Shn SH, Park IS, Choi HJ. Dilatation of severe corrosive esophageal stricture guided by right coronary artery catheter. *Korean J Gastrointest Endosc* 1991;11:77-80.
- Lee MS, Kim JW, Kim JH, Cho SW, Shim CS. Non-operative dilatation of corrosive esophageal and gastric angular stricture: a case report. *Korean J Gastrointest Endosc* 1989;9:151-155.