

# Effects of pentoxifylline on renal structure after urethral obstruction in rat: A stereological study

Mehdi Shirazi<sup>1</sup>, Ali Noorafshan<sup>1</sup>, Amir Farrokhi<sup>2</sup>

<sup>1</sup>Histomorphometry & Stereology Research Centre, Shiraz University of Medical Sciences, Shiraz, Iran

<sup>2</sup>Department of Urology, Shahid Faghihi Hospital, Shiraz University of Medical Sciences, Shiraz, Iran

## KEY WORDS

partial urethral obstruction ► pentoxifylline ► stereology

## ABSTRACT

**Objective.** Chronic renal failure due to tubulointerstitial fibrosis is one of complications of lower urinary tract obstruction. Since pentoxifylline is a xanthine derivative that inhibits some inflammatory mediators, we conducted this study to investigate whether pentoxifylline inhibits renal fibrosis in a rat model of partial urethral obstruction (PUO).

**Methods.** All the rats underwent experimental PUO. Then, the animals were divided randomly into two groups: positive control group and experimental group. The experimental group received pentoxifylline 100 mg/kg per day via oral gavages for 4-weeks. The control group received the same dose of normal saline. After 4-weeks, all the rats underwent left nephrectomy. Kidney volume and weight and fractional and absolute volumes of the glomeruli, tubules, interstitium and vessels were determined with stereological methods. To reduce the workload of reference (kidney) volume estimation, the total kidney volume was determined after estimation of tissue shrinkage on isotropic uniform random histological sections. The total volume (amount) of each renal structure including fibrosis was estimated to avoid the bias conclusion due to relying on volume density alone.

**Results.** The absolute volume of interstitial fibrosis was lower in the experimental group (PUO with pentoxifylline treatment) (~84%;  $p \leq 0.006$ ) in comparison with the control group (PUO with no treatment).

**Conclusion.** Pentoxifylline reduces interstitial renal fibrosis after partial urethral obstruction in rats.

in biochemical, immunologic, hemodynamic, and functional changes [2, 5-7]. Obstruction also stimulates a cascade in which elevated levels of angiotensin II, cytokines, and growth factors results in cellular inflammation, increased formation of extracellular matrix, tubulointerstitial fibrosis, and tubular cell apoptosis [2, 4, 8-10]. Pentoxifylline is a xanthine derivative that inhibits some inflammatory mediators. Therefore, it can be a reasonable factor to study reduction or prevention of its detrimental effects on the obstructed kidney in the present study. To our knowledge, the effects of pentoxifylline have not been studied in the partial urethral obstruction setting by stereological methods. Thus, we conducted this study to evaluate the effects of pentoxifylline in renal structure and preventing interstitial renal fibrosis after partial urethral obstruction of in rats using stereological methods. Stereological methods provide us an unbiased quantitative amount of fibrosis and other histological parameters. Because of precise and accurate sampling of the tissue, all the parts of the kidney had a same chance to be evaluated under microscope and this is a fundamental base of stereology. In addition we have designed a method to estimate the reference volume of the kidney with a low workload. While relying on the reference volume the total fibrotic tissue volume was estimated, but the fractional volume was not, because relying on the fractional volume of the fibrosis (or any histological structure) may inspire the wrong conclusion.

## MATERIALS AND METHODS

### Animals

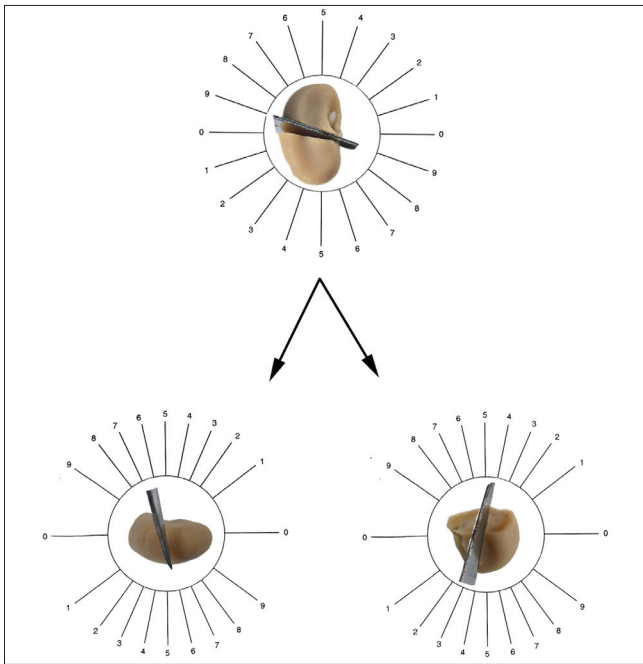
Eleven male Sprague-Dawley rats (weighing 180-200 g) were selected. They were housed in the laboratory with free access to food and water and maintained on a 12 hr dark/light cycle in rooms with a controlled temperature (22-26°C). The animals were treated according to the standard directive as recommended in and approved by the research authorities of Shiraz University of Medical Sciences. The laboratory animal committee of the university approved this animal research under license No: 89-5273. The rats were weighed and distributed at random into two groups: vehicle group ( $n = 5$ ) and pentoxifylline group ( $n = 6$ ). Both groups underwent partial urethral obstruction as will be described.

### Surgical Procedure

Eleven male rats were anesthetized with ketamine (25 mg/kg i.p.) and xylosine (2.5 mg/kg i.p.). Then, they were placed in a supine position, and abdominal cavity was opened by midline incision to expose the urethrovesical junction. A pediatric angiocath (22-gauge) was indwelled into the urethra. A 3-0 silk ligature was tied around the catheterized urethra. Then the catheter was removed to produce a partial obstruction of the bladder outlet, and the incision was sutured [15, 16]. This procedure was done as the same manner for all 11 male rats included in study. After the operation, the pentoxifylline group ( $n = 6$ ) received 100 mg/kg/day pentoxifylline solution via oral gavages by an expert animal laboratory technician for 4-weeks. The

## INTRODUCTION

Obstructive uropathy is a relatively common condition in which an anatomic or functional problem causes obstruction in the urinary flow. Obstruction of urine flow results in changes to the renal parenchyma. These changes include tubular atrophy and interstitial fibrosis; both of which are associated with progressive renal tissue loss [1, 2]. In the lower urinary tract, the most common reason for obstruction in elderly men are benign prostatic hyperplasia, bladder calculi, urethral stricture, and neoplasms of the bladder, prostate, or urethra [1]. Obstruction of the urinary tract is a risk factor for chronic renal failure [3, 4]. The renal pathology finding in men with obstructive nephropathy is chronic interstitial nephritis [3-5]. Obstruction of normal outflow results



**Fig. 1.** The orientator method to generate IUR sections. Each kidney was placed on a circle, each half of which was divided into 10 equal distances ( $\phi$ -clock), a random number between zero and nine was selected and the kidney was sectioned into two halves, with a blade in that direction (here 9) (bottom right). The cut surface of one half of the kidney was placed vertically on the  $\theta$ -clock with 10 unequal sinus-weighted divisions. The second cut was done by selecting a random number (label 6) (bottom left). The cut surface of the other half of the kidney was then placed parallel to the 0-0 direction of  $\theta$ -clock and the second cut was done by selecting a random number (label 4). The entire kidney was sectioned into slabs with a blade, placed in the direction of the second cuts.

positive control group ( $n = 5$ ) received the same volume of normal saline with a similar procedure adopted for the pentoxifylline group. After 4-weeks, the rats in both groups were anesthetized with ether inhalation room and underwent left nephrectomy.

### Stereological Study

The left kidney was cleaned of perirenal fat and connective tissue. After being dissecting out of the renal pelvis, the kidney was weighed. The primary volume, " $V_{\text{primary}}$ " of the kidney was measured using the immersion method. Briefly, a small jar with distilled water was placed on the scale and weighed, and then the kidney was suspended in the jar by a thin thread. The weight of the jar, kidney, and water in grams, minus the weight of the jar and water divided by the specific gravity of distilled water ( $\sim 1$ ) was the volume of the kidney in cubic centimeters.

For fixation, the kidney was placed in neutral buffered formaldehyde for 1-week. As some tissue deformation may occur, mainly in the form of shrinkage produced by fixation, tissue processing, and staining, which will influence the stereological estimation, the shrinkage had to be estimated. The shrinkage was also used for estimation of the final kidney volume after

**Table 1.** Mean (SD) of kidney weight (mg), final kidney volume ( $\text{mm}^3$ ), final volume of kidney, absolute volume of the cortex and medulla in the positive control and pentoxifylline groups

Group	Weight	Volume	Cortex	Medulla
PUO	1260 (170)	800 (190)	640 (30)	160 (30)
PUO + Pentoxifylline	1060 (140)	680 (70)	520 (80)	160 (80)

tissue processing without the need for serial sectioning, which is required in the Cavalieri method. Estimation of shrinkage and tubule length requires isotropic uniform random sectioning of the kidney [17, 18]. These sections were prepared by the orientator method. A brief explanation has been given as the legend of Figure 1.

The entire kidney was sectioned into slabs with a blade, placed in the direction of the second cuts with an interval of  $\sim 0.5$  mm; between nine and 11 slabs were collected from each kidney. A circle was then punched from a kidney slab using a trocar. The diameters of the circular piece of the kidney were measured using a micrometer. The area of the circle was estimated, using the formula for calculating the area of a circle. The cut surfaces of all the slabs and circular piece were embedded in paraffin and sectioned (5 mm thicknesses). The sections were stained with Heidenhain's azan. After staining, the area of the circular piece was measured again and the volume shrinkage [17] was calculated as:

$$\text{Volume shrinkage} = 1 - \left(\frac{AA}{AB}\right)^{1.5}$$

where AA and AB are the area of the circular piece after and before processing, sectioning and staining, respectively. The final volume of the kidney (the reference space) was corrected using:

$$V_{\text{final}} = V_{\text{primary}} \times (1 - \text{volume shrinkage})$$

Each sampled section was analyzed using a microscope (E-200, Nikon, Japan) linked to a video camera (Sony, Japan, SSC Dc 18P) and computer. Between 10 and 14 microscopic fields were studied in each kidney at equal intervals along the X- and Y-axis using a stage micrometer. This procedure was continued until all of the sections were studied by means of stereology software designed at our laboratory (Stereological Research Laboratory, Shiraz University of Medical Sciences, Shiraz, Iran). The stereological probe (composed of 25-points) was superimposed upon the tissue images viewed on the monitor. Using a point-counting method, a fractional volume ( $V_v$ ) of the renal cortex, medulla, glomeruli, PCT, DCT, collecting ducts, Henle's loop, vessels, and connective tissue was obtained and the following formula:

$$V_v = \frac{P_{\text{structure}}}{P_{\text{reference}}}$$

where " $P_{\text{structure}}$ " and " $P_{\text{reference}}$ " were the number of test points falling on the structure's profile and on the reference space, respectively (Fig. 2). Volume fraction of the cortex and medulla was estimated at final magnification of 180 and the other parameters at 1500. By multiplying the fractional volume by the final volume of the kidney, the absolute volume of the parameters was estimated to prevent the 'reference trap' [17, 18].

### Statistical analysis

Statistical comparisons were obtained from the Mann-Whitney  $U$ -test.  $P \leq 0.05$  was considered as significant.

## RESULTS

**Table 2.** Mean (SD) absolute volume ( $\text{mm}^3$ ) of the glomeruli and, proximal and distal convoluted tubules (PCT, DCT), collecting ducts (CD), loop of Henle (LH), interstitial tissue (IS) and vessels in the control and pentoxifylline groups

Group	Glome- ruli	PCT	DCT	CD	LH	IS	Vessel
PUO	30 (0.1)	390 (90)	90 (20)	140 (30)	10 (5)	130 (30)	30 (10)
PUO + Pen- toxifylline	20 (0.7)	390 (40)	100 (20)	120 (20)	10 (5)	20 (8)*	50 (10)

\* $p \leq 0.006$  PUO vs. PUO + pentoxifylline

The details of kidney weight, kidney volume, and absolute volume of the cortex and medulla are shown in Table 1. Kidney weight and volume and absolute volume of the cortex and medulla did not show any significant differences between PUO and PUO plus pentoxifylline. As seen in Table 2 and Figure 3 (plot) the mean absolute volume of the glomeruli and tubules did not show significant differences between two groups. The mean absolute volume of interstitial tissue in the pentoxifylline-treated group was ~84% less than that of the control group ( $p < 0.006$ ). Also an increase of the mean absolute of the vessels in the pentoxifylline group in comparison with control group was seen, but it was not significant statistically.

## DISCUSSION

The present study investigated the effects of pentoxifylline on the renal structure after partial urethral obstruction. Bladder outlet obstruction is the most common cause of lower urinary tract obstruction. Without treatment, bladder outlet obstruction like other forms of obstructive nephropathies results in chronic retention, bilateral hydronephrosis, renal tubulointerstitial fibrosis, and progressive renal tissue degeneration. The first choice of treatment for bladder outlet obstruction is surgical relief of obstruction. Sometimes clinicians should manage patients with bladder outlet obstruction who are not medically fit for operation or patients who refuse surgery or patients for whom operation should be postponed for correction of compromising medical problem. In these patients, an agent that can prevent obstruction-induced renal fibrosis or slow the process of renal parenchymal loss seems reasonable and even ideal. Furthermore, this new agent may be used as an adjunctive with other therapeutics in cases of bladder outlet obstruction. Pentoxifylline can reduce inflammation and also has antifibrotic and anti-ischemic effects that make it a potential therapy for many renal diseases [11-14]. Neutrophil-mediated effects, such as superoxide production, chemotaxis, phagocytosis, and TNF production are inhibited by pentoxifylline [19-22]. TNF- $\alpha$  plays an important role in molecular mechanism lead to tubular cell death. In addition to anti-ischemic and anti-inflammatory effects, pentoxifylline has anti-fibrotic effects that have been investigated in many studies. It has shown great promise as an anti-fibrotic therapy for radiation-induced skin fibrosis, nonalcoholic steatohepatitis, liver fibrosis, radiation-induced lung fibrosis, oral submucous fibrosis, intraperitoneal adhesions, pulmonary sarcoidosis, and corporeal fibrosis [Peyronie's disease] [23-30].

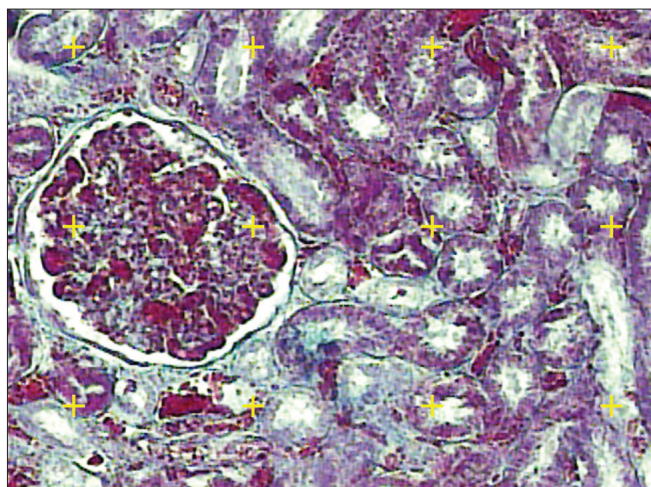


Fig. 2. A microscopic section of kidney. To estimate the volume fraction of the histological parameters, the total number of points hitting each component was divided by the total number of the points hitting the reference space.

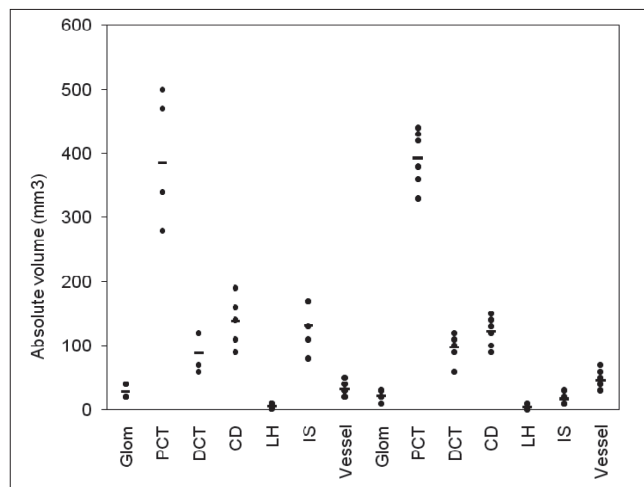


Fig. 3. Dot plot of the absolute volume ( $\text{mm}^3$ ) of the glomeruli (Glom), proximal convoluted tubules (PCT), distal convoluted tubules (DCT), collecting ducts (CD), loop of Henle (LH), interstitial fibrosis (IS), and vessels in the positive control (PUO) (first 7 parameters) and PUO + pentoxifylline (second 7 parameters) groups.

The results of the present study showed that absolute volume of interstitial fibrosis in the pentoxifylline treated [experimental] group was significantly less than the control group. It was concluded that pentoxifylline inhibited renal interstitial fibrosis after partial urethral obstruction. The results are in accordance with the following articles. Aslant et al. showed that pentoxifylline prevented increased free radical activity in unilateral ureteral obstruction [31]. Lin et al. showed that pentoxifylline attenuated tubulointerstitial fibrosis, myofibroblasts accumulation and expression of connective tissue growth factor and collagen I ( $\alpha 1$ ) in unilateral ureteral obstruction kidneys [11]. Zhou et al. reported that pentoxifylline inhibited tubulointerstitial fibrosis in a rat model of obstructive nephropathy while preventing loss of vascular endothelial growth factor [32]. Meldrum et al. showed that TNF- $\alpha$  neutralization ameliorated obstruction induced renal fibrosis and dysfunction. They used a unilateral ureteral obstruction model [33].

Another aspect of the present study is using the stereological methods to evaluate fibrosis. It has been mentioned that absolute volume of the structures must be estimated to prevent the reference trap [17, 18]. The reference trap refers to the wrong conclusion according to the comparison of densities. Thus the final volume of the kidney should be known. To reduce workload of estimating total volume of the kidney by the Cavaleiri method, that needs serial sectioning, we corrected the primary volume in a simple way that has been mentioned earlier [34, 35].

Finally, it should be noted that to our knowledge this is the only report that shows that pentoxifylline can inhibit interstitial renal fibrosis after partial urethral obstruction.

## Acknowledgement

The work was supported by grant No: 89-5273 from Shiraz University of Medical Sciences. The laboratory animals was provided and kept in Laboratory Animal House of the university. The research was done in Histomorphometry & Stereology Research Centre, Shiraz University of Medical Sciences, Shiraz, Iran.

## REFERENCES

1. Tseng TY, Stoller ML: *Obstructive uropathy*. Clin Geriatr Med 2009; 25 (3): 437-443.
2. Pais VM, Strandhoy JW, Assimos DG: *Pathophysiology of urinary tract obstruction*. In: Wein AJ, Kavoussi LR, Novick AC, Partin AW, Peters CA, eds. Campbell-Walsh Urology. Philadelphia Saunders 2007; pp. 1195-226.

3. Rule AD, Lieber MM, Jacobsen SJ: *Is benign prostatic hyperplasia a risk factor for chronic renal failure?* J Urol 2005; 173 (3): 691-696.
4. Sarmina I, Resnick MI: *Obstructive uropathy in patients with benign prostatic hyperplasia.* J Urol 1989; 141 (4): 866-869.
5. Coroneos E, Assouad M, Krishnan B, Truong LD: *Urinary obstruction causes irreversible renal failure by inducing chronic tubulointerstitial nephritis.* Clin Nephrol 1997; 48 (2): 125-128.
6. Bogaert GA, Mevorach RA, Kogan BA: *Renal hemodynamic and functional effects of 10 days' partial urinary obstruction in the fetal lamb.* J Urol 1994; 152 (1): 220-225.
7. Siegel NJ, Feldman RA, Lytton B, Hayslett JP: *Kashgarian Renal cortical blood flow distribution in obstructive nephropathy in rats.* Circ Res 1977; 40 (4): 379-384.
8. Misseri R, Rink RC, Meldrum DR, Meldrum KK: *Inflammatory mediators and growth factors in obstructive renal injury.* J Surg Res 2004; 15; 119 (2): 149-159.
9. Diamond JR, Ricardo SD, Klahr S: *Mechanisms of interstitial fibrosis in obstructive nephropathy.* Semin Nephrol 1998; 18 (6): 594-602.
10. Egido J, Gomez-Chiarri M, Ortoz A et al: *Role of tumor necrosis factor-alpha in the pathogenesis of glomerular diseases.* Kidney Int Suppl 1993; 39: S59-S64.
11. Lin SL, Chen RH, Chen YM et al: *Pentoxifylline attenuates tubulointerstitial fibrosis by blocking Smad3/4-activated transcription and profibrogenic effects of connective tissue growth factor.* J Am Soc Nephrol 2005; 16 (9): 2702-2713.
12. Zhang M, Xu YJ, Saini HK et al: *Pentoxifylline attenuates cardiac dysfunction and reduces TNF-alpha level in ischemic-reperfused heart.* Am J Physiol Heart Circ Physiol 2005; 289 (2): H832-H839.
13. Lin SL, Chen YM, Chiang WC et al: *Pentoxifylline: a potential therapy for chronic kidney disease.* Nephrology (Carlton) 2004; 9 (4): 198-204.
14. Zabel P, Schade FU, Schlaak M: *Inhibition of endogenous TNF formation by pentoxifylline.* Immunobiology 1993; 187 (3-5): 447-463.
15. Shirazi M, Noorafshan A, Bahri MA, Tanideh N: *Captopril reduces interstitial renal fibrosis and preserves more normal renal tubules in neonatal dogs with partial urethral obstruction: a preliminary study.* Urol Int 2007; 78 (2): 173-177.
16. Melman A, Tar M, Boczko J et al: *Evaluation of two techniques of partial urethral obstruction in the male rat model of bladder outlet obstruction.* Urology 2005; 66 (5): 1127-1133.
17. Nyengaard JR: *Stereologic methods and their application in kidney research.* J Am Soc Nephrol 1999; 10 (5): 1100-1123. Review.
18. Mandarim-de-Lacerda CA: *Stereological tools in biomedical research.* An Acad Bras Cienc 2003; 75 (4): 469-486.
19. Reed WR, DeGowin RL: *Suppressive effects of pentoxifylline on natural killer cell activity.* J Lab Clin Med 1992; 119 (6): 763-771.
20. Weinberg JB, Mason SN, Wortham TS: *Inhibition of tumor necrosis factor-alpha (TNF-alpha) and interleukin-1 beta (IL-1 beta) messenger RNA (mRNA) expression in HL-60 leukemia cells by pentoxifylline and dexamethasone: dissociation of acivicin-induced TNF-alpha and IL-1 beta mRNA expression from acivicin-induced monocytoid differentiation.* Blood 1992; 79 (12): 3337-3343.
21. Doherty GM, Jensen JC, Alexander HR et al: *Pentoxifylline suppression of tumor necrosis factor gene transcription.* Surgery 1991; 110 (2): 192-198.
22. Sullivan GW, Carper HT, Novick WJ Jr, Mandell GL: *Inhibition of the inflammatory action of interleukin-1 and tumor necrosis factor (alpha) on neutrophil function by pentoxifylline.* Infect Immun 1988; 56 (7): 1722-1729.
23. Magnusson M, Höglund P, Johansson K et al: *Pentoxifylline and vitamin E treatment for prevention of radiation-induced side-effects in women with breast cancer: a phase two, double-blind, placebo-controlled randomized clinical trial (Ptx-5).* Eur J Cancer 2009; 45 (14): 2488-2495.
24. Yalniz M, Bahçeciöğlü IH, Kuzu N et al: *Amelioration of steatohepatitis with pentoxifylline in a novel nonalcoholic steatohepatitis model induced by high-fat diet.* Dig Dis Sci 2007; 52 (9): 2380-2386.
25. Addolorato G, Russell M, Albano E et al: *Understanding and treating patients with alcoholic cirrhosis: an update.* Alcohol Clin Exp Res 2009; 33 (7): 1136-1144.
26. Kwon HC, Kim SK, Chung WK et al: *Effect of pentoxifylline on radiation response of non-small cell lung cancer: a phase III randomized multicenter trial.* Radiother Oncol 2000; 56 (2): 175-179.
27. Fedorowicz Z, Chan Shih-Yen E, Dorri M: *Interventions for the management of oral submucous fibrosis.* Cochrane Database Syst Rev 2008; (4): CD007156. Review.
28. Mendes JB, Campos PP, Rocha MA, Andrade SP: *Cilostazol and pentoxifylline decrease angiogenesis, inflammation, and fibrosis in sponge-induced intraperitoneal adhesion in mice.* Life Sci 2009; 84 (15-16): 537-543.
29. Paramothayan S, Lasserson T: *Treatments for pulmonary sarcoidosis.* Respir Med 2008; 102 (1): 1-9.
30. Payton S: *Therapeutic benefit of pentoxifylline for Peyronie's disease.* Nat Rev Urol 2010; 7 (5): 237.
31. Aslan A, Karagüzel G, Güngör F et al: *The effects of pentoxifylline on renal function and free radical production in unilateral ureteral obstruction.* Urol Res 2003; 31 (5): 317-322.
32. Zhou QG, Zheng FL, Hou FF: *Inhibition of tubulointerstitial fibrosis by pentoxifylline is associated with improvement of vascular endothelial growth factor expression.* Acta Pharmacol Sin 2009; 30 (1): 98-106.
33. Meldrum KK, Misseri R, Metcalfe P et al: *TNF-alpha neutralization ameliorates obstruction-induced renal fibrosis and dysfunction.* Am J Physiol Regul Integr Comp Physiol 2007; 292 (4): R1456-1464.
34. Shirazi M, Noorafshan A, Kroup M, Tanideh N: *Comparison of the effects of captopril, tamoxifen and L-carnitine on renal structure and fibrosis after total unilateral ureteral obstruction in the rat.* Scand J Urol Nephrol 2007; 41 (2): 91-97.
35. Hoseini L, Roozbeh J, Sagheb M et al: *Nandrolone decanoate increases the volume but not the length of the proximal and distal convoluted tubules of the mouse kidney.* Micron 2009; 40 (2): 226-230.

#### Correspondence

Ali Noorafshan  
 Histomorphometry Et Stereology Research Centre  
 Shiraz University of Medical Sciences  
 Zand Avenue  
 Shiraz, Iran  
 phone: +98 711 230 4372  
 noora@sums.ac.ir