

Multimodal Treatment Including Intracavitary Chemotherapy for Recurrent Pediatric Pleuropulmonary Blastoma

Review began 12/13/2021
Review ended 12/18/2021
Published 12/21/2021

© Copyright 2021

Habti et al. This is an open access article distributed under the terms of the Creative Commons Attribution License CC-BY 4.0., which permits unrestricted use, distribution, and reproduction in any medium, provided the original author and source are credited.

Merieme Habti ¹, Gervaise Hubert ², Monia Marzouki ², Nelson Piché ³

1. Pediatric Surgery, Université de Montréal, Montreal, CAN 2. Pediatric Oncology, Centre Hospitalier Universitaire Sainte-Justine, Montreal, CAN 3. Pediatric Surgery, Centre Hospitalier Universitaire Sainte-Justine, Montreal, CAN

Corresponding author: Merieme Habti, merieme.ha@gmail.com

Abstract

Pleuropulmonary blastoma (PPB) is a rare pediatric cancer, and although there have been improvements in its treatment approach, recurrences retain a very poor prognosis. Here, we report a case of a 30-month-old female who survived recurrent PPB after undergoing surgery, adjuvant chemotherapy, intrapleural cisplatin infusion, and targeted therapy through whole exome sequencing (WES). Intrapleural cisplatin infusion and target therapy appear to be safe and can be considered in a multimodal approach for the management of recurrent PPB.

Categories: Genetics, Pediatric Surgery, Oncology

Keywords: pleuropulmonary blastoma, intracavitary chemotherapy, pleuropulmonary blastoma recurrence, intrapleural cisplatin, target therapy oncology

Introduction

Although rare, pleuropulmonary blastomas (PPBs) remain the most common primary pediatric pulmonary malignancy, with a relatively poor prognosis [1]. Similar to most solid pediatric cancers, PPB recurrence is associated with a grim prognosis [2]. Herein, we report a case of recurrent PPB successfully treated with surgery, intrapleural cisplatin infusion, adjuvant systemic chemotherapy and radiotherapy, and targeted therapy. This case underlines the importance of a multimodal approach for recurrent PPB and the potential role of novel treatment techniques in managing this challenging malignancy.

Case Presentation

A 30-month-old female presented emergently with respiratory distress, desaturation, and fever. Past medical and familial histories were negative. Chest CT demonstrated a moderate right pleural effusion, left mediastinal shift, and a voluminous multinodular mass measuring 13 × 10 × 10 cm with cystic areas in the right pleural space (Figure 1).

How to cite this article

Habti M, Hubert G, Marzouki M, et al. (December 21, 2021) Multimodal Treatment Including Intracavitary Chemotherapy for Recurrent Pediatric Pleuropulmonary Blastoma. Cureus 13(12): e20584. DOI 10.7759/cureus.20584

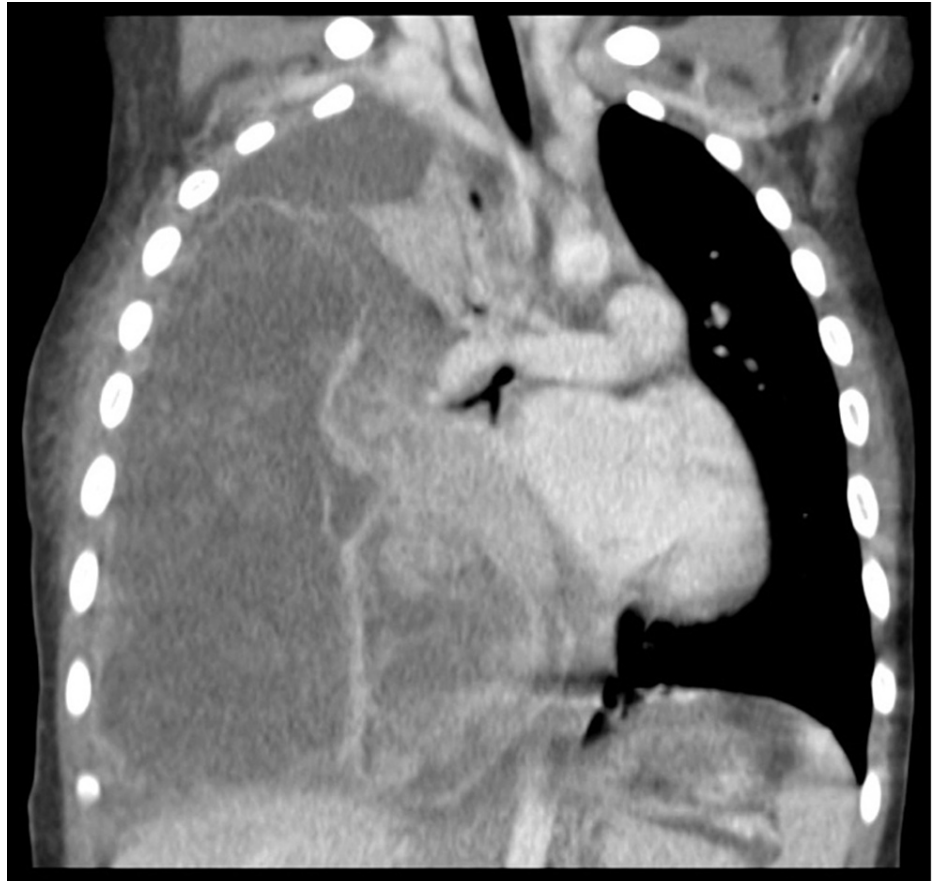


FIGURE 1: Chest CT at diagnosis

The patient was admitted, and a right thoracotomy was performed. A malignant-appearing friable tumor with a large pleural effusion was identified. Resection of the mass was performed by wedge resection of the right lower lobe. Histopathologic analysis established the diagnosis of a type II PPB. Extension workup revealed no brain metastases, no bone marrow involvement, and no other suspicious capitation sites on the PET scan. The postoperative course was favorable, and chemotherapy using the ifosfamide, vincristine, actinomycin D, and doxorubicin (IVADo) protocol was initiated according to the suggested protocol of the International Pleuropulmonary Blastoma Registry [3]. Genetic counseling was obtained, and testing for germinal DICER1 mutation proved to be positive about eight months after initial diagnosis. Since then, the patient underwent usual surveillance without identification of DICER1 germline mutation-associated new tumors [4]. The child completed a year of chemotherapy for a total of 12 cycles with surveillance CT scans every three months for the first year and every six months for the second year.

She relapsed locally at about six years of age when her PET and CT scans revealed a suspicious $69 \times 39 \times 65$ mm mass in the right pleural cavity (Figure 2). After multidisciplinary discussion and with consent from the parents, a second thoracotomy was performed, and the lesion was resected en bloc by a right lower lobectomy.

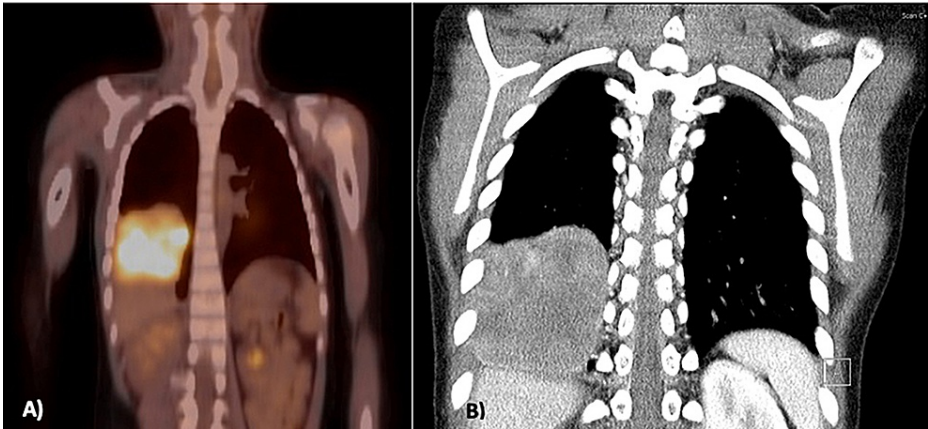


FIGURE 2: Imaging at the first relapse

A) PET scan, B) CT scan

This was followed within three hours of surgery by intrapleural cisplatin infusion. Immediately after surgery, aggressive IV hydration was begun using D5% 0.45 saline at 125 mL/m²/hour. Once the patient was deemed stable, 75 mg/m² of cisplatin diluted in warm normal saline to achieve a total volume of 180 mL was administered intrapleurally via the chest tube. The solution was given over 15 minutes and was left in the intrapleural cavity for four hours. During this time, patient positioning was changed every 15-30 minutes to improve cisplatin distribution in the pleural cavity. After four hours, the liquid was drained through the chest tube. Postoperative evolution was uneventful. The chest tube was ceased on postoperative day five, and the patient was discharged on postoperative day nine.

Adjuvant chemotherapy using vincristine, actinomycin, and cyclophosphamide (VAC) was begun one week postoperatively and administered for a total of 10 cycles. She also received local radiotherapy, with 25 fractions of 1.8 Gy (total: 45 Gy). She was also enrolled in the TRICEPS study, a prospective study aiming to use molecular profiling to better target treatments for hard-to-treat pediatric cancers [2]. Whole exome sequencing (WES) of her tumor revealed very high expression of fibroblast growth factor receptor 1 (FGFR1) and catenin beta 1 (CTNNB1) genes. Celecoxib (100 mg BID) was added to her treatment to target the CTNNB1 mutation.

Seven months later, on posttreatment imaging, CT showed persistent linear opacities in the right lower lung, and PET also revealed persistently increased metabolism adjacent to the surgical staple line (Figure 3). These findings were compatible with postoperative changes, but a second recurrence could not be excluded, and consequently, sorafenib (100 mg BID) was added to target the FGFR1 gene amplification.

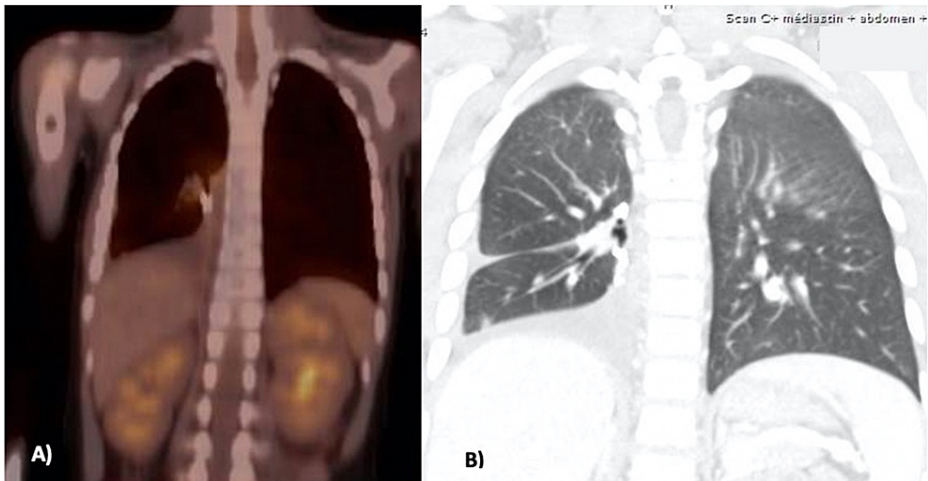


FIGURE 3: Imaging at the second relapse

A) PET scan, B) CT scan

Celecoxib was stopped two years after introduction at the parent's request, although no major side effects were noted. As with sorafenib, she temporarily showed slightly elevated liver enzymes and minor gastrointestinal symptoms (e.g., diarrhea and constipation), but the treatment has been well tolerated overall and is still ongoing. The patient is now 10 years old, and all follow-up imaging shows no relapse of her PPB almost four years after resection and intrapleural cisplatin infusion.

Discussion

PPB is a rare pediatric tumor usually arising from the lung or pleura. The earliest stage of PPB is a lung cyst, and PPBs can evolve into three types: type I (purely cystic), type II (cystic/solid), and type III (solid) [1]. This lung malignancy is known to be associated with DICER1 syndrome in about 66% of cases, which is linked to other pathologies such as ovarian tumors, multinodular goiter, or thyroid carcinomas [5].

Treatment varies depending on the PPB type but mainly relies on a combination of surgical resection, adjuvant chemotherapy, and/or radiotherapy [6].

Treatment options for recurrent cases are not firmly established and should be tailored individually for each patient. Our case report shows the potential benefit of a multimodal approach using both the conventional approach and more novel methods such as intracavitary chemotherapy and molecular profiling.

Intracavitary cisplatin perfusion, both intrathoracic and intraperitoneal, has been studied mainly in the adult population to improve local control, with fewer long-term sequelae than systemic chemotherapy [7-9]. This treatment method has been widely described for adult malignant mesothelioma, demonstrating both improved survival and reduced systemic toxicity [10]. The literature on intracavitary cisplatin use in pediatric patients is limited, but a potential benefit has been shown in managing rare pediatric tumors when unresectable or recurrent disease is contained within a body cavity [11,12]. In one study, two of three long-term survivors were treated with intracavitary cisplatin at diagnosis [11]. We chose to perform early postoperative intrapleural cisplatin perfusion to ensure patient hemodynamic and respiratory stability prior to intracavitary perfusion and optimize cisplatin distribution in the pleural space before adhesion formation. We opted for a closed technique, as opposed to an open intraoperative approach, to decrease the risk of cisplatin spillage.

Conclusions

Intrapleural cisplatin infusion appears safe and is a well-tolerated treatment option in children. It could be considered in a multimodal treatment plan to address recurrent PPB in the hopes of attaining long-term survival, but obviously, more studies are needed to better characterize this novel approach. Targeted therapy through whole exome sequencing also seems to be a promising novel approach for hard-to-treat pediatric cancers.

Additional Information

Disclosures

Human subjects: Consent was obtained or waived by all participants in this study. **Conflicts of interest:** In compliance with the ICMJE uniform disclosure form, all authors declare the following: **Payment/services info:** All authors have declared that no financial support was received from any organization for the submitted work. **Financial relationships:** All authors have declared that they have no financial relationships at present or within the previous three years with any organizations that might have an interest in the submitted work. **Other relationships:** All authors have declared that there are no other relationships or activities that could appear to have influenced the submitted work.

References

- Dehner LP, Schultz KA, Hill DA: Pleuropulmonary blastoma: more than a lung neoplasm of childhood. *Mo Med*. 2019, 116:206-10.
- Khater F, Vairy S, Langlois S, et al.: Molecular profiling of hard-to-treat childhood and adolescent cancers. *JAMA Netw Open*. 2019, 2:e192906. [10.1001/jamanetworkopen.2019.2906](https://doi.org/10.1001/jamanetworkopen.2019.2906)
- International Pleuropulmonary Blastoma (PPB) Treatment and Biology Registry. (2021). <https://ClinicalTrials.gov/show/NCT01464606>.
- Schultz KA, Williams GM, Kamihara J, et al.: DICER1 and associated conditions: identification of at-risk individuals and recommended surveillance strategies. *Clin Cancer Res*. 2018, 24:2251-61. [10.1158/1078-0432.CCR-17-3089](https://doi.org/10.1158/1078-0432.CCR-17-3089)
- Messinger YH, Stewart DR, Priest JR, et al.: Pleuropulmonary blastoma: a report on 350 central pathology-confirmed pleuropulmonary blastoma cases by the International Pleuropulmonary Blastoma Registry. *Cancer*. 2015, 121:276-85. [10.1002/cncr.29032](https://doi.org/10.1002/cncr.29032)
- Mlika M, Anjum F, El Mezni F: Pleuropulmonary blastoma. StatPearls Publishing, Treasure Island, FL; 2021.
- Howell SB, Pfeifle CL, Wung WE, Olshen RA, Lucas WE, Yon JL, Green M: Intraperitoneal cisplatin with systemic thiosulfate protection. *Ann Intern Med*. 1982, 97:845-51. [10.7326/0003-4819-97-6-845](https://doi.org/10.7326/0003-4819-97-6-845)
- Zhou H, Wu W, Tang X, Zhou J, Shen Y: Effect of hyperthermic intrathoracic chemotherapy (HITHOC) on the malignant pleural effusion: a systematic review and meta-analysis. *Medicine (Baltimore)*. 2017,

- 96:e5532. [10.1097/MD.0000000000005532](https://doi.org/10.1097/MD.0000000000005532)
9. Huo YR, Richards A, Liauw W, Morris DL: Hyperthermic intraperitoneal chemotherapy (HIPEC) and cytoreductive surgery (CRS) in ovarian cancer: a systematic review and meta-analysis. *Eur J Surg Oncol*. 2015, 41:1578-89. [10.1016/j.ejso.2015.08.172](https://doi.org/10.1016/j.ejso.2015.08.172)
 10. Chang MY, Sugarbaker DJ: Innovative therapies: intraoperative intracavitary chemotherapy . *Thorac Surg Clin*. 2004, 14:549-56. [10.1016/S1547-4127\(04\)00109-4](https://doi.org/10.1016/S1547-4127(04)00109-4)
 11. Katzenstein HM, Petricca S, Ricketts R, et al.: Intracavitary cisplatin therapy for pediatric malignancies . *Pediatr Blood Cancer*. 2010, 55:452-6. [10.1002/pbc.22508](https://doi.org/10.1002/pbc.22508)
 12. Boyer MW, Moertel CL, Priest JR, Woods WG: Use of intracavitary cisplatin for the treatment of childhood solid tumors in the chest or abdominal cavity. *J Clin Oncol*. 1995, 13:631-6. [10.1200/JCO.1995.13.3.631](https://doi.org/10.1200/JCO.1995.13.3.631)