

Topical heparin as an effective and safe treatment for patients with capecitabine-induced hand-foot syndrome: results of a phase IIA trial supported by proteomic profiling of skin biopsies

Analia Rodríguez-Garzotto, Lara Iglesias-Docampo, C. Vanesa Díaz-García, Isabel Ruppen, Pilar Ximénez-Embún, Carlos Gómez, J. Luis Rodríguez-Peralto, Javier Ortiz de Frutos, Jose A. Lopez-Martin, Cristina Grávalos, Hernán Cortés-Funes and M. Teresa Agulló-Ortuño 

Abstract

Background: Hand-foot syndrome (HFS) is a common adverse reaction associated with capecitabine chemotherapy that significantly affects the quality of life of patients. This study evaluates the safety and effectiveness of a topical heparin (TH) treatment on the clinical manifestations and anatomopathological alterations of capecitabine-induced HFS. In addition, we performed proteome profiling of skin biopsies obtained from patients with HFS at baseline and after heparin treatment.

Methods: Patients with grade ≤ 2 HFS associated with capecitabine were included in this study. The primary end point was the effectiveness of TH in reducing HFS of any grade. Clinical improvement was evaluated by clinicians, and an improvement was perceived by patients who performed a weekly visual analog scale questionnaire. Secondary end points included a comparative histological analysis and protein expression in skin biopsies at baseline and after 3 weeks of HT treatment. Proteomic profiling was carried out using quantitative isobaric labelling and subsequently validated by a T-array.

Results: Twenty-one patients were included in the study. The median TH treatment time was 7.6 weeks (range = 3.6–41.6 weeks), and the median response time was 3.01 weeks (95% CI = 2.15–3.97). At the end of treatment, 19 of 21 patients (90.48%) responded to treatment with a decrease in one or more grades of HFS. None of the patients experienced adverse effects related to TH usage, nor did they suspend chemotherapy treatment. The main findings observed in skin biopsies after treatment were a decrease in hyperkeratosis and lymphocytic infiltrates. The proteomic analysis showed altered expression of 34 proteins that were mainly related to wound healing, cell growth, and the immune response.

Conclusion: Based on our results, topical heparin is an effective and safe treatment for clinical manifestations of HFS, probably due to the restoration of skin homeostasis after heparin treatment, as supported by our proteomics-derived data.

Trial registration: EudraCT 2009-018171-13

Keywords: capecitabine, hand-foot syndrome, heparin, palmar-plantar erythrodysesthesia

Received: 20 September 2021; revised manuscript accepted: 23 February 2022.

Ther Adv Med Oncol

2022, Vol. 14: 1–12

DOI: 10.1177/
17588359221086911

© The Author(s), 2022.
Article reuse guidelines:
sagepub.com/journals-
permissions

Correspondence to:
M. Teresa Agulló-Ortuño
Laboratory of Thoracic
and Clinical-Translational
Oncology, Instituto de
Investigación Sanitaria
Hospital 12 de Octubre
(i + 12), Avda de Córdoba,
s/n, 28041 Madrid, Spain

Lung Cancer Group,
Clinical Research
Program, CNIO- H120,
Madrid, Spain

Biomedical Research
Networking Centre:
Oncology (CIBERONC),
Instituto de Salud Carlos
III, Madrid, Spain

Department of Nursing,
Physiotherapy and
Occupational Therapy,
Facultad de Fisioterapia y
Enfermería, Universidad
de Castilla-La Mancha
(UCLM), Toledo, Spain
agullo@h12o.es

**Analia Rodríguez-
Garzotto**

Medical Oncology
Department, Hospital
Universitario 12 de
Octubre, Madrid, Spain

Laboratory of Thoracic
and Clinical-Translational
Oncology, Instituto de
Investigación Sanitaria
Hospital 12 de Octubre
(i + 12), Madrid, Spain

Roche Farma España,
Madrid, Spain

Lara Iglesias-Docampo

Medical Oncology
Department, Hospital
Universitario 12 de
Octubre, Madrid, Spain

Laboratory of Thoracic
and Clinical-Translational
Oncology, Instituto de
Investigación Sanitaria
Hospital 12 de Octubre
(i + 12), Madrid, Spain

Lung Cancer Group,
Clinical Research
Program, CNIO- H120,
Madrid, Spain

C. Vanesa Díaz-García
Laboratory of
Thoracic and Clinical-
Translational Oncology,
Instituto de Investigación
Sanitaria Hospital 12 de
Octubre (i + 12), Madrid,
Spain

Isabel Ruppen
Pilar Ximénez-Embún
Proteomics Unit,
Spanish National Cancer
Research Centre (CNIO),
Madrid, Spain

Carlos Gómez
Cristina Grávalos
Hernán Cortés-Funes
Medical Oncology
Department, Hospital
Universitario 12 de
Octubre, Madrid, Spain

**J. Luis Rodríguez-
Peralto**
Pathology Department,
Hospital Universitario
12 de Octubre, Madrid,
Spain

Javier Ortiz de Frutos
Dermatology
Department, Hospital
Universitario 12 de
Octubre, Madrid, Spain

Jose A. Lopez-Martin
Medical Oncology
Department, Hospital
Universitario 12 de
Octubre, Madrid, Spain

Laboratory of
Thoracic and Clinical-
Translational Oncology,
Instituto de Investigación
Sanitaria Hospital 12 de
Octubre (i + 12), Madrid,
Spain

Introduction

The epidermis of the hands and feet is a specialized area of the skin that undergoes high levels of homeostatic mechanical and biochemical stress, showing a wide variety of adaptations.¹ Hand-foot syndrome (HFS) or palmar-plantar erythrodysesthesia is a side effect associated with different systemic chemotherapies, most frequently secondary to oral fluoropyrimidines such as capecitabine (Xeloda®).² HFS causes redness, swelling, and pain on the palms of the hands and/or the soles of the feet. Occasionally, thick calluses, blisters, or ulcers also appear, which makes it difficult to walk or use hands. Furthermore, infectious complications may lead to an increased severity.³ However, not everyone develops HFS, and the severity of symptoms may be different among patients. Usually, this condition is not life-threatening and rarely requires hospitalization, but it may cause significant discomfort and may affect the daily activities and quality of life of patients.⁴ The incidence of HFS in capecitabine-treated patients is estimated to range from 36% to 70%.^{2,5,6} The mainstay of treatment for the management of this toxicity is chemotherapy discontinuation or dose modification until symptomatic improvement.^{7,8} Supportive measures to reduce pain and discomfort, or even to prevent the onset of HFS, including analgesics, pyridoxine, oral or topical corticosteroids, and applications of moisturizing creams are being investigated.⁸⁻¹¹ However, these treatments are potentially insufficient in severe cases that may result in temporary or permanent cessation of chemotherapy.

The physiopathology of HFS is not well established. The clinical and histological changes observed are consistent with damage to the physiological barrier of the skin.¹²⁻¹⁴ Nonspecific inflammatory changes, lymphocytic infiltration, dilation of blood vessels and oedema, vacuolar degeneration of basal keratinocytes, marked hyperkeratosis with parakeratosis and apoptotic keratinocytes are the pathological findings described in other studies.^{7,12,15,16} The selective engagement of the dermis of palms and soles together with epithelial cell damage suggests a direct toxic effect on keratinocytes of the basal layer, although different hypotheses have been proposed.¹⁷ One of them relates HFS to increased levels of the enzyme thymidine phosphorylase (TP) in specialized skin cells, such as keratinocytes, which determines the accumulation of active metabolites of capecitabine in the epidermis, leading to an increased chance of developing

this side effect.¹⁸ Other hypotheses concerning the pathogenesis of HFS suggest that it involves an inflammatory phenomenon mediated by the overexpression of cyclooxygenase 2 (COX-2).¹⁹ Some authors postulate that capecitabine may be secreted by the eccrine system (sweat secretion), which would explain the occurrence of HFS mainly on the palms and soles because the largest number of eccrine glands are present at these locations.²⁰ Some authors suggest that HFS develops due to the increased vascularity and increased pressure and temperature of the hands and feet.²¹ HFS has been linked to immune reactions, as several clinical and histological similarities have been observed between HFS and acute graft *versus* host disease. Thus, chemotherapeutic drugs might determine changes in cell surface receptors inducing the host reaction.^{20,22}

Heparan sulphate (HS) is a strongly anionic linear polysaccharide with a high capacity to bind a diverse repertoire of proteins under physiological conditions.²³ HS binds to cell surface and matrix proteins, along with cytokines and chemokines, and these interactions modulate inflammatory cell maturation and activation, the diffusion and adhesion of leukocytes at the endothelium, and extravasation and chemotaxis.²⁴ Heparin is a glycosaminoglycan with anticoagulant activity that also inhibits the proliferation of various cell types *in vitro*. *In vivo* treatment inhibits the proliferation of vascular smooth muscle cells, fibroblasts, melanocytes and keratinocytes, and stimulates collagen synthesis. Heparin mimics the physiological effects of HS, but its actions depend on the dose, and it can act in the plasma membranes of cells in both the dermis and epidermis.^{25,26}

The proliferation of keratinocytes is regulated by different mechanisms, and heparin has been shown to modulate the binding of Keratinocyte Growth Factor (KGF) to its receptor, affecting cellular proliferation induced by the KGF mitogenic signal.^{27,28} Based on these findings, heparin might be a selective treatment aimed at the inhibition of hyperkeratosis.

The main objective of this study was to evaluate the safety and effectiveness of a 3-week topical heparin treatment on the clinical manifestations of capecitabine-induced HFS. In addition, we profiled the underlying molecular changes in patients with HFS during heparin treatment by collecting skin biopsies. Differentially expressed proteins were further confirmed based on histopathology.

Patients and methods

Study design and participants

This study was a proof-of-concept open-label phase 2a clinical trial that evaluated the safety and efficacy of topical heparin (TH) administration to treat HFS in patients receiving capecitabine treatment, either in combination chemotherapy or monotherapy. Between September 2010 and March 2013, 21 patients who were treated in the Medical Oncology Department of the Hospital '12 de Octubre' Hospital (Madrid, Spain), with HFS grade ≤ 2 , aged 18 years or older, had adequate bone marrow, liver, pancreatic and renal function, and presenting a performance status (PS) ≤ 2 according to the ECOG scale, were eligible for the study. The first patient was included in the study on September 24, 2010. All participating patients provided written informed consent. We excluded patients with evidence of disease progression, neurological deficits or dermatological diseases; participants in other clinical trials; patients treated with a drug other than capecitabine; or patients with heparin hypersensitivity.

Treatment consisted of the administration of TH (Menaven Gel[®], Menarini, Spain) that was administered 4 times daily for 21 days. The patients agreed to use only this treatment to palliate the HFS symptoms. The clinical efficacy of TH was assessed, and visual analog scale (VAS) questionnaires were completed weekly by all patients. If the clinical benefit of HFS was achieved, HT treatment was continued as long as capecitabine was continued as the cancer treatment until the patient's consent was withdrawn or based on the investigator's decision. Successive controls were performed every 3 weeks.

The study was conducted according to the Declaration of Helsinki, International Conference on Harmonization Guidelines for Good Clinical Practice, and in accordance with applicable local laws and regulations. The study protocol and informed consent forms were approved by the Institutional Review Board of '12 de Octubre' Hospital (ID number 10/012) and were registered with the clinical trial registration number EudraCT 2009-018171-13 on February 24, 2010.

Assessment of the treatment response

The effectiveness of HT treatment was interpreted as a clinical improvement at 3 weeks, an improvement perceived by the patient completing

the VAS questionnaire, or less use of pain medications and other symptomatic treatments for HFS. Safety was assessed by identifying adverse events associated with HT treatment, and they were recorded and categorized according to the NCI-CTCAE v4.0 scale. Changes in the HFS grade were evaluated by a research group team, using photographs captured at baseline and at 3 weeks of treatment. The team consisted of two oncologists and one dermatologist, who were unaware of the identification, the chemotherapy treatment and the administration/composition of HT received by the patients. In order to maintain objectivity, the photos were encrypted, and they made decisions by consensus.

Histological analysis of skin biopsies

Punch biopsies were obtained in the affected area of the thenar eminence of the hands in 20 patients who provided consent by dermatologist. Skin biopsies were collected at baseline and at 3 weeks of TH treatment. Half of each sample was embedded in paraffin, and the other half was frozen in OCT (optimum cutting temperature) compound for proteomic studies. Formalin-Fixed Paraffin-Embedded (FFPE) samples were stained with haematoxylin-eosin and microscopically examined by a specialized pathologist who performed a comparative qualitative analysis between the paired samples of each patient.

Quantitative proteomic profiling of skin biopsies

Protein extracts were obtained from OCT samples by homogenization in the presence of ceramide microspheres, protease inhibitors, benzamide and RIPA buffer using a Precellys device. Lysates were diluted in TEAB and digested with Lys-C/trypsin enzymes using the standard FASP protocol.²⁹ The resulting peptides were labelled with iTRAQ[®] reagent 4plex and pooled. The complex mixture was prefractionated offline with isoelectrofocusing separation (IEF) using an OFF-GEL system. Each of the 24 obtained fractions was separated using on-line C18 reverse-phase nanoliquid chromatography column coupled to an LTQ Orbitrap Velos mass spectrometer (Thermo Scientific, Germany) equipped with a nanoESI (nanoelectrospray ionization) source. Raw files were searched against the UniProtKB/Swiss-Prot human database (release date: January 11, 2011; 20,252 entries) using Proteome Discoverer 1.3.0.339 software (Thermo Fisher) and MASCOT (v 2.2) as the search engine.

Peptides were filtered at 1% of False Discovery Rate (FDR) using a decoy database. Although relative quantification and some statistical data were performed using Proteome Discoverer software, an additional fold change cut-off for all iTRAQ ratios (ratio < 0.77 or > 1.3) was selected to classify proteins as up- or downregulated, respectively. Proteins with iTRAQ ratios below the low range (0.77) were considered underexpressed, while those above the high range (1.3) were considered overexpressed. The functional enrichment analysis of the identified proteins was performed with Ingenuity Pathway Analysis (IPA) software v.8 (Ingenuity Systems, CA, USA).

Tissue microarrays and immunohistochemistry

Tissue microarrays (TMAs) were constructed with 5- μ m sections of tissue punches from 20 FFPE paired samples (at baseline and at 3 weeks of TH treatment) from patients included in the study. Each sample was examined for pathological validation by two independent investigators who were blinded to the patient's status before and after the TMA was constructed. Samples were stained using an automated tissue immunostainer (Dako, Canada). Slides were probed to validate the expression of the proteins of interest identified in the proteomic profiling assay with selective antibodies (Supplementary Table S1) and were visualized under a light microscope.

Statistical analyses

The sample size for this study was calculated using the Simon method in two stages for phase 2 studies based on the main objective, which was the assessment of the rate of clinical responses obtained with the TH treatment of patients with HFS. Treatment effectiveness was accepted if we achieved a response rate of at least 50% of the participants and rejected if it was less than 20%. Considering an alpha error of 0.05 and a power of 80%, 12 patients were required in the first stage. Because more than three significant responses were observed at this stage, we continued the inclusion of up to 21 patients.

Results

Patient characteristics and clinical association

The clinicopathological characteristics of the 21 patients included in this study are shown in Table 1. All patients had an ECOG performance status of 1 and HFS grade \leq 2 at the beginning of

treatment. No significant differences were found in HFS symptoms between groups stratified by sex, age, tumour type or number of previous treatment lines. Only one patient concomitantly received another drug (epirubicin) related to the triggering of HFS, who entered the study with grade 1 HFS. Total dose of capecitabine administered to patients up to the time prior to inclusion in the study is indicated in Supplementary Table S2. The grade of HFS developed by these patients is also shown.

Outcomes of topical heparin treatment

The symptoms of patients with HFS at the beginning of the study are presented in Table 2. Most of the patients had two or more symptoms associated with the pathology of HFS. The median TH treatment time of patients included in the study was 7.6 weeks (range = 3.6–41.6 weeks). In the assessment of pain perceived by patients using the VAS questionnaire, we observed a mean pain intensity at baseline of 5.5 ± 1.8 points (scale: 0–10) that decreased to 1.3 ± 1.6 at 3 weeks of treatment (Student's *t* test, $p < 0.001$) (Supplementary Table S3). At week 3, 76.2% (16 of 21) of patients responded to treatment with a decrease in one or more grades of HFS. At the end of treatment, we observed an improvement in 90.48% (19 of 21) of patients. The median time to a treatment response was 3.01 weeks (95% CI = 2.15–3.87 weeks). None of the patients experienced adverse events related to TH usage.

Pathological findings found in skin biopsies are described in Table 3. The presence of hyperkeratosis, lymphocytic infiltrates, loss of Langerhans cells and vascular dilatation were notable findings. The main improvement observed in the second sample was a decrease in hyperkeratosis and lymphocytic infiltrates.

Protein regulation in HFS

In this study, an isobaric tag for relative and absolute quantitation (iTRAQ)-based quantitative proteomics technique was used to describe the effect of TH treatment on patients with HFS. We compared the proteomic profiles of skin biopsies collected from patients after 3 weeks of TH treatment with that at baseline. A total of 1876 proteins were identified. The comparative analyses revealed 23 upregulated and 11 downregulated proteins, according to the established cut-off values (Table 4).

The functional enrichment analysis of the altered proteins was performed using IPA. The most important associated network functions belonged to cell-to-cell signalling (score 41); cellular assembly and organization (score 31); cell death, cellular growth and proliferation (score 24); and inflammatory response and cellular compromise (score 21). The biological processes in which these proteins are involved are shown in Figure 1(a). Subsequently, we generated a protein–protein interaction network between heparin and regulated proteins identified in our study (Figure 1(b)). This network shows two new interactions of heparin with the SPARC and THY1 proteins. Other significant networks in which heparin is involved in different biological pathways are shown in Supplementary Figure S1.

The functional annotation also highlighted the predicted inhibition of the transcriptional regulator MYC (p -value = $1.14E-06$) due to its potential interaction with 12 of the proteins identified in our network (Supplementary Figure S1.E).

Validation of the proteomic analysis

Proteins with altered expression profiles were monitored using a TMA with commercially available antibodies in pre- and posttreatment biopsy samples to validate the quantitative proteomic results. Supplementary Figure S2 shows the most relevant results.

Discussion

HFS is a common adverse skin reaction associated with a wide range of chemotherapeutic agents that appears on the hands and feet, causing discomfort and worsening the quality of life of patients. Despite the many studies conducted to date, effective therapies are unavailable for the prevention or treatment of HFS.^{4,10,11,30,31} Unfortunately, the mainstay of the management of HFS is a dose reduction, lengthening the interval between drug administrations, or even treatment discontinuation, with the subsequent drawbacks for patients.⁸ In this study, we examined the efficacy and safety of the topical application of heparin as an easy and accessible treatment capable of improving the symptoms of HFS without interrupting chemotherapeutic treatment.

Our results showed that most patients responded favourably to treatment, with effects observed as early as 3 weeks. We were able to observe

Table 1. Clinicopathological characteristics of patients treated with TH included in the study.

Characteristics (N = 21)	
Sex (N, %)	
Male	9 (42.86)
Female	12 (57.14)
Age (years)	
Mean ± SD	62.2 ± 10.08
Range	44–78
Performance status (N, %)	
ECOG 1	21 (100)
HFS grade* (N, %)	
1	4 (19.05)
2	17 (80.95)
Tumour type (N, %)	
Breast	10 (47.62)
Colorectal	8 (38.10)
Gastric	1 (4.76)
Head and Neck	1 (4.76)
Pancreas	1 (4.76)
Chemotherapy + Capecitabine (N, %)	
Capecitabine monotherapy	7 (33.33)
Bevacizumab	3 (14.29)
Bevacizumab + Cyclophosphamide	2 (9.52)
Gemcitabine	2 (9.52)
Erlotinib	1 (4.77)
Trastuzumab	1 (4.77)
Oxaliplatin	4 (19.05)
Oxaliplatin + Epirubicin	1 (4.77)
Treatment lines received (N, %)	
1	6 (28.57)
2	3 (14.29)
≥3	12 (57.14)
HFS, Hand-foot syndrome; SD, standard deviation; TH: topical heparin. *According to NCI-CTCAE criteria (vs 4.0).	

Table 2. Symptoms of HFS at the beginning of the study.

	Hands (N, %)	Foot (N, %)
Pain	14 (66.67)	18 (85.71)
Erythema	21 (100.0)	21 (100.0)
Edema	21 (100.0)	19 (90.5)
Hyperkeratosis	12 (57.14)	19 (90.48)
Blisters	0	2 (9.52)
Desquamation	6 (28.57)	18 (85.71)
HFS, Hand-foot syndrome.		

Table 3. Optical microscopy results of skin biopsies collected at baseline and after 3 weeks of HT treatment. At baseline, 20 samples were analysed, and 19 samples were analysed after 3 weeks of treatment.

	Baseline (N, %)	Week 3 (N, %)
Vacuolar degeneration	–	1 (5.26)
Hyperkeratosis	19 (95.0)	17 (89.47)
Lymphocytic infiltrate	18 (90.0)	6 (31.58)
Langerhans cell loss	14 (70.0)	15 (78.95)
Vascular dilatation	18 (90.0)	19 (100.0)
Basal layer effacement	–	1 (5.26)

significant skin regeneration, with a reduction in hyperkeratosis and lymphocytic infiltrates in the biopsies analysed. Although pain was not the most frequent symptom reported among the patients included in the study, it was the one that most distressed and reduced the quality of life of the patients.³² According to the VAS questionnaire, pain progressively decreased during treatment, decreasing from an initial mean score of 5.5 to a mean score of 1.3 at 3 weeks and 0.6 at the end of TH treatment.

Nevertheless, the pathophysiological mechanism of HFS remains unclear. In this regard, we have exploited the benefits of label-based approaches such as iTRAQ that enable an accurate and multiplexed quantitative analysis as a tool for the identification of tissue repair-associated biomarkers, which may also improve our understanding of

the pathophysiological processes leading to the development of HFS. Thus, we identified 34 differentially expressed proteins involved in HFS by performing proteomic profiling and validated some of them using immunohistochemistry.

Focusing on the molecular implications of these findings, we realize that NNMT catalyses the N-methylation of nicotinamide and other pyridines, which is an important activity for the metabolism of capecitabine to 5-FU. NNMT has been shown to be an antithrombotic agent limiting platelet-dependent thrombosis through a prostacyclin-related (PGI₂) mechanism mediated by COX-2³³ and exerts concomitant anti-inflammatory effects.³⁴ Thus, the overexpression of NNMT in our samples is consistent with studies that support the inhibition of COX2 in the treatment of HFS.¹⁹

SPARC, a matricellular glycoprotein that regulates cell growth through interactions with the extracellular matrix and cytokines, has been shown to be expressed at high levels in tissues undergoing morphogenesis, remodelling and wound repair,³⁵ inducing the formation of collagens.³⁶ In our study, we observed an increase in the expression of collagens in parallel with the expression of SPARC, which was previously described as a wound repair mechanism. However, heparan sulphate/heparin may act as a guiding scaffold in areas of collagen fibrillogenesis, playing a pivotal role in collagen maturation.³⁷ Moreover, we detected overexpressed Serpin H1 (HSP47), which binds specifically to collagen and participates in its biosynthesis.³⁸

Thy1 (CD90) is a receptor of T cells and is also constitutively expressed on the surface of fibroblasts. Thy1 plays a crucial role in controlling cell growth by suppressing proliferation, promoting apoptosis and participating in dermal fibroblast differentiation.³⁹ PERIOSTIN stimulates wound healing, facilitating the infiltration of mesenchymal cells and the differentiation of myofibroblasts.⁴⁰

Some of the proteins that were overexpressed in our study are related to inflammatory processes and the immune response, such as Thy 1, DERMICIMIN and S100.^{41,42} The S100 protein has been shown to be altered in other skin diseases, such as psoriasis or cancer,^{43,44} and is involved in epidermal differentiation.^{45–47}

Table 4. Differential protein expression in skin biopsies collected after three weeks of TH treatment compared to protein expression in biopsies collected at baseline. Proteins with possible clinical relevance in HFS.

Accession number	Gene name	Protein name	Fold change
P07919	<i>UQCRH</i>	Cytochrome b-c1 complex subunit 6	1.78
Q15063	<i>POSTN</i>	Periostin	1.67
P06702	<i>S100A9</i>	Protein S100-A9	1.66
P08123	<i>COL1A2</i>	Collagen alpha-2(I) chain	1.66
P29034	<i>S100A2</i>	Protein S100-A2	1.61
P02452	<i>COL1A1</i>	Collagen alpha-1(I) chain	1.58
P05109	<i>S100A8</i>	Protein S100-A8	1.57
P00441	<i>SOD1</i>	Superoxide dismutase [Cu-Zn]	1.54
P02461	<i>COL3A1</i>	Collagen alpha-1(III) chain	1.53
P81605	<i>DCD</i>	Dermcidin	1.53
P50454	<i>SERPINH1</i>	Serpin H1	1.49
P09486	<i>SPARC</i>	SPARC	1.44
P40261	<i>NNMT</i>	Nicotinamide N-methyltransferase	1.43
P04216	<i>THY1</i>	Thy-1 membrane glycoprotein	1.43
Q05707	<i>COL14A1</i>	Collagen alpha-1(XIV) chain	1.39
Q4ZHG4	<i>FNDC1</i>	Fibronectin type III domain-containing protein 1	1.36
Q13509	<i>TUBB3</i>	Tubulin beta-3 chain	1.36
P14555	<i>PLA2G2A</i>	Phospholipase A2, membrane associated	1.36
P02763	<i>ORM1</i>	Alpha-1-acid glycoprotein 1	1.35
Q12884	<i>FAP</i>	Seprase	1.32
P19652	<i>ORM2</i>	Alpha-1-acid glycoprotein 2	1.31
P16949	<i>STMN1</i>	Stathmin	1.30
Q05682	<i>CALD1</i>	Caldesmon	1.30
P05120	<i>SERPINB2</i>	Plasminogen activator inhibitor 2 (Serpin B2)	0.77
P20930	<i>FLG</i>	Filaggrin (FLG)	0.76
P22105	<i>TNXB</i>	Tenascin-X	0.76
Q96P63	<i>SERPINB12</i>	Serpin B12	0.75
P35908	<i>KRT2</i>	Keratin, type II cytoskeletal 2 epidermal	0.73
P29508	<i>SERPINB3</i>	Serpin B3 (SCCA1)	0.72
Q9NZH8	<i>IL36G</i>	Interleukin-36 gamma	0.72
P13645	<i>KRT10</i>	Keratin, type I cytoskeletal 10	0.70
P04264	<i>KRT1</i>	Keratin, type II cytoskeletal 1	0.62
P21926	<i>CD9</i>	CD9 antigen (tetraspanin)	0.58
P60985	<i>KRTDAP</i>	Keratinocyte differentiation-associated protein (KDAP)	0.56

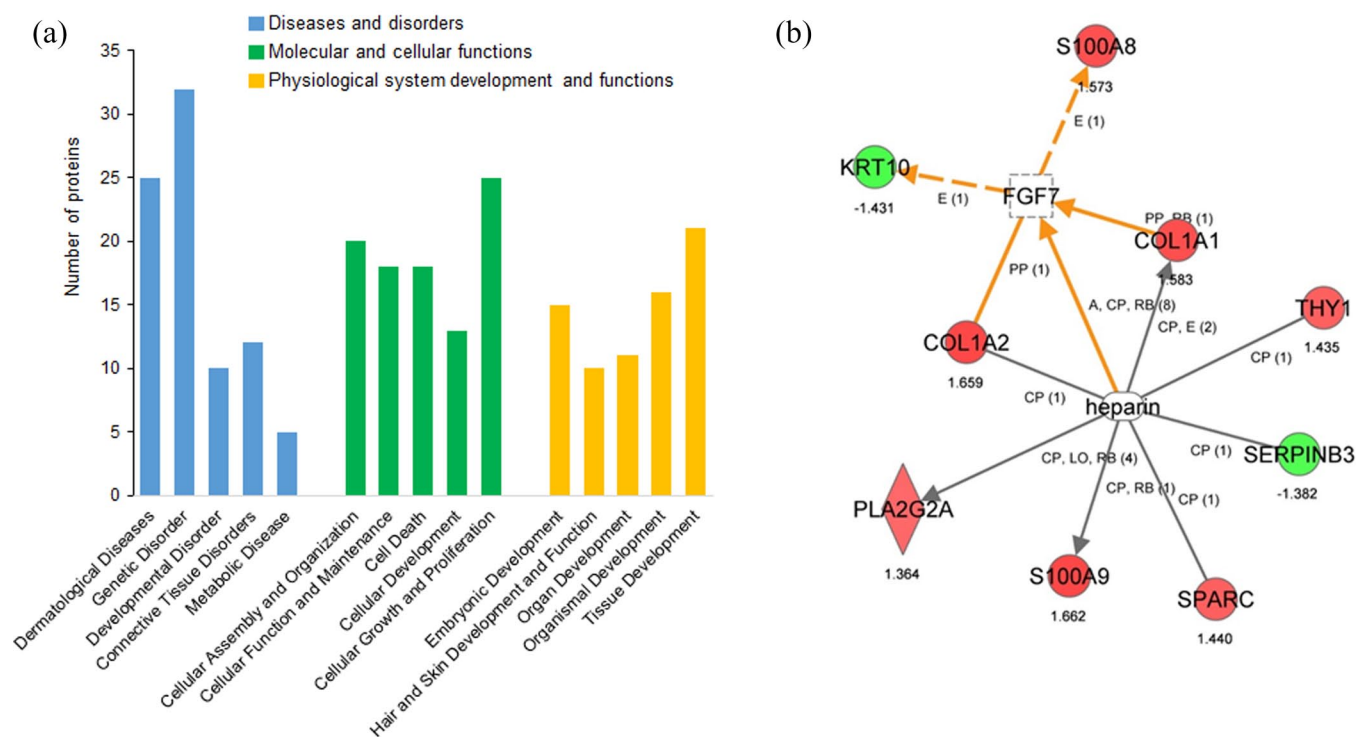


Figure 1. (a) Ingenuity pathway analysis (IPA) of the biological functions of 34 differentially expressed proteins identified in skin biopsies of patients treated with TH. (b) Network depicting the association of heparin with regulated proteins identified in our study (KRT10 and SERPIN3 are downregulated proteins).

STMN1 is a protein that plays a critical role in the regulation of microtubules in the cytoskeleton, and its overexpression is associated with the proliferation, migration, invasion and apoptosis of different cell types.⁴⁸ CALDESMON is a myosin-binding protein that plays an essential role in cell mitosis. Overexpression of CALDESMON, associated with Actin and HSP70, has been previously described in the setting of tissue injury.⁴⁹

Regarding the proteins that were identified as underexpressed in our study, serpins (B2 and B3) modulate keratinocyte differentiation and cell apoptosis.⁵⁰ Our data are consistent with the study by Higgins *et al.*⁵¹ describing heparin as a cofactor of the inhibitory functions of serpins, and would justify the decrease in hyperkeratosis observed in our patients. Similar to the regulation of keratinocyte differentiation, keratinocyte differentiation-associated protein (KDAP) expression was downregulated. This protein is secreted from granular keratinocytes into the extracellular space, where it functions as a soluble regulator of the cornification or desquamation of keratinocytes.⁵² This result would explain its underexpression in skin biopsies.

Consistent with the results of our study, Jiang *et al.*⁵³ showed that tetraspanin (CD9) expression decreases during keratinocyte migration in wound repair processes.

However, type I and type II keratins form a stable network contributing to keratinocyte mechanical properties. However, the expression of keratins 1, 2 and 10 appeared to be decreased in our study. Ramms *et al.*⁵⁴ examined a model of keratin KO cells and showed that keratin loss affects neither actin nor microtubule networks nor their overall protein concentration, and the expression of a single keratin pair is sufficient for the reconstitution of the mechanical properties of keratinocytes. Thus, given the clinical improvement observed in our patients, other keratins likely assume a mechanical role in keratinocytes.

Although MYC has not been identified as a deregulated protein, we showed its relationship with 12 proteins in our study. This transcription factor plays important roles in normal cellular physiology, regulating the proliferation, apoptosis and differentiation of mammalian cells.⁵⁵ Therefore, its predicted inhibition might be involved in the resolution of HFS.

The complicated balance observed in our study between proteins that promote proliferation and those that promote cell differentiation might be involved in the restoration of cutaneous homeostasis after TH treatment in our patients. Thus, an interaction may occur under physiological conditions, where tissue damage could induce its repair. However, we must take these results with caution, since other factors, in addition to the administration of TH, may be contributing to the observed changes in protein expression, given that the inclusion of a control group was not considered in the experimental design.

In summary, our data showed that the topical use of heparin could be an effective treatment for HFS to restore skin homeostasis. This treatment reverses stimulus-induced hyperkeratosis and improves the locoregional inflammatory response; more importantly, none of the patients included in our study discontinued chemotherapy treatment. Given the low cost and the lack of side effects, we propose that a topical heparin treatment can be used effectively and safely.

The main limitation of our work is the small number of patients and samples included. The selection of patients with a low grade of HFS (≤ 2) could also limit the wide applicability of our results in those with more severe symptoms. However, some chemotherapeutic agents can lead to side effects that share similarities with HFS, such as the hand foot skin reaction caused by multikinase inhibitors. Thus, a convenient approach would be to extend the study to determine the clinical benefit in patients with skin pathologies caused by other drugs, such as sorafenib, sunitinib, lenvatinib, and so on. The study of genetic, epigenetic and metabolomic variations in each patient that are potentially related to the triggering of HFS might be another issue to consider. More studies with a larger number of patients are necessary to confirm the potential value of the putative biomarkers described here and their clinical utility. However, the management of HFS during cancer treatment involves a combination of prevention, patient education and support measures. Mainly, the treatment of HFS depends on the severity of symptoms and effects on quality of life.

Acknowledgements

The authors thank the patients and their caregivers. The authors also thank Paz Torres, Elena Sánchez Viñez (Roche) and Remei Artigas

(Menarini) for the assistance provided to perform this study.

Author contributions

Analia Rodríguez-Garzotto: Conceptualization; Data curation; Formal analysis; Funding acquisition; Resources; Supervision; Writing – review and editing.

Lara Iglesias-Docampo: Conceptualization; Formal analysis; Funding acquisition; Resources; Supervision; Writing – review and editing.

C. Vanesa Díaz-García: Data curation; Formal analysis; Investigation; Methodology; Resources; Writing – review and editing.

Isabel Ruppen: Data curation; Formal analysis; Methodology; Writing – review and editing.

Pilar Ximénez-Embun: Data curation; Formal analysis; Methodology; Writing – review and editing.

Carlos Gómez: Data curation; Investigation; Methodology; Writing – review and editing.

J. Luis Rodríguez-Peralto: Data curation; Investigation; Methodology; Writing – review and editing.

Javier Ortiz de Frutos: Data curation; Investigation; Methodology; Writing – review and editing.

Jose A. Lopez-Martin: Data curation; Methodology; Writing – review and editing.

Cristina Grávalos: Data curation; Investigation; Methodology; Writing – review and editing.

Hernán Cortés-Funes: Conceptualization; Data curation; Funding acquisition; Methodology; Writing – review and editing.

M. Teresa Agulló-Ortuño: Conceptualization; Formal analysis; Investigation; Methodology; Supervision; Writing – original draft; Writing – review and editing.

Conflict of interest statement


The authors declared no potential conflicts of interest with respect to the research, authorship, and/or publication of this article.

Funding

The authors disclosed receipt of the following financial support for the research, authorship, and/or publication of this article: This work was supported by a grant from Roche and Menarini

Diagnostic. ONCOSUR was the sponsor of this study (B-001-09).

ORCID iD

M. Teresa Agulló-Ortuño  <https://orcid.org/0000-0002-7617-6681>

Supplemental material

Supplemental material for this article is available online.

References

- Danilenko DM, Phillips GD and Diaz D. In vitro skin models and their predictability in defining normal and disease biology, pharmacology, and toxicity. *Toxicol Pathol* 2016; 44: 555–563.
- de Man FM, Veerman GDM, Oomen-de Hoop E, *et al.* Comparison of toxicity and effectiveness between fixed-dose and body surface area-based dose capecitabine. *Ther Adv Med Oncol* 2019; 11: 1–14.
- Hoesly FJ, Baker SG, Gunawardane ND, *et al.* Capecitabine-induced hand-foot syndrome complicated by pseudomonal superinfection resulting in bacterial sepsis and death: case report and review of the literature. *Arch Dermatol* 2011; 147: 1418–1423.
- Kwakman JJM, Elshot YS, Punt CJA, *et al.* Management of cytotoxic chemotherapy-induced hand-foot syndrome. *Oncol Rev* 2020; 14: 442.
- Twelves CJ. Xeloda in adjuvant colon cancer therapy (X-ACT) trial: overview of efficacy, safety, and cost-effectiveness. *Clin Colorectal Cancer* 2006; 6: 278–287.
- Masuda N, Lee SJ, Ohtani S, *et al.* Adjuvant capecitabine for breast cancer after preoperative chemotherapy. *N Engl J Med* 2017; 376: 2147–2159.
- Gressett SM, Stanford BL and Hardwicke F. Management of hand-foot syndrome induced by capecitabine. *J Oncol Pharm Pract* 2006; 12: 131–141.
- Nikolaou V, Syrigos K and Saif MW. Incidence and implications of chemotherapy related hand-foot syndrome. *Expert Opin Drug Saf* 2016; 15: 1625–1633.
- Yap YS, Kwok LL, Syn N, *et al.* Predictors of hand-foot syndrome and pyridoxine for prevention of capecitabine-induced hand-foot syndrome: a randomized clinical trial. *JAMA Oncol* 2017; 3: 1538–1545.
- Abdelalim LR, Elnaggar YSR and Abdallah OY. Oleosomes encapsulating sildenafil citrate as potential topical nanotherapy for palmar plantar erythrodysesthesia with high ex vivo permeation and deposition. *AAPS PharmSciTech* 2020; 21: 310.
- Lian S, Zhang X, Zhang Y, *et al.* Pyridoxine for prevention of hand-foot syndrome caused by chemotherapy agents: a meta-analysis. *Clin Exp Dermatol* 2021; 46: 629–635.
- Nagore E, Insa A and Sanmartín O. Antineoplastic therapy-induced palmar plantar erythrodysesthesia (‘hand-foot’) syndrome. Incidence, recognition and management. *Am J Clin Dermatol* 2000; 1: 225–234.
- Degen A, Alter M, Schenck F, *et al.* The hand-foot-syndrome associated with medical tumor therapy – classification and management. *J Dtsch Dermatol Ges* 2010; 8: 652–661.
- Rosso JD, Zeichner J, Alexis A, *et al.* Understanding the epidermal barrier in healthy and compromised skin: clinically relevant information for the dermatology practitioner: proceedings of an expert panel roundtable meeting. *J Clin Aesthet Dermatol* 2016; 9: S2–S8.
- Scotté F, Tourani JM, Banu E, *et al.* Multicenter study of a frozen glove to prevent docetaxel-induced onycholysis and cutaneous toxicity of the hand. *J Clin Oncol* 2005; 23: 4424–4429.
- Scheithauer W and Blum J. Coming to grips with hand-foot syndrome. Insights from clinical trials evaluating capecitabine. *Oncology (Williston Park)* 2004; 18: 1161–1168, 1173; discussion 1173.
- Lou Y, Wang Q, Zheng J, *et al.* Possible pathways of capecitabine-induced hand-foot syndrome. *Chem Res Toxicol* 2016; 29: 1591–1601.
- Chalermchai T, Tantiphlachiva K, Suwanrusme H, *et al.* Randomized trial of two different doses of pyridoxine in the prevention of capecitabine-associated palmar-plantar erythrodysesthesia. *Asia Pac J Clin Oncol* 2010; 6: 155–160.
- Zhang RX, Wu XJ, Wan DS, *et al.* Celecoxib can prevent capecitabine-related hand-foot syndrome in stage II and III colorectal cancer patients: result of a single-center, prospective randomized phase III trial. *Ann Oncol* 2012; 23: 1348–1353.
- Milano G, Etienne-Grimaldi MC, Mari M, *et al.* Candidate mechanisms for capecitabine-related hand-foot syndrome. *Br J Clin Pharmacol* 2008; 66: 88–95.
- Kara IO, Sahin B and Erkisi M. Palmar-plantar erythrodysesthesia due to docetaxel-capecitabine therapy is treated with vitamin E without dose reduction. *Breast* 2006; 15: 414–424.

22. Childress J and Lokich J. Cutaneous hand and foot toxicity associated with cancer chemotherapy. *Am J Clin Oncol* 2003; 26: 435–436.
23. Bernfield M, Götte M, Park PW, *et al.* Functions of cell surface heparan sulfate proteoglycans. *Annu Rev Biochem* 1999; 68: 729–777.
24. Götte M. Syndecans in inflammation. *FASEB J* 2003; 17: 575–591.
25. Parisel C, Saffar L, Gattegno L, *et al.* Interactions of heparin with human skin cells: binding, location, and transdermal penetration. *J Biomed Mater Res A* 2003; 67: 517–523.
26. Ferrao AV and Mason RM. The effect of heparin on cell proliferation and type-I collagen synthesis by adult human dermal fibroblasts. *Biochim Biophys Acta* 1993; 1180: 225–230.
27. Hsu YR, Nybo R, Sullivan JK, *et al.* Heparin is essential for a single keratinocyte growth factor molecule to bind and form a complex with two molecules of the extracellular domain of its receptor. *Biochemistry* 1999; 38: 2523–2534.
28. Yang BB, Gillespie B, Smith B, *et al.* Pharmacokinetic and pharmacodynamic interactions between palifermin and heparin. *J Clin Pharmacol* 2015; 55: 1109–1118.
29. WiÅniewski JR, Zougman A, Nagaraj N, *et al.* Universal sample preparation method for proteome analysis. *Nat Methods* 2009; 6: 359–362.
30. Zenda S, Ryu A, Takashima A, *et al.* Hydrocolloid dressing as a prophylactic use for hand-foot skin reaction induced by multitargeted kinase inhibitors: protocol of a phase 3 randomised self-controlled study. *BMJ Open* 2020; 10: e038276.
31. Hofheinz RD, Gencer D, Schulz H, *et al.* Mapisal versus urea cream as prophylaxis for capecitabine-associated hand-foot syndrome: a randomized phase iii trial of the AIO quality of life working group. *J Clin Oncol* 2015; 33: 2444–2449.
32. McLellan B, Ciardiello F, Lacouture ME, *et al.* Regorafenib-associated hand-foot skin reaction: practical advice on diagnosis, prevention, and management. *Ann Oncol* 2015; 26: 2017–2026.
33. Chlopicki S, Swies J, Mogielnicki A, *et al.* 1-Methylnicotinamide (MNA), a primary metabolite of nicotinamide, exerts anti-thrombotic activity mediated by a cyclooxygenase-2/prostacyclin pathway. *Br J Pharmacol* 2007; 152: 230–239.
34. Ungerstedt JS, Heimersson K, Söderström T, *et al.* Nicotinamide inhibits endotoxin-induced monocyte tissue factor expression. *J Thromb Haemost* 2003; 1: 2554–2560.
35. Bradshaw AD, Reed MJ and Sage EH. SPARC-null mice exhibit accelerated cutaneous wound closure. *J Histochem Cytochem* 2002; 50: 1–10.
36. Brekken RA, Puolakkainen P, Graves DC, *et al.* Enhanced growth of tumors in SPARC null mice is associated with changes in the ECM. *J Clin Invest* 2003; 111: 487–495.
37. Weiss T, Ricard-Blum S, Moschovich L, *et al.* Binding of procollagen C-proteinase enhancer-1 (PCPE-1) to heparin/heparan sulfate: properties and role in PCPE-1 interaction with cells. *J Biol Chem* 2010; 285: 33867–33874.
38. Rocnik EF, van der Veer E, Cao H, *et al.* Functional linkage between the endoplasmic reticulum protein Hsp47 and procollagen expression in human vascular smooth muscle cells. *J Biol Chem* 2002; 277: 38571–38578.
39. Schmidt M, Gutknecht D, Simon JC, *et al.* Controlling the balance of fibroblast proliferation and differentiation: impact of Thy-1. *J Invest Dermatol* 2015; 135: 1893–1902.
40. Elliott CG, Forbes TL, Leask A, *et al.* Inflammatory microenvironment and tumor necrosis factor alpha as modulators of periostin and CCN2 expression in human non-healing skin wounds and dermal fibroblasts. *Matrix Biol* 2015; 43: 71–84.
41. Schubert K, Polte T, Bönisch U, *et al.* Thy-1 (CD90) regulates the extravasation of leukocytes during inflammation. *Eur J Immunol* 2011; 41: 645–656.
42. Gonzalez LL, Garrie K and Turner MD. Role of S100 proteins in health and disease. *Biochim Biophys Acta Mol Cell Res* 2020; 1867: 118677.
43. Takahashi T and Yamasaki K. Psoriasis and antimicrobial peptides. *Int J Mol Sci* 2020; 21: 6791.
44. Allgöwer C, Kretz AL, von Karstedt S, *et al.* Friend or foe: S100 proteins in cancer. *Cancers (Basel)* 2020; 12: 2037.
45. Lee Y, Jang S, Min JK, *et al.* S100A8 and S100A9 are messengers in the crosstalk between epidermis and dermis modulating a psoriatic milieu in human skin. *Biochem Biophys Res Commun* 2012; 423: 647–653.
46. Halawi A, Abbas O and Mahalingam M. S100 proteins and the skin: a review. *J Eur Acad Dermatol Venereol* 2014; 28: 405–414.
47. LeÅniak W and Graczyk-Jarzynka A. The S100 proteins in epidermis: topology and function. *Biochim Biophys Acta* 2015; 1850: 2563–2572.

48. Li X, Wang L, Li T, *et al.* STMN1 overexpression correlates with biological behavior in human cutaneous squamous cell carcinoma. *Pathol Res Pract* 2015; 211: 816–823.
49. Jarkovska K, Dvorankova B, Halada P, *et al.* Revelation of fibroblast protein commonalities and differences and their possible roles in wound healing and tumorigenesis using co-culture models of cells. *Biol Cell* 2014; 106: 203–218.
50. Sheshadri N, Catanzaro JM, Bott AJ, *et al.* SCCA1/SERPIN3 promotes oncogenesis and epithelial-mesenchymal transition via the unfolded protein response and IL6 signaling. *Cancer Res* 2014; 74: 6318–6329.
51. Higgins WJ, Fox DM, Kowalski PS, *et al.* Heparin enhances serpin inhibition of the cysteine protease cathepsin L. *J Biol Chem* 2010; 285: 3722–3729.
52. Tsuchida S, Bonkobara M, McMillan JR, *et al.* Characterization of Kdap, a protein secreted by keratinocytes. *J Invest Dermatol* 2004; 122: 1225–1234.
53. Jiang XP, Zhang DX, Teng M, *et al.* Downregulation of CD9 in keratinocyte contributes to cell migration via upregulation of matrix metalloproteinase-9. *PLoS ONE* 2013; 8: e77806.
54. Ramms L, Fabris G, Windoffer R, *et al.* Keratins as the main component for the mechanical integrity of keratinocytes. *Proc Natl Acad Sci USA* 2013; 110: 18513–18518.
55. Meyer N and Penn LZ. Reflecting on 25 years with MYC. *Nat Rev Cancer* 2008; 8: 976–990.

Visit SAGE journals online
[journals.sagepub.com/
home/tam](http://journals.sagepub.com/home/tam)

 SAGE journals