


# Instrumented cervical fusion in nine dogs with caudal cervical spondylomyelopathy

Tjarda E. Reints Bok DVM<sup>1</sup> | Koen Willemsen MD<sup>2</sup>  | Mattie H. P. van Rijen BSc<sup>2</sup> | Guy C. M. Grinwis DVM, PhD<sup>3</sup> | Marianna A. Tryfonidou DVM, PhD, DECVS<sup>1</sup> | Björn P. Meij DVM, PhD, DECVS<sup>1</sup>

<sup>1</sup>Department of Clinical Sciences of Companion Animals, Faculty of Veterinary Medicine, Utrecht University, Utrecht, The Netherlands

<sup>2</sup>Department of Orthopedics, University Medical Center Utrecht, Utrecht, The Netherlands

<sup>3</sup>Department of Pathobiology, Faculty of Veterinary Medicine, Utrecht University, Utrecht, The Netherlands

## Correspondence

Björn P. Meij, Department of Clinical Sciences of Companion Animals, Faculty of Veterinary Medicine, Utrecht University, Yalelaan 108, PO Box 80.154, NL-3508 TD Utrecht, The Netherlands.  
Email: b.p.meij@uu.nl

## Abstract

**Objective:** To report the long-term outcome of nine dogs treated for caudal cervical spondylomyelopathy (CCSM) with surgical spinal fusion.

**Study design:** Short case series.

**Animals:** Nine large-breed dogs.

**Methods:** Medical records of dogs treated for disc-associated CCSM (2013–2016) were reviewed. The surgery objective was spinal distraction by implantation of a SynCage and fixation with two Unilock plates. Follow-up included the Helsinki pain score questionnaire, neurological grading, radiography, computed tomography (CT), and micro-CT ( $\mu$ CT) with subsequent histopathology (two dogs).

**Results:** Clinical follow-up was obtained between 9 and 51 months ( $27.4 \pm 13.4$  months). The Helsinki pain score and neurological Griffith score improved ( $P < .01$ ) in all dogs and in eight of nine dogs, respectively. According to CT, the volume of bone (mean  $\pm$  SD) through the cage was  $79.5\% \pm 14.3\%$ , including compact bone ( $53.0\% \pm 23.4\%$ ). Subsidence was seen in one of nine dogs. Implant failure was evident in four dogs, and plates were removed in two dogs. In seven of nine dogs, infraclinical pathology was observed in adjacent segment, associated with implants engaging adjacent intervertebral discs. Radiographic evidence of bony fusion between vertebral bodies was noted in all dogs. Spinal fusion was confirmed by  $\mu$ CT and histopathology in two cervical spine segments that became available at 22 and 40 months postoperatively.

**Conclusion:** Instrumented spinal fusion in dogs with disc-associated CCSM resulted in owner satisfaction and radiographic evidence of interbody spinal fusion in all dogs.

**Clinical significance:** The fusion distraction technique reported here can be used to achieve spinal fusion with a good long-term outcome.

## 1 | INTRODUCTION

Caudal cervical spondylomyelopathy (CCSM) is a degenerative and progressive disorder of the intervertebral disc, ligaments, and articular facet joints resulting in compression of spinal cord and nerve roots. Disc-associated CCSM is frequently identified in Doberman pinschers and in other large-breed dogs.<sup>1,2</sup>

Conservative treatment consists of restricted activity, using a body harness, and analgesia and/or administration of steroids.<sup>3</sup> Surgical techniques for the treatment of CCSM include dorsal or ventral decompressive procedures, distraction-stabilization procedures, and total disc replacement. Distraction-stabilization techniques can involve intervertebral spacers such as allogenic cortical bone grafts, polymethylmethacrylate cement plugs, washers, customized devices, or other metallic spacers (such as cages) in combination with screws, pins, or plates.<sup>3-9</sup> Total disc replacement (disc arthroplasty) is used to maintain the functional vertebral motion unit. It has been investigated extensively in man, but veterinary application in dogs is rare, and long-term follow-up studies are lacking.<sup>10-13</sup>

Spinal fusion is currently considered the gold standard in surgical treatment of cervical myelopathy, the human analog disease for CCSM in dogs.<sup>10,14</sup> Bone bridging between the vertebral endplates is the objective of surgery because implants alone may not provide lifelong stability. One potential disadvantage of spinal fusion is adjacent segment pathology (ASP), in which degeneration or other pathologic processes occur cranially or caudally to the region of vertebral column fusion. Degenerative disc disease appears to play an important role, and ASP is described in man after spinal fusion techniques in the cervical and lumbar spine. When ASP becomes clinical, it is referred to as *adjacent segment disease* (ASD).<sup>15,16</sup> The longer the fused segment the greater the biomechanical stress on the adjacent mobile segment.<sup>17</sup> Adjacent segment pathology and ASD have also been described in dogs.<sup>18,19</sup> Attempts have been made to fuse the caudal cervical spine in dogs with CCSM by using different distraction cages or devices, but little information is available on long-term follow-up, with no solid evidence confirming spinal fusion through the cage by using computed tomography (CT), micro-CT ( $\mu$ CT), or histopathology.<sup>4,7,20</sup>

The objective of the present retrospective study was to describe and evaluate a distraction-stabilization technique in which an intervertebral titanium cage and plates are used in dogs with CCSM. Outcomes were assessed during long-term follow-up, and spinal fusion was examined with radiography, CT,  $\mu$ CT, and histopathology.

## 2 | MATERIALS AND METHODS

### 2.1 | Inclusion criteria


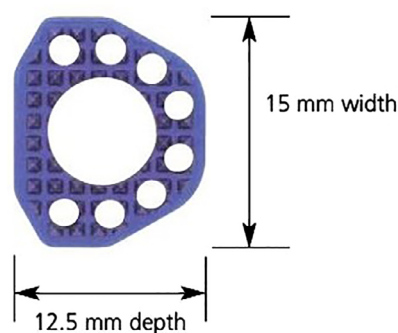
During 2.5 years (July 2013 to February 2016), nine dogs with disc-associated CCSM were treated with a distraction-fixation technique in which an intervertebral spacer and plates were used. Case records were reviewed retrospectively and included when signalment, clinical signs, diagnostic work-up, and surgical findings were complete. We asked that dogs return for a long-term follow-up examination at a minimum term of 9 months.

### 2.2 | Neurological assessment

Dogs were assessed preoperatively, postoperatively until hospital discharge, at 6 weeks postoperatively, and at long-term follow-up. Neurologic examinations were scored according to the modified Griffith scale in which zero is defined as a normal neurologic examination and five is defined as a nonambulatory tetraplegia without deep nociception.<sup>21,22</sup>

### 2.3 | Surgical technique and implants used

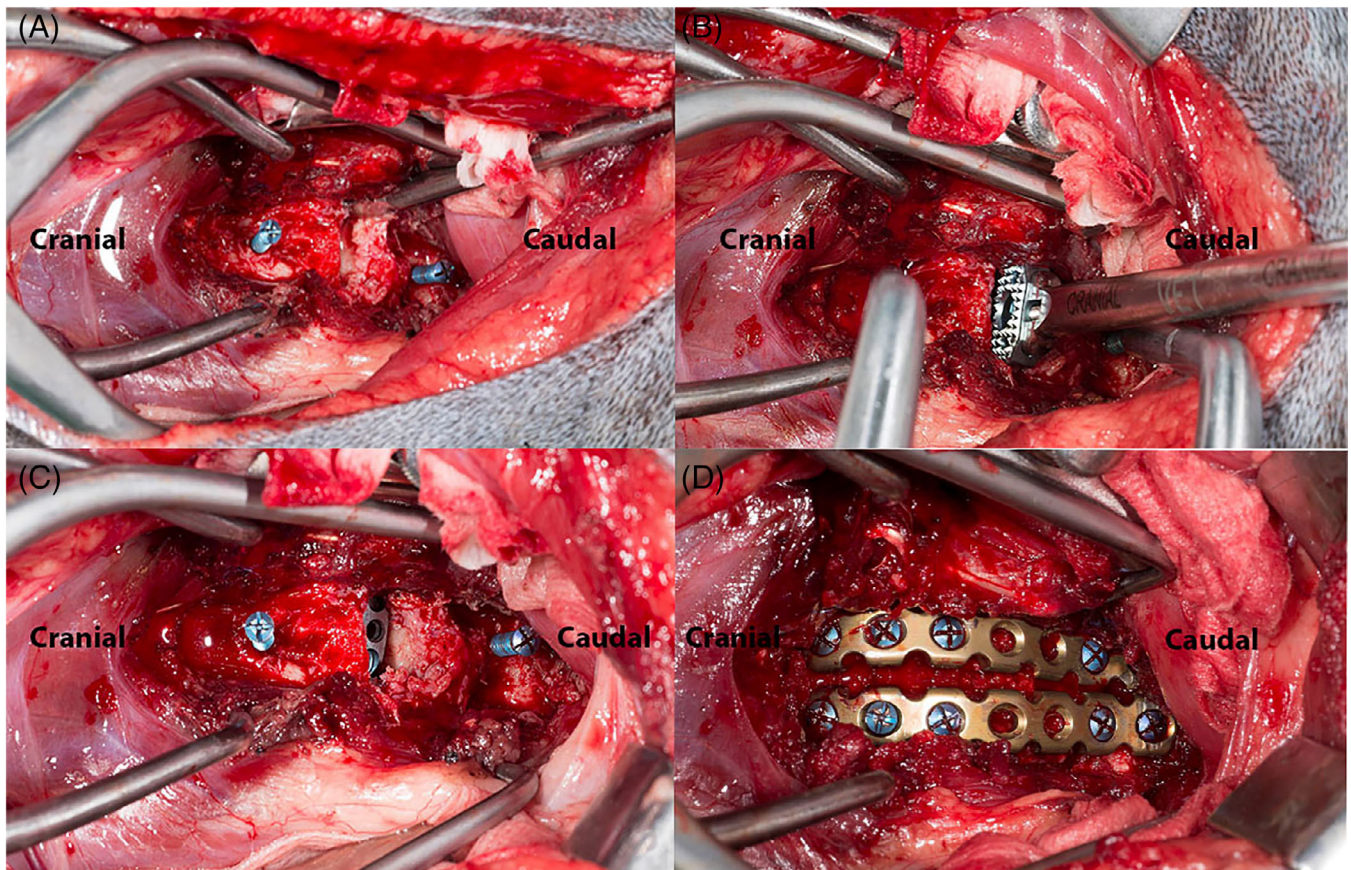
The same board-certified surgeon (B.P.M.) performed all surgeries. The procedure included a ventral approach to the affected disc, ventral fenestration of the annulus fibrosus, and nuclear pulpectomy.<sup>23</sup> After distraction of the vertebrae by using vertebral body screws and a cervical distractor (human cervical distractor; DePuy Synthes, Johnson & Johnson, Oberdorf, Switzerland), the dorsal annulus fibrosus was removed, the cartilaginous layer of the end plates was carefully curetted by using a 2-mm spoon bone curette, and a titanium cage (SynCage-C Short, curved; DePuy Synthes) was inserted (Figures 1 and 2). A trial cage was inserted first with a custom-



SynCage–Small grasped by implant holder

**FIGURE 1** The SynCage (image at left) is a titanium spacer with a concave cranial surface and a flat caudal surface. The cage measures 15 mm in laterolateral width, 12.5 mm in dorsoventral depth, and 5 mm in craniocaudal height. The central opening measures 5 mm in diameter and 4.5 mm in craniocaudal length (height). The implant holder is displayed in the image at right





**FIGURE 2** A, Ventral view of the C6-C7 intervertebral disc (IVD) disc space of dog 5 with caudal cervical spondylomyelopathy. The IVD is distracted on two screws inserted into the midline of the vertebral bodies, which allows removal of the ventral and dorsal annulus fibrosus, the nucleus pulposus, and curetting of the endplates. B, Insertion of a cage. C, The cage is impacted dorsal to the ventral cortex of the cervical vertebrae. D, Two locking plates are visible; an autologous cancellous bone graft was placed inside the cage and around the plates

made implant holder (DePuy Synthes; Figure 1). When fit was confirmed, the definitive cage was inserted and seated just below the ventral vertebral cortex (Figure 2). Before the cage was placed, it was packed with a cancellous bone graft harvested from the proximal humeral bone. Both sides of the cage contained tiny spikes to provide an optimal implant-endplate interface, limiting the risk of migration after distractor removal. Cage fixation was protected by double ventral plating by using locking plates and screws (Unilock; DePuy Synthes; Figure 2), which also were surrounded by a cancellous bone graft.

## 2.4 | Postoperative care

Postoperative care included monitoring neurologic status and urinary bladder function, analgesia management, and frequent turning if the dog was nonambulatory. Physiotherapy immediately postoperatively included standing proprioceptive feedback and passive range of motion exercises. Postoperative analgesia during hospitalization was provided by constant rate infusion of different analgesics (fentanyl, ketamine, lidocaine),

with rates depending on the dog's pain score. In addition, dogs were given meloxicam (0.1 mg/kg orally) once daily or carprofen (2 mg/kg orally) twice daily. Postoperative recommendations, beside physiotherapy, included 2 weeks of strict rest and chest harness restraint walks for 6 weeks beginning at 2 weeks postsurgery, 4 times daily for 5 minutes. Walks were increased every week by 5 minutes per walk according to the dog's ability.

## 2.5 | Imaging

Preoperative diagnostic imaging was performed with MRI (0.2 T Magnetom Open Viva; Siemens AG, Germany or Ingenia 1.5 T Omega; Phillips, The Netherlands) or CT (Somatom Definition AS 64; Siemens, The Netherlands). The modified Pfirrmann score for dogs on T2-weighted images was used to grade the degeneration status of the affected intervertebral disc in animals that underwent MRI.<sup>24</sup> Postoperative imaging included radiography (Digital RAD TH; Phillips) and/or CT. All imaging was performed with the cervical spine in neutral position.

## 2.6 | Follow-up

Follow-up included the Helsinki pain score questionnaire<sup>25</sup> and neurological grading according to the Griffith scale.<sup>21,22</sup> Owners scored the Helsinki questionnaire preoperatively and postoperatively at the long-term follow-up encounter or when CT was used to measure bone ingrowth through the cage to determine the degree of fusion.

Radiographs were assessed for implant stability, subsidence, and fusion. The criteria for assessment of radiographic fusion were adapted from McAfee et al.<sup>26</sup> Fusion was considered successful when there was evidence of continuous bony bridging between the vertebral bodies and no peri-implant lucency or evidence of implant loosening.<sup>26</sup>

Subsidence was present when the distance between the cranial endplate to the caudal endplate decreased.<sup>26</sup> Postoperative radiographs and CT images were assessed for adjacent segment pathology on the basis of disc space narrowing and degenerative changes at the end plates of adjacent vertebral bodies.<sup>7</sup> Minor complications were defined as those requiring no follow-up surgical or medical intervention, whereas major complications were defined as those that did require such intervention.

## 2.7 | Measurement of ingrowth of bone through the cage

The obtained DICOM (Digital Imaging and Communications in Medicine) files were transferred to an image analysis program (Mimics Medical v19; Materialise, Leuven Belgium) and subjected to multiplanar reconstruction to position the largest hole of the cage in line with the normal (craniocaudal) geometrical axis of the cage. A cylinder was fit into the inner volume of the cage (5.0-mm diameter  $\times$  4.5-mm length) and isolated by using the Boolean subtraction method as the region of interest. On this region of interest, automated threshold values for compact bone (Hounsfield unit [HU], 662-1988) and all bone (HU, 266-1988) were used to segment the bone. The percentage of threshold volume to the whole volume of the region of interest was calculated to measure the amount of bone ingrowth in the largest hole of the cage.

A 2-year-old mongrel dog, weighing 25 kg and euthanized for unrelated reasons, was used as control. This specimen was obtained from a donation program; the owners gave written consent and allowed use of the body for educational and research purposes. A titanium cage was inserted into the cadaver dog between C5 and C6 by using a surgical procedure similar to that used for the dogs with CCSM, followed by CT with similar settings. With the cadaver dog's CT result as a negative control, we used the overestimation effects of scattering caused by the empty titanium cage to calculate bone ingrowth in the largest hole in the titanium cage inserted in the CCSM dogs. We used the percentages of bone volume of the cadaver dog as negative control percentages representing the scattering

of the cage within the chosen HU thresholds to calculate the actual bone ingrowth in the CCSM dogs.

## 2.8 | Postmortem analysis

The postmortem caudal cervical spine segments were fixed and stored in a neutral-buffered 4% formaldehyde solution for  $\mu$ CT and histopathology. Micro-computed tomography (Quantum FX; Perkin Elmer, Waltham, Massachusetts) was performed under tube voltage of 90 kV, tube current of 180  $\mu$ A, scan time of 3 minutes, and resolution of 42  $\mu$ m. The three-dimensional images of the spine were automatically reconstructed in the built-in software of the  $\mu$ CT. The reconstructed images were then transferred to an image analysis program (Mimics Medical v19, Materialise), and the amount of bone ingrowth in the cage was calculated in the same manner as for CT images. For histopathological analysis, the formalin-fixed spinal segment including plates and cage was dehydrated by using benzoyl peroxide and embedded in methyl methacrylate with plastoid-N and benzoyl peroxide for qualitative assessment by histopathology. Histological sections of approximately 30  $\mu$ m were cut with a diamond saw (Leica SP1600; Leica Microsystems, Wetzlar, Germany), stained with methylene blue followed by basic fuchsin, and evaluated by a board-certified veterinary pathologist (G.C.M.G.).

## 2.9 | Statistical analysis

Statistical analysis was performed in SPSS v17 (SPSS, Chicago, Illinois). The Helsinki pain score, neurological Griffith scale, and presence of subsidence in each dog were tested for normal distribution, and, afterward, a Student's paired *t* test was applied. Significance was set at  $P < .05$ .

# 3 | RESULTS

## 3.1 | Demographics, diagnostic findings, and surgery

Nine dogs were included in the study, with a mean  $\pm$  SD age of  $80.7 \pm 33.4$  months and weight of  $36.4 \pm 4.7$  kg (Table 1). Diagnosis of CCSM was based on neurological examination (C1-T2 localization), survey radiographs, MRI (eight dogs), and CT (1 dog; Table 2, Figure 3). Spinal cord compression was caused by intervertebral disc protrusion alone or in combination with bone-related compression, other soft tissue compression, or vertebral canal stenosis. Two dogs (dogs 3 and 6) had evidence of preexisting, consolidated discospondylitis with secondary degeneration of the affected disc and subsequent CCSM. A swab was inserted into the intervertebral disc space during surgery for bacterial culture in both dogs, and both tested negative. One dog (dog 2) had undergone a prior surgical

**TABLE 1** Signalment, NG, and HPS in nine dogs with CCSM

Dog	Breed	BW, kg	Sex	Age, y	NG <sup>a</sup>		HPS <sup>b</sup>	
					Preop	Postop	Preop	Postop
1	Weimaraner	34	ME	7.5	2	0	36/44	12/44
2	Bernese mountain dog	47	MN	6	2	2	37/44	27/44
3	Bouvier des Flandres	37	ME	9.5	3	1	42/44	11/44
4	Weimaraner	35	FS	8.5	3	1-2	44/44	2/44
5	Weimaraner	31	ME	8.5	2	1	26/44	25/44
6	Golden retriever	34	ME	0.5	1	0	43/44	6/44
7	Golden retriever	36	ME	5.5	1	1	34/40	6/44
8	Weimaraner	34	MN	9	3	1	25/44	7/36
9	Bernese mountain dog	41	ME	5.5	2	0	31/44	13/44

Abbreviations: BW, body weight; CCSM, caudal cervical spondylomyelopathy; FS, female spayed; HPS, Helsinki pain score; ME, male entire; MN, male neutered; NG, neurological grade; Postop, postoperative; Preop, preoperative.

<sup>a</sup>According to the modified Griffith scale.<sup>21,22</sup>

<sup>b</sup>According to the Helsinki pain questionnaire.<sup>25</sup>

**TABLE 2** Imaging, diagnosis, and surgery in nine dogs with CCSM

Dog	Previous surgery or diagnosis	Imaging	Level of CCSM	Pfirman grading, <sup>24</sup> T2W MRI	Implants			Surgical time, min	Hospitalization, day
					Cage	Unilock plates	Screws		
1	None	RX, MRI	C5-C7	4, C5-C6; 5, C6-C7	Syncage	2 × 2.4	14	191	1
2	C-Lox	RX, MRI	C6-C7	3	Syncage	2 × 2.4	10	164	4
3	Discospondylitis	RX, MRI	C6-C7	5	Syncage	2 × 2.4	10	210	2
4	None	RX, MRI	C5-C6	4	Syncage	2 × 2.4	12	303	4
5	None	RX, CT	C6-C7	Collapsed disc	Syncage	2 × 2.0	12	221	2
6	Discospondylitis	RX, MRI	C6-C7	5	Syncage	2 × 2.0	8	165	1
7	None	RX, MRI	C6-C7	5	Syncage	2 × 2.4	10	215	2
8	None	RX, MRI	C5-C7	4, C5-C6; 5, C6-C7	Syncage	2 × 2.4	10	174	1
9	None	RX, MRI	C6-C7	3	Syncage	2 × 2.4	8	158	1

Abbreviations: CCSM, caudal cervical spondylomyelopathy; CT, computed tomography; RX native radiography.

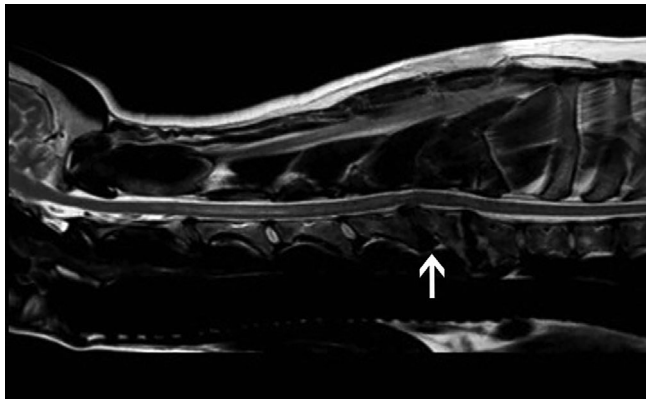
procedure with a different titanium cage type (C-Lox; Rita Leibinger) but that dog's condition had deteriorated neurologically within 1 week because of implant failure. Loosening of both cranial screws and ventral dislocation of the titanium cage were present. Surgery and anesthesia were uneventful in all animals. Mean  $\pm$  SD surgical time was  $200 \pm 45$  minutes, and hospitalization time was  $2 \pm 1$  days (Table 2).

Surgical treatment involved fixation with two Unilock plates secured with eight to sixteen 2.0- or 2.4-mm self-tapping titanium locking and cortical screws (Table 2). The two plates were of similar length and varied in size from six to nine holes. The holes at the level of the cage were left open.

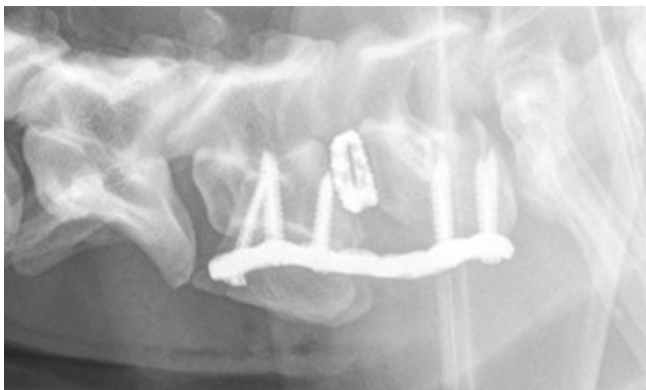
### 3.2 | Imaging

Radiographs were obtained immediately and 6 weeks after surgery in all dogs (Figure 4). Follow-up radiographs were obtained 3 to 6 months after surgery in seven of nine dogs. Radiographs were repeated at more than 20 months after surgery in three of nine dogs. The longest postsurgery follow-up by radiographs was 51 months. Five dogs returned for follow-up CT between 10 and 33 months after surgery. Bony bridging was present between the vertebral bodies in all dogs, without any peri-implant lucency. Formation of bone was seen in between the vertebral bodies, but fusion through the cage could not be assessed fully on radiographs.

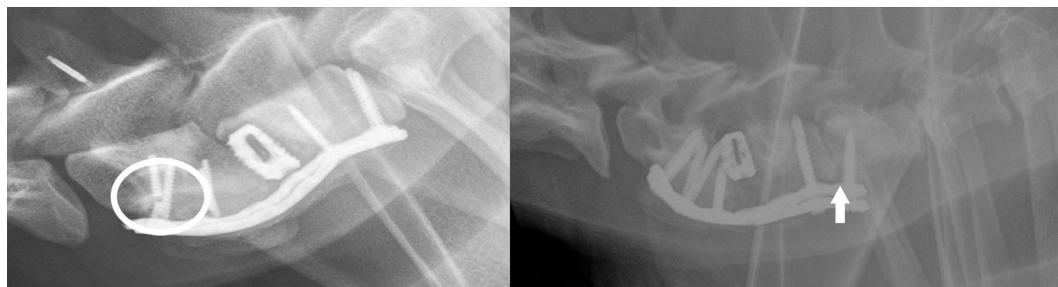



**FIGURE 3** Sagittal T2W MR image of dog 4 in neutral position. At the level of C5-C6 (white arrow) T2W signal intensity is absent, which is also noted at C6-C7 and C7-T1. The craniodorsal aspect of the vertebral body of C6 shows mild tipping toward the vertebral canal. There is a large amount of T2W hypointense extradural material noted at the ventral aspect of the spinal canal at the level of C5-C6, causing compression of the spinal cord at this level. Mild dilatation of the central spinal canal can be seen cranial to C5-C6. MRI findings are compatible with caudal cervical spondylomyelopathy at the level of C5-C6. At the level of C6-C7, there is no evidence of compression of the spinal cord



**FIGURE 4** Postoperative sagittal radiographic images of dog 2, with caudal cervical spondylomyelopathy treated by distraction-fixation with the cage and titanium plates



**FIGURE 5** Sagittal radiographic images of dogs 6 (image at left) and 3 (image at right) with caudal cervical spondylomyelopathy treated by distraction-fixation with the cage and locking plates. At 6 months of follow-up, there was evidence of implant failure in case dog 6 (left), marked by a broken screw (circle in image at left). In this dog, there was also subsidence of the cage into the cranial endplate of C7. The image at right illustrates adjacent segment pathology due to engagement of screws in the adjacent intervertebral disc (arrow)

Subsidence was measured as the distance from the cranial endplate to the caudal endplate. The distance bridged the cranial vertebral segment, caudal vertebral segment, and interposed disc space. This distance measured immediately after surgery (median, 57.3 mm; range, 51-64) did not differ from that measured at 6 weeks (56.3 mm; range, 50-62;  $P = .6$ ), with a median difference in length of 1 mm (range, 0-3). Minimal changes in the distance between the cranial and caudal endplate (1-2 mm) in the other dogs of this cohort can be attributed to slight differences in positioning during imaging. Clear subsidence was present in one dog (dog 6; Figure 5) with preexisting discospondylitis; osteolysis at the caudal endplate of C6 and cranial endplate of C7 and a collapsed disc space at this level were noted on preoperative radiographs. Fusion was noted in all dogs when long-term radiographs were compared with those obtained 6 weeks after surgery. No evidence of cage migration was evident on follow-up radiographs and/or according to CT.

### 3.3 | Clinical follow-up

The follow-up period varied from 9 to 51 months after surgery (mean  $\pm$  SD, 27.4  $\pm$  13.4 months). All owners completed the Helsinki pain score questionnaire preoperatively, at the follow-up encounter, or in reporting the dog's function just prior to death when applicable. Three of nine dogs were still alive at time of writing, at 21, 36, and 51 months postoperatively (Table 3). Five of nine dogs were euthanized for reasons unrelated to CCSM, and one dog's (dog 1) neurological condition deteriorated to the extent that it was euthanized 29 months after surgery. Overall, a neurological improvement was detected according to the Griffith scale, with a mean of 2.1 (range, 1-3) prior to surgery and 0.8 (range, 0-2) postoperatively ( $P < .01$ , Student's paired  $t$  test). All dogs' scores improved on the Helsinki pain score questionnaire (Table 1, Figure 6). The pain score (mean  $\pm$  SD) was 36 of 44  $\pm$  7 preoperatively compared with 12 of 44  $\pm$  8.5 postoperatively ( $P < .01$ , Student's paired  $t$  test).

**TABLE 3** Outcomes of nine dogs with CCSM

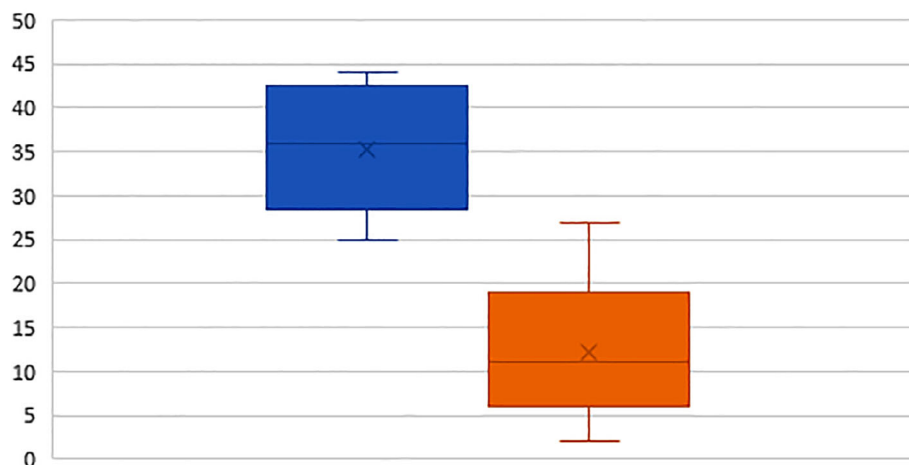
Dog	Bone ingrowth in cage				Complications					Follow-up			
	Imaging	CT settings			All bone, %	Compact bone, %	Broken screws	Screw loosening	Broken plates	Screws in IVD spaces	Survival, mo	Cause of death	ASP
		ST	kV	mAs									
1	CT	2 mm	100	151	57.8	23.2	0/14	1/14	2/2	C5-C6 C7-T1	40	Neurologic deterioration	C5-C6 <sup>a</sup> C7-T1 <sup>a</sup>
	µCT	42 µm	90	NA	65.3	35.6							
2	CT	2 mm	100	226	92.6	86.7	0/10	0/10	0/2	No	22	Histioytic sarcoma	NA
	µCT	42 µm	90	NA	91.5	69.8							
3	CT	2 mm	100	170	72.5	42.9	0/10	0/10	0/2	C7-T1	36	Alive	C5-C6 <sup>b</sup> C7-T1 <sup>a</sup>
4	CT	1 mm	120	330	88.9	60.9	0/12	0/12	0/2	C6-C7	31	Alive	C4-C5 <sup>a</sup> C6-C7 <sup>a</sup>
5	CT	2 mm	100	151	85.6	51.5	4/12	0/12	0/2	C7-T1	22	Prostate abscess	C5-C6 <sup>a</sup> C7-T1 <sup>a</sup>
6	RX						3/8	0/8	0/2	C7-T1	51	Alive	C7-T1 <sup>a</sup>
7	RX						2/10	0/10	0/2	C5-C6 C6-C7 C7-T1	9	Heart failure	C5-C6 <sup>a</sup> C7-T1 <sup>a</sup>
8	RX						0/10	0/10	0/2	C5-C6 C6-C7	12	Heart failure	C6-C7 <sup>a</sup>
9	RX						0/8	0/8	0/2	C6-C7	24	Primary bone tumor	NA

Abbreviations: ASP, adjacent segment pathology; CCSM, caudal cervical spondylomyelopathy; CT, computed tomography; IVD, intervertebral disc; NA, data not available; RX, radiograph; ST, slice thickness; µCT, micro-CT.

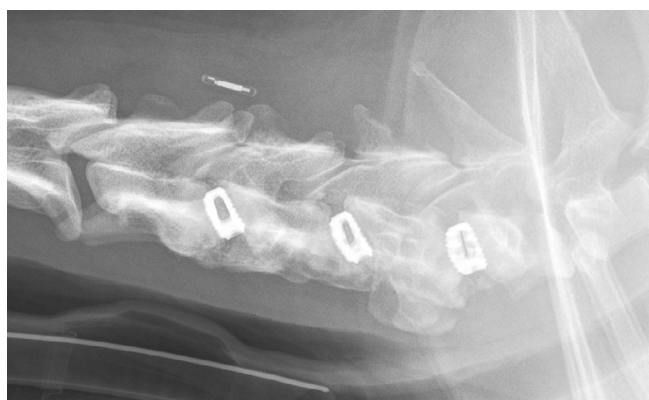
<sup>a</sup>Induced by implants.

<sup>b</sup>Induced by spinal fusion/bridging.

## Pre- and Post-operative Helsinki pain score questionnaire



**FIGURE 6** Helsinki pain score in nine dogs with caudal cervical spondylomyelopathy treated by distraction-fixation with an intervertebral spacer and locking plates. On this box plot, preoperative values are in blue and postoperative values are in orange. The box plot is bounded by the first quartile (bottom), and the third quartile (top), the horizontal line in the box represents the median, and the whiskers are error bars representing upward the maximum and downward the minimum of the data set



**FIGURE 7** Sagittal radiographic images of dog 4. Plates were removed, and adjacent segment disease was treated with two standalone cages at the levels of C4-C5 and C6-C7, next to the cage that was already in place at C5-C6

### 3.4 | Complications

Major complications were recorded for two dogs (dogs 4 and 5). At 7 months after surgery, one dog (dog 5) had developed apparent discomfort during swallowing, and broken screws were detected on follow-up imaging. Plates and screws were removed during revision surgery, but the cage was left in place. At 30 months after initial surgery, the neurological condition of dog 4 had worsened from grade 1 to grade 2 on the modified Griffith scale, and ASP in adjacent segments was diagnosed by CT. The owner elected revision surgery; screws and plates were removed, and two additional stand-alone cages were placed at C4-C5 and C6-C7 (Figure 7). Six weeks postoperatively, implants appeared unchanged on radiographs, and osseous fusion was present on the ventral side of the vertebral bodies of C4 to C7. This dog was still alive at the time of writing and had clinically improved to grade 1 on the Griffith scale.<sup>21,22</sup>

Minor complications included broken screws (Figure 5) in two other dogs (dogs 6 and 7) and two broken plates in one dog (dog 1) at 22 months after surgery. Revision surgery was

not deemed indicated because these findings were not associated with clinical signs, and spinal fusion was evident on radiography and CT. Adjacent segment pathology was visible in seven of nine dogs, in the cranial and caudal adjacent segments in five dogs and in the segment caudal to the cage location in two dogs. In eight of nine dogs, implants affected adjacent intervertebral discs; in total, 12 intervertebral disc spaces were affected, of which 11 of 12 showed ASP (Table 3, Figure 5). However, discomfort was not noted in any of the dogs except for dog 4, as described previously. One screw at C5 entered the ventral vertebral canal without apparent clinical signs in dog 8.

### 3.5 | Bone ingrowth through the cage

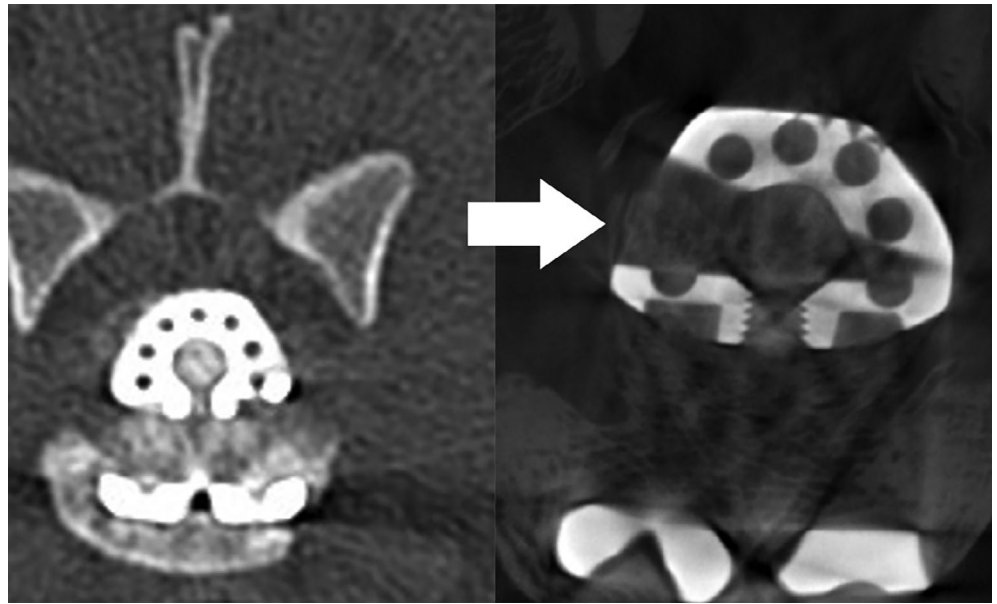
Owners of two dogs, dogs 1 and 2, that were euthanized at 40 and 22 months, respectively, after surgery (Table 3) gave consent to recover the cervical spine segment. The segments were subjected to radiography, CT (Figure 8),  $\mu$ CT (Figure 8), and subsequent histopathology. Bone fusion through the central largest hole of the cage was evident according to radiography, CT, and  $\mu$ CT (Table 3). According to CT, bone (mean  $\pm$  SD) represented  $79.2\% \pm 13.9\%$  (control  $48.5\%$ ) of the volume of the central largest hole of the cage (resembling a cylinder), and compact bone filled  $53.0\% \pm 21.5\%$  (control  $10.9\%$ ) of the volume. The percentages measured in the control are consistent with the amount of scattering of the cage, which was within the chosen HU threshold; percentages higher than the control were therefore more likely to be osseous tissue. According to CT vs  $\mu$ CT, the percentage of bone ingrowth for all bone and for compact bone in dog 1 was  $57.8\%$  vs  $65.3\%$  and  $23.2\%$  vs  $35.6\%$ , respectively; for dog 2, these values were  $92.6\%$  vs  $91.5\%$  and  $86.7\%$  vs  $69.8\%$ , respectively (Table 3).

### 3.6 | Histopathological examination

The intervertebral disc containing the cage was filled with fibrous tissue and a limited amount of trabecular bone in one



**FIGURE 8** Transverse reconstruction of computed tomography (CT, left) and micro-CT (right) images of dog 2 with caudal cervical spondylomyelopathy at 16 months and 22 months after treatment by distraction-fixation with an intervertebral spacer and locking plates



**FIGURE 9** Histopathology (methylene blue, basic fuchsin staining) of dog 1 (A,B) and dog 2 (C,D). Bone tissue is stained red-pink, and the titanium cage is stained black. The center of the cage of dog 1 (A,B) is filled mainly with fibrous tissue, whereas, in dog 2 (C,D), the center of the cage is largely filled with bone, and complete fusion of the vertebral body is established. Scale bars = 2.5 mm in A; 0.75 mm in B; 2.9 mm in C; 151  $\mu$ m in D



dog (dog 1, 40-month survival; Figure 9A,B). The tissue surrounding the cage consisted mainly of thin trabeculae of well-differentiated bone with less density compared with the bone tissue of the other dog (dog 2). In dog 2, well-differentiated trabeculae of lamellar bone and some fibrous tissue were present within the cage (22-month survival; Figure 9C,D). The trabecular bone appeared continuous with the bone of both adjacent vertebral bodies. Most of the annulus fibrosus and nucleus pulposus could not be identified because of replacement by well-differentiated bone.

## 4 | DISCUSSION

Combining cage and double plating with an autologous bone graft led to radiographic evidence of bony fusion between vertebrae in nine dogs in which CCSM had been diagnosed. Osseous fusion through the cage was confirmed in all dogs that underwent CT at 9 to 51 months postoperatively. Clinical signs improved in all nine dogs, but the neurological condition of one dog (dog 1) deteriorated 29 months after surgery, prompting euthanasia.

The SynCage used in this study was designed to stabilize, align, preserve, and restore function of the cervical spine and prevent disability in human patients. Multiple sizes of the cage are available, but only the smallest size (curved, C 4.5) was appropriate for the large-breed dogs in our study. Dogs have a natural lordotic position that increases the risk of ventral extrusion of intervertebral implants from shearing forces, and ventral fixation and stabilization are often required to prevent ventral dislodging of the intervertebral implants.<sup>27</sup> Dog 4, however, presented with ASD (adjacent segment pathology with clinical signs) at 30 months after the initial surgery, and two stand-alone cages were placed in the adjacent intervertebral discs. Radiographs at 6 weeks postoperatively revealed stable presentation of the implants and bony fusion on the ventral side of the vertebral bodies of C4 to C7; the dog was still alive at the time of writing and had clinically improved. It remains to be determined whether ventral fixation is redundant specifically in the cervical spine.

Combining plate fixation with placement of a distraction device such as a cage has been found to increase the rate of spinal fusion in man.<sup>28</sup> Fusion through bone bridging on the ventral or lateral side of the vertebral bodies and the plates was confirmed by radiography in 100% of the dogs. In dogs that underwent CT at long-term follow-up (10 to 33 months after surgery), osseous fusion through the cage was present to a variable extent (23.2%–86.7% of compact bone). In the two dogs whose spines were examined with  $\mu$ CT and histopathology, complete spinal fusion was evident through the cage in the dog (dog 2) that survived 22 months, and partial fusion was seen in the dog (dog 1) that survived 40 months. When the reported fusion rates within the follow-up period

of the present study are considered, in the long-term (ie, more than 10 months), time does not seem to play a significant role in outcome.

Significant subsidence was observed in one dog with preceding discospondylitis in the present study. Early postoperative subsidence occurred in 30% of humans treated with stand-alone cervical carbon fiber cages, without influence on clinical outcome or success of fusion.<sup>29</sup> Implant loosening or breakage of screws or plates was observed in five dogs, but only one of these dogs showed clinical signs of pain during swallowing, according to owner report. In this dog (dog 5), the implant failure was noted at 7 months after surgery, and fusion through the cage and bone bridging was already complete at that stage. Therefore, implant loosening or failure might be of less significance when stabilization from fusion or bone bridging has already been accomplished.

Adjacent segment pathology was observed by imaging in seven of nine dogs in the present study; however, only one dog's (dog 1) condition deteriorated in the long term. Adjacent segment pathology can be caused by progressive spontaneous degeneration of intervertebral discs over time, spinal fusion of a spinal segment causing an altered biomechanical loading of adjacent intervertebral discs, and effects of spinal implants (screws, plates) on the intervertebral disc or endplate.<sup>16</sup> It is not clear from our study to what extent each of these elements contributed to ASP, but, in our dogs, screws or plates frequently affected the adjacent disc, providing evidence of their probable role in the development of ASP. Adjacent segment pathology was seen in 12 of 18 adjacent segments, and, in 11 of 12 of these segments, the possible cause was iatrogenic, attributable to engagement of adjacent intervertebral discs by implants (screws or plates). There was no standardization in the number of intervertebral disc spaces bridged by the ventral plates in this study. After making comparisons among earlier cervical fixation studies, we noted that ASP was not assessed in neurologically improved dogs except in Steffen et al.<sup>7</sup> Imaging was performed, and ASP was diagnosed only in dogs that showed neurological deterioration.<sup>4,18,30-32</sup> Results of our study lead us to advise monitoring all dogs clinically (regardless of neurological improvement or not) during long-term follow-up. When dogs show neurological deterioration, imaging is advisable. In cases of ASP associated with clinical signs, the condition can be referred to as ASD.

The limitations of this study include its retrospective nature, small cohort of animals, descriptive nature, and lack a control group. Another limitation inherent to the retrospective nature of the study consists of the variability in assessment: one dog underwent CT while eight others underwent MRI. In our clinic, dynamic MRI is not routinely performed when CCSM has already been diagnosed in the neutral position unless clinical signs are inconclusive. The increase in anesthetic time, costs, and clear diagnosis on neutral MRI

were the main reasons to omit dynamic MRI. The selection of animals may have been biased by the high costs of the implants, which are in the same range as for fracture fixation and are reserved for a smaller population of client-owned dogs. Also, titanium scattering hampers assessment of bone fusion through the cage when performing  $\mu$ CT. To resolve this issue, we performed a calibration CT study in a cadaver dog with a cage placed in the caudal cervical spine, which allowed measurement of the baseline scattering by the cage and estimation of the amount of bone formation in the cages of our dogs with CCSM. However, some degree of scattering by the plates affecting the calculation of bone ingrowth in the cage could not be eliminated in this study.

In conclusion, the clinical outcomes of the nine dogs reported here were good, with a minimum follow-up time of 9 months in dogs with disc-associated CCSM treated by distraction-fixation with an intervertebral titanium cage and plates. Radiographs provided evidence of interbody spinal fusion in all dogs in addition to CT confirmation in five of five dogs and  $\mu$ CT and histopathology confirmation in two of two dogs each. Infraclinical ASP was associated with plates or screws engaging adjacent intervertebral disc spaces. Intervertebral disc spaces adjacent to the affected disc space should be avoided in the fixation.

## CONFLICT OF INTEREST

The authors declare no conflicts of interest related to this report.

## ORCID

Koen Willemsen  <https://orcid.org/0000-0002-8237-6321>

## REFERENCES

1. VanGundy TE. Disc-associated wobbler syndrome in the Doberman Pinscher. *Vet Clin Small Anim Pract.* 1998;18(3):667-696.
2. da Costa RC. Cervical spondylomyelopathy (wobbler syndrome) in dogs. *Vet Clin Small Anim Pract.* 2010;40(5):881-913.
3. Da Costa RC, Parent JM, Holmberg DL, Sinclair D, Monteith G. Outcome of medical and surgical treatment in dogs with cervical spondylomyelopathy: 104 cases (1988-2004). *J Am Vet Med Assoc.* 2008;233(8):1284-1290.
4. Solano MA, Fitzpatrick N, Bertran J. Cervical distraction-stabilization using an intervertebral spacer screw and string-of-pearl (SOP) plates in 16 dogs with disc-associated wobbler syndrome. *Vet Surg.* 2015;44(5):627-641.
5. Trotter EJ. Cervical spine locking plate fixation for treatment of cervical spondylotic myelopathy in large breed dogs. *Vet Surg.* 2009;38(6):705-718.
6. Bergman RL, Levine JM, Coates JR, Bahr A, Hettlich BF, Kerwin SC. Cervical spinal locking plate in combination with cortical ring allograft for a one level fusion in dogs with cervical spondylotic myelopathy. *Vet Surg.* 2008;37(6):530-536.
7. Steffen F, Voss K, Morgan JP. Distraction-fusion for caudal cervical spondylomyelopathy using an intervertebral cage and locking plates in 14 dogs. *Vet Surg.* 2011;40(6):743-752.
8. Joffe MR, Parr WCH, Tan C, Walsh WR, Brunel L. Development of a customized interbody fusion device for treatment of canine disc-associated cervical spondylomyelopathy. *Vet Comp Orthop Traumatol.* 2019;32(1):79-86.
9. Rohner D, Kowaleski MP, Schwarz G, Foreterre F. Short-term clinical and radiographical outcome after application of anchored intervertebral spacers in dogs with disc-associated cervical spondylomyelopathy. *Vet Comp Orthop Traumatol.* 2019;32(2):158-164.
10. Bakhsheshian J, Mehta VA, Liu JC. Current diagnosis and management of cervical spondylotic myelopathy. *Global Spine J.* 2017;7:572-586.
11. Adamo P, Burns G. Cervical arthroplasty in dogs with disc-associated caudal cervical spondylomyelopathy and cervical disc herniation: preliminary study of two cases. *J Vet Intern Med.* 2009;23(3):710.
12. Adamo F, Forterre F. Will there be a role for disc prostheses in small animals? In: Fingerroth JM, Thomas WB, eds. *Advances in Intervertebral Disc Disease in Dogs and Cats.* Ames, IA: ACVSI-Wiley-Blackwell; 2015:294-306.
13. Joaquim AF, Makhni MC, Riew KD. Evidence-based use of arthroplasty in cervical degenerative disc disease. *Int Orthop.* 2019;43(4):767-775.
14. Baskin JJ, Vishteh AG, Dickman CA, Sonntag VK. Techniques of anterior cervical plating. *Oper Tech Neurosurg.* 1998;1(2):90-102.
15. Park P, Garton HJ, Gala VC, Hoff JT, McGillicuddy JE. Adjacent segment disease after lumbar or lumbosacral fusion: review of the literature. *Spine (Phila Pa 1976).* 2004;29(17):1938-1944.
16. Hilibrand AS, Robbins M. Adjacent segment degeneration and adjacent segment disease: the consequences of spinal fusion? *Spine J.* 2004;4(6):190-194.
17. Chow DH, Luk KD, Evans JH, Leong JC. Effects of short anterior lumbar interbody fusion on biomechanics of neighboring unfused segments. *Spine.* 1996;21(5):549-555.
18. Wilson ER, Aron DN, Roberts RE. Observation of a secondary compressive lesion after treatment of caudal cervical spondylomyelopathy in a dog. *J Am Vet Med Assoc.* 1994;205(9):1297-1299.
19. Ortega M, Gonçalves R, Haley A, Wessmann A, Penderis J. Spondylosis deformans and diffuse idiopathic skeletal hyperostosis (DISH) resulting in adjacent segment disease. *Vet Radiol Ultrasound.* 2012;53(2):128-134.
20. De Decker S, Caemaert J, Tshamala MC, et al. Surgical treatment of disk-associated wobbler syndrome by a distractable vertebral titanium cage in seven dogs. *Vet Surg.* 2011;40(5):544-554.
21. Griffiths I. Small animal clinic spinal disease in the dog. *In Pract.* 1982;4:44-52.
22. Wheeler SJ, Sharp NJ. Patient examination. *Wheeler SJ, Sharp NJ. Small Animal Spinal Disorders, Diagnosis and Surgery.* 2nd ed. Philadelphia, PA: Elsevier-Mosby; 2005:32.
23. Platt SR, da Costa RC. Cervical vertebral column and spinal cord. In: Johnston SA, Tobias KM, eds. *Veterinary Surgery.* 2nd ed. St Louis, MO: Elsevier Health Sciences; 2017:465-467.

24. Bergknut N, Auriemma E, Wijsman S, Voorhout G, Hagman R, Lagerstedt A. Evaluation of intervertebral disk degeneration in chondrodystrophic and nonchondrodystrophic dogs by use of Pfirrmann grading of images obtained with low-field magnetic resonance imaging. *Am J Vet Res.* 2011;72(7):893-898.
25. Wiseman-Orr ML, Scott EM, Reid J, Nolan AM. Validation of a structured questionnaire as an instrument to measure chronic pain in dogs on the basis of effects on health-related quality of life. *Am J Vet Res.* 2006;67(11):1826-1836.
26. McAfee PC, Boden SD, Brantigan JW, et al. Symposium: a critical discrepancy—a criteria of successful arthrodesis following interbody spinal fusions. *Spine.* 2001;26(3):320-334.
27. Schöllhorn B, Bürki A, Stahl C, Howard J, Forterre F. Comparison of the biomechanical properties of a ventral cervical intervertebral anchored fusion device with locking plate fixation applied to cadaveric canine cervical spines. *Vet Surg.* 2013;42(7):825-831.
28. Kaiser MG, Haid RW Jr, Subach BR, Barnes B, Rodts GE Jr. Anterior cervical plating enhances arthrodesis after discectomy and fusion with cortical allograft. *Neurosurgery.* 2002;50(2):229-238.
29. Bartels RH, Donk RD, Feuth T. Subsidence of stand-alone cervical carbon fiber cages. *Neurosurgery.* 2006;58(3):502-508.
30. Bergman RL, Levine JM, Coates JR, Bahr A, Hettlich BF, Kerwin SC. Cervical spinal locking plate in combination with cortical ring allograft for a one level fusion in dogs with cervical spondylotic myelopathy. *Vet Surg.* 2008;37(6):530-536.
31. da Silva AC, Bernard F, Bardet J. Caudal cervical arthrodesis using a distractable fusion cage in a dog. *Vet Comp Orthop Traumatol.* 2010;23(03):209-213.
32. McKee W, Butterworth S, Scott H. Management of cervical spondylopathy-associated intervertebral disc protrusions using metal washers in 78 dogs. *J Small Anim Pract.* 1999;40(10):465-472.

**How to cite this article:** Reints Bok TE, Willemsen K, van Rijen MHP, Grinwis GCM, Tryfonidou MA, Meij BP. Instrumented cervical fusion in nine dogs with caudal cervical spondylomyelopathy. *Veterinary Surgery.* 2019;48:1287–1298. <https://doi.org/10.1111/vsu.13312>