

A novel *CASR* mutation (p.Glu757Lys) causing autosomal dominant hypocalcaemia type 1

Benjamin Kwan^{1,2}, Bernard Champion^{1,3}, Steven Boyages^{1,4}, Craig F Munns^{1,5},
Roderick Clifton-Bligh^{1,6}, Catherine Luxford^{1,6} and Bronwyn Crawford^{1,2}

¹University of Sydney, Sydney, New South Wales, Australia, ²Department of Endocrinology, Concord Repatriation General Hospital, Sydney, New South Wales, Australia, ³Department of Clinical Medicine, Macquarie University, Sydney, New South Wales, Australia, ⁴Department of Endocrinology, Westmead Hospital, Sydney, New South Wales, Australia, ⁵The Children's Hospital at Westmead, Sydney, New South Wales, Australia, and ⁶Cancer Genetics Laboratory, Kolling Institute, Royal North Shore Hospital, Sydney, New South Wales, Australia

Correspondence
should be addressed
to B Kwan
Email
benjamin.kwan@sydney.edu.au

Summary

Autosomal dominant hypocalcaemia type 1 (ADH1) is a rare familial disorder characterised by low serum calcium and low or inappropriately normal serum PTH. It is caused by activating *CASR* mutations, which produces a left-shift in the set point for extracellular calcium. We describe an Australian family with a novel heterozygous missense mutation in *CASR* causing ADH1. Mild neuromuscular symptoms (paraesthesia, carpopedal spasm) were present in most affected individuals and required treatment with calcium and calcitriol. Basal ganglia calcification was present in three out of four affected family members. This case highlights the importance of correctly identifying genetic causes of hypocalcaemia to allow for proper management and screening of family members.

Learning points:

- ADH1 is a rare cause of hypoparathyroidism due to activating *CASR* mutations and is the mirror image of familial hypocalciuric hypercalcaemia.
- In patients with ADH1, symptoms of hypocalcaemia may be mild or absent. Basal ganglia calcification may be present in over a third of patients.
- *CASR* mutation analysis is required for diagnostic confirmation and to facilitate proper management, screening and genetic counselling of affected family members.
- Treatment with calcium and activated vitamin D analogues should be reserved for symptomatic individuals due to the risk of exacerbating hypercalciuria and its associated complications.

Background

ADH1 is a rare disorder arising from activating mutations of the calcium-sensing receptor gene (*CASR*). It is the mirror image of familial hypocalciuric hypercalcaemia and is characterised by hypocalcaemia with low or inappropriately normal PTH. To date, more than 70 mutations have been reported in association with ADH1

(1). Treatment with activated vitamin D analogues and calcium should be reserved for symptomatic patients, due to the risk of hypercalciuria and severe complications such as nephrocalcinosis, nephrolithiasis and renal impairment. We describe an Australian family with a novel heterozygous missense mutation causing ADH1.

Case presentation

A 40-year-old Caucasian woman presented with muscle spasms affecting the hands, feet, abdomen and chest. She had been diagnosed with hypocalcaemia at age 23 years during her second pregnancy. At that time, she was noted to have basal ganglia calcification on CT imaging performed for investigation of Bell's palsy. She had a history of childhood *petit mal* seizures. Her medications included calcitriol 0.25 µg daily, calcium 600mg daily and cholecalciferol 1000 IU daily. Despite this, she had symptomatic hypocalcaemia with an inappropriately low-normal PTH: serum calcium 1.94 mmol/L (reference range 2.15–2.55 mmol/L), PTH 1.7 pmol/L (reference range 1.6–6.9 pmol/L). Serum magnesium, phosphate and creatinine levels were in the normal range. A 24-h urine calcium while on treatment was 7.2 mmol/day (reference range 2.5–7.5 mmol/day).

There was a family history of hypocalcaemia also in her brother, nephew and father (Fig. 1). Her 43-year-old brother had a history of recurrent muscle spasms since youth. After being diagnosed with type 1 diabetes mellitus at age 28 years, he decided to undergo a whole-body CT scan (as part of a general health check), which showed basal ganglia calcification. Serum calcium was low (1.93 mmol/L), as was PTH (0.7 pmol/L). He was subsequently treated with oral calcium, calcitriol 0.5 µg bd and magnesium. In 2007, when his 3-year-old son required a blood test for an unrelated, acute febrile illness, his father requested serum calcium be measured. The serum calcium was 1.82 mmol/L, PTH 1.0 pmol/L, phosphate 2.25 mmol/L (reference range 0.80–1.50), with normal serum creatinine and magnesium. A spot urine calcium to creatinine ratio was 0.26 (reference range 0.05–1.1). There was no calcification seen on a brain CT at age 4 years. During childhood, he developed muscle

cramps at night after prolonged activity and episodes of jaw tetany. He also had a history of attention deficit hyperactivity disorder and obsessive compulsive disorder. There was no history of seizure disorder. He was treated with calcitriol 0.75 µg bd and calcium 600mg daily, with symptomatic relief and maintenance of serum calcium between 1.8–1.9 mmol/L. Serial renal tract ultrasounds have not demonstrated nephrolithiasis.

The index patient's 65-year-old father had asymptomatic hypocalcaemia discovered incidentally after he presented with an electrocution injury many years ago. He had no symptoms of hypocalcaemia. He had a history of type 2 diabetes mellitus, chronic obstructive pulmonary disease, vitamin B12 deficiency and gastroesophageal reflux disease. His serum calcium was 1.92 mmol/L, PTH 2.7 pmol/L and 24-h urine calcium 1.9 mmol/day. A brain MRI showed bilateral basal ganglia and cerebellar dentate nuclei calcification. He was not treated with any calcium or calcitriol.

Investigation

The index patient underwent genetic testing. Chromosomal analysis with fluorescence *in situ* hybridisation was arranged primarily to exclude 22q11.2 deletion syndrome (DiGeorge syndrome) and was normal. Sanger sequencing revealed a heterozygous CASR missense variant (c.2269G>A, p.Glu757Lys). The affected family members (father, II-1; brother, III-2; nephew, IV-1 – see Fig. 1) were subsequently referred for CASR mutation analysis and each found to harbour the same CASR variant (c.2269G>A, p.Glu757Lys) (Table 1). This variant has not yet been reported to be associated with ADH1 and has not been identified in normal population cohorts. Its pathogenicity is supported by segregation with phenotype

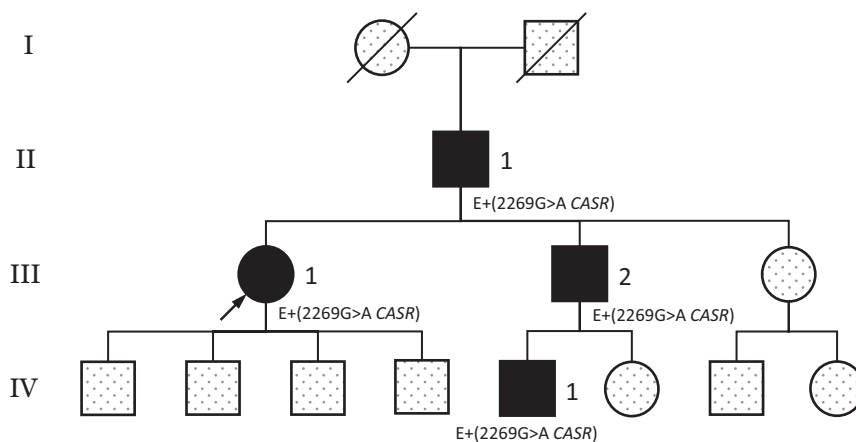


Figure 1
Family pedigree. The arrow indicates the proband. Filled symbols, individuals with hypocalcaemia; dotted symbols, status unknown; slash, deceased; E, CASR gene mutation analysis.

**Table 1** Characteristics of affected individuals.

Family member	Pedigree number ^a	Sex	Age, years	Serum calcium (corrected), mmol/L ^b		PTH, pmol/L ^c	Treatment	Basal ganglia calcification	Clinical features	<i>CASR</i> gene analysis
Proband	III-1	F	40	1.93	1.7	Calcitriol, calcium	Yes	Muscle spasms Childhood petit mal seizures	Heterozygous c.2269G>A	
Father	II-1	M	65	1.92	2.7	None	Yes	Asymptomatic	Heterozygous c.2269G>A	
Brother	III-2	M	43	1.93	0.7	Calcitriol, calcium	Yes	Muscle spasms	Heterozygous c.2269G>A	
Nephew	IV-1	M	13	1.78	1.0	Calcitriol, calcium	No	Muscle spasms Fatigue	Heterozygous c.2269G>A	

^aPedigree number as appears on family pedigree in Table 1. ^bSerum calcium reference range, 2.15–2.55 mmol/L. ^cPTH reference range 1.6–6.9 mmol/L.

in our kindred, its absence from population cohorts and *in silico* prediction tools (Polyphen-2, MutationTaster) (2, 3).

Outcome and follow-up

To date, there have been no adverse effects of treatment, such as nephrolithiasis, nephrocalcinosis or renal impairment in affected individuals treated with calcium and calcitriol. They are monitored with annual biochemistry (serum calcium, phosphate, creatinine), annual 24-h urine calcium measurement and second yearly renal tract ultrasound.

All affected individuals received genetic counselling. Laboratory and genetic testing was offered to the index patient's asymptomatic sister, who has declined. Our index patient's four offspring and her brother's unaffected offspring are currently asymptomatic (see Fig. 1). Serum calcium will be measured opportunistically whenever they should require laboratory testing for other reasons.

Discussion

We describe three generations of a family with ADH1 due to a novel heterozygous *CASR* missense mutation (c.2269G>A, p.Glu757Lys). ADH1 is a rare disorder arising from activating *CASR* mutations, characterised by hypocalcaemia and hypoparathyroidism due to a left-shift in the set point for extracellular calcium (4). Most reported mutations causing ADH1 are heterozygous missense mutations (www.casrdb.mcgill.ca) (1). Relative hypercalciuria may occur due to reduced PTH and lower renal calcium reabsorption, as well as increased activation of the mutated *CASR* in the distal renal tubule (5). The clinical presentation tends to be variable, ranging from asymptomatic hypocalcaemia to mild neuromuscular symptoms, and in severe cases, may manifest as seizures

(6). Basal ganglia calcification is seen commonly in ADH1. In one series, 36% of patients were observed to have basal ganglia calcification, with the youngest patient being 5 years of age (7). In our cohort, several kindred had basal ganglia calcification seen at diagnosis, consistent with this being a complication of the disease rather than its treatment.

Accurate diagnosis of ADH1 with confirmatory genetic testing is important to allow for appropriate screening and genetic counselling of family members and to avoid unnecessary treatment. Treatment of asymptomatic individuals should be avoided due to the risk of exacerbating hypercalciuria and its associated complications (nephrocalcinosis, nephrolithiasis and renal impairment). In symptomatic individuals, the aim of therapy should be to achieve symptom relief using the lowest possible dose of calcium and activated vitamin D analogues rather than aiming to achieve normocalcaemia. Thiazide diuretics may be used alongside calcitriol to reduce renal calcium excretion.

This case reports a novel *CASR* mutation causing ADH1. In patients presenting with hypoparathyroidism, a positive family history of hypocalcaemia should prompt clinicians to consider rarer familial causes, as these diagnoses will have important implications on management, screening and genetic counselling of affected individuals.

Declaration of interest

The authors declare that there is no conflict of interest that could be perceived as prejudicing the impartiality of this case report.

Funding

This research did not receive any specific grant from any funding agency in the public, commercial or not-for-profit sector.



Patient consent

All data have been fully anonymised and there is no identifying information in this manuscript. As such, written informed consent was not obtained but can be pursued at the journal's request.

Author contribution statement

B Kwan reviewed the literature and prepared the manuscript. B Champion, S Boyages and C Munns were treating physicians and reviewed the manuscript. R Clifton-Bligh and C Luxford assisted in reviewing the manuscript. B Crawford was the treating physician for the index patient and oversaw the preparation of the manuscript.

References

- 1 Pidasheva S, D'Souza-Li L, Canaff L, Cole DE & Hendy GN. CASRdb: calcium-sensing receptor locus-specific database for mutations causing familial (benign) hypocalciuric hypercalcemia, neonatal severe hyperparathyroidism, and autosomal dominant hypocalcemia. *Human Mutation* 2004 **24** 107–111. (<https://doi.org/10.1002/humu.20067>)
- 2 Adzhubei IA, Schmidt S, Peshkin L, Ramensky VE, Gerasimova A, Bork P, Kondrashov AS & Sunyaev SR. A method and server for predicting damaging missense mutations. *Nature Methods* 2010 **7** 248–249. (<https://doi.org/10.1038/nmeth0410-248>)
- 3 Schwarz JM, Cooper DN, Schuelke M & Seelow D. MutationTaster2: mutation prediction for the deep-sequencing age. *Nature Methods* 2014 **11** 361–362. (<https://doi.org/10.1038/nmeth.2890>)
- 4 Conigrave AD. The calcium-sensing receptor and the parathyroid: past, present, future. *Frontiers in Physiology* 2016 **7** 563. (<https://doi.org/10.3389/fphys.2016.00563>)
- 5 Roszko KL, Bi RD & Mannstadt M. Autosomal dominant hypocalcemia (hypoparathyroidism) types 1 and 2. *Frontiers in Physiology* 2016 **7** 458. (<https://doi.org/10.3389/fphys.2016.00458>)
- 6 Tan YM, Cardinal J, Franks AH, Mun HC, Lewis N, Harris LB, Prins JB & Conigrave AD. Autosomal dominant hypocalcemia: a novel activating mutation (E604K) in the cysteine-rich domain of the calcium-sensing receptor. *Journal of Clinical Endocrinology and Metabolism* 2003 **88** 605–610. (<https://doi.org/10.1210/jc.2002-020081>)
- 7 Raue F, Pichl J, Dörr HG, Schnabel D, Heidemann P, Hammersen G, Jausch-Hancke C, Santen R, Schöfl C, Wabitsch M, *et al.* Activating mutations in the calcium-sensing receptor: genetic and clinical spectrum in 25 patients with autosomal dominant hypocalcaemia - a German survey. *Clinical Endocrinology* 2011 **75** 760–765. (<https://doi.org/10.1111/j.1365-2265.2011.04142.x>)

Received in final form 21 August 2018

Accepted 30 August 2018