

Torsion of Normal Adnexa in a 31-year-old Woman: A Case Report and Literature Review

Nao Wakui, Ai Miyoshi, Yuji Kamei, Takeya Hara, Akiko Fujishiro, Serika Kanao, Hirokazu Naoi, Hirohumi Otsuka, Masaaki Nagamatsu, Takeshi Yokoi

Department of Obstetrics and Gynecology, Kaizuka City Hospital, Osaka, Japan

Abstract

It is known that a large ovarian cyst will likely cause torsion. However, normal adnexal torsion is rare and occurs in premenarchal girls in most cases. This is a case of a reproductive woman. A 31-year-old woman suffering from acute abdominal pain in the lower and right side consulted her gynecologist. The next day she had a computed tomography performed and was suspected of ovarian torsion. She did not have fever, nausea, or leukocytosis, but her abdominal pain persisted. Diagnostic laparoscopy was performed and showed torsion of the right fallopian tube, which was swollen and looked like a hydrosalpinx with a normal ovary. We did detorsion and excision of the right tube. However, pathological findings showed that the right tube was not a hydrosalpinx but was swollen due to blood stasis. We determined that this case was torsion of normal adnexa. In such cases, diagnostic laparoscopy is very effective.

Keywords: Diagnostic laparoscopy, reproductive woman, normal adnexal torsion

INTRODUCTION

Adnexal torsion is a relatively frequent cause of a woman's acute abdominal pain and can occur in individuals of any age, but most commonly during a woman's reproductive age. Most of the cases have some swelling of the adnexa, for example, paraovarian cysts, simple cysts, or dermoid cysts. In normal adnexal torsion, the twisted adnexa do not have any visible morphologic pathology and is very rare, occurring in about 8%–18% of all cases of torsions.^[1] Most adnexal torsion swelling occurs in postmenarchal women, but the most normal adnexal torsion occurs in premenarchal girls.^[2] To the best of our knowledge, a few cases have ever been reported in patients with the torsion of normal adnexa in a postmenarchal woman. We now report a rare case of normal adnexal torsion in a postmenarchal reproductive woman.

CASE REPORT

The case was 0 gravida, 31-year-old woman. She had never suffered from intrapelvic infectious diseases such as pelvic inflammatory disease or appendicitis. One day she felt a dull pain in her right side from the lower back to the abdomen. She consulted her gynecologist, but there was no abnormality in her uterus and bilateral adnexa. Next day, she consulted

her urologist as her pain continued. She had a computed tomography scan of the abdomen carried out. It showed that her right ovary and salpinx had swollen to 5 cm. Hence, she came to our hospital for treatment about 60 h after the onset of abdominal pain.

When she came to our hospital, she did not have a fever (her temperature was 36.8°C) or nausea. Her white blood cell (WBC) was 4890/ml, and C-reactive protein was within the normal range, but her abdominal pain continued. Magnetic resonance imaging revealed massive ovarian edema and a twisted salpinx [Figure 1]. We undertook a diagnostic laparoscopy about 68 h after the onset of abdominal pain. There was no ascites or adhesion. Her left adnexa and uterus looked normal, and her right adnexa were rotated 360° clockwise. The right ovary was a little swollen but not ischemic. There was no ovarian tumor [Figure 2]. As the right tube resembled hydrosalpinx, we thought that a hydrosalpinx was the cause

Address for correspondence: Dr. Nao Wakui,
Department of Obstetrics and Gynecology, Kaizuka City Hospital,
3-10-20 Hori Kaizuka-Shi, Osaka, Japan 597-0015.
E-mail: nao_wakui0307@yahoo.co.jp

This is an open access article distributed under the terms of the Creative Commons Attribution-NonCommercial-ShareAlike 3.0 License, which allows others to remix, tweak, and build upon the work non-commercially, as long as the author is credited and the new creations are licensed under the identical terms.

For reprints contact: reprints@medknow.com

How to cite this article: Wakui N, Miyoshi A, Kamei Y, Hara T, Fujishiro A, Kanao S, *et al.* Torsion of normal adnexa in a 31-year-old woman: A case report and literature review. *Gynecol Minim Invasive Ther* 2018;7:33-5.

Access this article online

Quick Response Code:



Website:
www.e-gmit.com

DOI:
10.4103/GMIT.GMIT_4_17

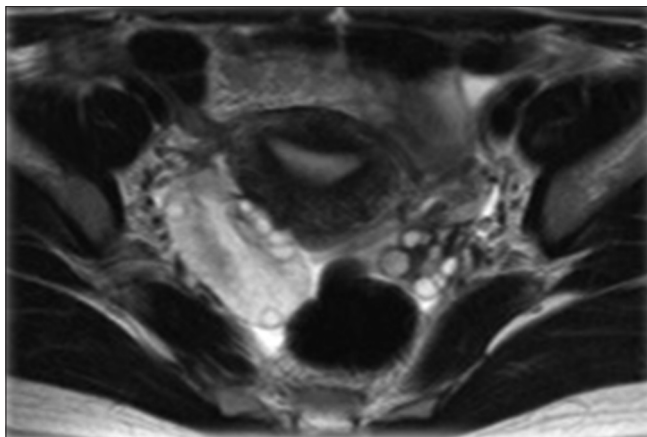


Figure 1: Magnetic resonance imaging image before operation; T2-weighted, coronal section image. Right ovarian edema was massive

of the right adnexa torsion. We performed detorsion of her adnexa and right salpingectomy to prevent recurrences. After the operation, her pain disappeared and she did not have any postoperative complications. We confirmed that her right ovary returned to a normal size of 31.5 mm. Her cervical mucus test was negative for *Neisseria gonorrhoeae* and *Chlamydia trachomatis*. She was discharged 7 days after the operation.

Pathological findings showed that the right tube was not a hydrosalpinx. Although the serous membrane side of the right tube looked very swollen, the edema of the interstitial tissue was conspicuous and the extension of the internal duct was poor. There was no thinning of and/or unclear mucosal lamella which is typical signs of a hydrosalpinx. It suggests that the right adnexa were swollen simply due to blood stasis. We determined that this was a case of “the torsion of normal adnexa.”

DISCUSSION

Torsion of adnexa may occur in any woman, from *in utero* to postmenopausal, but it is most common in women of reproductive age. Smorgick *et al.* in their study reported that the most frequent cause is ovarian cysts (including simple cysts, dermoid cysts, corpus luteum cysts, and benign epithelial tumor) which account for 45.8%, followed by paraovarian cysts (33.3%) in postmenarchal women. Torsion of normal adnexa accounts for only 16.7% of cases in postmenarchal women. In contrast in premenarchal girls, the most frequent diagnosis of the cause of adnexal torsion is “torsion of normal adnexa” (35%), followed by simple cysts (30%), dermoid cysts (25%), and paraovarian cysts/malignant ovarian tumors.^[2]

Melcer *et al.* in their study reported that the presence of a multicystic ovary caused by ovulation induction treatment was found in women of reproductive age (20 years to menopause, in 5.5%) and in pregnancy (in 35.5%).^[3] Spitzer *et al.* also reported that assisted reproductive technology (ART) and ovarian stimulation with ovarian hyperstimulation syndrome (OHSS) increases ovarian torsion in pregnant women.^[4]

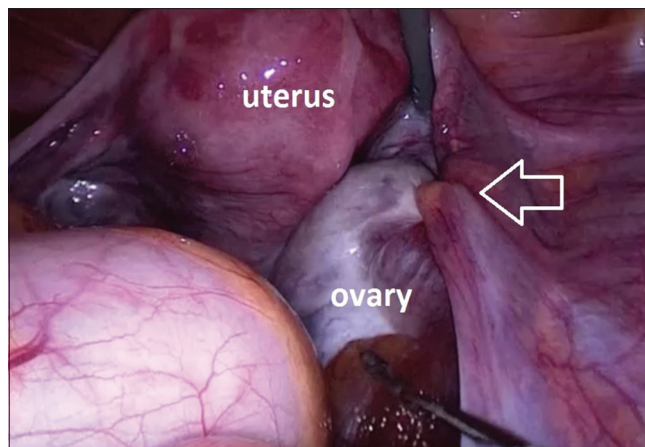


Figure 2: Findings of the laparotomy. Right adnexa was swollen and twisted

Tanaka *et al.* reported a case of torsion of the normal ovary in the postpartum period. They proposed that a possible reason for the postpartum normal adnexal torsion is the rapid anatomical changes in the pelvis, accompanied by the involution of the uterus while the utero-ovarian ligament remains disproportionately stretched. This allows the normal ovary increased room to move and twist.^[5]

We encountered a very rare case of torsion of normal adnexa in a 31-year-old woman, who was of reproductive age. To the best of our knowledge, the torsion of normal adnexa in a postmenarchal woman, one who is not postpartum, who has not received ART nor OHSS, has not been previously reported. The etiology of torsion of the normal adnexa is also not well defined. In the pediatric population, several authors proposed reasons such as the uterus is relatively small and the utero-ovarian ligaments are disproportionately long, or abrupt changes in intra-abdominal pressure with vomiting and coughing, adnexal venous congestion due to perimenarchal hormone activity, and sudden movement.^[6,7] We propose a new hypothesis: her torsion episode occurred in the proliferative phase 2 weeks after the last menstruation, and hence, a large follicle may have made her ovary temporarily enlarged and therefore easily twisted. Sexual intercourse could have also promoted the possibility of torsion, but this could not be confirmed.

The symptoms of normal adnexal torsion are almost identical to that of torsion with the adnexal tumor. Pansky *et al.* reported a study that compared normal adnexa to pathologic adnexa in postmenarchal women. In that study, abdominal pain was the most prevalent symptom, followed by nausea and vomiting, and by subfebrile range fever in both groups. The prevalence of an elevated WBC count was also common. There was no significant difference in previous surgery between the two groups.^[1] Melcer *et al.* reported that the torsion occurred slightly more frequently on the right side (53%–70%), and this tendency is similar to torsion of normal adnexa.^[3]

On the other hand, the torsion recurrence rate of normal adnexa is much higher than that of pathologic adnexa within

2 or 3 years after the operations. In some literature, the torsion recurrence of normal adnexa happens slightly more frequently on the ipsilateral side.^[1,2] There does not appear to be a significant difference in recurrent rates among the patients of different age groups.^[2,3]

Pansky *et al.* also reported that torsion recurrence rates depend on initial surgical management in the cases of pathologic adnexal torsion. The recurrence rates were reported as 28.6% in cases with only detorsion, 12.5% in cases with cyst aspiration, and 5.3% in cases with pathology resection.^[1] We can imagine easily that normal adnexal torsion recurs more frequently than pathologic adnexal torsion because we can only perform detorsion in the initial operation. However, it is difficult to foresee the recurrence so that there is no consensus about how long patients with normal adnexal torsion should be followed after operations. If the woman who experienced normal adnexal torsion visits the hospital with her abdominal pain, we should take a recurrence into consideration.

Adnexal torsion accounts for 3% of gynecologic surgical emergencies,^[5] but this is sometimes underestimated. Excessive conservative management can cause ovarian necrosis. Kruger and Heller reported that only fever was significantly common in the patients with adnexal necrosis,^[8] and Taskin *et al.* reported that ovarian function in rats with torsion for three cycles would be lost if the time of torsion lasted longer than 36 h.^[9] However, in cases of normal adnexal torsions with hemorrhagic necrosis, Chen *et al.* reported that the ischemic duration lasted from 16 to 288 h.^[10] Whether necrosis occurs may depend on not only on time after symptom onset but also how the extent the adnexa is twisted.

In this case, the time from the symptom onset to the operation was 68 h, but the torsion was only 360° hence that there was no finding of necrosis in her specimen. Her symptom was only abdominal pain, without fever or leukocytosis. The less severe symptoms may be associated with less ovarian damage, but it should be noted that the abdominal pain may sometimes become less severe when organ ischemia is established.

We experienced a very rare case of torsion of normal adnexa in a postmenarchal woman. We should recognize normal adnexal torsion as a cause of acute abdominal pain even if she is of reproductive age and treat it accordingly to avoid loss of ovarian functions.

In such case when the diagnosis is uncertain, an exploratory laparotomy is very effective. In particular, diagnostic laparoscopy is minimally invasive. We can see inside the abdomen at high magnification, stop any bleeding, untwist

the twisted organ, or excise it as required. Gynecological patients are often young, and small scars are cosmetically more appealing.

Acknowledgments

Thank you very much to Masumi Takeda for giving me a chance to make a case report. Also thanks to Ai Miyoshi for editing and advices for this paper.

Declaration of patient consent

The authors certify that they have obtained all appropriate patient consent forms. In the form the patient(s) has/have given his/her/their consent for his/her/their images and other clinical information to be reported in the journal. The patients understand that their names and initials will not be published and due efforts will be made to conceal their identity, but anonymity cannot be guaranteed.

Financial support and sponsorship

Nil.

Conflicts of interest

The authors have no conflicts of interest relevant to this article.

REFERENCES

1. Pansky M, Smorgick N, Herman A, Schneider D, Halperin R. Torsion of normal adnexa in postmenarchal women and risk of recurrence. *Obstet Gynecol* 2007;109:355-9.
2. Smorgick N, Melcer Y, Sarig-Meth T, Maymon R, Vaknin Z, Pansky M, *et al.* High risk of recurrent torsion in premenarchal girls with torsion of normal adnexa. *Fertil Steril* 2016;105:1561-5.e3.
3. Melcer Y, Sarig-Meth T, Maymon R, Pansky M, Vaknin Z, Smorgick N, *et al.* Similar but different: A Comparison of adnexal torsion in pediatric, adolescent, and pregnant and reproductive-age women. *J Womens Health (Larchmt)* 2016;25:391-6.
4. Spitzer D, Wirleitner B, Steiner H, Zech NH. Adnexal torsion in pregnancy after assisted reproduction-case study and review of the literature. *Geburtshilfe Frauenheilkd* 2012;72:716-20.
5. Tanaka Y, Koyama S, Shiki Y. Torsion of a normal ovary during the early postpartum period. *CRSLS MIS Case Reports from SLS*. [Doi: 10.4293/CRSLS.2013.00250].
6. Kokoska ER, Keller MS, Weber TR. Acute ovarian torsion in children. *Am J Surg* 2000;180:462-5.
7. Mordehai J, Mares AJ, Barki Y, Finaly R, Meizner I. Torsion of uterine adnexa in neonates and children: A report of 20 cases. *J Pediatr Surg* 1991;26:1195-9.
8. Kruger E, Heller DS. Adnexal torsion. A clinicopathologic review of 31 cases. *J Reprod Med* 1999;44:71-5.
9. Taskin O, Birincioglu M, Aydin A, Buhur A, Burak F, Yilmaz I, *et al.* The effects of twisted ischaemic adnexa managed by detorsion on ovarian viability and histology: An ischaemia-reperfusion rodent model. *Hum Reprod* 1998;13:2823-7.
10. Chen M, Chen CD, Yang YS. Torsion of the previously normal uterine adnexa. Evaluation of the correlation between the pathological changes and the clinical characteristics. *Acta Obstet Gynecol Scand* 2001;80:58-61.