





Case Report

Squamous cell and urothelial carcinomas in an ileal neobladder

Takeru Fujimoto,¹  Hiromasa Sakamoto,¹  Takaki Sakurai,²  Kasumi Kanai,¹ Kazuto Imai¹  and Teruyoshi Aoyama¹

Departments of ¹Urology, and ²Diagnostic Pathology, Kansai Electric Power Hospital, Osaka, Japan

Abbreviations & Acronyms

CK = cytokeratin
 CT = computed tomography
 GATA3 = GATA-binding protein 3
 IHC = immunohistochemical
 SCC = squamous cell carcinoma
 TURBT = transurethral resection of a bladder tumor
 UC = urothelial carcinoma

Correspondence: Hiromasa Sakamoto M.D., Ph.D., Department of Urology, Kansai Electric Power Hospital, 2-1-7 Fukushima, Fukushima-ku, Osaka 553-0003, Japan. Email: sakamoto.hiromasa@c3.kepco.co.jp

How to cite this article: Fujimoto T, Sakamoto H, Sakurai T *et al.* Squamous cell and urothelial carcinomas in an ileal neobladder. *IJU Case Rep.* 2022; 5: 141–144.

This is an open access article under the terms of the Creative Commons Attribution-NonCommercial-NoDerivs License, which permits use and distribution in any medium, provided the original work is properly cited, the use is non-commercial and no modifications or adaptations are made.

Received 7 October 2021; accepted 21 December 2021.

Online publication 2 February 2022

Introduction: In cases of ileal neobladder following radical cystectomy for the treatment of bladder cancer, tumor development in the isolated gut segment is extremely rare. Herein, we report a case of squamous cell and urothelial carcinomas in the ileal neobladder 23 years after radical cystectomy.

Case presentation: A 71-year-old man was referred to our hospital for further examination of a solitary tumor in an ileal neobladder. At the age of 48 years, he underwent radical cystectomy with ileal neobladder reconstruction. Transurethral resection of the bladder tumor was performed, and histopathological findings showed squamous cell carcinoma with high-grade urothelial carcinoma.

Conclusion: To our knowledge, this is the first report of squamous cell and urothelial carcinomas in an ileal neobladder. While secondary tumor development in an ileal neobladder is rare, it is a cause for concern as a late postoperative adverse event. Therefore, long-term follow-ups are recommended.

Key words: ileal neobladder, squamous cell carcinoma, urothelial carcinoma.

Keynote message

We report a rare case of squamous cell carcinoma and urothelial carcinoma in an ileal neobladder 23 years after radical cystectomy. Long-term follow-ups are recommended considering tumor development as a late postoperative adverse event.

Introduction

Radical cystectomy is the standard treatment for muscle-invasive bladder cancer. For the last several decades, the orthotopic ileal neobladder has become a popular method of continent urinary diversion following radical cystectomy.¹ In patients with an ileal neobladder, tumor development in the isolated gut segment without the involvement of other urinary tracts is rare.² Furthermore, adenocarcinoma is the major histologic type among secondary tumors after urinary diversion using isolated gut, whereas SCC and UC are rare.³

We present an extremely rare case of SCC and UC in an ileal neobladder 23 years after radical cystectomy.

Case report

A 48-year-old man underwent radical cystectomy with Hautmann ileal neobladder reconstruction for the treatment of muscle-invasive bladder cancer.⁴ Histopathological findings showed UC, high-grade, and pT1. He had continued self-catheterization due to excessive postvoid residual urine for 13 years after the operation. Urine cytology had been consistently negative, and no finding suggestive of recurrence on CT was noted. After 23 years, the patient reported gross hematuria. Urinary examination revealed hematuria with pyuria; urine cytology was negative. CT revealed a solitary mass at the posterior wall of the neobladder (Fig. 1) and enlarged mesenteric and presacral lymph nodes. No other metastases were observed and the upper urinary tract was normal. Cystoscopy revealed a papillary broad-based tumor at the

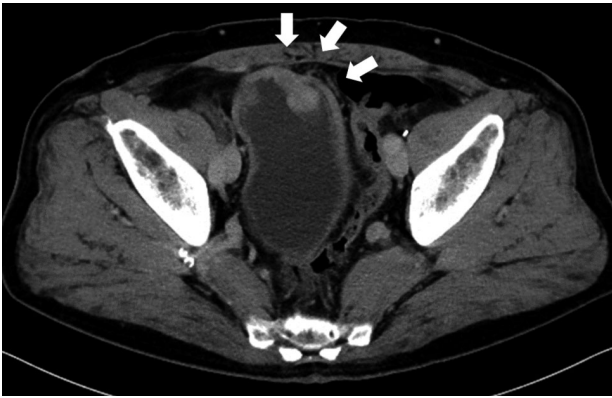


Fig. 1 Computed tomography scan showing a solitary mass at the posterior wall of neobladder (white arrow).

posterior wall of the neobladder which was distant from the new bilateral ureteral orifices (Fig. 2). No tumor was detected in the urethra.

TURBT was performed and histopathological findings of the resected specimens showed SCC (Fig. 3a) with high-grade UC (Fig. 3b) along with muscularis propria invasion at some sites. The infiltration of inflammatory cells was identified in the background ileal mucosa and morphological changes, such as the urothelium, were observed in the mucosa which was strongly inflamed near the tumor (Fig. 3c). In IHC staining, GATA3 was negative in the tumor but positive in the background mucosa with morphological changes like the urothelium (Fig. 3d). The tumor was positive for CK7 expression and negative for CK20 expression in both SCC (Fig. 3e,f) and UC (Fig. 3g,h).

Based on the clinical diagnosis of SCC and UC in an ileal neobladder with mesenteric and presacral lymph node

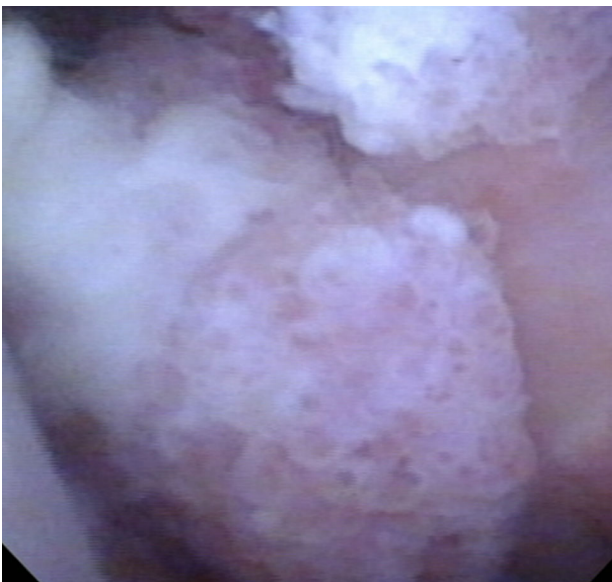

Fig. 2 Cystoscopy revealed a papillary tumor at the posterior wall of neobladder.

metastases, chemotherapy with gemcitabine and cisplatin was initiated; however, it was discontinued after one cycle due to adverse events. Pembrolizumab was administered as a second-line treatment. Lymph node metastases remained stable after six cycles of pembrolizumab; however, local recurrence inside the neobladder was identified. TURBT was performed, and histopathological findings showed viable SCC with high-grade UC.

Discussion

We report a rare case of SCC and UC in an ileal neobladder 23 years after radical cystectomy. To our knowledge, this is the first report of SCC and UC in a single tumor in an ileal neobladder.

Kälble et al. reported a direct comparison of the secondary tumor risk in different forms of urinary diversions. They indicated that ureterosigmoidostomies and cystoplasties were associated a significantly increased tumor risk, whereas ileal neobladder or conduit seemed to have a lower risk than ileocolonic neobladders or other forms of urinary diversion. They estimated that secondary tumor development in an ileal neobladder is extremely rare, at <0.1%.⁵ However, only a few patients with ileal neobladder have reached 20 years of follow-up. A plausible latency period for secondary tumor development in an ileal neobladder remains unclear; therefore, it cannot not determine how long a follow-up period would be sufficient for cancer surveillance. Hence, long-term follow-up may be recommended considering the possibility of secondary tumor development, even in the case of a patient who underwent radical cystectomy and orthotopic ileal neobladder. In the present case, histopathological findings of TURBT before cystectomy showed the diffused submucosal invasion, which was the reason for performing cystectomy owing to the high risk of progression. The final pathological stage after cystectomy was also pT1; this might be why long-term follow-up had been possible and considered as a limitation.

The mechanism of carcinogenesis in the mucosa of an ileal neobladder is unclear. There might be two mechanisms for the development of SCC: differentiated from UC or originating from the intestinal mucosa. UC is known to exhibit several histological variants. Squamous differentiation is the most common variant of UC, occurring in as many as 40% of cases of invasive UC.⁶ Primary small intestinal malignancies are rare, with only 1.5–2% of gastrointestinal tumors.⁷ Among them, primary SCC of the small intestine is extremely rare.⁸ In an analysis of 1,312 consecutive pathologic specimens of the small intestine, only three cases (0.2%) of primary SCC were found.⁹ SCC in the ileal neobladder is extremely rare, and only two case reports are available.^{10,11} Hong et al. speculated that SCC of the intestinal mucosa originates from squamous metaplasia in the presence of chronic inflammation.¹¹ In the present case, chronic inflammation due to urinary tract infection was implicated; however, squamous metaplasia was not pathologically identified. IHC revealed a CK7+/CK20- pattern in the tumor. CK7 and CK20 are both generally positive in UC and negative in SCC.^{12,13} CK7 expression is preserved in high-grade UC including squamous differentiation,¹⁴ whereas CK20

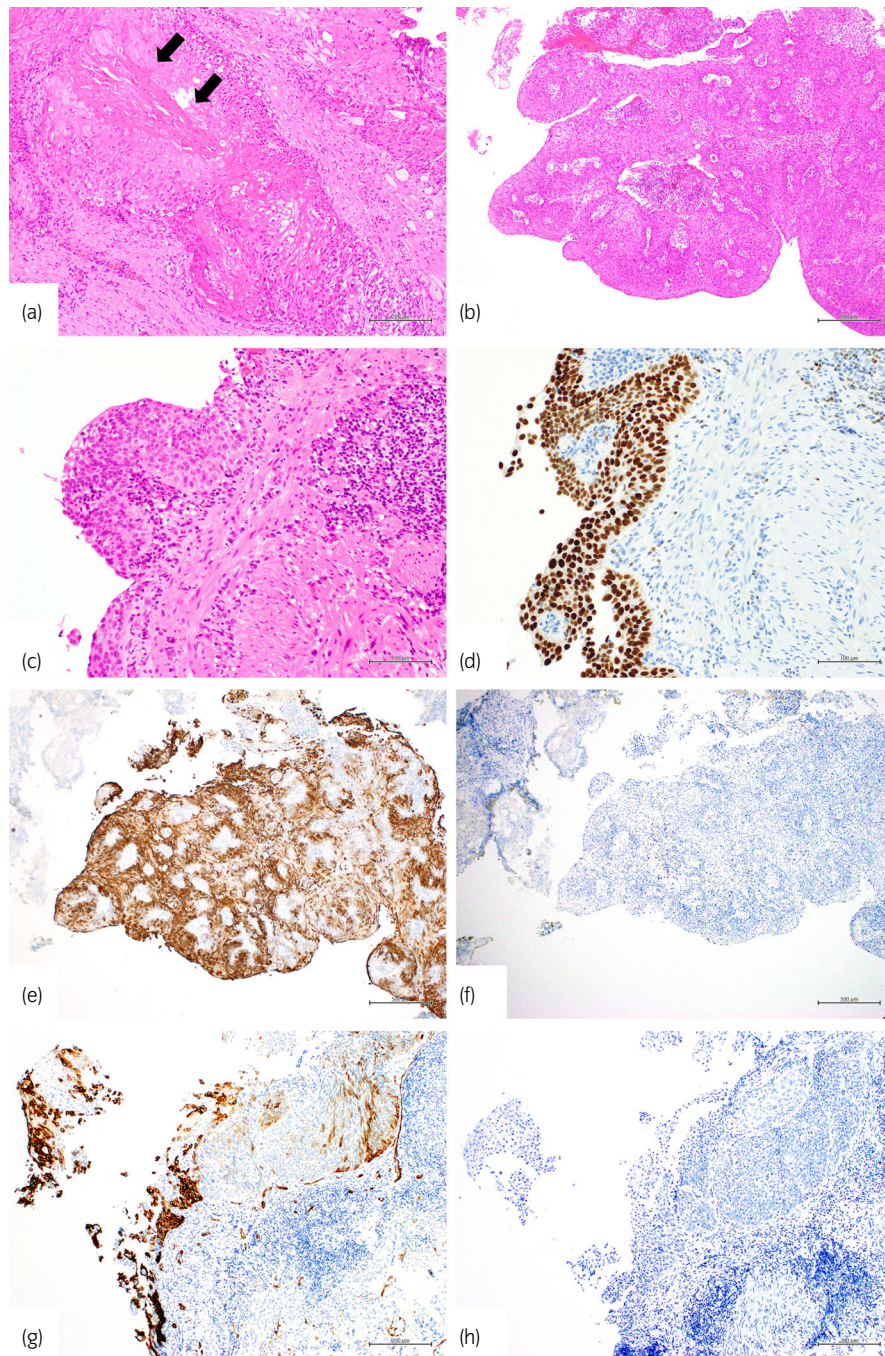


Fig. 3 Histopathological findings of tumor specimens showing SCC and UC. Hematoxylin and eosin staining with high and low magnification. (a) The tumor mainly consists of SCC with keratinization (black arrow), (b) partly of UC with papillary structure and no keratinization. (c) Morphological change like urothelium is seen in the strongly inflamed background mucosa near the tumor, (d) areas positive for IHC staining of GATA3. SCC is (e) positive for CK7 expression and (f) negative for CK20 expression. UC is also (g) positive for CK7 expression and (h) negative for CK20 expression. Scale bar: (a) 200 μm , (b) 500 μm , (c) 100 μm , (d) 100 μm , (e) 500 μm , (f) 500 μm , (g) 500 μm , and (h) 500 μm .

expression is attenuated.^{13,14} These results suggest that SCC were more likely to be differentiated from UC than did de novo.

Regarding the mechanism of UC development in an ileal neobladder, two hypotheses have been proposed: direct invasion and implantation.² Herawi et al. suggested that UC had the ability to seed and implant even on nonurothelial surfaces.¹⁵ In the present case, the tumor was distant from the

urethra and new bilateral ureteral orifices of the anastomoses. IHC staining revealed GATA3 positive lesion in the background mucosa with morphological changes such as the urothelium. These results suggest that UC could be implanted into the intestinal mucosa rather than directly invading it. GATA3, also known as GATA-binding protein 3 and trans-acting T-cell-specific transcription factor, has recently been recognized as an urothelial-associated IHC marker.¹⁶ GATA3

is present in the urothelium or in most UC cases; however, it is absent in poorly differentiated UC or UC with squamous differentiation.¹⁷ In addition, GATA3 is negative in the normal intestinal mucosa.¹⁷ The usefulness of GATA3 in the diagnosis of UC in an ileal neobladder has not been reported. Our results suggest that high-grade UC could have originated via implantation into the intestinal mucosa of the neobladder and then differentiated into SCC.

Conclusion

We encountered an extremely rare case of SCC and UC in an ileal neobladder. Although secondary tumor development in an ileal neobladder is rare, it is one of the postoperative late adverse events. Since early identification of this rare malignancy is desirable, long-term follow-ups may be essential in cases of ileal neobladder following radical cystectomy.

Acknowledgments

The authors would like to thank Editage (www.editage.com) for English language editing.

Author Contributions

Takeru Fujimoto: Conceptualization; Data curation; Writing – original draft. Hiromasa Sakamoto: Conceptualization; Writing – original draft. Takaki Sakurai: Writing – review & editing. Kasumi Kanai: Data curation. Kazuto Imai: Data curation. Teruyoshi Aoyama: Writing – review & editing.

Conflict of interest

The authors declare no conflict of interest.

Approval of the research protocol by an institutional reviewer board

The protocol for this research project has been approved by our institutional reviewer board. Approval No. 21-047.

Informed consent

Informed consent was obtained from the patient for publication of this case report.

Registry and registration no. of the study/trial

Not applicable.

References

- Hautmann RE. Urinary diversion: ileal conduit to neobladder. *J. Urol.* 2003; **169**: 834–42.
- Doshi CP, Barkan GA, Quek ML. Urothelial carcinoma recurrence in an orthotopic neobladder without urethral or upper urinary tract involvement. *Case Rep. Urol.* 2019; **2019**: 8458706.
- Austen M, Kalble T. Secondary malignancies in different forms of urinary diversion using isolated gut. *J. Urol.* 2004; **172**: 831–8.
- Hautmann RE. Surgery illustrated - surgical atlas ileal neobladder. *BJU Int.* 2010; **105**: 1024–35.
- Kälble T, Hofmann I, Riedmiller H, Vergo D. Tumor growth in urinary diversion: a multicenter analysis. *Eur. Urol.* 2011; **60**: 1081–6.
- Kim SP, Frank I, Cheville JC *et al.* The impact of squamous and glandular differentiation on survival after radical cystectomy for urothelial carcinoma. *J. Urol.* 2012; **188**: 405–9.
- Hatzaras I, Palesty JA, Abir F *et al.* Small-bowel tumors: epidemiologic and clinical characteristics of 1260 cases from the connecticut tumor registry. *Arch. Surg.* 2007; **142**: 229–35.
- Wang F-D, Wang Z-W, Xue H-D *et al.* Primary squamous cell carcinoma of the small intestine: pathogenesis and clinical features. *Chin. Med. J.* 2016; **129**: 2131–3.
- Terada T. Malignant tumors of the small intestine: a histopathologic study of 41 cases among 1,312 consecutive specimens of small intestine. *Int. J. Clin. Exp. Pathol.* 2012; **5**: 203–9.
- Zang Z, Wang J, Zuo Y, Hu Y, Shi Y, Xu H. Squamous cell carcinoma in an ileal neobladder: a case report and review of the literature. *Chin. Med. J.* 2001; **114**: 1105–6.
- Hong R, Choi D-Y, Shin D-E, Moon H-Y, Kee K-H. Squamous cell carcinoma of an ileal neobladder – a case report. *The Korean. J. Pathol.* 2009; **43**.
- Chu P, Wu E, Weiss LM. Cytokeratin 7 and cytokeratin 20 expression in epithelial neoplasms: a survey of 435 cases. *Mod. Pathol.* 2000; **13**: 962–72.
- Hammam O, Wishahi M, Khalil H *et al.* Expression of cytokeratin 7, 20, 14 in urothelial carcinoma and squamous cell carcinoma of the Egyptian urinary bladder cancer. *J. Egypt. Soc. Parasitol.* 2014; **44**: 733–40.
- Paner GP, Annaiah C, Gulmann C *et al.* Immunohistochemical evaluation of novel and traditional markers associated with urothelial differentiation in a spectrum of variants of urothelial carcinoma of the urinary bladder. *Hum. Pathol.* 2014; **45**: 1473–82.
- Herawi M, Leppert JT, Thomas GV, De Kernion JB, Epstein JI. Implants of noninvasive papillary urothelial carcinoma in peritoneum and ileocolonic neobladder: support for “seed and soil” hypothesis of bladder recurrence. *Urology* 2006; **67**: 746–50.
- Agarwal H, Babu S, Rana C *et al.* Diagnostic utility of GATA3 immunohistochemical expression in urothelial carcinoma. *Indian J. Pathol. Microbiol.* 2019; **62**: 244–50.
- Miettinen M, McCue PA, Sarlomo-Rikala M *et al.* GATA3: a multispecific but potentially useful marker in surgical pathology: a systematic analysis of 2500 epithelial and nonepithelial tumors. *Am. J. Surg. Pathol.* 2014; **38**: 13–22.