

Novel Insights into the Pathogenesis of Hirschsprung's-associated Enterocolitis

Chun-Lei Jiao, Xu-Yong Chen, Jie-Xiong Feng

Department of Pediatric Surgery, Tongji Hospital, Huazhong University of Science and Technology, Wuhan, Hubei 430000, China

Abstract

Objective: To systematically summary the updated results about the pathogenesis of Hirschsprung's-associated enterocolitis (HAEC). Besides, we discussed the research key and direction based on these results.

Data Sources: Our data cited in this review were obtained mainly from PubMed from 1975 to 2015, with keywords "Hirschsprung enterocolitis", "Hirschsprung's enterocolitis", "Hirschsprung's-associated enterocolitis", "Hirschsprung-associated enterocolitis", "HAEC", and "EC".

Study Selection: Articles regarding the pathogenesis of HAEC were selected, and the articles mainly regarding the diagnosis, surgical approach, treatment, and follow-up were excluded.

Results: Several factors, mainly including mucus barrier, intestinal microbiota, and immune function, as well as some other factors such as genetic variations and surgical reasons, have been found to be related to the pathogenesis of HAEC. Changed quantity and barrier property of mucus, different composition of microbiota, and an abnormal immune state work together or separately trigger HAEC.

Conclusions: The maintenance of intestinal homeostasis is due to a well cooperation of microbiota, mucus barrier, and immune system. If any part presents abnormal, intestinal homeostasis will be broken. Meanwhile, for patients with Hirschsprung's disease or HAEC, dysfunction of these parts has been found. Thus, the happening of HAEC may be mainly attributed to the disorders of intestinal microbiota, mucus barrier, and immune system.

Key words: Enterocolitis; Hirschsprung's-associated Enterocolitis; Hirschsprung's Disease; Pathogenesis

INTRODUCTION

Hirschsprung's disease (HSCR) was first described by Harald Hirschsprung a century ago.^[1] The incidence of HSCR is 1/5000 in live born infants. The basic pathological feature of HSCR is the absence of ganglion cells in the distal bowel, which results in the functional obstruction manifesting severe chronic constipation and abdominal distention.^[2,3]

The most common and most severe complication of HSCR is Hirschsprung's-associated enterocolitis (HAEC). In recent years, one-stage pull-through surgery has been commonly performed to deal with HSCR, and the methods have developed from laparotomy to minimally invasive surgery such as transanal pull-through operations and laparoscopy-assisted operations. However for children in a poor condition such as total colonic aganglionosis, low birth weight, and severe HAEC, a multistage surgery is more conservative.^[4-9] But HAEC happens despite the surgical methods. Patients with HAEC usually manifest abdominal

distention, diarrhea, fever, and even shock. Without timely and effective treatment, HAEC may cause the death of children with HSCR.^[3,10]

Bill *et al.*^[11] gave the first detailed description in 1962. Many reports and studies have been published up to now. Due to the different diagnostic criteria, the morbidity of HAEC is from 17% to 50%, with an average of 25%.^[12] It is associated with the types and other complications. HAEC occurs more frequently in the long segment type. Moreover, the total colonic type has a morbidity up to 55.4%.^[13] Down

Address for correspondence: Dr. Jie-Xiong Feng,

Department of Pediatric Surgery, Tongji Hospital, Huazhong University of Science and Technology, No. 1095, Jiefang Avenue, Wuhan, Hubei 430000, China
E-Mail: fengjixiong@126.com

This is an open access article distributed under the terms of the Creative Commons Attribution-NonCommercial-ShareAlike 3.0 License, which allows others to remix, tweak, and build upon the work non-commercially, as long as the author is credited and the new creations are licensed under the identical terms.

For reprints contact: reprints@medknow.com

© 2016 Chinese Medical Journal | Produced by Wolters Kluwer - Medknow

Received: 16-01-2016 **Edited by:** Xin Chen

How to cite this article: Jiao CL, Chen XY, Feng JX. Novel Insights into the Pathogenesis of Hirschsprung's-associated Enterocolitis. *Chin Med J* 2016;129:1491-7.

Access this article online

Quick Response Code:



Website:
www.cmj.org

DOI:
10.4103/0366-6999.183433

syndrome (DS) is the most frequent congenital disease that accompanies HSCR. HAEC presents a higher rate with the coexistence of HSCR and DS.^[14] Patients who have underwent multistage surgery and laparotomy demonstrated a higher morbidity.^[9,15]

Researches should not be limited to recognize clinical manifestations and take the treatment which seems effective. The most important thing is to find out the pathogenesis of HAEC. Some differences were found among HAEC children, HSCR children without HAEC and normal controls, which may interpret the development of HAEC. However, results are not so satisfactory because of the fact that no conclusion can completely and clearly explain the pathogenesis of HAEC. Moreover, results are always contradictory. Mucus barrier, intestinal microbiota, and immune function are major factors that are related to the intestinal inflammation. In the present article, we gave a comprehensive description mainly from these three parts, in spite of the inconsistent results, to inspire readers to achieve more new theories about HAEC.

MUCUS BARRIER

On the surface of intestinal epithelia, mucins composed of highly glycosylated proteins constitute a protective mucus. Moreover in colon, mucus is composed of the outer layer and inner layer. The former is the habitat of intestinal microbiota and is essential to form the intestine microenvironment. The latter prevents the permeation of the microbiota to the deeper tissues. Mucus is renewed by mucins secreted by goblet cells for every few hours. Mucins in intestine are mainly secretory types MUC-2 and Muc5AC.^[16,17]

Mattar *et al.*^[18] collected stool samples from HSCR patients and found that MUC-2 was obviously lower in HSCR group, and interestingly, the expression of MUC-2 in HAEC group could not be detected. Thiagarajah *et al.*^[19] have studied mucins and goblet cells in HSCR patients and *Ednrb*^{-/-} mice (HSCR mice models). What was different to the study of Mattar *et al.*^[18] was that they detected no change of MUC-2, but a reduction of MUC-4 in the distal colon of HSCR patients, as well as in *Ednrb*^{-/-} mice. Besides, they found that in the distal colon of HSCR patients, although goblet cells got more, mucins inside goblet cells reduced. Furthermore, goblet cells of *Ednrb*^{-/-} mice showed differences in both aganglionic and ganglionic segments. Goblet cells of aganglionic segments were larger and more, while in the ganglionic segments they were found smaller and less. SAM-pointed domain-containing Ets-like factor (SPDEF) and Math1 factors which are relative to the differentiation of goblet cells increased. This might lead to the abnormal differentiation of goblet cells. Contradictorily, in the research of Aslam *et al.*,^[20] by histological staining, no difference was found between HSCR patients and the control. Besides, the expressions of MUC 1, 2, 3, 4, 5AC, 5B, 6, 7, and 8 in HSCR group were similar to those of control group. Besides, a study showed that radioactive mucin precursors [35S]-sulfate and [3H]-glucosamine,

which are turnover of mucin precursors, were reduced in HSCR patients in both aganglionic and ganglionic segments.^[21]

In earlier studies, researchers focused on neutral mucin type and sulfomucin type. Fujimoto^[22] found that neutral mucins and sulfomucins were both significantly reduced in the piebald lethal mouse model of HSCR. But Teitelbaum *et al.*^[23] detected an increase in neutral mucins and a decrease in sulfomucins. The increase in sulfomucins was also reported.^[24]

The abnormal composition of mucins will lead to the dysfunction of mucus barrier. As a consequence, bacteria translocation may happen and HAEC follows. These researches showed that mucins might be associated with HAEC, but there was no direct evidence between aganglionosis and mucins production.

Yildiz *et al.*^[25] performed a research to study the transport property of mucus barrier in *Ednrb*^{-/-} mice. The result showed that for passive particle transport, the distal colon, as well as the proximal colon, showed a significantly reduced transport rate. Furthermore, compared with the controls, the particle showed a more regular track and a shorter distance, which meant they were hindered. Moreover for active microbe transport, by real-time tracking, *Escherichia coli* transport showed a reduced rate in the proximal colon rather than in the distal colon. The abnormality of the proximal colon matched the fact that HAEC happened even after the definitive pull-through surgery.

INTESTINAL MICROBIOTA

Numerous symbionts and commensals, including bacteria, fungi, and virus, exist in human bowels. Most of these microbiota are bacteria, with 10^{11} – 10^{12} inhabiting in the large bowel and a smaller group, 10^5 – 10^9 in the small intestine. They play a vital role in maintaining the intestinal homeostasis and keeping normal immune function.^[26,27] The *Firmicutes* and *Bacteroidetes* are two phyla mainly existing in the gut. Resident microbiota is essential in the development of immune response.^[28] As described in many previous studies, plenty of diseases, such as ulcerative colitis, Crohn's disease (CD), functional gastrointestinal disorders, and colorectal cancer, are all relative to the unbalance of intestinal microbiota.^[29,30]

A concept “microbiota-gut-brain axis” emerges nowadays, which means that intestinal microbiota interact with the nervous system and have an impact on it. The interaction is bidirectional. The central and enteric nervous system (ENS) also communicate with intestinal microbiota by means of neural, endocrine, immune, and humoral links to influence their composition and behavior.^[31-34] According to this, we may speculate that aganglionosis will lead to an abnormal distribution of microbiota.

In recent years, with the development of technique, DNA sequencing is used more frequently in the analysis of

intestinal microbiota. In a multicenter study of Frykman *et al.*,^[35] not only bacteria but also fungus were different in HAEC children compared with HSCR children without HAEC. They found the modest reductions in *Firmicutes* and *Verrucomicrobia*, but the increases in *Bacteroidetes* and *Proteobacteria*. Varieties of fungi were obviously reduced. Specifically, *Candida* sp. was increased, but *Malassezia* and *Saccharomyces* sp. were reduced. Shen *et al.*^[36] indicated that *Bifidobacteria* were reduced in HAEC group compared with HSCR and control groups, and they also found that *Lactobacilli* in both HAEC and HSCR groups were markedly decreased compared to control group. Similarly, Pierre *et al.*^[37] found that for P21-24 *Ednrb*^{-/-} mice, a reduction of *Lactobacillus* was observed.

In order to study bacteria from different colonic segments, Yan *et al.*^[38] collected stool samples from proximal colons and distal colons during operations. HAEC group showed a greater diversity in the composition of bacteria. Furthermore, HAEC group had a greater variety in proximal segments than that in distal segments. But in HSCR group, bacteria in distal segments outnumbered that in proximal segments. In HSCR children, 46% *Bacteroidetes* and 21% *Proteobacteria* occupied the majority of Phylum. In contrast, in HAEC group, *Proteobacteria* occupied the largest portion with a proportion of 55%. Moreover *Firmicutes*, with a proportion of 18%, followed. Ward *et al.*^[39] studied the bacteria of aganglionic colon in *Ednrb*^{-/-} mice. They found that *Ednrb*^{-/-} mice had more *Bacteroidetes* and less *Firmicutes*. Genus and species also showed variations. Besides, the colon from postnatal day 7 (P7) *Ednrb*^{-/-} mice was dominated by coagulase-negative *Staphylococcus* species, which were rare in the control.

Wang *et al.*^[40] used oral probiotics, composed of *Bifidobacteria*, *Lactobacilli*, and *Enterococcus* as a precaution of HAEC. Results showed that the probiotics would not only reduce the morbidity of HAEC but also make it less severe. But a consensus has not been reached. In a prospective study of El-Sawaf *et al.*,^[41] they declared that the morbidity of HAEC between probiotics and placebo treating group was of no difference.

In some earlier studies, researchers tried to find relations between HAEC and *Clostridium difficile*. However, conclusions also seem to be contradictory. Some reported a significantly higher isolation rate of *C. difficile* of HAEC children.^[42] But contradictorily, others declared that no difference existed between HSCR children with diarrhea and those without diarrhea.^[43] A research declared that pseudomembranous colitis complicating HSCR caused by *C. difficile* had a mortality as high as around 50%.^[44]

Nutrition in intestine lumen may also play a role in microbiota composition. Demehri *et al.*^[45] found that fecal short-chain fatty acid (SCFA) changed in HAEC children. Compared to patients without HAEC, they showed a 4-fold decline in total SCFA concentration. SCFA is necessary for the

development of microbiota. They detected reduced acetate and increased butyrate in HAEC children. Moreover related to this, most of the butyrate-producing genera demonstrated a multifold expansion, while acetate-producing genera also showed this phenomenon. Decreased acetate production, or increased acetate absorption, or bacteria utilizing acetate for the production of butyrate might be responsible for this result. There was also a study suggesting that formate was abundant in *Ednrb*^{-/-} mice.^[39]

IMMUNE FUNCTION

A large compartment of immune cells resides in the intestine. Innate and adaptive immunity work together to eliminate pathogens including bacteria, fungi, viruses, and helminth and to maintain intestinal homeostasis. It mainly includes gut-associated lymphoid tissue, which is consisted of Peyer's patches, solitary follicles, aggregate follicles, and diffusely distributed lymphoid cells in the lamina propria of the gut where priming adaptive immune cells reside. Besides, macrophages, dendritic cells, innate lymphoid cells, paneth cells found only in the small intestine, goblet cells and intestinal epithelial cells all contribute to intestinal innate immunity and then adaptive immunity.^[46-48]

Gut innervation takes part in the development of the intestinal immune system. Evidence of inflammatory neural reflex has been found. Parasympathetic nervous system can modulate lymphoid tissues and immune cells in intestine. Both innate and adaptive immune cells express receptors for neurotransmitters. Abnormality of parasympathetic nervous system has been found in CD patients and Dextran sodium sulfate(DSS)/2,4,6-trinitrobenzene sulfonic acid(TNBS)-treated mice.^[49,50] Besides, ENS neuropeptide can influence intestinal immunity.^[51,52] Abnormality of ENS and parasympathetic nervous system in HSCR may play a role in the dysfunction of intestinal immunity.

Researchers have demonstrated the defect of adaptive immunity in HSCR. Cheng *et al.*^[53] found that small spleen phenotype and splenic lymphopenia existed in *Ednrb*^{-/-} mice, which was characterized by 5- to 20-fold reductions of total spleen cells, CD19⁺ mature B-cells, CD4⁺ T-cells, and CD8⁺ T-cells. Besides, B-cells showed a relative reduction compared with T-cells. Moreover, there was a strong inverse correlation between histopathological enterocolitis (EC) scores and total spleen cells, as well as B-cells. Afterward, Frykman *et al.*^[54] explained why the immune defect appeared. Their further research showed that severe HAEC led to thymic involution, splenic lymphopenia, and suppression of B lymphopoiesis. This was just like the manifestations in neonates who developed sepsis. Elevated glucocorticoid might be the mediator. This supports the fact that HSCR patients who have not been timely treated are always in a severe situation. They also illuminated that lymphopenia was related to colonic aganglionosis, while it had no relationship with the *ednrb* gene.^[54] However, Dang *et al.*^[55] found that genetic background was related to

different immune state. Abnormal splenic microarchitecture with lymphopenia was observed in AGH-Ednrb^{-/-} rats, but not detected in LE and F344 genetic background Ednrb^{-/-} rats. They speculated that the development of T-cells and B-cells might be relative to endothelin signaling pathway and be influenced by the genetic background. Gosain *et al.*^[56] also found immune defect in Ednrb^{-/-} mice. Mucosal immune function beyond aganglionic colon declined before histological change emerged. IgM⁺ IgD^{hi} (Mature) B lymphocytes related to the production of secretory IgA decreased in Peyer's patches. They also studied the spleen of Ednrb^{-/-} mice and had the same conclusion that B-cells decreased. However, they found mature B-cells increased, which was opposite to the study of Cheng *et al.*^[53] In contrast to these studies, Turnock *et al.*^[57] found that T-cells, B-cells, and immunoglobulin-containing cells in intestine mucosa showed no difference in HAEC children.

Secretory IgA is of vital importance for intestinal immunity. Moore *et al.*^[58] detected an obvious increase of IgM and IgG, without an increase of IgA in aganglionic and transitional segments. Imamura *et al.*^[59] demonstrated that IgA, IgM, and J chain containing plasma cells, CD68 positive monocyte/macrophages, and CD45RO positive leukocytes increased in HAEC children. Secretory component in the intestine lumen reduced, which reflected a reduction of secretory IgA. This might be due to the failure of transfer of IgA to intestinal lumen. In addition, NK cells in ganglionic segments increased but showed no difference in aganglionic segments. In the piebald lethal mouse model of HSCR, immune cells and immunoglobulin-producing cells, especially IgA-containing cells, were significantly increased in acute illness group compared with the relatively chronic illness group. Furthermore in the latter group, IgA-containing cells are distributed mainly in the deep layer of lamina propria.^[22,60] Wilson-Storey *et al.*^[61,62] discovered a decrease of secretory IgA and these patients were with an obvious deficiency of the transfer of secretory IgA. Besides, they found a deficiency of white blood cells in HSCR children.

The immunity of small intestine has been studied as well. Pierre *et al.*^[37] demonstrated that at the late time point (P22) of Ednrb^{-/-} mice, the expression and activity of secretory phospholipase A2, an antimicrobial protein secreted by Paneth cells in small intestine, were reduced. The dysfunction of innate immunity in the small intestine may explain the reason why HAEC happens beyond the aganglionic segments and even after the definitive surgery. These findings are not restricted to the aganglionic segments, which mean that even after the resection of the diseased colon, abnormal intestinal immunity is still there to cause HAEC.

OBSTRUCTION OF THE DISTAL AGANGLIONIC COLON

The basic manifestation of HSCR is the functional obstruction in the distal colon, which leads to fecal stasis and then the reproduction of pathogens. As a consequence, mucosa is invaded and HAEC even systematic inflammation

happens.^[3,63] Caniano *et al.*^[64] found that in the piebald lethal mouse model of HSCR, obstruction of the distal colon resulted in a loss of colonic mucosal barrier integrity, allowing intraluminal pathogens to move through the mucosal surface and enter the circulation. This contributed to the happening of HAEC before operations.

GENETIC VARIATIONS

Lui *et al.*^[65] detected that expressions of caudal type homeobox gene-1 and -2 (*CDX-1* and *CDX-2*), which control the proliferation and differentiation of mucosal cells, were reduced in children with HAEC. Moore *et al.*^[66] showed that the ITGB2 (CD18) immunomodulation-related gene coding for the β -subunit of leukocyte adhesion molecule lymphocyte function-associated antigen 1 was found with genetic variations in those patients presented with HAEC symptoms. In addition, others researched the most important susceptibility gene for Crohn's EC, NOD2. But they illustrated that HAEC was independent of it.^[67]

SURGICAL FACTORS

Hackam *et al.*^[68] referred that postoperation HAEC were related to many risk factors, such as anastomotic stricture or leak, and postoperative intestinal obstructions. But later Estevão-Costa *et al.*^[69] claimed that these risk factors were not common after the surgery, which meant that they should not be responsible for postoperation HAEC. What led to the high morbidity of postoperation HAEC was the existence of intestinal neuronal malformations in reserved intestines postoperations. Subsequently, HAEC occurred due to intestinal stasis. Other studies stood for the latter point. Malformations in the reserved segment are mainly type B intestinal neuronal dysplasia and hypoganglionosis.^[70,71]

OTHER FACTORS

A research of Dembowski *et al.*^[72] found that the reduction of albumin existed both before and after HAEC in Ednrb^{-/-} rats. In the piebald lethal mouse model of HSCR, researchers also found that albumin declined gradually at the time around P50.^[64] Lloyd-Still and Demers^[73] used cholestyramine to treat an infant with HAEC and found it effective. Cholestyramine caused a significant reduction of prostaglandin E (PGE) in the colostomy drainage-fluid. According to this, they speculated PGE activity, enterotoxin, and bile acid malabsorption might contribute to the development of HAEC. A study showed that neuroendocrine cells (NE cells) cells of aganglionic segments were significantly higher than that of ganglionic segments. But in the latter, NE cells in patients with HAEC showed a lower level than patients without HAEC.^[74,75]

CONCLUSION

HAEC, as a common and severe complication of HSCR, must be understood thoroughly. Mucus barrier, intestinal microbiota, and immune function are major factors that

are related to intestinal inflammation. In HAEC children, abnormal mucus barrier cannot prevent the permeation of bacteria and help to build a normal microenvironment. In addition, the immune system shows a defect to some extent. It is worthy of note that not only an insufficient innate immune system but also a dysfunctional adaptive immune system exist in the intestine of HSCR. Then, increased pathogenic microorganism whose production is allowed as a result of alterations of intestinal microbiota will enter the deeper layer of intestine and even the circulation system. And thus, local and systematic inflammation happens. Maybe interaction of mucus barrier, microbiota, immune function, and abnormal ENS is the main trigger of HAEC [Figure 1].

However, the inconsistency of the results and the uncertainty of treatment due to these theories still confuse doctors and researchers. The present viewpoints are still far from impeccable. Due to the lack of clear explanations for the whole process of HAEC, the known pathogenesis of HAEC may be only a tip of the iceberg. The direct evidence of the effect of ENS malformation on mucus barrier, microbiota, and immune system should be checked out in HAEC. The role of probiotics on microbiota need to be studied in model animals to find whether it is effective in HAEC. Researches have demonstrated abnormalities in intestinal immune system. Furthermore, crosstalk between these immune cells should be studied. People also need to find the immune state in the environment of HAEC and its recover after HAEC. In the future, scientists should dig deeper in the areas of mucus barrier, microbiota, and immune function, or even a completely new field.

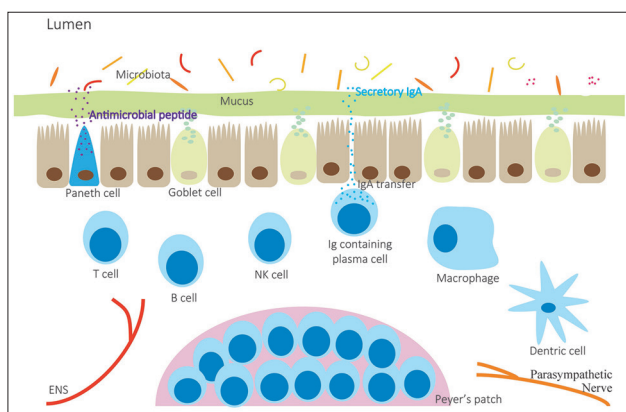


Figure 1: The maintenance of intestinal homeostasis is attributed to a well-organized cooperation of microbiota, mucus barrier, immune system, and nervous system. Unbalance of microbiota, alteration of mucus composition and mucin production by goblet cells, and abnormality of immune system which includes a deficient distribution of immune cells, failing IgA transfer leading to a decrease of secretory IgA, a decrease of secretory phospholipase A2 secreted by Paneth cells, and a reduction of B-cells in Peyer's patches, together with abnormal enteric nervous system and parasympathetic nervous system, trigger the occurrence and development of Hirschsprung's-associated enterocolitis.

Financial support and sponsorship

This study was supported by a grant from National Natural Science Foundation of China (No. 81270441).

Conflicts of interest

There are no conflicts of interest.

REFERENCES

- Sergi C. Hirschsprung's disease: Historical notes and pathological diagnosis on the occasion of the 100(th) anniversary of Dr. Harald Hirschsprung's death. *World J Clin Pediatr* 2015;4:120-5. doi: 10.5409/wjcp.v4.i4.120.
- McKeown SJ, Stamp L, Hao MM, Young HM. Hirschsprung disease: A developmental disorder of the enteric nervous system. *Wiley Interdiscip Rev Dev Biol* 2013;2:113-29. doi: 10.1002/wdev.57.
- Langer JC. Hirschsprung disease. *Curr Opin Pediatr* 2013;25:368-74. doi: 10.1097/MOP.0b013e328360c2a0.
- Somme S, Langer JC. Primary versus staged pull-through for the treatment of Hirschsprung disease. *Semin Pediatr Surg* 2004;13:249-55. doi: 10.1053/j.sempedsurg.2004.10.012.
- Gosemann JH, Friedmacher F, Ure B, Lacher M. Open versus transanal pull-through for Hirschsprung disease: A systematic review of long-term outcome. *Eur J Pediatr Surg* 2013;23:94-102. doi: 10.1055/s-0033-1343085.
- Chen Y, Nah SA, Laksmi NK, Ong CC, Chua JH, Jacobsen A, *et al.* Transanal endorectal pull-through versus transabdominal approach for Hirschsprung's disease: A systematic review and meta-analysis. *J Pediatr Surg* 2013;48:642-51. doi: 10.1016/j.jpedsurg.2012.12.036.
- Zhu T, Feng J, Zhang W, Wei M, Yu D, Zhang X, *et al.* Subtotal colectomy with a single-incision laparoscopic surgery technique in children with long-segment Hirschsprung disease and allied disorders. *Pediatr Surg Int* 2013;29:197-201. doi: 10.1007/s00383-012-3221-4.
- Craigie RJ, Conway SJ, Cooper L, Turnock RR, Lamont GL, Baillie CT, *et al.* Primary pull-through for Hirschsprung's disease: Comparison of open and laparoscopic-assisted procedures. *J Laparoendosc Adv Surg Tech A* 2007;17:809-12. doi: 10.1089/lap.2007.0081.
- Sulkowski JP, Cooper JN, Congeni A, Pearson EG, Nwomeh BC, Doolin EJ, *et al.* Single-stage versus multi-stage pull-through for Hirschsprung's disease: Practice trends and outcomes in infants. *J Pediatr Surg* 2014;49:1619-25. doi: 10.1016/j.jpedsurg.2014.06.002.
- Demehri FR, Halaweish IF, Coran AG, Teitelbaum DH. Hirschsprung-associated enterocolitis: Pathogenesis, treatment and prevention. *Pediatr Surg Int* 2013;29:873-81. doi: 10.1007/s00383-013-3353-1.
- Bill J, Chapman AH, Chapman ND. The enterocolitis of Hirschsprung's disease: Its natural history and treatment. *Am J Surg* 1962;103:70-4. doi: 10.1016/0002-9610(62)90016-8.
- Vieten D, Spicer R. Enterocolitis complicating Hirschsprung's disease. *Semin Pediatr Surg* 2004;13:263-72. doi: 10.1053/j.sempedsurg.2004.10.014.
- Moore SW. Total colonic aganglionosis in Hirschsprung disease. *Semin Pediatr Surg* 2012;21:302-9. doi: 10.1053/j.sempedsurg.2012.07.004.
- Friedmacher F, Puri P. Hirschsprung's disease associated with Down syndrome: A meta-analysis of incidence, functional outcomes and mortality. *Pediatr Surg Int* 2013;29:937-46. doi: 10.1007/s00383-013-3361-1.
- Kim AC, Langer JC, Pastor AC, Zhang L, Sloots CE, Hamilton NA, *et al.* Endorectal pull-through for Hirschsprung's disease – A multicenter, long-term comparison of results: Transanal vs transabdominal approach. *J Pediatr Surg* 2010;45:1213-20. doi: 10.1016/j.jpedsurg.2010.02.087.
- Johansson ME, Sjövall H, Hansson GC. The gastrointestinal mucus system in health and disease. *Nat Rev Gastroenterol Hepatol* 2013;10:352-61. doi: 10.1038/nrgastro.2013.35.
- Pelaseyed T, Bergström JH, Gustafsson JK, Ermund A, Birchenough GM, Schütte A, *et al.* The mucus and mucins of the goblet cells and enterocytes provide the first defense line of the gastrointestinal tract and interact with the immune system. *Immunol Rev* 2014;260:8-20. doi: 10.1111/imr.12182.

18. Mattar AF, Coran AG, Teitelbaum DH. MUC-2 mucin production in Hirschsprung's disease: Possible association with enterocolitis development. *J Pediatr Surg* 2003;38:417-21. doi: 10.1053/jpsu.2003.50071.
19. Thiagarajah JR, Yildiz H, Carlson T, Thomas AR, Steiger C, Pieretti A, *et al.* Altered goblet cell differentiation and surface mucus properties in Hirschsprung disease. *PLoS One* 2014;9:e99944. doi: 10.1371/journal.pone.0099944.
20. Aslam A, Spicer RD, Corfield AP. Histochemical and genetic analysis of colonic mucin glycoproteins in Hirschsprung's disease. *J Pediatr Surg* 1999;34:330-3. doi: 10.1016/S0022-3468(99)90202-6.
21. Aslam A, Spicer RD, Corfield AP. Children with Hirschsprung's disease have an abnormal colonic mucus defensive barrier independent of the bowel innervation status. *J Pediatr Surg* 1997;32:1206-10. doi: 10.1016/S0022-3468(97)90683-7.
22. Fujimoto T. Natural history and pathophysiology of enterocolitis in the piebald lethal mouse model of Hirschsprung's disease. *J Pediatr Surg* 1988;23:237-42. doi: 10.1016/S0022-3468(88)80730-9.
23. Teitelbaum DH, Caniano DA, Qualman SJ. The pathophysiology of Hirschsprung's-associated enterocolitis: Importance of histologic correlates. *J Pediatr Surg* 1989;24:1271-7. doi: 10.1016/S0022-3468(89)80566-4.
24. Akkary S, Sahwy E, Kandil W, Hamdy MH. A histochemical study of the mucosubstances of the colon in cases of Hirschsprung's disease with and without enterocolitis. *J Pediatr Surg* 1981;16:664-8. doi: 10.1016/S0022-3468(81)80547-7.
25. Yildiz HM, Carlson TL, Goldstein AM, Carrier RL. Mucus barriers to microparticles and microbes are altered in Hirschsprung's disease. *Macromol Biosci* 2015;15:712-8. doi: 10.1002/mabi.201400473.
26. Marietta E, Rishi A, Taneja V. Immunogenetic control of the intestinal microbiota. *Immunology* 2015;145:313-22. doi: 10.1111/imm.12474.
27. Hooper LV, Gordon JI. Commensal host-bacterial relationships in the gut. *Science* 2001;292:1115-8. doi: 10.1126/science.1058709.
28. Kamada N, Núñez G. Regulation of the immune system by the resident intestinal bacteria. *Gastroenterology* 2014;146:1477-88. doi: 10.1053/j.gastro.2014.01.060.
29. Marchesi JR, Adams DH, Fava F, Hermes GD, Hirschfield GM, Hold G, *et al.* The gut microbiota and host health: A new clinical frontier. *Gut* 2016;65:330-9. doi: 10.1136/gutjnl-2015-309990.
30. Tojo R, Suárez A, Clemente MG, de los Reyes-Gavilán CG, Margolles A, Gueimonde M, *et al.* Intestinal microbiota in health and disease: Role of bifidobacteria in gut homeostasis. *World J Gastroenterol* 2014;20:15163-76. doi: 10.3748/wjg.v20.i41.15163.
31. Holzer P, Farzi A. Neuropeptides and the microbiota-gut-brain axis. *Adv Exp Med Biol* 2014;817:195-219. doi: 10.1007/978-1-4939-0897-4_9.
32. Cryan JF, Dinan TG. Mind-altering microorganisms: The impact of the gut microbiota on brain and behaviour. *Nat Rev Neurosci* 2012;13:701-12. doi: 10.1038/nrn3346.
33. Ray K. Gut microbiota. Host-microbe interactions and the enteric nervous system: A new connection? *Nat Rev Gastroenterol Hepatol* 2015;12:311. doi: 10.1038/nrgastro.2015.69.
34. Mayer EA, Tillisch K, Gupta A. Gut/brain axis and the microbiota. *J Clin Invest* 2015;125:926-38. doi: 10.1172/JCI76304.
35. Frykman PK, Nordenskjöld A, Kawaguchi A, Hui TT, Granström AL, Cheng Z, *et al.* Characterization of bacterial and fungal microbiome in children with Hirschsprung disease with and without a history of enterocolitis: A multicenter study. *PLoS One* 2015;10:e0124172. doi: 10.1371/journal.pone.0124172.
36. Shen DH, Shi CR, Chen JJ, Yu SY, Wu Y, Yan WB. Detection of intestinal bifidobacteria and lactobacilli in patients with Hirschsprung's disease associated enterocolitis. *World J Pediatr* 2009;5:201-5. doi: 10.1007/s12519-009-0038-x.
37. Pierre JF, Barlow-Anacker AJ, Erickson CS, Heneghan AF, Levenson GE, Dowd SE, *et al.* Intestinal dysbiosis and bacterial enteroinvasion in a murine model of Hirschsprung's disease. *J Pediatr Surg* 2014;49:1242-51. doi: 10.1016/j.jpedsurg.2014.01.060.
38. Yan Z, Poroyko V, Gu S, Zhang Z, Pan L, Wang J, *et al.* Characterization of the intestinal microbiome of Hirschsprung's disease with and without enterocolitis. *Biochem Biophys Res Commun* 2014;445:269-74. doi: 10.1016/j.bbrc.2014.01.104.
39. Ward NL, Pieretti A, Dowd SE, Cox SB, Goldstein AM. Intestinal aganglionosis is associated with early and sustained disruption of the colonic microbiome. *Neurogastroenterol Motil* 2012;24:874-e400. doi: 10.1111/j.1365-2982.2012.01937.x.
40. Wang X, Li Z, Xu Z, Wang Z, Feng J. Probiotics prevent Hirschsprung's disease-associated enterocolitis: A prospective multicenter randomized controlled trial. *Int J Colorectal Dis* 2015;30:105-10. doi: 10.1007/s00384-014-2054-0.
41. El-Sawaf M, Siddiqui S, Mahmoud M, Drongowski R, Teitelbaum DH. Probiotic prophylaxis after pullthrough for Hirschsprung disease to reduce incidence of enterocolitis: A prospective, randomized, double-blind, placebo-controlled, multicenter trial. *J Pediatr Surg* 2013;48:111-7. doi: 10.1016/j.jpedsurg.2012.10.028.
42. Thomas DF, Fernie DS, Bayston R, Spitz L, Nixon HH. Enterocolitis in Hirschsprung's disease: A controlled study of the etiologic role of *Clostridium difficile*. *J Pediatr Surg* 1986;21:22-5. doi: 10.1016/S0022-3468(86)80644-3.
43. Hardy SP, Bayston R, Spitz L. Prolonged carriage of *Clostridium difficile* in Hirschsprung's disease. *Arch Dis Child* 1993;69:221-4. doi: 10.1136/adc.69.2.221.
44. Mc Laughlin D, Friedmacher F, Puri P. The impact of *Clostridium difficile* on paediatric surgical practice: A systematic review. *Pediatr Surg Int* 2014;30:853-9. doi: 10.1007/s00383-014-3543-5.
45. Demehri FR, Frykman PK, Cheng Z, Ruan C, Wester T, Nordenskjöld A, *et al.* Altered fecal short chain fatty acid composition in children with a history of Hirschsprung-associated enterocolitis. *J Pediatr Surg* 2016;51:81-6. doi: 10.1016/j.jpedsurg.2015.10.012.
46. Iwasaki A, Medzhitov R. Control of adaptive immunity by the innate immune system. *Nat Immunol* 2015;16:343-53. doi: 10.1038/ni.3123.
47. Azzali G. Structure, lymphatic vascularization and lymphocyte migration in mucosa-associated lymphoid tissue. *Immunol Rev* 2003;195:178-89. doi: 10.1034/j.1600-065X.2003.00072.x.
48. Mowat AM, Agace WW. Regional specialization within the intestinal immune system. *Nat Rev Immunol* 2014;14:667-85. doi: 10.1038/nri3738.
49. Costes LM, Boeckxstaens GE, de Jonge WJ, Cailotto C. Neural networks in intestinal immunoregulation. *Organogenesis* 2013;9:216-23. doi: 10.4161/org.25646.
50. Cervi AL, Lukewich MK, Lomax AE. Neural regulation of gastrointestinal inflammation: Role of the sympathetic nervous system. *Auton Neurosci* 2014;182:83-8. doi: 10.1016/j.autneu.2013.12.003.
51. Busch RA, Heneghan AF, Pierre JF, Wang X, Kudsk KA. The enteric nervous system neuropeptide, bombesin, reverses innate immune impairments during parenteral nutrition. *Ann Surg* 2014;260:432-43. doi: 10.1097/SLA.0000000000000871.
52. Chandrasekharan B, Nezami BG, Srinivasan S. Emerging neuropeptide targets in inflammation: NPY and VIP. *Am J Physiol Gastrointest Liver Physiol* 2013;304:G949-57. doi: 10.1152/ajpgi.00493.2012.
53. Cheng Z, Wang X, Dhall D, Zhao L, Bresee C, Doherty TM, *et al.* Splenic lymphopenia in the endothelin receptor B-null mouse: Implications for Hirschsprung associated enterocolitis. *Pediatr Surg Int* 2011;27:145-50. doi: 10.1007/s00383-010-2787-y.
54. Frykman PK, Cheng Z, Wang X, Dhall D. Enterocolitis causes profound lymphoid depletion in endothelin receptor B- and endothelin 3-null mouse models of Hirschsprung-associated enterocolitis. *Eur J Immunol* 2015;45:807-17. doi: 10.1002/eji.201444737.
55. Dang R, Sasaki N, Nishino T, Nakanishi M, Torigoe D, Agui T. Lymphopenia in Ednr^b-deficient rat was strongly modified by genetic background. *Biomed Res* 2012;33:249-53. doi: 10.2220/biomedres.33.249.
56. Gosain A, Barlow-Anacker AJ, Erickson CS, Pierre JF, Heneghan AF, Epstein ML, *et al.* Impaired cellular immunity in the murine neural crest conditional deletion of endothelin receptor-B model of Hirschsprung's disease. *PLoS One* 2015;10:e0128822. doi: 10.1371/journal.pone.0128822.
57. Turnock RR, Spitz L, Strobel S. A study of mucosal gut immunity in infants who develop Hirschsprung's-associated enterocolitis. *J Pediatr Surg* 1992;27:828-9. doi: 10.1016/0022-3468(92)90375-H.
58. Moore SW, Johnson G, Schneider JW. Elevated tissue immunoglobulins in Hirschsprung's disease - Indication of early immunologic response. *Eur J Pediatr Surg* 2000;10:106-10. doi: 10.1055/s-2008-1072336.

59. Imamura A, Puri P, O'Briain DS, Reen DJ. Mucosal immune defence mechanisms in enterocolitis complicating Hirschsprung's disease. *Gut* 1992;33:801-6. doi: 10.1136/gut.33.6.801.
60. Fujimoto T, Reen DJ, Puri P. Inflammatory response in enterocolitis in the piebald lethal mouse model of Hirschsprung's disease. *Pediatr Res* 1988;24:152-5. doi: 10.1203/00006450-198808000-00002.
61. Wilson-Storey D, Scobie WG, Raeburn JA. Defective white blood cell function in Hirschsprung's disease: A possible predisposing factor to enterocolitis. *J R Coll Surg Edinb* 1988;33:185-8. doi: 10.1016/S0022-3468(89)80752-3.
62. Wilson-Storey D, Scobie WG. Impaired gastrointestinal mucosal defense in Hirschsprung's disease: A clue to the pathogenesis of enterocolitis? *J Pediatr Surg* 1989;24:462-4. doi: 10.1016/S0022-3468(89)80402-6.
63. Haricharan RN, Georgeson KE. Hirschsprung disease. *Semin Pediatr Surg* 2008;17:266-75. doi: 10.1053/j.sempedsurg.2008.07.005.
64. Caniano DA, Teitelbaum DH, Qualman SJ, Shannon BT. The piebald-lethal murine strain: Investigation of the cause of early death. *J Pediatr Surg* 1989;24:906-10. doi: 10.1016/S0022-3468(89)80593-7.
65. Lui VC, Li L, Sham MH, Tam PK. CDX-1 and CDX-2 are expressed in human colonic mucosa and are down-regulated in patients with Hirschsprung's disease associated enterocolitis. *Biochim Biophys Acta* 2001;1537:89-100. doi: 10.1016/S0925-4439(01)00056-4.
66. Moore SW, Sidler D, Zaahl MG. The ITGB2 immunomodulatory gene (CD18), enterocolitis, and Hirschsprung's disease. *J Pediatr Surg* 2008;43:1439-44. doi: 10.1016/j.jpedsurg.2007.12.057.
67. Lacher M, Fitze G, Helmbrecht J, Schroepf S, Berger M, Lohse P, *et al.* Hirschsprung-associated enterocolitis develops independently of NOD2 variants. *J Pediatr Surg* 2010;45:1826-31. doi: 10.1016/j.jpedsurg.2010.02.039.
68. Hackam DJ, Filler RM, Pearl RH. Enterocolitis after the surgical treatment of Hirschsprung's disease: Risk factors and financial impact. *J Pediatr Surg* 1998;33:830-3. doi: 10.1016/S0022-3468(98)90652-2.
69. Estevão-Costa J, Carvalho JL, Soares-Oliveira M. Risk factors for the development of enterocolitis after pull-through for Hirschsprung's disease. *J Pediatr Surg* 1999;34:1581-2. doi: 10.1016/S0022-3468(99)90139-2.
70. Wu X, Feng J, Wei M, Guo X, Li R, Xuan X, *et al.* Patterns of postoperative enterocolitis in children with Hirschsprung's disease combined with hypoganglionosis. *J Pediatr Surg* 2009;44:1401-4. doi: 10.1016/j.jpedsurg.2008.11.004.
71. Ure BM, Holschneider AM, Schulten D, Meier-Ruge W. Clinical impact of intestinal neuronal malformations: A prospective study in 141 patients. *Pediatr Surg Int* 1997;12:377-82. doi: 10.1007/BF01076944.
72. Dembowski C, Hofmann P, Koch T, Kamrowski-Kruck H, Riedesel H, Krammer HJ, *et al.* Phenotype, intestinal morphology, and survival of homozygous and heterozygous endothelin B receptor-deficient (spotting lethal) rats. *J Pediatr Surg* 2000;35:480-8. doi: 10.1016/S0022-3468(00)90218-5.
73. Lloyd-Still JD, Demers LM. Hirschsprung's enterocolitis, prostaglandins, and response to cholestyramine. *J Pediatr Surg* 1978;13:417-8. doi: 10.1016/S0022-3468(78)80467-9.
74. Soeda J, O'Briain DS, Puri P. Regional reduction in intestinal neuroendocrine cell populations in enterocolitis complicating Hirschsprung's disease. *J Pediatr Surg* 1993;28:1063-8. doi: 10.1016/0022-3468(93)90520-U.
75. Soeda J, O'Briain DS, Puri P. Mucosal neuroendocrine cell abnormalities in the colon of patients with Hirschsprung's disease. *J Pediatr Surg* 1992;27:823-7. doi: 10.1016/0022-3468(92)90374-G.