

# Stent-assisted Coiling for Ruptured Basilar Artery Dissecting Aneurysms: An Initial Experience of Four Cases

Satoshi KOIZUMI,<sup>1</sup> Masaaki SHOJIMA,<sup>1</sup> Akira IJIMA,<sup>1</sup> Soichi OYA,<sup>2</sup> Toru MATSUI,<sup>2</sup>  
Gakushi YOSHIKAWA,<sup>3</sup> Kazuo TSUTSUMI,<sup>3</sup> Hirofumi NAKATOMI,<sup>1</sup>  
and Nobuhito SAITO<sup>1</sup>

<sup>1</sup>*Department of Neurosurgery, The University of Tokyo Hospital, Bunkyo-ku, Tokyo;*

<sup>2</sup>*Department of Neurosurgery, Saitama Medical Center, Kawagoe, Saitama;*

<sup>3</sup>*Department of Neurosurgery, Showa General Hospital, Kodaira, Tokyo*

## Abstract

No treatment strategy has been established for subarachnoid hemorrhages due to basilar artery (BA) trunk dissecting aneurysms. Our aim was to report our initial experience performing stent-assisted coiling (SAC) for ruptured BA dissecting aneurysms to validate the effectiveness of this treatment. We experienced four consecutive cases of ruptured dissecting BA trunk aneurysm treated with SAC between 2008 and 2014 at three institutions. Aneurysm rebleeding was prevented without causing severe brainstem ischemia in all cases. In our opinion, both the blockage of the inflow to aneurysms and the preservation of the antegrade flow of the BA can be achieved by SAC, although controversies regarding long-term stability and appropriate antiplatelet therapy remain.

Key words: basilar trunk aneurysm, stent-assisted coiling, dissecting aneurysm, subarachnoid hemorrhage, reconstructive endovascular treatment

## Introduction

Subarachnoid hemorrhage (SAH) due to a dissecting aneurysm has a catastrophic mortality rate because of the high probability of rebleeding in the acute phase.<sup>1)</sup> Dissecting aneurysms presenting with SAH more frequently occur in the vertebrobasilar circulation.<sup>2)</sup> Among these dissecting aneurysms, the effectiveness of the proximal vertebral artery (VA) occlusion on trapping by direct surgical clipping<sup>3–5)</sup> or endovascular coiling<sup>6–9)</sup> has been established in the literature. However, basilar artery (BA) trunk dissecting aneurysms pose a significant treatment challenge because antegrade BA flow and the blockage of the inflow to the aneurysm should be maintained. We recently treated four cases of ruptured BA dissecting aneurysm with stent-assisted coiling (SAC). We obliterated the aneurysms with preservation of the normal flow of the BA trunk in all cases. Herein, we report our initial experience to validate the effectiveness of this treatment, and discuss the problems that remain to be addressed.

## Materials and Methods

Between September 2008 and March 2014, we treated four consecutive cases of ruptured BA trunk dissecting

aneurysms with SAC at the University of Tokyo Hospital and its two affiliated hospitals. The medical records and imaging data of these four cases were retrospectively reviewed.

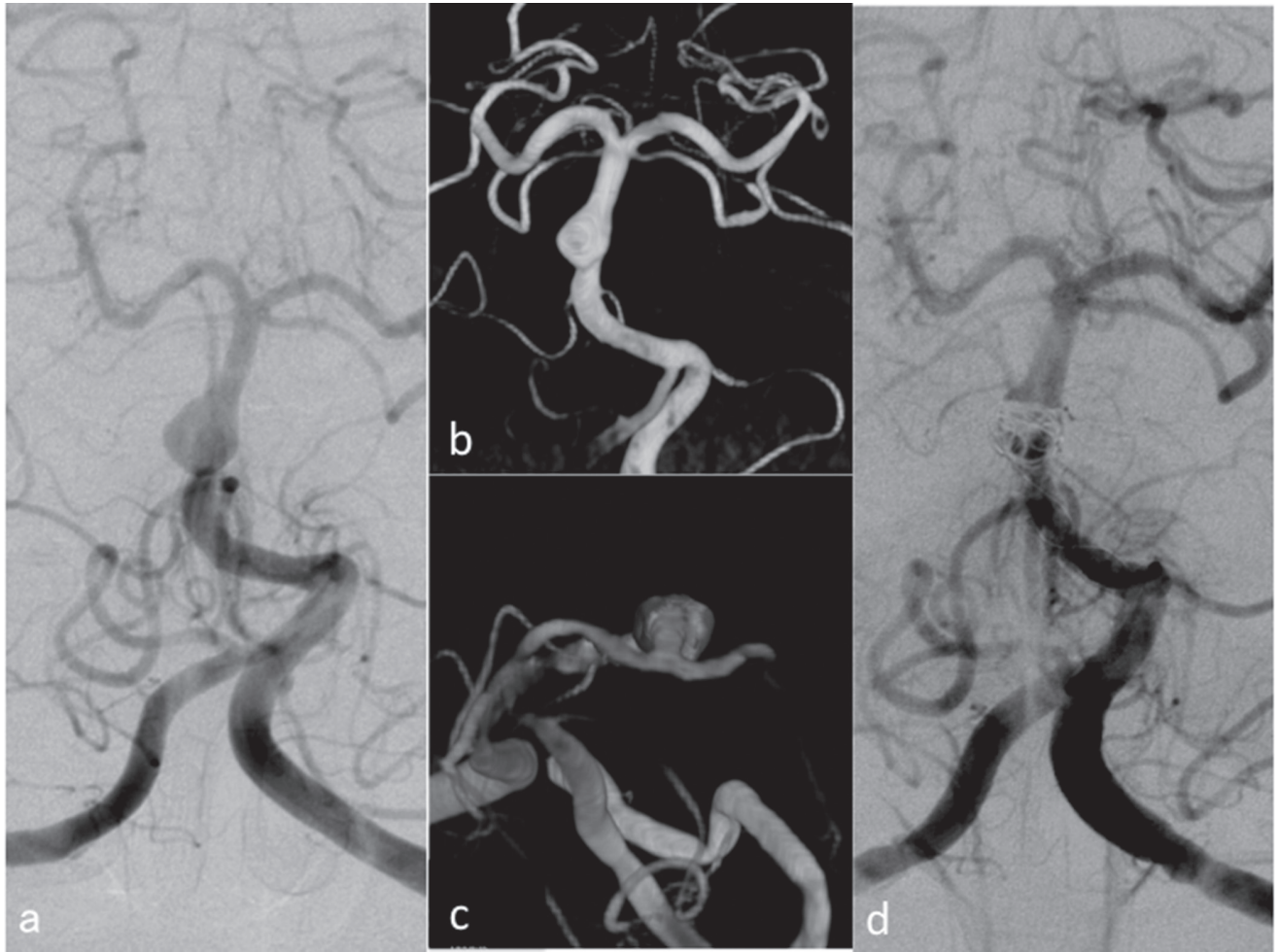
Table 1 shows the clinical and demographic data of the four cases (2 men and 2 women; median age, 51 years [range, 40–80 years]). In all the cases, confirmation of the aneurysm was performed by conventional catheter angiography and three-dimensional rotation angiography. BA trunk dilatation could be detected easily by conventional angiography. To distinguish the acute arterial dissection from the other types of basilar trunk aneurysms,<sup>10)</sup> the diagnosis of acute BA dissection was made according to the following two criteria: (1) focal dilatation of the vessel diameter at the non-branching site of the BA trunk with associated SAH and (2) no thickening of the vessel wall, which implies chronic formation of the aneurysm. Vessel wall hematoma on magnetic resonance imaging, which is required for a definite diagnosis of acute arterial dissection, was not taken into consideration in our series. SAC was performed between 2 days and 20 days (mean, 8.8 days) after the rupture of the aneurysms.

Oral antiplatelet administration was initiated on the morning of the treatment day. In cases 2 and 4, dual antiplatelet therapy (DAPT) was initiated in the morning of the treatment day and was continued after

Table 1 Summary of the four cases

Case	Age (years)	Sex	WFNS grade	Tx day	Stent	Coil number and total length	Antiplatelet before Tx	Intraoperative heparin	Embolization	Antiplatelet after Tx	Complication	mRS at discharge	f/u AG	Clinical f/u
1	40	F	1	4	Leo (3.5 × 18 mm)	2 coils, 21 cm	clopidogrel 300 mg	10,000 u	dome filling	ASA 100 mg + clopidogrel 300 mg	dilatation of the residual aneurysm	0	60 Mo	60 Mo
2	56	M	5	9	Driver splint (3 × 15 mm) × 2	12 coils, 70 cm	ASA 100 mg + cilostazol 100 mg	7,500 u	dome filling	ASA 100 mg + clopidogrel 300 mg	BA occlusion	5	1.5 Mo	3 Mo
3	46	M	5	2	Enterprize (4.5 × 37 mm)	4 coils, 28 cm	clopidogrel 300 mg	7,500 u	dome filling	clopidogrel 75 mg	dilatation of the residual aneurysm	2	14 Mo	14 Mo
4	80	F	4	20	Enterprize (4.5 × 37 mm)	14 coils, 109 cm	ASA 100 mg + clopidogrel 300 mg	8,000 u	dome filling	ASA 100 mg + clopidogrel 300 mg	none	4	(-)	1 Mo

AG: angiography, ASA: acetylsalicylic acid, BA: basilar artery, F: female, f/u: follow-up, M: male, Mo: months, mRS: modified Rankin scale, Tx: treatment, WFNS: World Federation of Neurosurgical Societies.



**Fig. 1** Case 1 imaging. **a**: Preoperative left vertebral angiogram showing the dissecting aneurysm. **b, c**: Three-dimensional rotation angiogram showing the dissection of the basilar trunk (**b**, antero-posterior view; **c**, cranio-caudal view). Note the all-around dilatation at the non-branching site of the artery, which demonstrated dissecting rather than saccular aneurysm. **d**: Left vertebral angiogram just after treatment.

treatment. In the remaining two cases, however, DAPT was not employed before the treatment. We refrained from DAPT in those cases because of the risk of fatal bleeding complication before treatment. During SAC, 7,500 to 10,000 units of heparin were administered via a guiding catheter to prevent thrombotic complications. After the microcatheter for the coiling was placed inside the aneurysm, the stent covering the dissecting BA was expanded using the jail technique. After the stenting, coiling through the jailed microcatheter was performed. We used heparin only during the treatment and did not administer anticoagulants thereafter.

### Results

In all the four cases, SAC for the aneurysm was successfully completed. Brainstem infarction as a result of the SAC treatment occurred in no cases. However, case 2

showed delayed BA occlusion 1 month after when oral antiplatelet agents were stopped to perform lumbo-peritoneal shunt placement for the normal pressure hydrocephalus. In this case, the patient remained in a coma from the time of SAH onset to the postoperative period after the shunt operation; therefore, could not expect an occlusion considering the patient's clinical condition. The angiography showing the occlusion was performed as a routine follow-up examination before the transfer to a nearby hospital. In case 4, SAC for the lesion was successful, but the general condition of the patient was poor because of the initial bleeding damage.

Long-term follow-up angiography (longer than 1 year after SAC) was conducted in two cases (1 and 3); both exhibited a slight dilatation of the dissecting lumen, for which a close follow-up was continued. During the mean follow-up of 20 months, no rebleeding was observed.

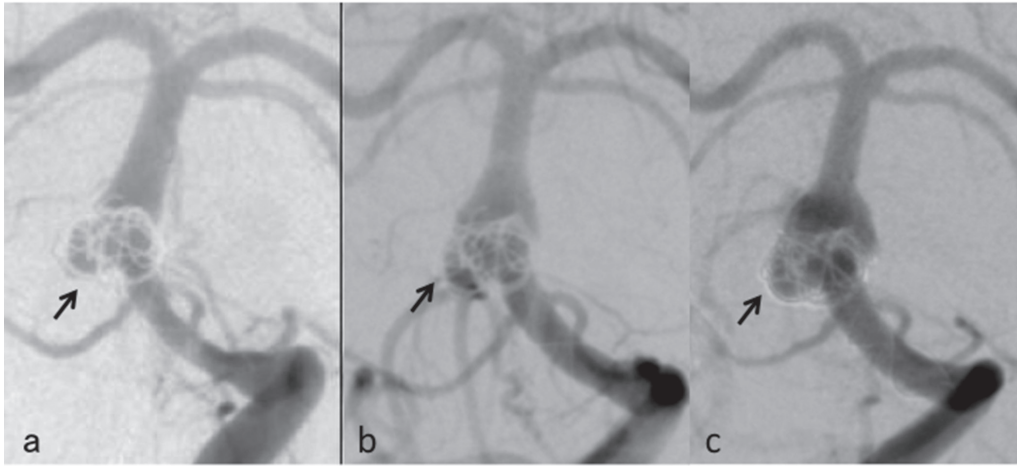


Fig. 2 Long-term follow-up of case 1. a-c: Left vertebral angiogram performed 1 year (a), 3 years (b), and 5 years (c) after the treatment. Note the gradual dilatation of the residual aneurysm (*black arrows*).

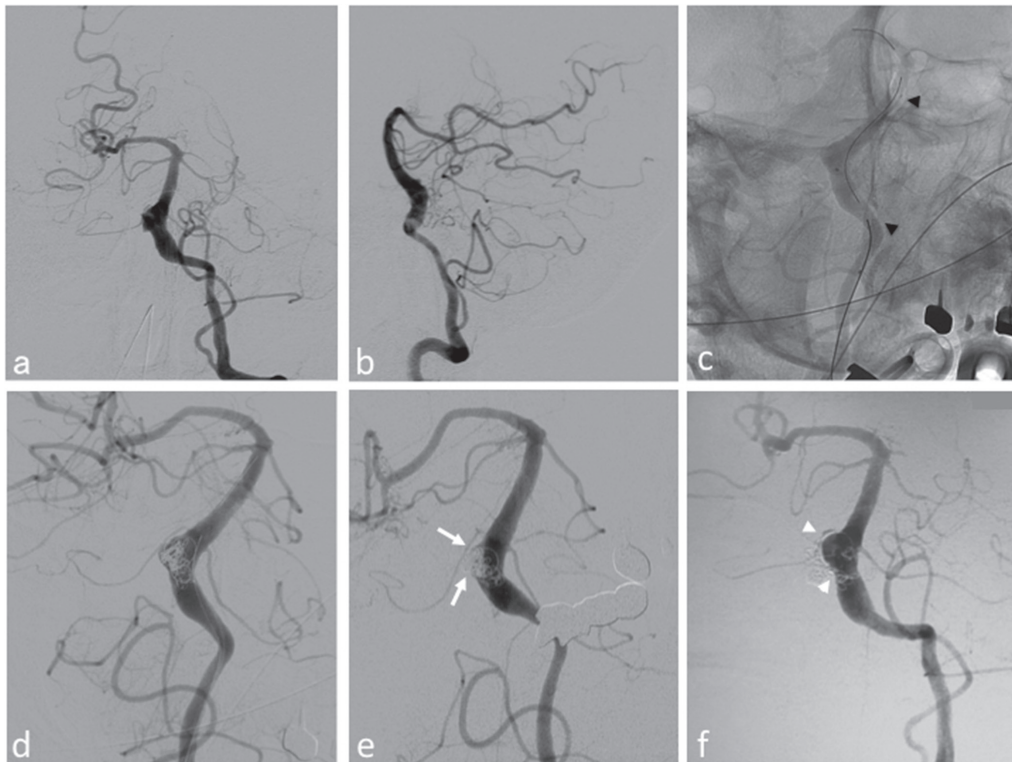


Fig. 3 Case 3 imaging. a, b: Preoperative left vertebral angiograms (a, antero-posterior view; b, lateral view). Note the dissecting aneurysm extending from the mid-basilar artery to the left vertebral artery. c: Placement of the Codman Enterprise VRD (Johnson & Johnson Codman, Miami, Florida, USA) through the dissecting aneurysm. *Black arrowheads* show the distal and proximal markers of the stent. d-f: Postoperative left vertebral angiograms (d, just after treatment; e, 1 month after treatment; f, 14 months after treatment). Note that the partial filling observed in (d) is no longer apparent in (e) (*white arrows*). However, slight dilatation of the coiled lumen can be observed in (f) (*white arrowheads*).

## Illustrative Cases

### I. Case 1

A 40-year-old woman with no medical history experienced a sudden-onset headache. Head computed tomography

(CT) revealed a diffuse SAH in the basal cistern, and she was transferred to our department. Her consciousness was clear with no neurological deficit (World Federation of Neurological Societies [WFNS] grade 1). Angiography revealed a BA trunk dissecting aneurysm (Fig. 1a-c). Direct

surgery, involving anastomosis of the superficial temporal artery to the superior cerebellar artery and proximal BA ligation, was attempted. The anastomosis, however, was not successful, and BA ligation was abandoned. Therefore, SAC using a Leo stent (Balt, Montmorency, France) was then attempted on day 4 (Fig. 1d) with the approval of the hospital ethics committee. Clopidogrel (300 mg) was administered in the morning of the treatment day, and a combination of acetylsalicylic acid (100 mg daily) and clopidogrel (75 mg daily) was administered thereafter. Her postoperative course was uneventful. She was discharged with a modified Rankin scale (mRS) score of 0. The 1-year follow-up angiography showed slight dilatation of the dissecting portion, and yearly angiography was continued for 5 years (Fig. 2a–c). Rebleeding did not occur during the 5-year follow-up.

## II. Case 3

A 46-year-old man with untreated hypertension and a history of severe smoking was admitted to our hospital because of a sudden loss of consciousness. On arrival, his consciousness level was comatose with a minimal response to pain (WFNS grade 5). His head CT scan revealed an SAH, and a dissecting aneurysm extending from the left VA to the mid-BA trunk was detected on angiography (Fig. 3a, b). The intervention was performed on day 2. The patient was pretreated with clopidogrel 300 mg on the day of the treatment and was continued thereafter at 75 mg daily. After the Enterprise VRD (Johnson & Johnson Codman, Miami, Florida, USA) was placed over the entire length of the lesion (Fig. 3c), coil embolization of the dilatation was completed while the partial filling of the dilating portion was still observed (Fig. 3d). On a second angiography 1 month after the treatment, partial filling of the dilating portion was no longer visible, which suggested good thrombosis of the cavities around the coils (Fig. 3e). At the 12-month clinical follow-up, his mRS score was 2. Although a slight dilatation of the dissection lumen was observed on the follow-up angiography performed 14 months after surgery (Fig. 3f), we decided to continue close observation.

## Discussion

Ninety percent of BA trunk dissecting aneurysms eventually rebleed, resulting in deaths or severe neurological sequelae.<sup>11</sup> Despite the poor prognosis, the treatment is extremely difficult because the blood inflow to the aneurysm should be blocked without impairing normal BA blood flow. To date, there is no standard treatment strategy for the treatment of BA trunk dissecting aneurysms.

Under such circumstances, SAC is gaining popularity as a treatment option for difficult cerebral aneurysms,<sup>12</sup> and its clinical use is expanding to dissecting aneurysms.<sup>13,14</sup> Previous reports indicate the possibility that both the blocking of inflow to aneurysms and preserving

the flow of the parent artery may be achieved with SAC. In a few reported cases,<sup>11,13,15</sup> no rebleeding or brainstem infarction was experienced during the 6–24 months of angiographical and clinical follow-up. We believe that our initial experience showed promising results consistent with those previous reports, although the number of reported cases is quite small.

There are at least two problems that need to be addressed before SAC is accepted as the standard therapy for ruptured BA trunk dissecting aneurysms. First, the long-term efficacy of the treatment has yet to be confirmed. The dilatation of the coiled portion after SAC was observed in two of our cases. Our cases showed satisfactory results for the prevention of the rebleeding in the acute phase, but the long-term stability is another problem. The other problem is the variety of perioperative antiplatelet and anticoagulation therapies. In our cases, delayed occlusion of the BA occurred in case 2 when the antiplatelet agents were discontinued, demonstrating the importance of antiplatelet therapy after SAC. On the other hand, no bleeding event related to antithrombotic or anticoagulation therapy was experienced. At least, we may be more aggressive with DAPT, since SAC of acutely ruptured intracranial aneurysms has already been performed with DAPT in many cases.<sup>16</sup>

The treatment of ruptured dissecting aneurysm of the BA trunk is extremely difficult with little evidence in the literature. Although there have been very few reports of SAC for these aneurysms in the literature to draw any strong conclusion, the accumulation of more cases may gradually prove its effectiveness for this disease.

## Conflicts of Interest Disclosure

The authors state that no competing interests or financial disclosure exist for this manuscript.

## References

- 1) Kawaguchi S, Sakaki T, Tsunoda S, Morimoto T, Hoshida T, Kawai S, Iwanaga H, Nikaido Y: Management of dissecting aneurysms of the posterior circulation. *Acta Neurochir (Wien)* 131: 26–31, 1994
- 2) Yamaura A, Yoshimoto T, Hashimoto N, Ono J: Nationwide study of nontraumatic intracranial arterial dissection: clinical features and outcome. *Surg Cereb Stroke* 26: 79–86, 1998
- 3) Lemole GM, Henn J Jr, Javedan S, Deshmukh V, Spetzler RF: Cerebral revascularization performed using posterior inferior cerebellar artery-posterior inferior cerebellar artery bypass. Report of four cases and literature review. *J Neurosurg* 97: 219–223, 2002
- 4) Ogasawara K, Kubo Y, Tomitsuka N, Sasoh M, Otawara Y, Arai H, Ogawa A: Treatment of vertebral artery aneurysms with transposition of the posterior inferior cerebellar artery to the vertebral artery combined with parent artery occlusion. Technical note. *J Neurosurg* 105: 781–784, 2006

- 5) Yasui T, Komiyama M, Nishikawa M, Nakajima H: Subarachnoid hemorrhage from vertebral artery dissecting aneurysms involving the origin of the posteroinferior cerebellar artery: report of two cases and review of the literature. *Neurosurgery* 46: 196–200; discussion 200–201, 2000
- 6) Iihara K, Sakai N, Murao K, Sakai H, Higashi T, Kogure S, Takahashi JC, Nagata I: Dissecting aneurysms of the vertebral artery: a management strategy. *J Neurosurg* 97: 259–267, 2002
- 7) Kashiwazaki D, Ushikoshi S, Asano T, Kuroda S, Houkin K: Long-term clinical and radiological results of endovascular internal trapping in vertebral artery dissection. *Neuroradiology* 55: 201–206, 2013
- 8) Lee JM, Kim TS, Joo SP, Yoon W, Choi HY: Endovascular treatment of ruptured dissecting vertebral artery aneurysms—long-term follow-up results, benefits of early embolization, and predictors of outcome. *Acta Neurochir (Wien)* 152: 1455–1465, 2010
- 9) Sugiu K, Tokunaga K, Watanabe K, Sasahara W, Ono S, Tamiya T, Date I: Emergent endovascular treatment of ruptured vertebral artery dissecting aneurysms. *Neuroradiology* 47: 158–164, 2005
- 10) Saliou G, Sacho RH, Power S, Kostynskyy A, Willinsky RA, Tymianski M, terBrugge KG, Rawal S, Krings T: Natural history and management of basilar trunk artery aneurysms. *Stroke* 46: 948–953, 2015
- 11) Kim BM, Suh SH, Park SI, Shin YS, Chung EC, Lee MH, Kim EJ, Koh JS, Kang HS, Roh HG, Won YS, Chung PW, Kim YB, Suh BC: Management and clinical outcome of acute basilar artery dissection. *AJNR Am J Neuroradiol* 29: 1937–1941, 2008
- 12) Wakhloo AK, Mandell J, Gounis MJ, Brooks C, Linfante I, Winer J, Weaver JP: Stent-assisted reconstructive endovascular repair of cranial fusiform atherosclerotic and dissecting aneurysms: long-term clinical and angiographic follow-up. *Stroke* 39: 3288–3296, 2008
- 13) Jin SC, Kwon DH, Choi CG, Ahn JS, Kwun BD: Endovascular strategies for vertebrobasilar dissecting aneurysms. *AJNR Am J Neuroradiol* 30: 1518–1523, 2009
- 14) Lee BH, Kim BM, Park MS, Park SI, Chung EC, Suh SH, Choi CS, Won YS, Yu IK: Reconstructive endovascular treatment of ruptured blood blister-like aneurysms of the internal carotid artery. *J Neurosurg* 110: 431–436, 2009
- 15) Yu JL, Wang HL, Xu N, Xu K, Wang B, Luo Q: Endovascular treatment of aneurysms arising from the basilar artery trunk and branches. *Interv Neuroradiol* 16: 369–383, 2010
- 16) Bodily KD, Cloft HJ, Lanzino G, Fiorella DJ, White PM, Kallmes DF: Stent-assisted coiling in acutely ruptured intracranial aneurysms: a qualitative, systematic review of the literature. *AJNR Am J Neuroradiol* 32: 1232–1236, 2011

---

*Address reprint requests to:* Satoshi Koizumi, MD, Department of Neurosurgery, The University of Tokyo Hospital, 7-3-1, Hongo, Bunkyo-ku, Tokyo 113-8655, Japan.  
*e-mail:* sakoizumi-tyky@umin.net