

Severe fat-soluble vitamin deficiency suspected secondary to intrahepatic cholestasis of pregnancy: A case report

Minhazur Sarker^{*}, Chloe Getrajdman, Leslie Warren, Lauren Ferrara

Department of Obstetrics, Gynecology and Reproductive Science, Mount Sinai Health System & Icahn School of Medicine at Mount Sinai, New York, NY, 1176 5th Ave 9th Floor, New York, NY 10029, USA

ARTICLE INFO

Keywords:

Bile acids
Case report
Cholestasis
Fat-soluble vitamins
Vitamin K

ABSTRACT

Intrahepatic cholestasis is the most common hepatobiliary complication of pregnancy. Worsening cholestasis, measured by total bile acid levels, has been associated with an increased incidence of adverse fetal outcomes; however, maternal morbidity remains rare. This report highlights a case of severe fat-soluble vitamin deficiency suspected to be secondary to severe cholestasis. Active management with weekly vitamin supplementation and close outpatient follow-up resulted in the delivery of a 32-week healthy neonate. We propose consideration of screening for fat-soluble vitamin deficiency for patients whose pregnancy is complicated by severe cholestasis or early-onset cholestasis.

1. Introduction

Intrahepatic cholestasis of pregnancy (IHCP) typically arises in the third trimester and is characterized by elevated serum total bile acids (TBA). IHCP onset in the first or second trimester is rare and warrants a work-up for other causes of elevated bile acids, such as liver pathology or malabsorption physiology or pathology. Maternal bile acids can cross the placenta, accumulate in the amniotic fluid and fetus, and pose a risk to the fetus via a poorly understood mechanism [1]. Fetal adverse outcomes associated with cholestasis include stillbirth, spontaneous preterm labor, iatrogenic preterm birth, and meconium-stained amniotic fluid [2–4]. With TBA levels $>100 \mu\text{mol/L}$, the risk of stillbirth significantly increases. [3]

Bile acids, primarily cholic acid and chenodeoxycholic acid, are synthesized by the liver and function in the absorption of dietary fats and oils. Not surprisingly, individuals with liver disease often suffer from malabsorption. Although IHCP is a disease of the hepatobiliary system, IHCP-associated maternal adverse outcomes are relatively rare. There are two reported cases of IHCP-associated severe fat-soluble vitamin deficiencies resulting in adverse maternal outcomes [5,6].

In the first reported case, in 2017, the patient presented with signs of preterm labor and hematuria and was found to have elevated INR, undetectable vitamin K, and cholestasis at 24 weeks of gestation [5]. She

was initially managed with vitamin K intramuscular injection and transfusion-mediated coagulopathy correction; however, coagulopathy recurred at 26 weeks followed by spontaneous preterm birth [5]. A second case of IHCP-associated coagulopathy from vitamin K deficiency, diagnosed at 22 weeks, was managed with weekly outpatient vitamin K infusions and the pregnancy resulted in preterm prelabor rupture of membranes and spontaneous preterm labor at 32 weeks [6].

In this report, we present another case of suspected IHCP-induced fat-soluble vitamin deficiency managed with weekly vitamin K infusions, adjuvant rifampin for bile acid reduction, and subsequent planned preterm delivery. As a result of these persistent associations, we propose screening for fat-soluble vitamin deficiency in the setting of early-onset or severe IHCP.

2. Case Presentation

The patient was a 30-year-old woman, para 0-2-1-1, with history notable for one unexplained spontaneous abortion at 16 weeks of gestation complicated by cholestasis with unknown peak TBA, one prior twin stillbirth at 30 weeks of gestation also complicated by cholestasis with unknown peak TBA, and one 29-week live vaginal birth complicated by severe cholestasis (TBA $\geq 200 \mu\text{mol/L}$) and coagulopathy. Her first two pregnancies were managed at outside hospitals and no medical

^{*} Corresponding author at: Department of Obstetrics and Gynecology at Mount Sinai Icahn School of Medicine, Mount Sinai Hospital, 1176 5th Ave 9th Floor, New York, NY 10029, USA.

E-mail addresses: minhazsarker@gmail.com (M. Sarker), chloe.getrajdman3@mountsinai.org (C. Getrajdman), leslie.warren@mountsinai.org (L. Warren), lauren.ferrara@mssm.edu (L. Ferrara).

<https://doi.org/10.1016/j.crwh.2022.e00430>

Received 28 June 2022; Received in revised form 6 July 2022; Accepted 7 July 2022

Available online 9 July 2022

2214-9112/© 2022 The Authors. Published by Elsevier B.V. This is an open access article under the CC BY-NC-ND license (<http://creativecommons.org/licenses/by-nc-nd/4.0/>).

records were available. The patient reported that during the twin pregnancy, she had received two weeks of inpatient management for cholestasis and her admission course was complicated by spontaneous bleeding from mucous membranes, including in the eyes, ears, and mouth, concerning for severe coagulopathy with resultant stillbirth.

During her third pregnancy, she had had baseline testing at 14 weeks

of gestation that had shown normal coagulation markers, bile acids, and hepatic function panel. At 18 weeks of gestation, the patient had reported severe itching including palms and soles. Repeat testing revealed a TBA of 176.6 $\mu\text{mol/L}$. After gastroenterology consultation, an abdominal ultrasound scan and CAT scan revealed no abnormalities and patient history did not warrant any additional work-up. A diagnosis of

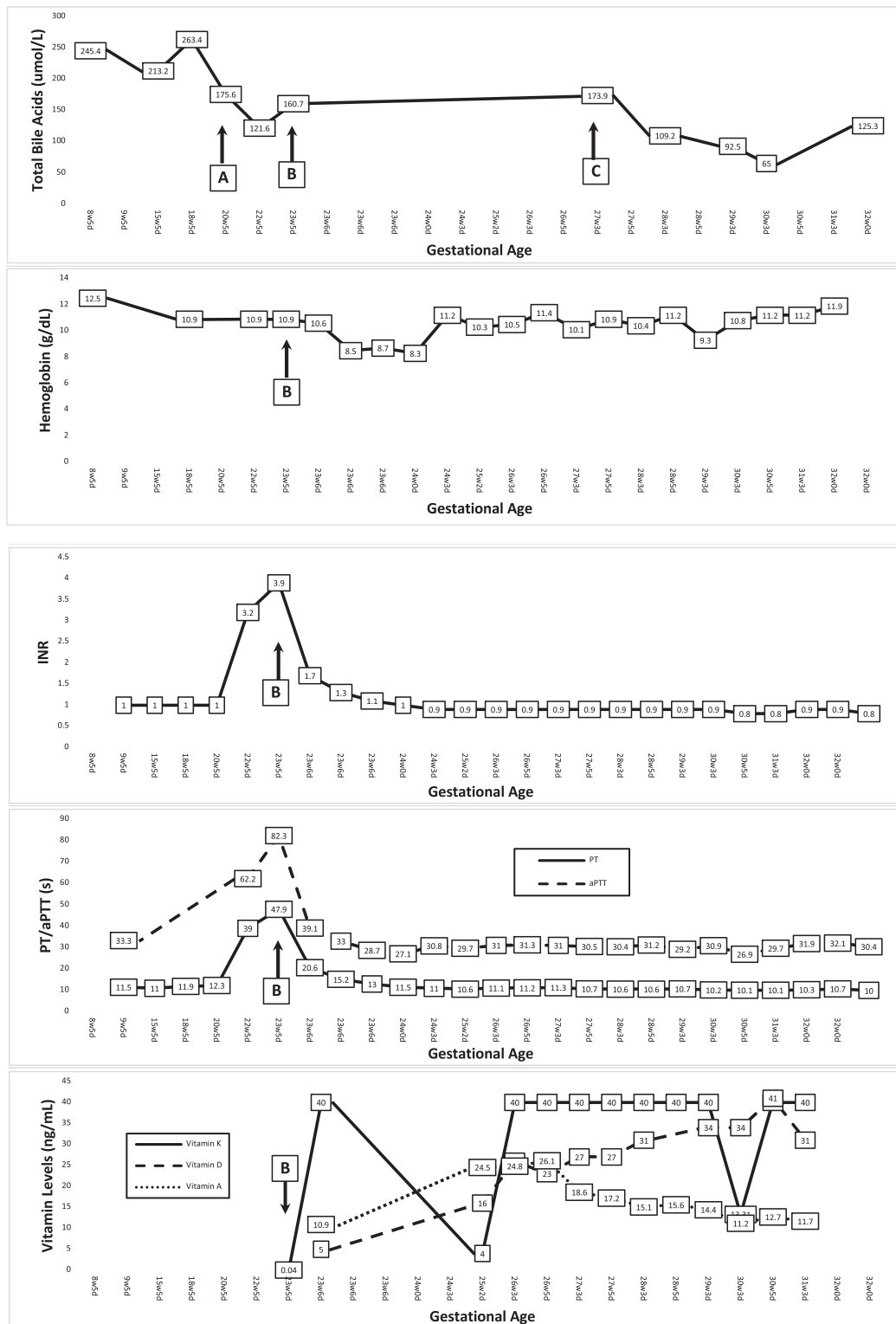


Fig. 1. Laboratory trends of markers of interest throughout intrapartum course. At 20w5d, the patient was started on rifampin (point A). At 23w5d, she presented with hematuria, was diagnosed with coagulopathy, and started on vitamin K treatments (point B). At 27w3d, rifampin was restarted (point C).

severe cholestasis was made and ursodeoxycholic acid therapy was initiated. At 24 weeks of gestation, her pruritus and hepatic function tests continued to worsen, and a plan was made for inpatient admission. No acute events occurred throughout admission until 29 weeks of gestation, when she had an episode of spontaneous bleeding from her lips and gums and new vaginal bleeding. Laboratory testing revealed coagulopathy and thus the patient was induced at 29w5d, resulting in the delivery of a neonate weighing 1250 g. After an uncomplicated NICU admission, the healthy neonate was discharged home. The patient's laboratory abnormalities began normalizing within 2 weeks postpartum and returned to baseline at 10 weeks postpartum. Approximately 1 year postpartum, the patient presented with right upper quadrant abdominal pain and underwent a laparoscopic cholecystectomy.

During her fourth and most recent pregnancy, the patient had initiated care at 8 weeks of gestation, at which time she reported itching on her palms and soles, and baseline tests revealed significantly elevated TBA of 245.4 $\mu\text{mol/L}$, AST of 66 IU/L and ALT of 136 IU/L, and normal coagulation factors. Ursodeoxycholic acid therapy was initiated at 300 mg three times daily and then increased to 600 mg three times daily shortly thereafter. From 8 weeks to 20 weeks of gestation, TBA fluctuated (Fig. 1) but remained elevated. Given her ongoing symptoms and persistent severely elevated TBA, adjuvant rifampin therapy was started at 20 weeks of gestation since this has previously shown success in managing severe TBA elevations in cholestasis [7,8].

At 22w5d, the patient had elevated INR of 3.2 and elevated PT of 39 s and aPTT of 62.2 s but these tests were not reviewed until 23w5d, when she presented to labor and delivery with acute-onset right-flank pain and hematuria. Initial studies revealed worsening coagulation status, with INR of 3.9 and PT of 47.9 s and aPTT of 82.3 s, and she was admitted to the antepartum service for further evaluation. Given the decrease in hemoglobin from 10.6 to 8.5 g/dL, anemia studies were done; these ruled out hemolysis, autoimmune, macrocytic, or microcytic anemia. Further history revealed that although she previously had reported regular bowel movements in her prior pregnancy workup, her "normal" stool was clay colored. Gastroenterology, hematology, and urology teams were consulted. Abdominal and renal ultrasounds were negative for acute pathology, and right-flank pain and hematuria were presumed to be secondary to coagulopathy. Given the clay-colored stools, further testing for hepatitis A, hepatitis B, and hepatitis C was performed, but all results were negative. The patient was not meeting criteria for other causes of fat malabsorption and a plan was made to defer invasive testing such as magnetic resonance cholangiopancreatography or endoscopic retrograde cholangiopancreatography until the postpartum period.

In the setting of elevated INR, vitamin K testing was requested; this showed severe deficiency, with vitamin K of <0.04 ng/mL. 10 units intramuscular vitamin K was administered which quickly corrected her coagulopathy within 24 h (Fig. 1). Additional laboratory studies revealed global fat-soluble vitamin deficiencies, including vitamin A and vitamin D. She was started on vitamin K 10 units intramuscular three times per week and vitamin D 1000 units daily with additional 25,000 units weekly. Owing to multiple case reports of rifampin-associated coagulopathy, rifampin was held on admission [9,10].

After 1 week of coagulation factor, the patient was discharged home and remained on the above regimen. Twice-weekly liver function, coagulation factors (aPTT/PT/INR), and vitamin level monitoring along with twice-weekly non-stress tests and biophysical profiles were used for monitoring. All subsequent testing remained reassuring. At the 27-week visit once IHCP-induced coagulopathy was suspected, rifampin therapy was restarted.

Upon approaching 29 weeks of gestation, the patient began requesting induction of labor at every antenatal encounter in the setting of anxiety regarding prior pregnancy severe cholestasis leading to severe coagulopathy and delivery at 29 weeks. After patient counseling regarding risks and benefits, a plan was made for 32-week induction of labor. At the time of the scheduled induction of labor, her vitamin

studies, coagulopathy factors, and hepatic function tests were all within normal limits and TBA level was 125.3. She underwent an uncomplicated induction of labor resulting in the normal spontaneous delivery of a neonate weighing 1680 g with Apgar scores of 8/9 and no postpartum complications. After an uncomplicated 27-day NICU course, the neonate was discharged in stable condition.

3. Discussion

We present a case of suspected IHCP-induced severe fat-soluble vitamin deficiency. To our knowledge, this is the third report of this adverse association, with this patient having had multiple recurrences. During her third pregnancy, she had presented with early-onset and severe IHCP warranting further work-up for liver and malabsorption etiologies. After imaging revealed no abnormalities and her medical history did not suggest further testing was indicated, she was managed as a severe case of IHCP. At 2 weeks postpartum, her laboratory marker abnormalities began normalizing, which remained consistent with IHCP. Although we are not able to objectively show complete normalization until 10 weeks postpartum, this was limited by the patient's inability to present for another visit and thus it is unclear whether her physiology normalized sooner than the 10-week mark. During the postpartum period, after discussion with gastroenterology, hematology, and maternal-fetal medicine teams, a plan was made to defer any additional work-up unless clinically indicated.

During her most recent pregnancy's symptomatic presentation with hematuria, the differential diagnosis included urinary tract infection, pyelonephritis, nephrolithiasis, other urinary tract pathology, and liver or IHCP-associated coagulopathy. After thorough work-up which helped delineate etiology, IHCP-associated coagulopathy was presumed by diagnosis of exclusion. Additionally, the rapid correction of her coagulopathic state with vitamin K supplementation was also consistent with prior reports [6]. Given her history of iatrogenic preterm birth in the setting of severe coagulopathy at 29 weeks, joint decision making resulted in her electing to undergo risk-reducing preterm induction of labor at 32 weeks of gestation.

In terms of pathophysiology, cholestasis causes reduced enterohepatic circulation of bile acids, which may result in decreased absorption of fat-soluble vitamins [5]. Specifically, impaired bile acid secretion disrupts the patient's ability to emulsify and absorb fatty acids in the small intestine, ultimately resulting in fat-soluble vitamin deficiencies. This patient's clay-colored stool is suggestive of a possible baseline malabsorption. Outside of pregnancy, her baseline malabsorption produced no clinically apparent symptoms; however, the increased physiologic demands of pregnancy and onset of cholestasis likely led to the fat-soluble vitamin deficiencies producing a severely coagulopathic state. Differential diagnosis for her baseline malabsorption included biliary cirrhosis, sclerosing cholangitis, gallstones, viral infectious etiology, structural anomalies (ex. strictures), malignancy, and medication side-effects. Given her work-up and management noted above, differential diagnosis now included mild structural anomalies or sclerosing cholangitis leading to narrowing of the bile duct. Shortly after her most recent pregnancy, the patient underwent a laparoscopic bilateral salpingectomy for permanent sterilization and did not wish to pursue in-vitro fertilization. Her bile acid levels normalized similarly to the third pregnancy postpartum course and the plan will be for invasive testing if clinically indicated per gastroenterology.

In the setting of other malabsorption physiology such as bariatric surgery, both the American College of Obstetricians and Gynecologists and the Royal College of Obstetricians and Gynaecologists recommend screening for iron, calcium, vitamin D, and vitamin B deficiencies. The Royal College of Obstetricians and Gynaecologists further recommends screening for vitamin A, vitamin B12, vitamin K, and folate deficiencies. Extrapolating from this recommendation and considering multiple emerging cases of suspected IHCP-induced fat-soluble vitamin deficiency, we propose screening for fat-soluble vitamin deficiencies in

pregnancies complicated by mid-trimester IHCP or severe IHCP (TBA $\geq 100 \mu\text{mol/L}$). This screening intervention has the potential to diagnose clinically significant vitamin deficiencies and allow for therapeutic intervention prior to onset of severe coagulopathy and progression to possible disseminated intravascular coagulation or other adverse outcomes.

4. Conclusion

With this report, we highlight an additional rare incidence of suspected severe IHCP-induced fat-soluble vitamin deficiency. As a result of persistent occurrence of this adverse outcome, we propose routine baseline screening and monitoring for fat-soluble vitamin deficiency in women whose pregnancy is complicated by severe IHCP (TBA $\geq 100 \mu\text{mol/L}$) or mid-trimester early-onset IHCP. This intervention may help predict the onset of adverse outcomes, including coagulopathy. Additionally, the findings in this case help validate the effectiveness of rifampin in lowering total bile acid levels.

5. Patient Perspective

During my last pregnancy, I delivered a healthy baby despite all my complications related to cholestasis. Because of this, I returned for treatment by the same medical team since I believe they are the reason I have a healthy child. For this pregnancy, I remained anxious throughout its entirety, especially after I had my initial scare with blood in my urine. Although it was difficult for me to come in two to three times per week for clinic appointments, vitamin K treatments, ultrasounds, and blood tests, I trusted that my medical team was doing everything to ensure another healthy delivery. Since my last pregnancy had complications at 29 weeks, I began asking to be delivered around that time but the benefits of waiting until at least 32 weeks to allow the baby to grow were discussed. I am happy to say that my baby was discharged home from the NICU at 36 weeks and is healthy. I could not be more thankful to the doctors that took care of me and my newborn baby.

Contributors

Minhazur Sarker participated directly in patient care, performed the literature review, and authored the manuscript and all revisions.

Chloe Getrajdman participated directly in patient care, prepared the case summary, and participated in manuscript writing and revisions.

Leslie Warren assisted in all aspects of manuscript writing and revisions.

Lauren Ferrara primarily managed the patient and actively participated in every step of manuscript writing and revision.

Funding

No funding from an external source supported the publication of this case report.

Patient consent

Informed and written consent was obtained from the patient prior to formulation of this case report.

Provenance and peer review

This article was not commissioned and was peer reviewed.

Conflict of interest statement

The authors declare that they have no conflict of interest regarding the publication of this case report.

References

- [1] V. Geenes, A. Lövgren-Sandblom, L. Benthin, et al., The reversed Feto-maternal bile acid gradient in intrahepatic cholestasis of pregnancy is corrected by ursodeoxycholic acid, *PLoS One* 9 (1) (2014), e83828, <https://doi.org/10.1371/JOURNAL.PONE.0083828>.
- [2] L. Brouwers, M.P.H. Koster, Godelieve, et al., Intrahepatic cholestasis of pregnancy: maternal and fetal outcomes associated with elevated bile acid levels, *Am. J. Obstet. Gynecol.* 212 (2015) 100.e1–100.e7, <https://doi.org/10.1016/j.ajog.2014.07.026>.
- [3] C. Ovadia, P.T. Seed, A. Sklavounos, et al., Association of adverse perinatal outcomes of intrahepatic cholestasis of pregnancy with biochemical markers: results of aggregate and individual patient data meta-analyses, *Lancet.* 393 (10174) (2019) 899–909, [https://doi.org/10.1016/S0140-6736\(18\)31877-4](https://doi.org/10.1016/S0140-6736(18)31877-4).
- [4] T. Kawakita, L.I. Parikh, P.S. Ramsey, et al., Predictors of adverse neonatal outcomes in intrahepatic cholestasis of pregnancy, *Am. J. Obstet. Gynecol.* 213 (4) (2015) 570.e1, <https://doi.org/10.1016/J.AJOG.2015.06.021>.
- [5] M. Maldonado, A. Alhousseini, M. Awadalla, et al., Intrahepatic Cholestasis of Pregnancy Leading to Severe Vitamin K Deficiency and Coagulopathy, Published online, 2017, <https://doi.org/10.1155/2017/5646247>.
- [6] A.C. Mahle, B.D. Morris, Z. Frazer, C. Novak, Severe vitamin deficiencies in pregnancy complicated by progressive familial intrahepatic cholestasis, *BMJ Case Rep.* 14 (2021), 240248, <https://doi.org/10.1136/bcr-2020-240248>.
- [7] V. Geenes, J. Chambers, R. Khurana, et al., Rifampicin in the Treatment of Severe Intrahepatic Cholestasis of Pregnancy, 2022, <https://doi.org/10.1016/j.ejogrb.2015.03.020>.
- [8] J. Liu, A.M. Murray, E.B. Mankus, K.E. Ireland, O.M. Acosta, P.S. Ramsey, Adjuvant use of rifampin for refractory intrahepatic cholestasis of pregnancy, *Obstet. Gynecol.* 132 (3) (2018) 678–681, <https://doi.org/10.1097/AOG.0000000000002794>.
- [9] F. Sampaziotis, W.J.H. Griffiths, Letter to the Editors Severe Coagulopathy Caused by Rifampicin in Patients with Primary Sclerosing Cholangitis and Refractory Pruritus, Published online, 2011, <https://doi.org/10.1111/j.1365-2125.2011.04158.x>.
- [10] R. Tiperneni, F. Khalid, H. Fichadiya, A. Al-Alwan, G.H.F. Mohan, View of deranged haemostasis: rifampin-induced coagulopathy, *Eur. J. Case Rep. Intern. Med.* 9 (2022), https://doi.org/10.12890/2022_003380. Accessed July 5, 2022.