



Comparison of artifacts between paste and collodion method of electrode application in pediatric EEG



Danielle Brigham^a, Yash Shah^a, Kanwaljit Singh^b, Ivan Pavkovic^a, Shefali Karkare^a, Sanjeev V. Kothare^{a,*}

^aDepartment of Pediatrics, Cohen Children's Medical Center, NY, USA

^bDepartment of Pediatrics, University of Massachusetts Medical School, MA, USA

ARTICLE INFO

Article history:

Received 31 July 2019

Received in revised form 7 November 2019

Accepted 8 November 2019

Available online 30 November 2019

Keywords:

Collodion

Paste

EEG artifacts

ABSTRACT

Objectives: Children pose challenges to obtain quality EEG data due to excessive artifact. Collodion is used in EEG electrodes due to its water resistance and strong adhesive qualities. This study was done to evaluate differences in artifacts between the collodion and paste method.

Methods: 115 subjects (children age >3 years) were randomized into paste and collodion groups and artifacts evaluated at baseline and every hour over 30 s increments. Age, sleep state, and number of electrodes with artifact were also documented. *T*-test was performed to determine differences in the various parameters between the two groups.

Results: 61 subjects were in the paste group and 54 in the collodion group. Mean of total seconds of artifact from 0 to 24 h were 41.8 s in paste group versus 30.3 s in collodion group (**P = 0.02**). Children >11 years old had less artifact than younger children from 0 to 24 h (24.3 versus 41.2 s, **P = 0.03**), and from 24 to 48 h (33.1 versus 43.1 s, **P = 0.03**). There was a significant effect of sleep vs. awake state recordings on artifact from 0 to 24 h (30.3 versus 50.2 s, **P = 0.01**).

Conclusion: Electrode problems are common with both collodion and paste in prolonged AEEG monitoring. However, for studies less than 24 h, collodion may be a better alternative.

Significance: Our study provides evidence that in some cases collodion may be a better alternative to paste in terms of decreased artifacts.

© 2019 International Federation of Clinical Neurophysiology. Published by Elsevier B.V. This is an open access article under the CC BY-NC-ND license (<http://creativecommons.org/licenses/by-nc-nd/4.0/>).

1. Introduction

The EEG is an invaluable tool in neurology, especially in the evaluation for seizure and epilepsy. Long-term recordings, in the form of video EEG (VEEG) or ambulatory EEG (AEEG), are gold standard and extremely helpful in diagnosis and treatment. Either study can be difficult to perform in the pediatric age group, where the record is marred with significant artifact. It is easier to perform EEGs in an inpatient setting, when the patient is monitored, and the EEG technicians can reapply electrodes if removed. However, VEEG is not cost effective, as the AEEG costs 51–65% less than a 24-hour inpatient VEEG (Foley et al., 2000) and is often denied by insurance. Plus, it needs hospital resources which might not be present at smaller centers. Thus, the AEEG may be the only option available. Unfortunately, this may be problematic in chil-

dren as the electrode connection degrades with time and may give significant artifact.

This artifact can be caused by various reasons; however major contributors in the pediatric population include difficulty keeping pediatric patients motionless while applying the leads, and keeping the electrodes secured on the patient's head. Pediatric patients tend to have co-morbidities of intellectual disability and behavioral problems as well; this can make it even more difficult to get an accurate EEG study. As excessive artifact can limit the overall quality of the study, could the usage of a particular adhesive for EEG lead placement reduce the amount of artifact?

According to the American Clinical Neurophysiology Society Guidelines, EEG electrodes can be applied with paste or collodion. Kuratani et al. (2016) Collodion is water resistance and has strong adhesive qualities. It works while drying due to the evaporation of ethyl ether; the nitrocellulose forms a secure film bonding the electrode to the skin and hair. These properties make it ideal for applying electrodes in EEG studies. Unfortunately, a common complaint about collodion usage is the smell of ethyl ether (Mavidon Inc., 2009), and as per US OSHA guidelines, a specialized fume extraction apparatus is needed to decrease the amount of ethyl

* Corresponding author at: Department of Pediatrics, Cohen Children's Medical Center, Pediatric Neurology Service Line for Northwell Health, Zucker School of Medicine at Hofstra/Northwell, 2001 Marcus Avenue, Suite W290, Lake Success, NY 11042, USA.

E-mail address: skothare@northwell.edu (S.V. Kothare).

ether exposure (Young et al., 1993). Additionally, collodion is flammable and needs to be properly stored and managed appropriately for any spillage (Mavidon Inc., 2009). Although collodion is an effective adhesive material, the strong odor and need for caution in its usage makes it not universally used for EEG electrode connection.

The objective of this study was to compare the usage of collodion versus traditional conductive paste in adhering AEEG electrodes. We hypothesized that the use of collodion would decrease the amount of artifact seen in the AEEG studies. Another hypothesis was that older children would be less likely to interfere in eeg equipment and thus have less artifacts.

2. Methods

This was a prospective study, evaluating artifact on AEEG studies obtained in an ambulatory (outpatient) setting in the pediatric population from November 2017 until March 2018. Data was obtained by review of AEEG studies after Institutional Review Board approval. 115 subjects who completed an AEEG at an urban tertiary care children's hospital were evaluated.

The subjects were randomized into a traditional paste group (Elefix Conductive EEG paste by Nippon Coviden) or a collodion group in a 1:1 ratio. A block randomization method was used. Standard application of EEG using the international 10–20 system was performed in both groups. There were a total of 19 electrodes applied, and they were kept in place using a net. EEG technicians were not aware of the purpose of the study and why they were asked to use paste or collodion in different patients.

Inclusion criteria included pediatric subjects scheduled for a 24–48 h AEEG study and impedance at hook up within acceptable range (1–5 K Ω). Exclusion criteria included subjects with extreme behavioral issues or aggressive behavior Children <3 years old were also excluded from the study, as it has been the EEG technician's experience that these children have more skin breakdown and ulceration from the collodion.

EEGs were analyzed by 2 blinded epileptologists, using a referential montage. Three 10 s epochs were assessed at baseline and every 1 h of the study subsequently. The total number of seconds of artifact was documented at every time point. The number of electrodes affected by artifact, and sleep-wake state were also documented as well as age of the subjects.

Data analysis was performed to compare amount of artifact seen with the paste group compared to the collodion group. Secondary analysis was performed to determine impact of both age, sleep/wake state, and duration of study on amount of artifact. T-test was performed to detect any difference between number of electrodes involved and seconds of artifact at each point of time between paste and collodion group. Kappa analysis using interclass correlation coefficient was performed to assess differences between the two blinded EEG reviewers.

3. Results

61 subjects were in the traditional paste group and 54 subjects in the collodion group. The mean age in the paste group was 10 years old versus 11 years old in the collodion group. Fifty-four percent (31/61) of subjects in paste group were male, vs. 48% in collodion group (26/54).

The mean of total electrodes with artifact from 0 to 24 h was 8.2 electrodes in the paste group versus 7.1 electrodes in the collodion group ($P = 0.012$), and 5.5 electrodes vs. 6.2 electrodes from 24 to 48 h ($P = 0.52$; Table 1). Mean of total seconds of artifact from 0 to 24 h was 41.8 s in paste group versus 30.3 s in collodion group ($P = 0.02$), and 57.7 s versus 52.5 s from 24 to 48 h ($P = 0.69$).

There was a significant effect of age on seconds of artifact, at all time-points. Older children (age >11 years old) had less artifact than young children (age <11 years old) from 0 to 24 h (24.3 s versus 41.2 s, $P = 0.026$), and from 24 to 48 h (33.1 s versus 43.1 s, $P = 0.03$; Fig. 1). There was also a significant effect of sleep on seconds of artifact from 0 to 24 h (30.3 s during sleep versus 50.2 s during awake state, $P = 0.01$; Fig. 1). Seconds of artifact did not differ significantly between sleep and awake state from 24 to 48 h (53.3 s versus 66.2 s, $P = 0.07$). (Table 1).

Average measure Interclass Correlation Coefficient (ICC) was 0.835 with a 95% confidence interval from 0.369 to 0.938, $p < 0.001$ to indicate that the findings from the two EEG reviewers were statistically similar.

4. Discussion

The results of the study have shown that electrode problems are common with both collodion and traditional conductive paste in prolonged AEEG monitoring. After 24 h of recording, both the paste and collodion groups had similar amounts of artifact measured in seconds and equivalent number of electrodes involved (Fig. 1). But in subjects with less than 24 h of AEEG monitoring, the collodion group had fewer seconds of artifact and decreased number of electrodes involved, both statistically significant.

Artifacts were observed less in older children (>11 year old) from 0 to 24 h, and from 24 to 48 h. Similarly, decreased artifact was observed during sleep state from 0 to 24 h but not in subjects with over 24 h of recording.

There are limited studies available to assess the degree of artifact present during EEG monitoring using different electrode applications, especially in the pediatric population.

Young et al. (2006) compared collodion-applied electrodes versus subdermal wire electrodes for 10 comatose Intensive Care Unit (ICU) subjects. Artifacts were measured (60 Hz and other types) between both groups, and impedance at the end of the study was also noted. The collodion group had more artifact compared to the subdermal wire electrode group. The collodion group also had worsened impedance (Young et al., 2006). However, it is important to note that the American Clinical Neurophysiology Society advises against the use of wire electrodes (Kuratani et al., 2016).

Another study by Falco et al. (2005) monitored 40 adult subjects with drug-resistant epilepsy for long-term video EEG monitoring. Patients were divided into 2 groups: collodion versus an EC2[®] paste. Impedance was measured initially and at 24 h into the study. The collodion group had greater impedance values at both the beginning and end. Paste time was also less in the EC2[®] paste group (Falco et al., 2005). They recommended that EC2[®] paste may substitute collodion in electrode placement for long-term video EEG monitoring.

Finally, another study analyzed how the impedance changed over time with two commonly used gels (EC2[®] paste versus Ten-20[®] paste) using tripolar concentric ring electrodes (Wigton and Besio, 2009). Electrodes were attached to a signal generator and a 30 Hz signal with amplitude of 500 mV was applied to the circuit. Ten experiments were run to acquire ten sets of data for each paste. The Ten-20[®] paste had a higher impedance, but remained at a fairly consistent impedance throughout the test. The EC2[®] paste had lower impedance, and showed a decrease in impedance over time. They concluded that the EC2[®] paste made the most sense as an experimental paste; as it created lower impedance values, however further work needs to be performed to validate the results on humans.

There are also limited studies regarding the best technique for prolonged EEG studies. One study by Lau et al. (2011) performed

Table 1
Artifact in collodion and paste groups.

	Collodion		Paste		p-value
Mean Total Electrodes Involved 0–48 h (SD)	10.4 (4.1)	61	9.8 (4.8)	54	0.434
Mean Total Electrodes Involved 0–24 h (SD)	8.2 (1.9)	61	7.1 (2.4)	54	0.012
Mean Total Electrodes Involved 24–48 h (SD)	5.5 (3.7)	25	6.2 (3.7)	23	0.522
Mean Total Seconds of Artifact from 0 to 48 h (SD)	61.1 (57.4)	61	57.5 (41.9)	54	0.717
Mean Total Seconds of Artifact from 0 to 24 h (SD)	30.3 (27.9)	61	41.8 (32.8)	54	0.02
Mean Total Seconds of Artifact from 24 to 48 h (SD)	57.7 (44.3)	25	52.5 (36.2)	23	0.698

Bold values indicate statistically significant values (<0.05).

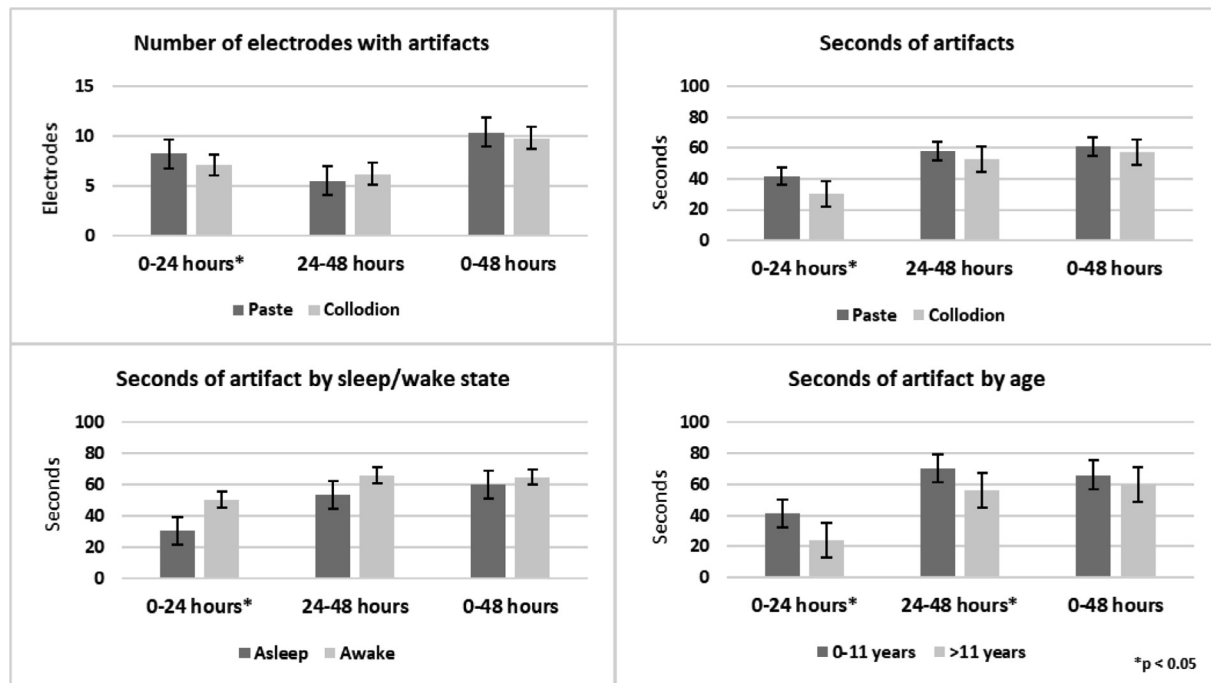


Fig. 1. Bar charts showing artifacts in collodion and paste groups.

a prospective study evaluating 100 adult inpatient subjects receiving prolonged EEG (Lau et al., 2011). They were randomized into 4 different groups: collodion-Ten20[®] (electrode paste), collodion-Elefix[®] (electrode paste), Hypafix[®] (medical tape)-Ten20[®], and Hypafix[®]-Elefix[®]. Collodion-Ten20[®] had the longest hook up time, but lowest number of electrode repairs. Hypafix[®]-Ten20[®] had the shortest hook up time; Hypafix[®]-Elefix[®] had the highest number of patients needing electrode repairs. They concluded that collodion-Ten20[®] should be used for studies >24 h, while Hypafix[®] would be more suitable for routine EEG studies.

There are no studies available comparing amounts of artifact or best technique in children in the ambulatory setting.

4.1. Future work

The data must be interpreted in the appropriate clinical context. The cause of artifact could not be determined due to lack of simultaneous video recording.

EC2[®] paste is another option used for electrode application and prior studies have shown EC2[®] superior to collodion in impedance and time to hook up (Falco et al., 2005). This could be further assessed, comparing EC2[®] paste, traditional paste, and collodion in a larger study in the future.

5. Conclusion

We have shown that electrode problems are common with both collodion and traditional paste in prolonged AEEG monitoring in the pediatric population, particularly as the study duration increases. However, for shorter AEEG monitoring (less than 24 h), collodion may be a better alternative over conductive paste to reduce artifact in this age group and obtain better quality recording. More artifact was also observed in younger children (<11 year old) and during the awake state. It remains to be determined if EC2[®] paste is better than collodion in reducing artifact in studies >24 h in pediatric AEEGs.

Declaration of Competing Interest

The authors declare that they have no known competing financial interests or personal relationships that could have appeared to influence the work reported in this paper.

References

- Falco, C., Sebastiano, F., Cacciola, L., Orabona, F., Ponticelli, R., Stirpe, P., et al., 2005. Scalp electrode placement by EC2 adhesive paste in long-term video-EEG monitoring. *Clin. Neurophysiol.* 116 (8), 1771–1773.

- Foley, C.M., Legido, A., Miles, D.K., Chandler, D.A., Grover, W.D., 2000. Long-term computer-assisted outpatient electroencephalogram monitoring in children and adolescents. *J. Child Neurol.* 15 (1), 49–55.
- Kuratani, J., Pearl, P.L., Sullivan, L., Riel-Romero, R.M., Cheek, J., Stecker, M., et al., 2016. American Clinical Neurophysiology Society guideline 5: minimum technical standards for pediatric electroencephalography. *J. Clin. Neurophysiol.* 33 (4), 320–323.
- Lau, R.R., Powell, M.K., Terry, C., Jahnke, D., 2011. Neurotelemetry electrode application techniques compared. *Am. J. Electroneurodiagnostic Technol.* 51 (3), 165–182.
- Mavidon Inc., Collodion Safety Guideline; 2009. Available from: https://www.mvamed.com/MSDS_Forms/CollodionSafety.pdf. [Accessed 26 July 2019].
- Wigton, R.L., Besio, W.G., 2009. Differential impedance testing of EC2[®] and Ten-20[®] adhesive paste for tripolar concentric electrodes. In: IEEE 35th Annual Northeast Bioengineering Conference. Cambridge, MA, pp. 1–2.
- Young, B., Blais, R., Campbell, V., Covacich, D., Demelo, J., Leitch, G., et al., 1993. Vapors from collodion and acetone in an EEG laboratory. *J. Clin. Neurophysiol.* 10 (1), 108–110.
- Young, G.B., Ives, J.R., Chapman, M.G., Mirsattari, S.M., 2006. A comparison of subdermal wire electrodes with collodion-applied disk electrodes in long-term EEG recordings in ICU. *Clin. Neurophysiol.* 117 (6), 1376–1379.