

## Isolated Unilateral Agenesis of Pulmonary Artery and Reappraisal of Embryological Evolution

### INTRODUCTION

The isolated unilateral agenesis of the unilateral pulmonary artery (UAPA) is a very rare anomaly, with a prevalence of 1 in 200 000 population. This abnormality was first described by Frenzel in 1868.<sup>1</sup> According to the existing nomenclature of pharyngeal arches, this abnormality occurs as a result of early resorption of the proximal part of the right sixth arch leading to the failure of connection between the right pulmonary artery and pulmonary trunk.<sup>2</sup> However, there remains confusion as regards to the definite nomenclature of pharyngeal arches in humans.

### CASE REPORT

A 29-year-old man presented with a history of intermittent chest pain for the last 2 years radiating to the left arm without any relationship to exertion. On examination, his heart rate was 98 bpm and his blood pressure was 124/82 mm Hg. The cardiovascular and respiratory examination did not reveal any significant abnormality. On radiography of the chest, the right hemithorax appeared small and the left lung showed signs of hyperinflation. His electrocardiogram (ECG) was normal except for mild tachycardia. (Figure 1A) The stress Myocardial Perfusion Imaging (MPI) done showed mild reversible defect involving ~5% of left ventricular myocardium in Left Anterior Descending Artery (LAD) territory. (Figure 1B) Coronary angiography revealed a large collateral arising from the left circumflex (LCx) and supplying the right lung (Figure 1C; Video 1). The selective angiogram of the right subclavian artery revealed systemic collaterals arising from the right subclavian, right internal mammary, and lateral-thoracic artery (Figure 1D,E; Videos 2 and 3). The pulmonary angiogram showed the absence of the right pulmonary artery (RPA) (Figure 2C, Video 4). The computed tomography angiography demonstrated the absence of RPA and a diverticulum of the right brachiocephalic artery (Figure 2D, E).

### DISCUSSION

The UAPA is a very rare anomaly. The majority of such cases have RPA agenesis as in our case. In the majority of cases, the intraparenchymal part is supplied by the systemic collaterals, but collaterals may arise from coronaries also.<sup>3</sup> The majority of the patients remain asymptomatic and do not require any specific treatment; however, some may develop angina and heart failure due to the steal phenomena which might necessitate the closure of the coronary collaterals.<sup>3-5</sup> Regarding management of this anomaly, the asymptomatic patients do not require any treatment. However, patients with recurrent hemoptysis and pulmonary infections may need pneumonectomy or lobectomy. Our patient did not have any significant symptoms and so he was reassured.<sup>6</sup>

The embryological development of pharyngeal arches in humans has remained a matter of controversy for a long time. As per the existing nomenclature, the pharyngeal arches have been numbered as 1-4 and 6. According to this nomenclature, the early resorption of the proximal part of the sixth arch leads to the failure of connection between RPA and pulmonary trunk. However, there has been consistent criticism of the presence of 6 arches. The reasons cited for this odd numbering were that there is a transient fifth pharyngeal arch present during development, which

### CASE REPORT



Jeet Ram Kashyap

Suraj Kumar

Sreenivas Reddy

Raghavendra Rao K

Lipi Uppal

Department of Cardiology, Government Medical College & Hospital, Chandigarh, India

#### Corresponding author:

Suraj Kumar

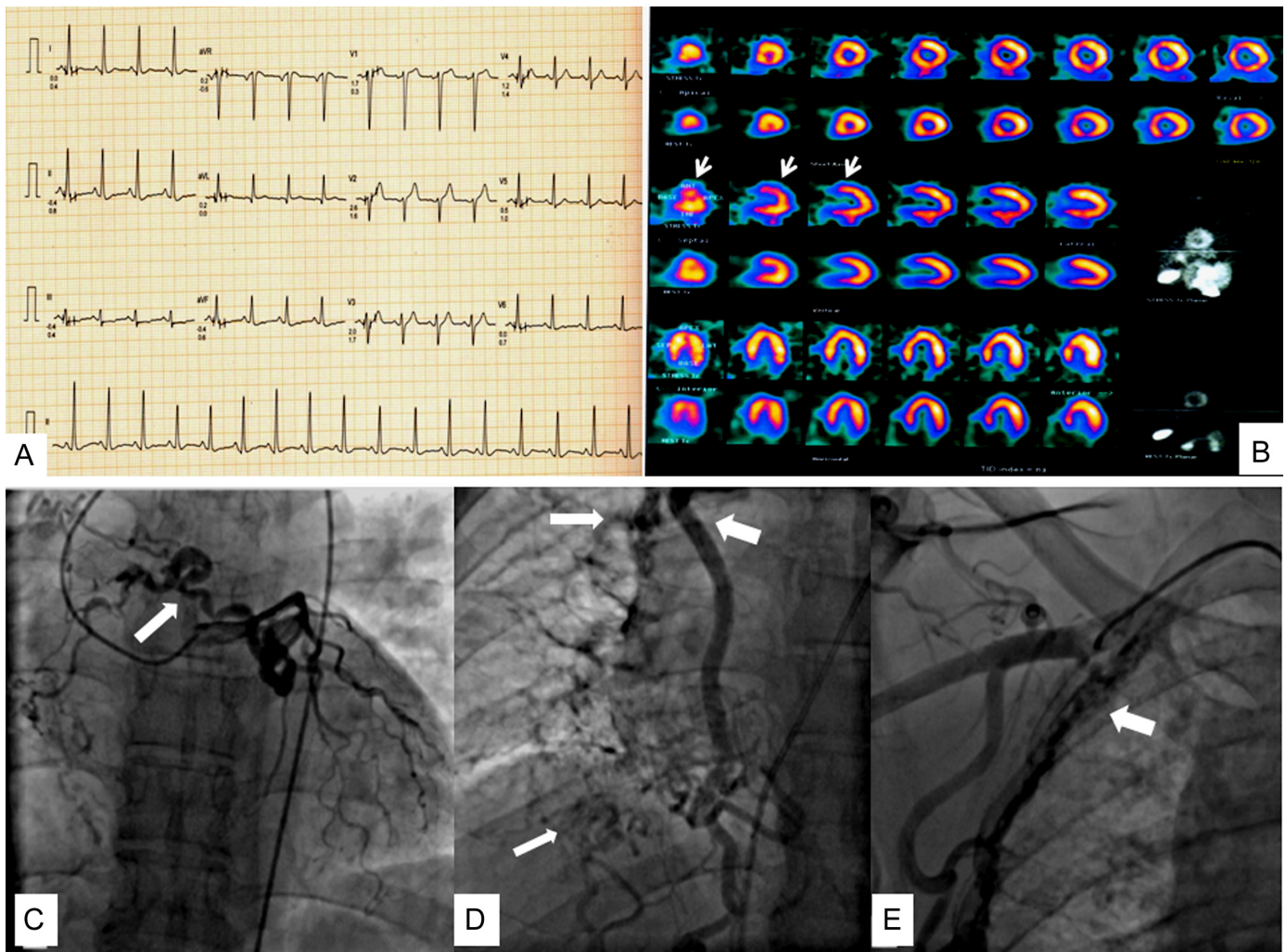
drskarora87@gmail.com

**Cite this article as:** Kashyap JR, Kumar S, Reddy S, K RR, Uppal L. Isolated unilateral agenesis of pulmonary artery and reappraisal of embryological evolution. *Anatol J Cardiol.* 2022;26(3):226-228.

DOI:10.5152/AnatolJCardiol.2021.465



Copyright@Author(s) - Available online at anatoljcardiol.com.  
Content of this journal is licensed under a Creative Commons Attribution-NonCommercial 4.0 International License.



**Figure 1. (A) Electrocardiogram normal except for tachycardia, (B) stress MPI showing a very little ~5% reversible defect in LAD territory, (C) left coronary angiogram showing large collateral arising from LCx and supplying the branches of RPA, (D) systemic collaterals from right internal mammary artery and (E) from the lateral-thoracic artery. (All collaterals shown by white arrows). ECG, electrocardiogram; LCx, left circumflex.**

regresses as the embryo grows, and second, such numbering represents the evolutionary considerations.<sup>7</sup> However, to date, there is no convincing evidence for this theory. Graham et al<sup>7</sup>, in their review, have proposed to name the pharyngeal arches simply from 1 to 5; however, Anderson et al<sup>8</sup> suggested naming the pharyngeal arches as 1-4 and the last arch as pulmonary arch so as to minimize the confusion.

During normal embryogenesis, the distal right terminal arch disappears, and the distal left terminal arch forms the ductus arteriosus. Pfefferkorn et al<sup>2</sup> first described the diverticulum of the brachiocephalic artery and linked it to this developmental anomaly. In our patient, the proximal RPA got obliterated by early resorption of the proximal right terminal arch. The persistence of the distal right terminal arch links the distal RPA to the right dorsal aorta, the primitive brachiocephalic artery. Late closure of the distal right terminal arch, a vessel histologically identical to the contralateral ductus arteriosus, creates RPA discontinuity and the brachiocephalic artery diverticulum (Figure 2A,B).

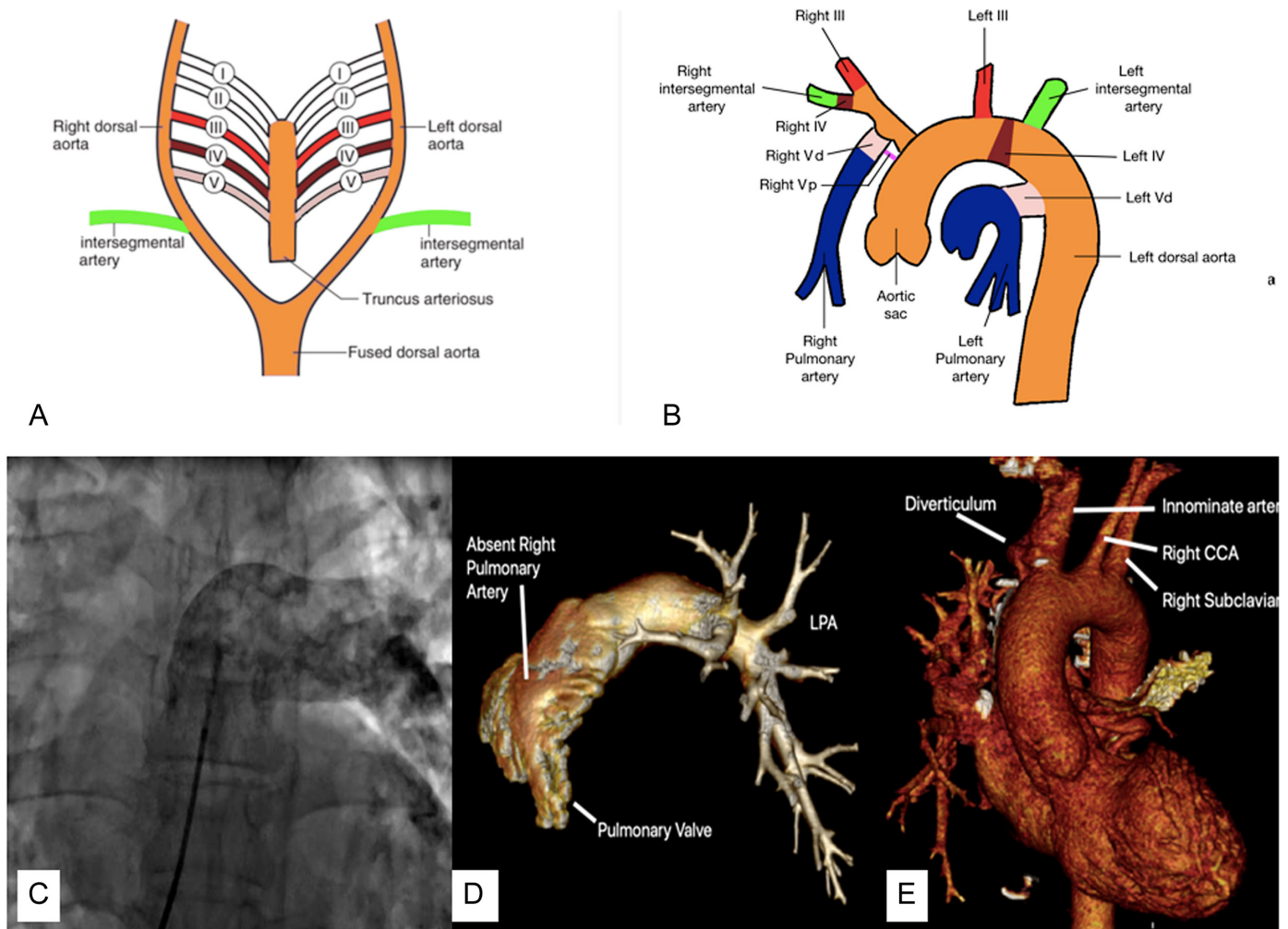
## CONCLUSION

Isolated agenesis of the unilateral pulmonary artery results from early resorption of the proximal part of the right terminal arch, causing interruption of connection with the pulmonary trunk. We emphasize that the numbering of the pharyngeal arches in amniotes should be done as 1-4 and the terminal arch be named as "pulmonary arch" so as to minimize the confusion regarding this odd numbering of 1-4 and then sixth arch.

**Informed Consent:** Written informed consent was obtained from all participants who participated in this study.

**Video 1:** Coronary angiogram in Antero-posterior (AP) Caudal view showing large collateral supplying the right lung.

**Video 2:** Right internal mammary artery angiogram in AP view showing a collateral(s) predominantly supplying the lower lobe right lung.



**Figure 2.** (A) The proposed 5 primitive aortic arches, the first and second arch disappear during early fetal life, (B) left aortic arch and absent right pulmonary artery. The proximal part of the terminal arch (herein being referred to as fifth arch) disappears early. The distal part of the terminal aortic arch originates from the innominate artery near its base, and obliterate after birth, leaving the diverticulum of innominate artery, (C) angiogram of the main pulmonary trunk with filling of the left pulmonary artery (LPA) only and complete absence of RPA, (D) volume-rendered 3D reconstruction of multidetector computed tomography (MDCT) image demonstrating the absence of the RPA and (E) MDCT and 3D reconstruction shows diverticulum of the innominate artery. RPA, right pulmonary artery.

**Video 3:** Right subclavian artery angiogram in AP view showing collaterals from lateral-thoracic artery supplying the outer border of the right lung.

**Video 4:** Pulmonary angiogram showing opacification of left pulmonary artery only and the absence of right pulmonary artery.

## REFERENCES

1. Fraentzel O. Ein Fall von anormer Communicationder aorta mit der arteria pulmonalis. *Archiv f pathol Anat.* 1868;43(3):420-426. [CrossRef]
2. Pfefferkorn JR, Löser H, Pech G, Toussaint R, Hilgenberg F. Absent pulmonary artery: a hint to its embryogenesis. *Pediatr Cardiol.* 1982;3(4):283-286. [CrossRef]
3. Kruzliak P, Syamasundar RP, Novak M, Pechanova O, Kovacova G. Unilateral absence of pulmonary artery: pathophysiology, symptoms, diagnosis and current treatment. *Arch Cardiovasc Dis.* 2013;106(8-9):448-454. [CrossRef]
4. Bockeria LA, Makhachev OA, Khiriev TKh, Abramyan MA. Congenital isolated unilateral absence of pulmonary artery and variants of collateral blood supply of the ipsilateral lung. *Interact Cardiovasc Thorac Surg.* 2011;12(3):509-510. [CrossRef]
5. Wang P, Yuan L, Shi J, Xu Z. Isolated unilateral absence of pulmonary artery in adulthood: a clinical analysis of 65 cases from a caseseriesandsystematicreview. *J ThoracDis.* 2017;9(12):4988-4996. [CrossRef]
6. Jariwala P, Maturu VN, Christopher J, Jadhav KP. Congenital isolated unilateral agenesis of pulmonary arteries in adults: case series and review. *Indian J Thorac Cardiovasc Surg.* 2021;37(Suppl 1):144-154. [CrossRef]
7. Graham A, Poopalasundaram S, Shone V, Kiecker C. A reappraisal and revision of the numbering of the pharyngeal arches. *J Anat.* 2019;235(6):1019-1023. [CrossRef]
8. Anderson RH, Bamforth SD, Gupta SK. How best to describe the pharyngeal arch arteries when the fifth arch does not exist? *Cardiol Young.* 2020;30(11):1708-1710. [CrossRef]