

Case Reports

Injection into the Longus Colli Muscle via the Thyroid Gland

Małgorzata Tyślerowicz^{1*} & Wolfgang H. Jost²¹Department of Neurophysiology, Copernicus Memorial Hospital, Łódź, PL, ²Parkinson-Klinik Ortenau, Wolfach, DE

Abstract

Background: Anterior forms of cervical dystonia are considered to be the most difficult to treat because of the deep cervical muscles that can be involved.

Case Report: We report the case of a woman with cervical dystonia who presented with anterior sagittal shift, which required injections through the longus colli muscle to obtain a satisfactory outcome. The approach via the thyroid gland was chosen.

Discussion: The longus colli muscle can be injected under electromyography (EMG), computed tomography (CT), ultrasonography (US), or endoscopy guidance. We recommend using both ultrasonography and electromyography guidance as excellent complementary techniques for injection at the C5-C6 level.

Keywords: Anterior sagittal shift, longus colli, thyroid gland, sonography, electromyography

Citation: Tyślerowicz M, Jost WH. Injection into the longus colli muscle via the thyroid gland. Tremor Other Hyperkinet Mov. 2019; 9. doi: 10.7916/tohm.v0.718

*To whom correspondence should be addressed. E-mail: mtyślerowicz@wp.pl

Editor: Elan D. Louis, Yale University, USA

Received: August 13, 2019; **Accepted:** October 24, 2019; **Published:** December 6, 2019

Copyright: © 2019 Tyślerowicz and Jost. This is an open-access article distributed under the terms of the Creative Commons Attribution–Noncommercial–No Derivatives License, which permits the user to copy, distribute, and transmit the work provided that the original authors and source are credited; that no commercial use is made of the work; and that the work is not altered or transformed.

Funding: None.

Financial Disclosures: None.

Conflicts of Interest: The authors report no conflicts of interest.

Ethics Statement: This study was performed in accordance with the ethical standards detailed in the Declaration of Helsinki. All patients have provided written informed consent.

Background

Cervical dystonia (CD) is the most common form of focal dystonia in adults,¹ characterized by involuntary sustained or intermittent neck-muscle contractions, resulting in abnormal phasic or tonic movements or posture of the head.² Botulinum neurotoxin (BoNT) injections are considered the first-line of treatment for CD due to its high degree of effectiveness and safety in approximately 80–85% of the patients, as has been demonstrated in numerous controlled clinical studies.^{3–12} Pain can be a prominent symptom in 68–75% of cases and may cause significant disability.¹³ According to the Col-Cap concept, we can recognize 11 (8+3) phenomenological forms of CD.¹⁴ Patients may present with head/neck movements in three planes: coronal, sagittal, or transverse, resulting in turning, tilting, flexion, extension, or a combination of these postures. Prominent anterocollis occurs in about 25% of CD cases and may be either primary or secondary.² Anterior forms of CD are considered the most difficult to treat because of the deep cervical muscles that can be involved.¹⁵ Injections of superficial cervical flexor muscles, such as sternocleidomastoid (SCM), anterior/middle scalene (AS/MS), or levator scapulae (LS), can be only occasionally effective in that variant of CD.

We find that longus colli (LCo) injections with fluoroscopy,¹⁶ computed tomography (CT),^{17,18} electromyography (EMG)¹⁹ or ultrasonography (US) guidance²⁰ give satisfying results. Endoscopic guidance can also be used for targeting the upper part of this muscle.²¹ Anterior Sagittal Shift (ASS), known as “goose neck,” is a special form of CD that combines anterocollis and retrocaput. There are different treatment protocols. On the basis of the Col-Cap concept, we should choose the muscles involved in these two forms of CD.²² We can also find another suggestion based on EMG functional guidance and inject both SCM and splenius capitis muscles.¹⁹ We will now describe an injection into the longus colli muscles via the thyroid gland in a patient with ASS.

Case report

The patient is a 60-year-old woman who presents with cervical dystonia. The onset was in 2002 and started with neck pain, then she noticed flexion of the neck. We diagnosed ASS (Figure 1A). The patient provided written consent to publish her images. The patient underwent several treatment sessions with BoNT injections into her neck muscles under EMG and/or US control without any significant improvement. She had

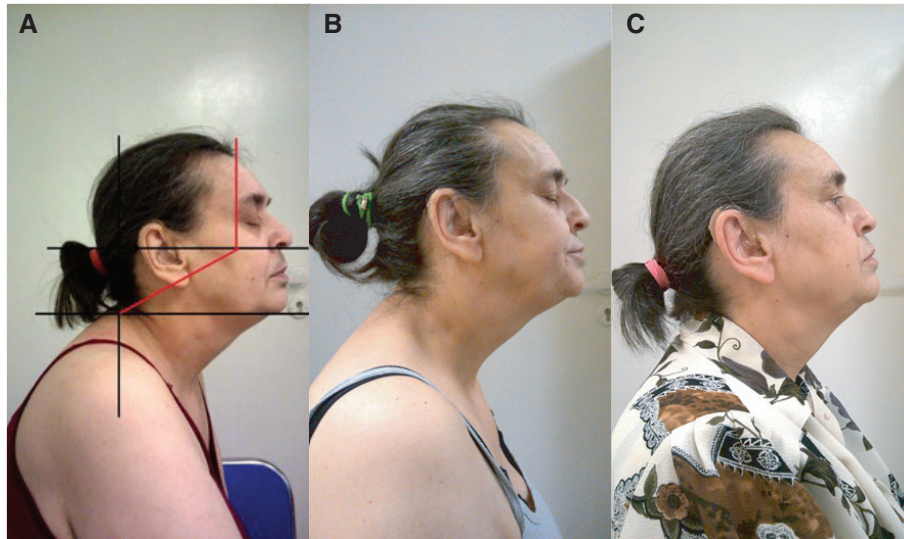


Figure 1. Progress in Patient. (A) Patient before BoNT. (B) Patient at 4 weeks after BoNT injection with only slight improvement regarding retrocaput. (C) Patient at 4 weeks after the injection.

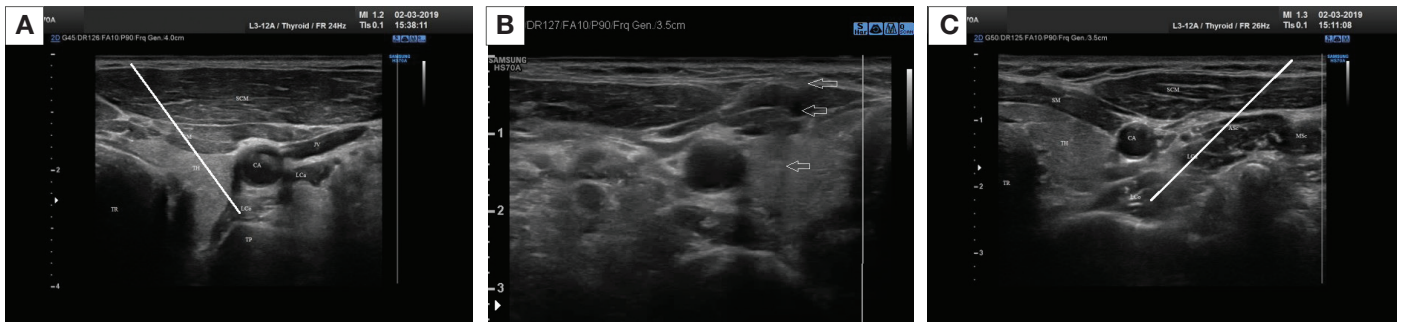


Figure 2. Ways of Approaching Used in US-guided LCo Injections. (A) Medial approach of the injection of LCo via the thyroid gland. (B) Arrows show the path of the needle via the thyroid gland. (C) Lateral approach of the injection of LCo via SCM and the anterior scalene muscle.

an approximately 20% reduction in pain, with only slight improvement regarding the head position (retrocaput) (Figure 1B). We attempted different combinations of target muscles. On the basis of COL-CAP concept, we injected middle scalene, levator scapulae, obliquus capitis inferior (OCI), semispinalis capitis, and trapezius muscles, and, based on the experience of other researchers in this form of CD, both SCM and splenius capitis muscles as well. There was no difference in the final result between these sessions. We used onabotulinumtoxin A in a total dose of 200 U in each session. Because of unsatisfactory results, we decided to inject the longus colli muscle. The patient was placed supine on the examination table. The potential risks of side effects, such as bleeding, damage to other structures, or dysphagia, were explained to the patient. The longus colli was visualized with a 12.5 MHz linear US transducer. We decided to use the medial approach via the thyroid gland (Figure 2A and B). Using US guidance and an EMG

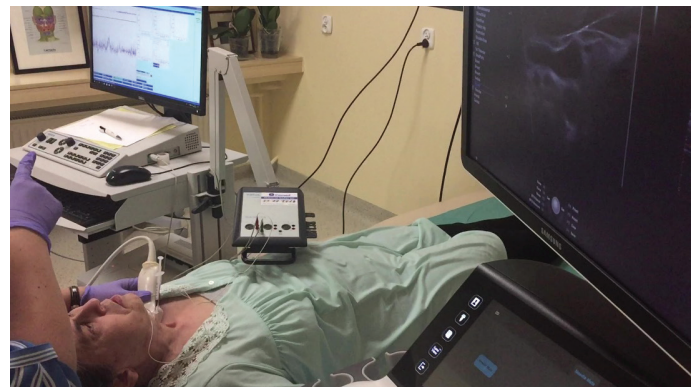


Figure 3. Simultaneous Use of Both Methods. Longus colli activation in EMG while the patient flexed the neck.

injection needle (26 G × 50 mm), onabotulinumtoxin A was injected 15 U per side (Figure 3). The dose was chosen based on the recommendations of the botulinum toxin atlas and other published experiences, in which 60 U of abobotulinumtoxin A was used on each side,¹⁹ 30–35 U of abobotulinumtoxin A unilaterally,¹⁷ or 25 U of abobotulinumtoxin A on one side and 10 U on the other side.²⁰ Based on the publication,¹⁹ in which seven patients with “goose neck” dystonia were reported, both sternocleidomastoids and splenius capitis presented increased dystonic activity on EMG. In addition to both longus colli muscles, we also injected both SCM (each 30 U) and both splenius capitis (each 30 U). The splenius capitis muscles act as extensors of the head, and there is no risk injecting them to worsen anterocollis. After 4 weeks, the patient presented significant improvement (Figure 1C). There were no side effects.

Discussion

BoNT injections are the first-line of treatment for CD with a high response rate and low incidence of adverse effects.^{3–12}

Since examinations of the muscle using imaging techniques were started,¹⁴ we have witnessed the introduction of the so-called Col-Cap concept, which is the classification of the phenomenological forms into 11 variants. Among them, the anterior forms (anterocaput and anterocollis) are the most difficult to treat¹⁵ because of the deep cervical muscles that are very often involved. Injecting of these deep lying muscles carries the risk of damage to neighboring structures, such as blood vessels, nerves or the esophagus. ASS is a specific type of CD involving neck flexion (anterocollis) and head extension (retrocaput). The longus colli muscle is a deep neck muscle situated on the anterior surface of the vertebral column between the atlas and the third thoracic vertebra. It is broad in the middle part and narrow at either end and consists of three portions: A superior and an inferior oblique and a vertical one. The Longus Colli muscle (LCo) can be treated under fluoroscopy,¹⁶ CT,^{17,18} EMG,¹⁹ or US²⁰ control approximately at the fifth neck vertebra level by BoNT injection in the pars obliqua inferior and the pars recta. In one of the studies, neurobotulinum toxin treatment under CT-guided injections was rated to be good or very good by only three out of eight patients (37.5%) with severe antecaput and/or antecollis.¹⁸ Six out of eight patients reported on dysphagia, whereas one patient developed a small hematoma at the place where the tip of the needle had been inserted, resulting in mild dysphagia. In another paper, one case injected with the same guidance was presented, in which treatment was repeated several times and the patient reported subjective improvement of his anterocollis of about 40%.¹⁷ Only the second injection led to mild dysphagia, which was completely reversible after 4 weeks. No other side effects were noted. In another study, a total of 10 injection sessions were performed on three patients under fluoroscopy guidance.¹⁶ In two patients whose main complaint was neck pain, marked improvement in pain relief was observed. In the third patient, who had prominent motor symptoms but no pain, a 20–30% motor improvement was reported. All patients complained about mild post-procedure injection site discomfort and one patient reported a sore throat lasting several days. Swallowing difficulties were reported after two of the 10 injections and were related

to higher doses of BoNT. Potential drawbacks in this method of guidance are X-ray exposure and allergic contrast agent reactions.

Injection of LCo under EMG guidance can be effective and safe as is presented in the published cases¹⁹ of the two double-chin patients with bilateral suprahyoid, SCM, and LCo injections. During the review at 4 weeks postinjection, the mean subjective improvement observed was from 50 to 80%. Neck flexor weakness was observed in one patient, who complained of difficulty in lifting her head from the pillow in the first 3 weeks. In one case, which applied the same methods, that is, injection of the LCo muscle under both EMG and US control, pain and posture improvement without side effects was reported.²⁰ The injection of the pars obliqua superior of the LCo requires endoscopic guidance.²¹ There are two percutaneous approaches, the medial and lateral, depending on individual patient anatomy. We need US to find the most optimal path to target LCo and avoid damaging surrounding structures.²³ Using a medial approach, we proceed via the thyroid gland, between the carotid sheath and trachea, paying close attention to the esophagus, as well as the inferior and superior thyroid arteries. We have discussed this approach with several ENT and radiologist doctors who deal with thyroid gland biopsy. We can additionally use Doppler technique to visualize arteries and perform laboratory tests assessing coagulation system to decrease the risk of bleeding. When approaching the LCo laterally, the needle is guided laterally to the carotid sheath but medially to the anterior scalene to avoid traversing the phrenic nerve (Figure 2C). The lateral approach is performed going through the anterior scalene muscle. The drawback of this method is that the placement of the EMG needle tip is often not visible, so we need EMG as a functional guidance. The patient is positioned supine, and the EMG needle is inserted under US control. To check the correct placement of the needle tip, we ask the patient to flex the neck expecting the proper EMG sound reflecting muscle activation. In the case described here, we had to change the needle position to a deeper level to get an adequate acoustic response. This is the reason why we recommend using both EMG and US guidance. Even though both of these techniques are simultaneously in use, we must of course be aware that the injection of longus colli muscle carries some risk, which is why we should try to minimize it. Of course, numerous cases of subjects undergoing this procedure without adverse effects would make a more reliable and convincing argument; however, for now, we can share our experience with only one such case. Once more subjects have been treated in this way, we will be glad to share our observations and conclusions.

References

1. Norris SA, Jinnah HA, Espay AJ, Klein C, Brüggemann N, Barbano RL, et al. Clinical and demographic characteristics related to onset site and spread of cervical dystonia: onset site and spread of cervical dystonia. *Mov Disord* 2016;31(12):1874–1882. doi: 10.1002/mds.26817
2. Jankovic J, Leder S, Warner D, Schwartz K. Cervical dystonia: clinical findings and associated movement disorders. *Neurology* 1991;1;41(7):1088–1091. doi: 10.1212/wnl.41.7.1088
3. Tsui JK, Eisen A, Mak E, Carruthers J, Scott A, Calne DB. A pilot study on the use of botulinum toxin in spasmodic torticollis. *Can J Neurol Sci* 1985;12(4): 314–316. doi: 10.1017/s031716710003540x

4. Greene P, Kang U, Fahn S, Brin M, Moskowitz C, Flaster E. Double-blind, placebo-controlled trial of botulinum toxin injections for the treatment of spasmodic torticollis. *Neurology* 1990;40(8):1213–1218. doi: 10.1212/wnl.40.8.1213
5. Brans JWM, Lindeboom R, Snoek JW, Zwarts MJ, van Weerden TW, Brunt ER, et al. Botulinum toxin versus trihexyphenidyl in cervical dystonia: a prospective, randomized, double-blind controlled trial. *Neurology* 1996;46:1066–1107. doi: 10.1212/wnl.46.4.1066
6. Lew MF, Adornato BT, Duane DD, Dykstra DD, Massey JM, Brin MF, et al. Botulinum toxin type B: a double-blind, placebo-controlled, safety and efficacy study in cervical dystonia. *Neurology* 1997;49:701–707. doi: 10.1212/wnl.49.3.701
7. Poewe W, Deuschl G, Nebe A, Feifel E, Wissel J, Benecke R, et al. What is the optimal dose of botulinum toxin A in the treatment of cervical dystonia? Results of a double blind, placebo controlled, dose ranging study using Dysport. *J Neurol Neurosurg Psychiatry* 1998;64(1):13–17. doi: 10.1136/jnnp.64.1.13
8. Brashear A, Lew MF, Dykstra DD, Comella CL, Factor SA, Rodnitzky RL, et al. Safety and efficacy of NeuroBloc (botulinum toxin type B) in type A-responsive cervical dystonia. *Neurology* 1999;53(7):1439–1446. doi: 10.1212/wnl.53.7.1439
9. Truong D, Duane DD, Jankovic J, Singer C, Seeberger LC, Comella CL, et al. Efficacy and safety of botulinum type A toxin (Dysport) in cervical dystonia: results of the first US randomized, double-blind, placebo-controlled study. *Mov Disord* 2005;20(7):783–791. doi: 10.1002/mds.20403
10. Truong DD, Jost WH. Botulinum toxin: clinical use. *Parkinsonism Relat Disord* 2006;12(6):331–355. doi: 10.1016/j.parkreldis.2006.06.002
11. Benecke R, Jost WH, Kanovsky P, Ruzicka E, Comes G, Grafe S. A new botulinum toxin type A free of complexing proteins for treatment of cervical dystonia. *Neurology* 2005;64:1949–1951. doi: 10.1212/01.WNL.0000163767.99354.C3
12. Comella CL, Jankovic J, Shannon KM, Tsui J, Swenson M, Leurgans S, et al. Comparison of botulinum toxin serotypes A and B for the treatment of cervical dystonia. *Neurology* 2005;65(9):1423–1429. doi: 10.1212/01.wnl.0000183055.81056.5c
13. Comella CL. The treatment of cervical dystonia with botulinum toxins. *J Neural Transm* 2008;115(4):579–583. doi: 10.1007/s00702-007-0831-4
14. Reichel G. Cervical dystonia: a new phenomenological classification for botulinum toxin therapy. *Basal Ganglia* 2011;1(1):5–12. doi: 10.1016/j.baga.2011.01.001
15. Finsterer J, Maeztu C, Revuelta GJ, Reichel G, Truong D. Collum-caput (COL-CAP) concept for conceptual anterocollis, antero-caput, and forward sagittal shift. *J Neurol Sci* 2015;355(1–2):37–43. doi: 10.1016/j.jns.2015.06.015
16. Glass GA, Ku S, Ostrem JL, Heath S, Larson PS. Fluoroscopic, EMG-guided injection of botulinum toxin into the longus colli for the treatment of anterocollis. *Parkinsonism Relat Disord* 2009;15(8):610–613. doi: 10.1016/j.parkreldis.2009.01.006
17. Herting B, Wunderlich S, Glöckler T, Bendszus M, Mucha D, Reichmann H, et al. Computed tomographically-controlled injection of botulinum toxin into the longus colli muscle in severe anterocollis. *Mov Disord* 2004;19(5):588–590. doi: 10.1002/mds.10704
18. Heffer H, Blondin D, Kahlen U, Moll M, Antoch G, Schek J. CT-guided intramuscular botulinum toxin A injections into the deep anterior neck muscles in patients with pure antecaput or antecollis. *Basal Ganglia* 2012;2(2):97–101. doi: 10.1016/j.baga.2012.03.003
19. Flowers JM, Hicklin LA, Marion M-H. Anterior and posterior sagittal shift in cervical dystonia: a clinical and electromyographic study, including a new EMG approach of the longus colli muscle. *Mov Disord* 2011;26(13):2409–2414. doi: 10.1002/mds.23905
20. Allison SK, Odderson IR. Ultrasound and electromyography guidance for injection of the longus colli with botulinum toxin for the treatment of cervical dystonia. *Ultrasound Q* 2016;32(3):302–306. doi: 10.1097/RUQ.0000000000000226
21. Reichel G, Stenner A, von Sanden H, Herrmann L, Feja C, Löffler S. Endoscopic-guided injection of botulinum toxin into the longus capitis muscle and into the obliquus superior part of the longus colli muscle in dystonic antecaput: our experience. *Basal Ganglia* 2016;6(2):97–100. doi: 10.1016/j.baga.2016.01.007
22. Tatu L, Jost WH. Anatomy and cervical dystonia: “Dysfunction follows form.” *J Neural Transm* 2017;124(2):237–243. doi: 10.1007/s00702-016-1621-7
23. Schramm A, Bäumer T, Fietzek U, Heitmann S, Walter U, Jost WH. Relevance of sonography for botulinum toxin treatment of cervical dystonia: an expert statement. *J Neural Transm* 2015;122(10):1457–1463. doi: 10.1007/s00702-014-1356-2