

Staphylococcus aureus Endocarditis as a Complication of Toxocariasis-Associated Endomyocarditis With Fibrosis: A Case Report

Esther Kuenzli,¹ Niklaus Labhardt,² Gianmarco Balestra,³ Maja Weisser,⁴ Michael J. Zellweger,⁵ and Johannes Blum²

¹Division for Infectious Diseases and Hospital Epidemiology, University Hospital Basel and Swiss Tropical and Public Health Institute, Basel, ²Swiss Tropical and Public Health Institute, Basel, ³Medical Intensive Care Unit, ⁴Division for Infectious Diseases and Hospital Epidemiology, and ⁵Department of Cardiology, University Hospital Basel, Switzerland

Complications associated with *Toxocara canis* infection are rare. We present a case of a patient with *Staphylococcus aureus* endocarditis as a complication of an endomyocardial fibrosis caused by *T canis*. The epidemiological, pathological, and clinical features of this rare complication are described here.

Keywords. endocarditis; endomyocardial fibrosis; *Staphylococcus aureus*; *Toxocara* species.

CASE REPORT

In March 2013, a 45-year-old male patient presented to a hospital in Switzerland with fatigue, generalized joint aches, and loss of appetite. Due to an eosinophilia of >8000/ μ L (normal, <300/ μ L), a screening for helminthiasis was done using an in-house enzyme-linked immunosorbent assay. It revealed a positive titer for *Toxocara* spp of 1.75 optical density ([OD] normal, <0.5 OD). In the transthoracic echocardiography, endocardial fibrosis was suspected, leading to the diagnosis of toxocariasis-associated endomyocarditis. A computer tomography of the chest and abdomen showed a splenomegaly and an increased number of normal-sized mediastinal and retroperitoneal lymph nodes. Treatment with albendazole 400 mg twice daily for 14 days and prednisone 90 mg once daily for 5 days was prescribed. During hospitalization, a right subclavian vein thrombosis was diagnosed, warranting oral anticoagulation.

Three months later, eosinophilia was still 800/ μ L. A second treatment course with albendazole was evaluated. Before it

could be applied, the patient presented with acute fever and general malaise.

At admission, he was febrile without apparent focus. The white blood cell count was 4.3×10^9 /L (normal, $4\text{--}10 \times 10^9$ /L), and C-reactive protein was 26 mg/L (<10 mg/L). Transesophageal echocardiography (TEE) showed a mobile structure in the left ventricular apex (Figure 1). For a presumed infective endocarditis, intravenous antibiotic therapy with amoxicillin plus clavulanic acid 2.2 g 6 times/day plus gentamycin 90 mg 3 times/day was started. All blood cultures drawn at admission showed growth of *Staphylococcus aureus*, leading to the diagnosis of staphylococcal endocarditis, most likely facilitated by the toxocariasis-induced endomyocardial fibrosis because the thrombus was in the apex, not on the valves. Therapy was adapted to flucloxacillin 2 g 6 times/day plus gentamycin 140 mg twice a day according to resistance testing.

Within hours of admission, the patient developed septic shock and respiratory failure. Repeated TEE showed a decreased left ventricular systolic function and a large left ventricular thrombus, increasing in size despite full anticoagulation. On day 7, it filled up the apical 50% of the left ventricle. Parts of it were highly mobile (Figure 1), causing multiple septic emboli.

The eosinophils increased from 73/ μ L on day 2 to 736/ μ L on day 8. Because septic shock is usually associated with decreased eosinophils and simultaneously the titer for *Toxocara* spp was 1.04 OD (see Figure 2), we assumed a persisting *Toxocara* spp infection. Because ongoing endocardial inflammation would facilitate continuous appositional thrombus growth, a second treatment course with albendazole 400 mg 3 times daily for 4

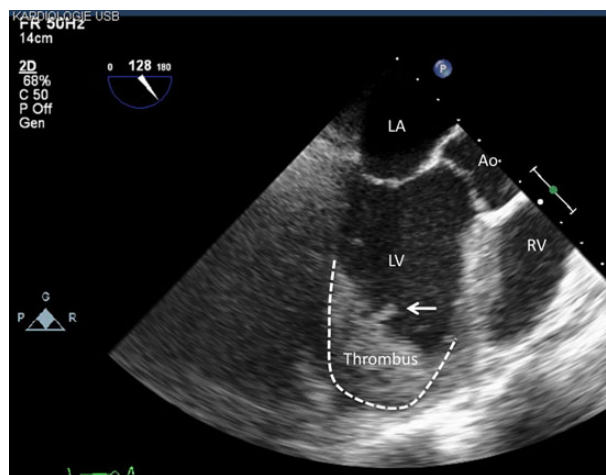


Figure 1. Transesophageal echocardiography: left ventricular apical thrombus. Abbreviations: Ao, aorta; LA, left atrium; LV, left ventricle; RV, right ventricle.

Received 24 March 2016; accepted 11 July 2016.

Correspondence: E. Kuenzli, Swiss Tropical and Public Health Institute, Socinstrasse 57, Basel 4051, Switzerland (esther.kuenzli@unibas.ch).

Open Forum Infectious Diseases®

© The Author 2016. Published by Oxford University Press on behalf of the Infectious Diseases Society of America. This is an Open Access article distributed under the terms of the Creative Commons Attribution-NonCommercial-NoDerivs licence (<http://creativecommons.org/licenses/by-nc-nd/4.0/>), which permits non-commercial reproduction and distribution of the work, in any medium, provided the original work is not altered or transformed in any way, and that the work is properly cited. For commercial re-use, please contact journals.permissions@oup.com. DOI: 10.1093/ofid/ofw145

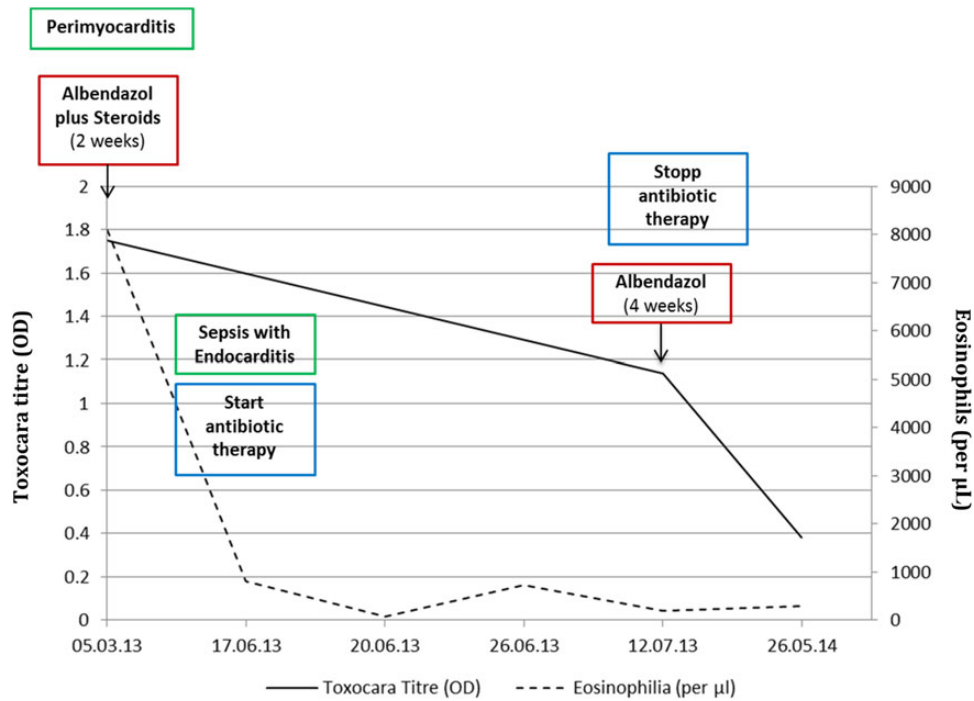


Figure 2. Serological titer and eosinophil count over time. Abbreviation: OD, optical density.

weeks was started. Antibiotic treatment was continued for a total of 6 weeks.

Echocardiographic follow up 6 weeks after completion of antibiotic therapy and 4 weeks after completion of albendazole therapy showed complete resolution of the thrombus. Ten months later, parallel titration for *Toxocara* spp showed a

titer of 0.38 OD. Eosinophils were 300/µL, and left ventricular ejection fraction and diastolic function had normalized (Figure 3).

DISCUSSION

The patient showed unusual complications of a *Toxocara* spp infection. Toxocariasis is a helminth infection of dogs and cats; however, humans are accidental hosts. Most infected humans are asymptomatic, but fever, hepatosplenomegaly, gastrointestinal, respiratory, neurological, and ocular symptoms or allergic reactions can occur [1, 2]. Clinically relevant cardiac manifestations, even though rare in humans, include myocarditis, pericarditis, Loeffler's endocarditis, and combinations of these [3]. The diagnosis is usually based on clinical symptoms, eosinophilia and serological titers.

The clinical entity described in our patient is not only consistent with previous case reports [4, 5], but it can be explained by pathophysiological processes associated with toxocariasis [6–9]: as in idiopathic hypereosinophilic syndrome, infiltration of the myocardium by eosinophils leads to focal myocyte necrosis. The resulting fibrosis is a risk factor for subsequent thrombosis [6, 10]. In addition, peripheral blood eosinophilia caused by parasitic infections can cause hypercoagulable states, favoring thrombosis [9, 11]. The patient not only suffered from a right subclavian vein thrombosis when toxocariasis was first diagnosed, but he showed a growing apical thrombus despite full anticoagulation during the second bout of illness.

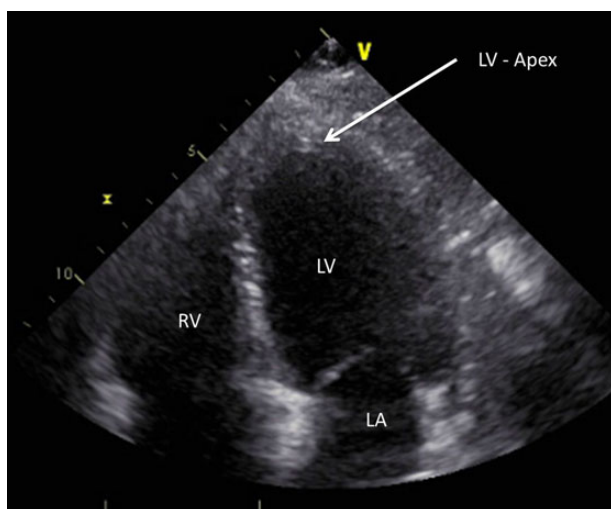


Figure 3. Transthoracic echocardiography (at follow up). Abbreviations: LA, left atrium; LV, left ventricle; RV, right ventricle.

Furthermore, an association between helminth and staphylococcal infections has been described. Different potentially causative mechanisms are discussed in the literature: (1) increased histamine and immunoglobulin E levels together with eosinophilia impair neutrophil function [12, 13]; (2) bacteria could be trapped in the granulomas around the larvae; and (3) common genetic defects predisposing not only for nematode infections but for staphylococcal infections as well have been postulated [8].

CONCLUSIONS

The case illustrates the difficulty of assessing therapeutic responses in infections with no clearly defined clinical and laboratory endpoints. In these situations, treatment success has to be evaluated by indirect parameters such as eosinophilia and course of serologic titers. Repeated and prolonged treatment may be considered if eosinophilia and/or serology remain elevated.

Acknowledgments

Potential conflicts of interest. All authors: No reported conflicts. All authors have submitted the ICMJE Form for Disclosure of Potential Conflicts of Interest.

References

1. Despommier D. Toxocariasis: clinical aspects, epidemiology, medical ecology, and molecular aspects. *Clin Microbiol Rev* **2003**; 16:265–72.
2. Holland C, Smith H, eds. *Toxocara: The Enigmatic Parasite*. Wallingford, Oxfordshire, UK: CABI Publishing; **2006**.
3. Kuenzli E, Neumayr A, Chaney M, Blum JA. Toxocariasis-associated cardiac disease - a systematic review of the literature. *Acta Tropica* **2016**; 154:107–20.
4. De Cock C, Lemaitre J, Deuvaert FE. Löeffler endomyocarditis: a clinical presentation as right ventricular tumor. *J Heart Valve Dis* **1998**; 7:668–71.
5. Traboulsi R, Boueiz A, Kanj SS. Catastrophic aortic thrombosis due to *Toxocara* infection. *Scand J Infect Dis* **2006**; 39:283–5.
6. Cookston M, Stober M, Kayes SG. Eosinophilic myocarditis in CBA/J mice infected with *Toxocara canis*. *Am J Pathol* **1990**; 136:1137–45.
7. Schaffer SW, Dimayuga ER, Kayes SG. Development and characterization of a model of eosinophil-mediated cardiomyopathy in rats infected with *Toxocara canis*. *Am J Physiol* **1992**; 262(5 Pt 2):H1428–34.
8. Moreira-Silva SF, Leite AL, Brito EF, Pereira FE. Nematode infections are risk factors for staphylococcal infection in children. *Mem Inst Oswaldo Cruz* **2002**; 97:395–9.
9. Ames PR, Aloj G, Gentile F. Eosinophilia and thrombosis in parasitic diseases: an overview. *Clin Appl Thromb Hemost* **2011**; 17:33–8.
10. Corradi D, Vaglio A, Maestri R, et al. Eosinophilic myocarditis in a patient with idiopathic hypereosinophilic syndrome: insights into mechanisms of myocardial cell death. *Hum Pathol* **2004**; 35:1160–3.
11. Rohrbach MS, Wheatley CL, Slifman NR, Gleich GJ. Activation of platelets by eosinophil granule proteins. *J Exp Med* **1990**; 172:1271–4.
12. Davis SD, Schaller J, Wedgwood RJ. Job's syndrome. Recurrent, "cold", staphylococcal abscesses. *Lancet* **1966**; 1:1013–5.
13. Caldwell K, Lobell M, Coccia PF. Mitogenic response to *Toxocara* antigen and chemotactic defect in visceral larva migrans. *Am J Dis Child* **1980**; 134:845–7.