

Acute Myeloid Leukemia With *RBM15-MKL1* Presenting as Severe Hepatic Failure

Global Pediatric Health
Volume 4: 1–5
© The Author(s) 2017
Reprints and permissions:
sagepub.com/journalsPermissions.nav
DOI: 10.1177/2333794X16689011
journals.sagepub.com/home/gph



Yoshiko Nakano, MD¹, Kai Yamasaki, MD¹, Yasunori Otsuka, MD¹,
Atsushi Ujio, MD¹, Rie Kawakita, MD¹, Nobuyoshi Tamagawa, BSc¹,
Keiko Okada, MD, PhD¹, Hiroyuki Fujisaki, MD, PhD¹,
Tohru Yorifuji, MD, PhD¹, and Junichi Hara, MD, PhD¹

Received December 6, 2016. Accepted for publication December 11, 2016.

Case Report

A 1-month-old girl was transferred to our hospital with marked abdominal distension. She was born to a healthy mother at 39 weeks' gestation, and her postnatal course was unremarkable. On admission, she was afebrile and exhibited hepatomegaly with considerable ascites, causing respiratory failure. Her laboratory results on admission were as follows: white blood cells, $42.5 \times 10^9/L$ with 1.5% atypical blast cells, 66% neutrophils, and 16.5% lymphocytes; hemoglobin, 10.9 g/dL; platelets, $18 \times 10^9/L$; aspartate aminotransferase, 944 U/L; alanine aminotransferase, 390 U/L; total bilirubin, 3.5 mg/dL; direct bilirubin, 2.1 mg/dL; lactate dehydrogenase, 2783 U/L; fibrinogen, not detected; fibrinogen degeneration product, 69.1 g/mL; and ferritin, 12 610 g/L. An enhanced computed tomography (CT) showed prominent hepatomegaly with patchy fibrotic areas and narrowing of the intrahepatic portal vein and the inferior vena cava at the hepatic portal area (Figure 1a). Bone marrow examination revealed hypercellularity with dysplastic erythroid hyperplasia (60% of bone marrow cells) with megaloblastic changes; some of these cells stained positive for periodic acid-Schiff (PAS; Figure 1c). In addition, prominent hemophagocytosis was observed (Figure 1d). By flow cytometric analysis, <5% of total cells were detected in the CD45^{low-int}/side scatter (SSC) blast gate, and no monoclonal increases of specific populations were observed. She was evaluated for possible causes of acute liver failure including infection, metabolic disorders, and malignancies, but results of blood and urine analysis and culture tests were unremarkable. A liver biopsy could not be performed because of severe condition. A cytological examination of the ascites sample was negative for malignancy, and peripheral blasts had disappeared by day 4 after admission.

The patient was treated with pulsed steroids and plasma exchange for hepatic failure of unknown cause. However, her hepatic function and ascites continued to worsen. On day 14 after hospitalization, although her white blood cell count had normalized at $10.1 \times 10^9/L$, blast cells were again detected in blood, representing 4% of the white blood cell count. The results of G-banded karyotyping of the initial bone marrow sample revealed t(1;22)(p13;q13). The patient was diagnosed with acute myeloid leukemia (AML) with *RBM15-MKL1*. A bone marrow aspiration at that time revealed normocellular bone marrow, a decrease in the proportion of dysplastic erythroblasts, and an increase in the monoclonal blast cell count (Figure 1e and f). These blast cells were negative for myeloperoxidase stain and partially positive for PAS stain. Flow cytometric analysis demonstrated that the proportion of CD41- and CD61-positive cells increased, whereas that of CD71/CD235a double-positive cells decreased compared to the counts obtained in the initial bone marrow analysis (Figure 2a and b). Array comparative genomic hybridization (aCGH) using SurePrint G3 Human CGH microarrays 4×180 K (Agilent Technologies) revealed the amplification at the p11.21-p11.1 bands (position 42 932 086-43 333 638) on chromosome 8. A follow-up CT on day 19 showed the progression of hepatomegaly and stenosis of the portal vein and inferior vena cava. Diffuse spread of low-density areas was noted in the liver as well as the spleen (Figure 1b).

¹Osaka City General Hospital, Osaka, Japan

Corresponding Author:

Yoshiko Nakano, Department of Pediatric Hematology and Oncology, Children's Medical Center, Osaka City General Hospital, 2-13-22, Miyakojimahondori, Miyakojima, Osaka 534-0021, Japan.
Email: yonakano@ncc.go.jp



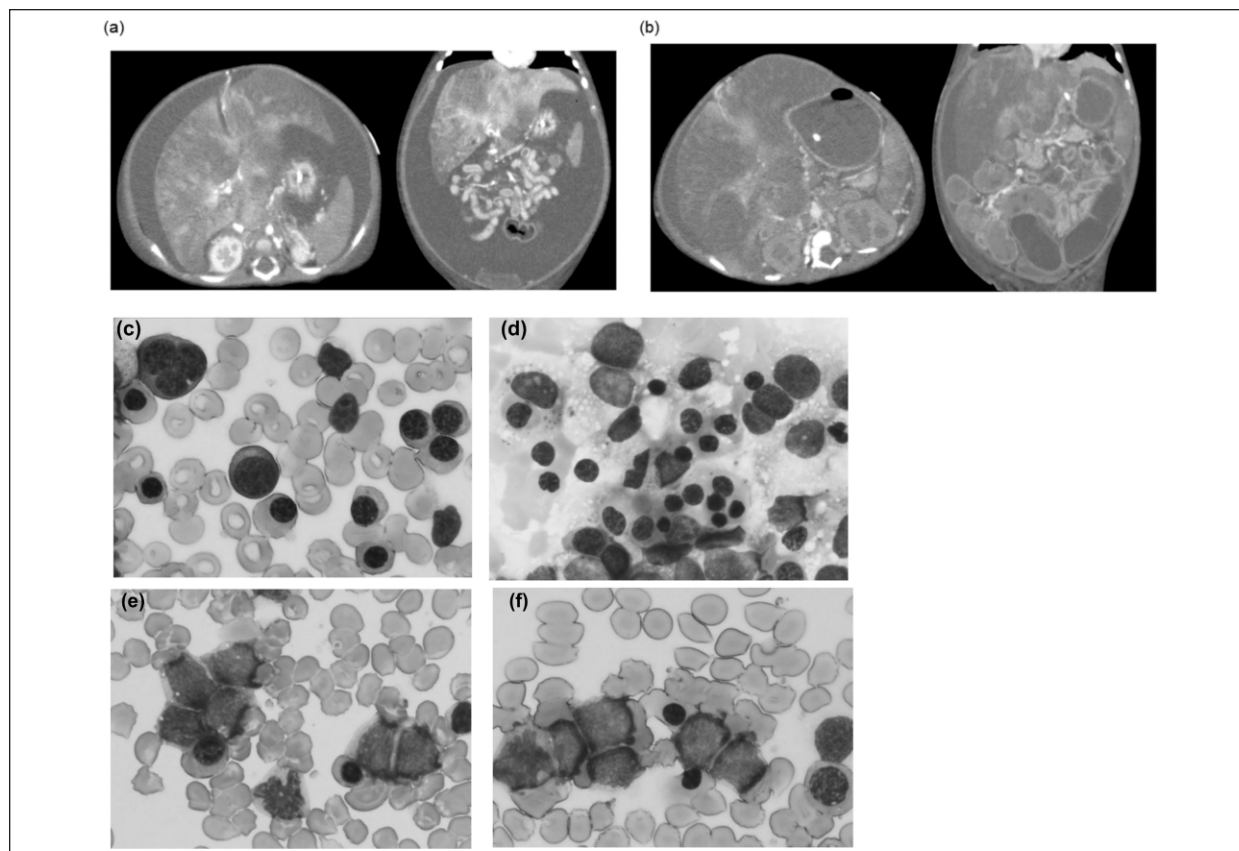


Figure 1. (a) Initial computed tomography scan showed prominent hepatomegaly with patchy low-density areas, narrowing of the intrahepatic portal vein and the inferior vena cava in the hepatic portal area, and prominent ascites. (b) Follow-up scan showed progression of the hepatomegaly and the distribution of the low-density areas in both the liver and spleen. There was progression in the stenosis of the portal veins and the inferior vena cava, and the intestines were dilated with thickened walls. (c-e) May-Giemsa-stained bone marrow smears: c, d, on admission and e, f, 14 days later. An increase in dysplastic erythroblasts (c) and hemophagocytosis (d) on admission were observed. Later, the proportion of dysplastic erythroblasts decreased, and an increase in the number of monoclonal blast cells was observed (e, f). The blast cells had a high nuclear-cytoplasmic ratio. The cytoplasm was basophilic and showed pseudopod formation.

The patient's condition was too severe to permit standard induction chemotherapy for AML. Therefore, continuous infusion of cytarabine (initially at 0.7 mg/kg/day and increased to 10 mg/kg/day) was administered for 10 days. Although the blast cells disappeared from the peripheral blood and the progression of hepatomegaly transiently stopped, her condition deteriorated with progression of jaundice, ascites, and disseminated intravascular coagulation as the bone marrow recovered. The patient died of liver failure on day 52 after hospitalization.

Discussion

Acute myeloid leukemia with t(1;22)(p13;q13) RNA-binding motif protein-15 (*RBM15*)-megakaryoblastic leukemia protein-1 (*MKLI*) has been a distinct

subgroup in the World Health Organization classification since 2008.¹ Although this subgroup represents less than 1% of AML cases, it represents >50% of acute megakaryoblastic leukemia (AMKL) cases among infants and young children without Down syndrome.^{2,3} Although early reports showed a poor prognosis, recent reports suggest that, in appropriately treated cases, the prognosis is comparable to or even better than other childhood AMKL without *RBM15-MKLI*.²⁻⁸ Therefore, a prompt diagnosis is important. It is occasionally difficult, however, because patients with AML with *RBM15-MKLI* may exhibit prominent organomegaly without an increase of blasts in the peripheral blood or bone marrow. Some previously reported patients were initially misdiagnosed with solid tumors and died before they received correct diagnosis and chemotherapy was administered.^{2-4,8} As

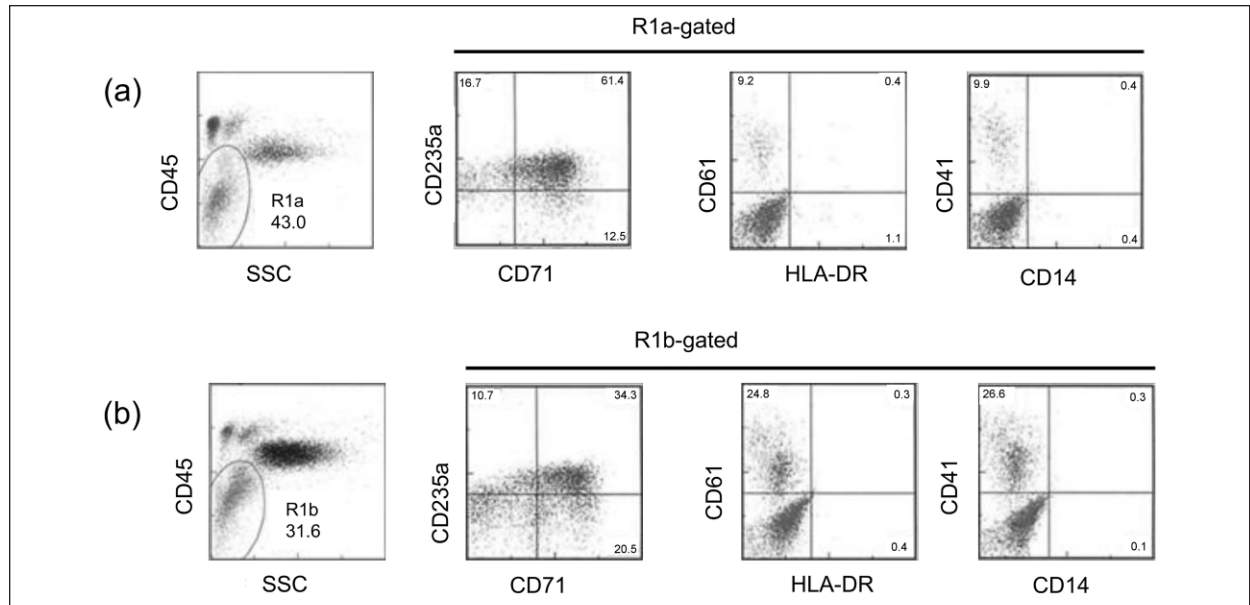


Figure 2. Flow-cytometric analysis of bone marrow aspirates: (a) on admission and (b) 14 days later. The proportion of CD41- and CD61-positive cells decreased and that of CD71/CD235a double-positive cells increased in the CD45^{low-int}/SSC gate (R1a and R1b). Corresponding cell percentages are indicated.

in the present case, karyotype analysis is crucial for confirming the diagnosis. Furthermore, one of the diagnostic pitfalls is that, in one previous report, the patient showing a normal karyotype was diagnosed by detecting *RBM15-MKLI* fusion transcription.⁵

Although diffuse hepatomegaly is a common initial sign of pediatric leukemia, liver dysfunction and ascites are rare. To date, several cases of childhood leukemia have been reported with severe liver failure at initial clinical presentation.⁹⁻¹¹ In some cases, correct diagnosis is made at autopsy or after the start of hepatic transplantation.⁹ The pathogenesis of liver failure in leukemia is uncertain. Hepatocyte ischemia caused by blast infiltration and the decrease in hepatic blood flow are proposed mechanisms.⁹⁻¹¹ In our case, multiple low-density areas on the CT scan seemed to represent hepatocyte necrosis or infiltration by blasts, and the occlusion of venous flow may have caused massive transudative ascites. Although our CT findings could be interpreted as infectious hepatitis or portal hypertension with venous occlusions, the progression of hepatomegaly and emergence of low-density areas in the liver and spleen strongly indicated leukemia.

As for erythroid cell dysplasia, it is unusual in the context of AML with *RBM15-MKLI*.^{1,2} To date, 2 cases of AML with *RBM15-MKLI* showing erythroleukemic morphology have been reported.^{6,12} In one of these cases, although bone marrow findings at the time

of the initial diagnosis met the FAB criteria for erythroleukemia, the presentation was clearly compatible with AMKL at the time of relapse. In the present case, the proliferation of variable dysplastic erythroid precursors was predominant in the initial bone marrow examination, whereas 2 weeks later, the megakaryoblasts were dominant. These clinical findings suggested that these blast cells originated from a megakaryocyte-erythroid progenitor in a subset of cases of AML with *RBM15-MKLI*.

Nearly half of the previously reported cases of AML with *RBM15-MKLI* showed complex karyotypes besides t(1;22)(p13;q13).²⁻⁴ Using an *RBM15-MKLI* knock-in mouse model, Mercher et al showed that expression of the *RBM15-MKLI* fusion gene resulted in abnormal megakaryopoiesis but was not sufficient to cause AMKL, for which additional cooperating abnormalities (eg, *MPL* mutation) were required.¹³ In this case, although t(1;22)(p13;q13) was the sole abnormality detected by G-banding, focal amplification in 8p11 was detected by aCGH. Amplification of this region has also been reported in 2 patients with juvenile myelomonocytic leukemia.¹⁴ The amplified region harbored 4 genes, including farnesyltransferase (*FNTA*), *POMK*, *HGSNAT*, and *POTEA*. Of these, *FNTA*, which is involved in the RAS signaling pathway, may be related to the development of AML.

Conclusions

Acute leukemia with *RBM15-MKL1* should be considered as an important differential diagnosis of acute liver failure of unknown causes in infants and young children. Even if morphological findings of bone marrow do not show typical findings of acute megakaryoblastic leukemia, karyotype analysis and screening for *RBM15-MKL1* transcripts provide important clues.

Acknowledgments

The authors thank Drs. Takeshi Higashiura, Hideki Shimaoka and Sho Wada for advice about patient care, and Katsunori Kanetaka, Kazumasa Ishizuka, and Yuzuru Yasuji for morphological analysis.

Author Contributions

YN: Contributed to conception and design; contributed to acquisition, analysis, and interpretation; drafted manuscript; critically revised manuscript; gave final approval; agrees to be accountable for all aspects of work ensuring integrity and accuracy.

KY: Contributed to conception and design; contributed to acquisition, analysis, and interpretation; drafted manuscript; critically revised manuscript; gave final approval; agrees to be accountable for all aspects of work ensuring integrity and accuracy.

YO: Contributed to conception and design; contributed to acquisition, analysis, and interpretation; critically revised manuscript; gave final approval; agrees to be accountable for all aspects of work ensuring integrity and accuracy.

AU: Contributed to conception and design; contributed to acquisition, analysis, and interpretation; critically revised manuscript; gave final approval; agrees to be accountable for all aspects of work ensuring integrity and accuracy.

RK: Contributed to conception; contributed to acquisition, analysis, and interpretation; critically revised manuscript; gave final approval; agrees to be accountable for all aspects of work ensuring integrity and accuracy.

NT: Contributed to conception; contributed to acquisition, analysis, and interpretation; critically revised manuscript; gave final approval; agrees to be accountable for all aspects of work ensuring integrity and accuracy.

KO: Contributed to conception; contributed to interpretation; critically revised manuscript; gave final approval; agrees to be accountable for all aspects of work ensuring integrity and accuracy.

HF: Contributed to conception; contributed to interpretation; critically revised manuscript; gave final approval; agrees to be accountable for all aspects of work ensuring integrity and accuracy.

TY: Contributed to conception and design; contributed to acquisition, analysis, and interpretation; drafted manuscript; critically revised manuscript; gave final approval; agrees to be accountable for all aspects of work ensuring integrity and accuracy.

JH: Contributed to conception and design; contributed to analysis and interpretation; drafted manuscript; critically revised manuscript; gave final approval; agrees to be accountable for all aspects of work ensuring integrity and accuracy.

Declaration of Conflicting Interests

The author(s) declared no potential conflicts of interest with respect to the research, authorship, and/or publication of this article.

Funding

The author(s) received no financial support for the research, authorship, and/or publication of this article.

References

- Arber DA, Brunning RD, Le Beau MM, et al. Acute myeloid leukemia with recurrent genetic abnormalities. In: Swerdlow SH, Campo E, Harris NL, et al, eds. *World Health Organization Classification of Tumors of Hematopoietic and Lymphoid Tissues*. Lyon, France: IARC Press; 2008:117-118.
- Carroll A, Civin C, Schneider N, et al. The t(1;22)(p13;q13) is nonrandom and restricted to infants with acute megakaryoblastic leukemia: a Pediatric Oncology Group Study. *Blood*. 1991;78:748-752.
- Lion T, Hass OA, Harbott J, et al. The translocation t(1;22)(p13;q13) is a nonrandom marker specifically associated with acute megakaryocytic leukemia in young children. *Blood*. 1992;79:3325-3330.
- Bernstein J, Dastugue N, Haas OA, et al. Nineteen cases of the t(1;22)(p13;q13) acute megakaryoblastic leukemia of infants/children and a review of 39 cases: report from a t(1;22) study group. *Leukemia*. 2000;14:216-218.
- Duchayne E, Fenneteau O, Pages MP, et al. Acute megakaryoblastic leukemia: a national clinical and biological study of 53 adult and childhood cases by the Groupe Français d'Hématologie Cellulaire (GFHC). *Leuk Lymphoma*. 2003;44:49-58.
- Inaba H, Zhou Y, Ablu O, et al. Heterogeneous cytogenetic subgroups and outcomes in childhood acute megakaryoblastic leukemia: a retrospective international study. *Blood*. 2015;126:1575-1584.
- de Rooij JD, Hollink IH, Arentsen-Peters ST, et al. NUP98/JARID1A is a novel recurrent abnormality in pediatric acute megakaryoblastic leukemia with distinct HOX gene expression pattern. *Leukemia*. 2013;27:2280-2288.
- Kawasaki Y, Makimoto M, Nomura K, et al. Neonatal acute megakaryoblastic leukemia mimicking congenital neuroblastoma. *Clin Case Rep*. 2015;3:145-149.
- Litten JB, Rodríguez MM, Maniaci V. Acute lymphoblastic leukemia presenting in fulminant hepatic failure. *Pediatr Blood Cancer*. 2006;47:842-845.
- Lazure T, Beauchamp A, Croisille L, Ferlicot S, Feneux D, Fabre M. Congenital anerythremic erythroleukemia presenting as hepatic failure. *Arch Pathol Lab Med*. 2003;127:1362-1365.

11. Lewis MS, Kaicker S, Strauchen JA, Morotti RA. Hepatic involvement in congenital acute megakaryoblastic leukemia: a case report with emphasis on the liver pathology findings. *Pediatr Dev Pathol.* 2008;11:55-58.
12. Oshima M, Fukushima T, Koike K, Hoshida C, Izumi I, Tsuchida M. Infant leukemia with t(1;22) presenting proliferation of erythroid and megakaryocytic cell lineages. *Rinsho Ketsueki.* 1994;40:230-235.
13. Mercher T, Raffel GD, Moore SA, et al. The OTT-MAL fusion oncogene activates RBPJ-mediated transcription and induces acute megakaryoblastic leukemia in a knockin mouse model. *J Clin Invest.* 2009;119:852-864.
14. Ripperger T, Tauscher M, Praulich I, et al. Constitutional trisomy 8p11.21-q11.21 mosaicism: a germline alteration predisposing to myeloid leukemia. *Br J Hematol.* 2011;155:209-217.