



Received: 2015.04.30  
Accepted: 2015.07.02  
Published: 2015.10.25

**Authors' Contribution:**

- A** Study Design
- B** Data Collection
- C** Statistical Analysis
- D** Data Interpretation
- E** Manuscript Preparation
- F** Literature Search
- G** Funds Collection

## Atypical Presentation of Ewing's Sarcoma with a Single Left Orbital Metastasis

Marta Puglia<sup>□</sup>, Alessandra Acquaviva<sup>□</sup>, Andrea Ponsiglione<sup>□</sup>, Luigi Barbuto<sup>□</sup>,  
Nilde Di Paolo<sup>□</sup>, Dario De Rosa<sup>□</sup>, Simonetta Sicuranza<sup>□</sup>, Simone Maurea<sup>□</sup>,  
Massimo Imbriaco<sup>□</sup>

Department of Advanced Biomedical Sciences, University Federico II, Naples, Italy

**Author's address:** Massimo Imbriaco, Department of Advanced Biomedical Sciences, University Federico II, Naples, Italy,  
e-mail: mimbriaco@hotmail.com

### Summary

**Background:**

We present an uncommon case of Ewing's sarcoma in a 16-year-old boy.

**Case Report:**

This case can be considered unique because of the atypical presentation, normal laboratory tests and absence of the typical symptoms such as pain, masses or swelling, fatigue or weight loss, breathing problems linked to lung metastases or pathologic fractures. The only event that brought the patient to our attention was the sudden onset of left proptosis.

**Conclusions:**

The final histopathology together with CT and PET-CT findings led to the diagnosis of a multi-metastatic Ewing's sarcoma involving the orbit, skeleton, bone marrow and lymph nodes.

**MeSH Keywords:**

Exophthalmos • Neoplasm Metastasis • Neuroectodermal Tumors • Sarcoma, Ewing

**PDF file:**

<http://www.polradiol.com/abstract/index/idArt/894507>

### Background

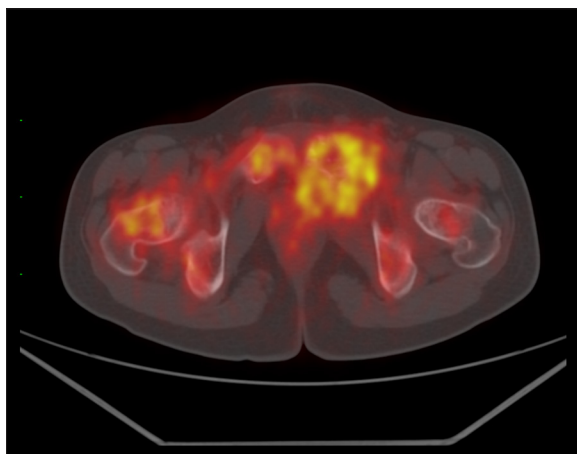
Skeletal Ewing's sarcoma represents one of the clinical-pathologic entities of the "Ewing family of tumors", which also includes extra-osseous Ewing's sarcoma, primitive neuroectodermal tumor (PNET), and Askin tumor. Skeletal Ewing's sarcoma is the second most common primary malignant bone tumor in children and adolescents after osteosarcoma; the highest incidence is in the second decade of life [1]. It frequently involves the diaphysis or meta-diaphyseal region of the long bones; the pelvis, ribs, and spine are also commonly involved [2]. At presentation, 20–30% of new cases are metastatic [3]. Clinically, patients often present with local pain and swelling, palpable mass, pathologic fracture or constitutional symptoms such as fever, fatigue, weight loss, anemia [4]. Radiographically, Ewing's sarcoma is an osteolytic lesion that frequently extends through the cortex and into the periosteum and the soft tissue [5]. Microscopically, Ewing family of tumors is a histologically different group of tumors having varying degrees of neuronal differentiation with small round cell morphology [6]. When the histological patterns are not conclusive for the diagnosis, immunohistochemical markers are highly sensitive and useful for final diagnosis [7]. Differential

diagnosis may not be easy because many other neoplasms can present small round cell morphology and can be positive for CD99 including lymphomas, mesenchymal chondrosarcoma, small cell osteosarcoma, synovial sarcoma and desmoplastic round cell tumor [8]. The research of genetic rearrangements is often necessary to confirm the diagnosis of Ewing's sarcoma. In particular, EWS-FLI1 and EWS-ERG are the most frequent types of translocation fusion genes seen in this family of tumors [9].

We hereby describe a rare case of Ewing's sarcoma in a 16-year-old boy that presented with a sudden onset of left proptosis initially imputable to a foreign body reaction. The final histopathology together with CT and PET-CT findings led to the diagnosis of a multi-metastatic Ewing's sarcoma involving the orbit, skeleton, bone marrow and lymph nodes.

### Case Report

A 16-year-old male showed no noteworthy problem until November 2013, when he developed a left proptosis due to a foreign body reaction. Because of the proptosis the patient was transferred to the orbital pathology unit where

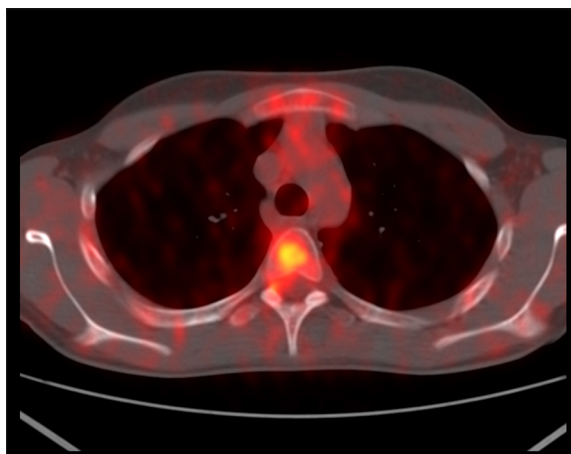


**Figure 1.** FDG-PET image showing severe FDG uptake (SUV max: 12) at the level of the right upper femur and the left pubic bone.

he underwent excisional biopsy for a lesion that appeared on a pre-operative CT scan with a maximum diameter of 5×2 cm and with a partially calcified wall. The final histological diagnosis was consistent with an Ewing's sarcoma. The patient underwent a total-body CT scan for staging. A marked morpho-structural alteration was noted in the pelvis at the level of the left pubic ramus, for the presence of a mass (maximum diameter: 8 cm) that incorporated the bone structure and reached the neighbouring soft tissues; this lesion infiltrated the obturator muscles, the pectineus, the inferior side wall of the bladder and the anterior perianal area. There were multiple bony lesions involving several vertebrae throughout the spine, pelvis, iliac wings and right femur. In addition, there were multiple inguinal and obturator lymph nodes. Those findings were confirmed on a PET-CT scan that showed a large area of FDG uptake in the left pubic branch with infiltration of the adjacent soft tissues (Figure 1, SUV max 12). Severe increase of FDG uptake was also present along the cervical, thoracic (Figure 2, SUV max 8) and lumbar spine, at the iliac wings, on the right femur where mainly lytic alterations were appreciated; those findings were associated with widespread and uneven accumulation of FDG at the level of the whole osteomedullary compartment. The above described case indicated a clear example of multi-metastatic Ewing's sarcoma with onset from the left pubic ramus but without any form of pain and without any kind of symptoms linked to this pathology. Subsequently, the patient was sent to a specialized paediatric oncological structure for chemotherapy treatment. Currently, the patient is treated with vincristine, doxorubicin, cyclophosphamide, ifosfamide, and etoposide. At the end of this program, a chemotherapy regimen with high-dose busulfan and melphalan will be performed.

## Discussion

Ewing's sarcoma, being an extremely malignant tumour, metastasizes at a very high rate and also tends to break through the cortex of bone of origin into the adjacent tissues. Spread of this tumour into the orbits is most likely through blood. Metastases to orbits are extremely rare in Ewing's sarcoma. Most of the patients with metastatic



**Figure 2.** FDG-PET image showing severe FDG uptake (SUV: 8) at the level of the upper thoracic vertebra.

orbital Ewing's sarcoma have unilateral proptosis, generally on the same side as the primary tumour and clinically presenting as rapidly developing proptosis with haemorrhage and necrosis as in neuroblastoma [10]; hereby, we report an atypical presentation of a young male patient who presented with orbital involvement as the first manifestation of the pathology. The delay of the right diagnosis was caused by the absence of typical symptoms that Ewing's sarcoma should give especially if multi-metastatic and by the rare location of the metastasis. Ewing's sarcoma is a rare malignant neoplasm that comprises approximately 4–6% of primary bone tumors. It is a rare and highly lethal malignant neoplasm of the bone and is composed of small round cells with uncertain histogenesis. Ewing's sarcoma is responsible for about 4–40% of all bone tumors and commonly involves long bones and the pelvis [11]. Recent studies indicate that most Ewing's sarcoma cases have their origins in neuro-ectodermal tumors [6]. This neoplasm usually affects adolescent and young adult males [11]. In clinical terms, this tumor has an aggressive behavior and is identified with rapid growth and high probability of metastasis at diagnosis. This case report deals with a 16-year-old patient wrongly diagnosed with proptosis due to a foreign body reaction, and hospitalized. As the symptoms did not remit, biopsy was carried out and the patient was operated leading to the final diagnosis of Ewing's sarcoma. Unilateral proptosis can be caused by various pathologies such as thyrotoxicosis, orbital cellulitis, dacryoadenitis, hemangioma, foreign body reaction, cavernous sinus thrombosis, malignancy and other. The differential diagnosis among all these pathologic entities was based on the history and the clinical examination. The age of the patient, the lack of typical symptoms of thyrotoxicosis, inflammatory or systemic diseases and the non-pulsatile nature of the proptosis, were suggestive of a foreign body reaction. But a more careful and accurate examination, requested for persistence of proptosis, allowed to suspect a malignancy that was confirmed by biopsy. The histological features present in our patient where common to those seen in other small, round cell tumors of neuroectodermal origin, such as malignant lymphoma, neuroblastoma, and rhabdomyosarcoma, and therefore, cytochemical and immunohistochemical studies were important to establish an accurate diagnosis. The integration of both radiological and nuclear medicine

examinations were crucial to determine the extent of the disease, to identify the primary tumor and for a correct staging of the disease.

## Conclusions

Skeletal Ewing's sarcoma is the second most common primary malignant bone tumor in children and adolescents after osteosarcoma. Clinically, patients often present with local pain, swelling, palpable mass, pathologic fracture or

constitutional symptoms such as fever, fatigue, weight loss, anemia. At presentation 20–30% of new cases are metastatic but metastases to orbits are extremely rare in Ewing's sarcoma. In our case report the only event that brought the patient to our attention was the sudden onset of left proptosis in absence of other typical symptoms. Thanks to the final histopathology together with CT and PET-CT findings we could obtain the diagnosis of a multi-metastatic Ewing's sarcoma involving the orbit, skeleton, bone marrow and lymph nodes almost completely silent.

## References:

1. Esiashvili N, Goodman M, Marcus RB Jr: Changes in incidence and survival of Ewing's sarcoma patients over the past 3 decades: Surveillance Epidemiology and End Results data. *J Pediatr Hematol Oncol*, 2008; 30: 425–30
2. Mascarenhas L, Siegel S, Spector L et al: Malignant bone tumors. In: Bleyer a, O'Leary M, Barr R et al. (eds.), *Cancer Epidemiology in Older Adolescents and Young Adults 15 to 29 Years of Age, Including SEER Incidence and Survival: 1975–2000*. Bethesda, MD: National Cancer Institute; 2006; 97–109
3. Rodríguez-Galindo C, Navid F, Liu T et al: Prognostic factors for local and distant control in Ewing sarcoma family of tumors. *Ann Oncol*, 2008; 19: 814–20
4. Widhe B, White T: Initial symptoms and clinical features in osteosarcoma and Ewing sarcoma. *J Bone Joint Surg Am*, 2000; 82: 667–74
5. Stoker DJ, Saifuddin A: Bone tumors: malignant lesions. In: Adam A, Dixon AK et al. (eds.), *Grainer & Allison's Diagnostic Radiology: A Textbook of Medical Imaging*. Edinburg: Churchill Livingstone; 2008; 1050–81
6. Parham DM, Hijazi Y, Steinberg SM et al: Neuroectodermal differentiation in Ewing's sarcoma family of tumors does not predict tumor behavior. *Hum Pathol*, 1999; 30: 911–18
7. Folpe AL, Goldblum JR, Rubin BP et al: Morphologic and immunophenotypic diversity in Ewing family tumors: a study of 66 genetically confirmed cases. *Am J Surg Pathol*, 2005; 29: 1025–33
8. Llombart-Bosch A, Machado I, Navarro S et al: Histological heterogeneity of Ewing's sarcoma/PNET: an immunohistochemical analysis of 415 genetically confirmed cases with clinical support. *Virchows Arch*, 2009; 455: 397–411
9. Patibandla MR, Uppin SG, Thotakura AK et al: Primary Ewing's sarcoma of cavernous sinus in an infant: a case report and review of literature. *Turk Neurosurg*, 2013; 23: 98–103
10. Khurana AK, Ahluwalia BK, Gupta S et al: Bilateral proptosis due to metastatic Ewing's sarcoma of the orbit: fine needle aspiration cytology (FNAC) and histopathology of a case. *Indian J Ophthalmol*, 1992; 40: 15–17
11. Sharada P, Girish HC, Umadevi Hs, Priya NS: Ewing's sarcoma of the mandible. *J Oral Maxillofac Pathol*, 2006; 10: 31–35