

# The Seven-Color TcMsEP Grading System: A Novel Alarm Method for Intraoperative Neurophysiological Monitoring Using Transcranial Electrical Stimulated Muscle Evoked Potentials (TcMsEPs) in Intramedullary Spinal Cord Tumor Surgeries

Yasushi Fujiwara<sup>1)</sup>, Shinji Kotaka<sup>1)</sup>, Ryo Ohta<sup>1)</sup>, Yasuo Arakawa<sup>2)</sup>, Yutaka Kadonishi<sup>1)</sup>, Makoto Nishimori<sup>1)</sup>, Hideki Manabe<sup>1)</sup> and Nobuo Adachi<sup>3)</sup>

1) Orthopedics and Micro-surgical Spine Center, Hiroshima City Asa Hospital, Hiroshima, Japan

2) Medical Engineering Center, Hiroshima City Asa Hospital, Hiroshima, Japan

3) Department of Orthopedics, Hiroshima University, Hiroshima, Japan

## Abstract:

**Introduction:** Surgeons need precise information about motor deterioration risk during surgery for intramedullary spinal cord tumors (IMSCTs). However, the conventional TcMsEP alarm criterion provides limited information with a less than or a more than single alarm criterion without any grades in between, resulting in false-negative and false-positive outcomes.

Therefore, we developed a “seven-color TcMsEP grading system” for neuromonitoring to provide more graded information. This study investigates the system’s efficacy.

**Methods:** This study included 60 patients that underwent resection surgeries for IMSCTs. TcMsEP outcomes were classified into seven grades: Grade “D-0 Green” includes a wave amplitude decrease of 0%-50% compared with the baseline amplitude. Grade “D-1 Lime” includes a 50%-70% decrease. Grade “D-2 Yellow” includes a 70%-90% decrease. Grade “D-3 Orange” includes a more than 90% decrease with a clearly visible waveform. Grade “D-4 Red” includes a minimal and abnormally shaped wave. The severest, grade “D-5 Black,” includes a wave that has completely disappeared. The additional grade “D-X Gray” includes cases in which the baseline wave is undetectable.

Postoperative motor deterioration was evaluated in the upper limbs (PUMD) and lower limbs (PLMD) individually.

**Results:** PLMD only occurred in cases with more than a 90% wave amplitude decrease (from D-3 to D-5) and with the undetectable baseline wave (D-X). The PLMD rate increased according to the severity of the amplitude decreases (29% in D-3, 67% in D-4, 80% in D-5). Most PUMD occurred in cases with more than a 90% decrease, but one case with grade D1 had PUMD.

**Conclusions:** The seven-color graded alarm criterion supports surgeons’ decisions on how to treat the wave amplitude decrease during surgery. It provides motor deterioration risk in each grade without false negatives. Moreover, the corresponding colors enable quick comprehension of the risks.

## Keywords:

microscopic surgery, Intraoperative neuromonitoring, Intramedullary spinal cord tumor

Spine Surg Relat Res 2021; 5(4): 238-243  
dx.doi.org/10.22603/ssrr.2020-0144

## Introduction

Intraoperative neurophysiological monitoring is expected to reduce the risk of postoperative motor deterioration (PMD). Transcranial muscle evoked potential (TcMsEP) monitoring is widely used because of its high monitoring

sensitivity and the ability to monitor paresis in every muscle individually.

TcMsEP monitoring is especially useful in resection surgeries for intramedullary spinal cord tumors (IMSCTs) because there is a high risk of PMD<sup>1,2)</sup>. When the wave amplitude decrease happens during IMSCT surgery, surgeons first

Corresponding author: Yasushi Fujiwara, Rxd11306@nifty.com

Received: September 8, 2020, Accepted: November 2, 2020, Advance Publication: December 5, 2020

Copyright © 2021 The Japanese Society for Spine Surgery and Related Research

perform rescue interventions, including steroid injection, suspending surgery, etc. If the wave does not recover, surgeons have to decide whether to continue tumor resection or to abandon tumor resection. Therefore, the alarm criterion in TcMsEP monitoring for those decisions is quite important.

However, there is controversy about a standard criterion. Various kinds of alarm criteria have been reported, such as a threshold elevation<sup>3)</sup>, amplitude reduction (50%<sup>4)</sup>, 70%<sup>5,6)</sup>, and 80%<sup>7)</sup>, waveform disappearance<sup>8)</sup>, 10% delay in latency<sup>4)</sup>, and waveform changes<sup>9)</sup>. However, none of these alarm criteria has become the standard because every alarm criterion has false-negative outcomes (PMD occurs without an alarm) and false-positive outcomes (PMD does not occur with an alarm). Generally, a smaller amplitude reduction criterion will increase the false positives, and a larger amplitude reduction criterion will increase the false negatives.

In order to solve this problem, the Japanese Society for Spine Surgery and Related Research (JSSR) recommended a “two-stage alarm criterion”<sup>10)</sup> for IMSCT surgery: an over 70% TcMsEP wave amplitude decrease as a criterion for rescue intervention and the wave disappearance as a criterion for abandoning tumor resection.

However, the method of treating the amplitude decreases between 70% and 100% remains controversial because there are various grades within the wave amplitude decreases. The criterion for abandoning tumor resection is especially controversial because each patient has a different background, including age, tumor pathology, surgical condition, etc.: In some cases, continuing tumor resection while disregarding the monitoring alarm is more beneficial for a patient’s long-term outcome, but in other cases, abandoning tumor resection according to the monitoring alarm is more beneficial.

Therefore, surgeons need more graded information about how high the risk is when the wave decreases to make accurate decisions. Thus, we have developed a new alarm system for TcMsEP monitoring to evaluate a more accurate risk of PMD according to the severity of the wave amplitude decrease: TcMsEP monitoring outcomes are classified into 7 grades according to the waveform changes during surgery. Moreover, a corresponding color is added to each grade to comprehend the degree of severity quickly.

In this study, we have investigated the efficacy of this method among patients who underwent resection surgeries for intramedullary spinal cord tumors in our institute.

## Materials and Methods

This study included 60 cases that underwent resection surgeries for intramedullary spinal cord tumors. The mean age was 53 years old, and there were 19 males and 41 females. Histologically, there were 15 ependymomas, 6 astrocytomas, 19 hemangiomas, 5 hemangioblastomas, and 15 other tumors. There were 32 cervical cases, 19 cases in the upper-middle thoracic spine (T1-10), and 9 cases in the thoracolumbar spine. The local institutional review board approved the study, and patients provided informed consent.

D-0 Green	<50% wave amplitude decrease
D-1 Lime	50-70% wave amplitude decrease
D-2 Yellow	70-90% wave amplitude decrease
D-3 Orange	>90% decrease without waveform change
D-4 Red	Minimal and abnormally shaped wave
D-5 Black	A complete wave disappearance
D-X Gray	A baseline wave cannot be detected

**Figure 1.** The seven-color TcMsEP grading system.

During surgery, Tc-MsEP monitoring was performed according to the JSSR method<sup>5)</sup> using Epoch XP (Axon company), Endeavor CR (Natus), and Neuromaster (Nihon Kohden). Total intravenous anesthesia was administered during intraoperative spinal cord monitoring using propofol and remifentanyl. Rocuronium induced a neuromuscular blockade at the intubation time, and Sugammadex reversed it immediately after intubation. Basically, no muscle relaxant was used during surgery. A transcranial five-train electrical stimulation was delivered via two subdermal corkscrew-like electrodes.

The waves were recorded from the muscles with a pair of needle or disc electrodes inserted into the muscles: the deltoid (C5), the biceps brachii (C5, 6), the triceps brachii (C7), the abductor digiti minimi (C8, Th1), hip adductors (L2, 3), the quadriceps femoris (L2, 3, 4), the tibialis anterior (L4, 5), the abductor hallucis (S1), and anal sphincter muscles (S2, 3, 4).

The Tc-MsEPs recorded before the invasive surgical procedures were taken as the baseline. The peak-to-peak amplitudes were measured and compared with the baseline values.

PMD, which is defined by a more than one level deterioration in manual muscle testing, was evaluated in the upper limbs (PUMD) and the lower limbs (PLMD) individually at one day after surgery.

### The seven-color TcMsEP grading system

In this method, TcMsEP outcomes were classified into 7 grades with corresponding colors, as shown in Fig. 1.

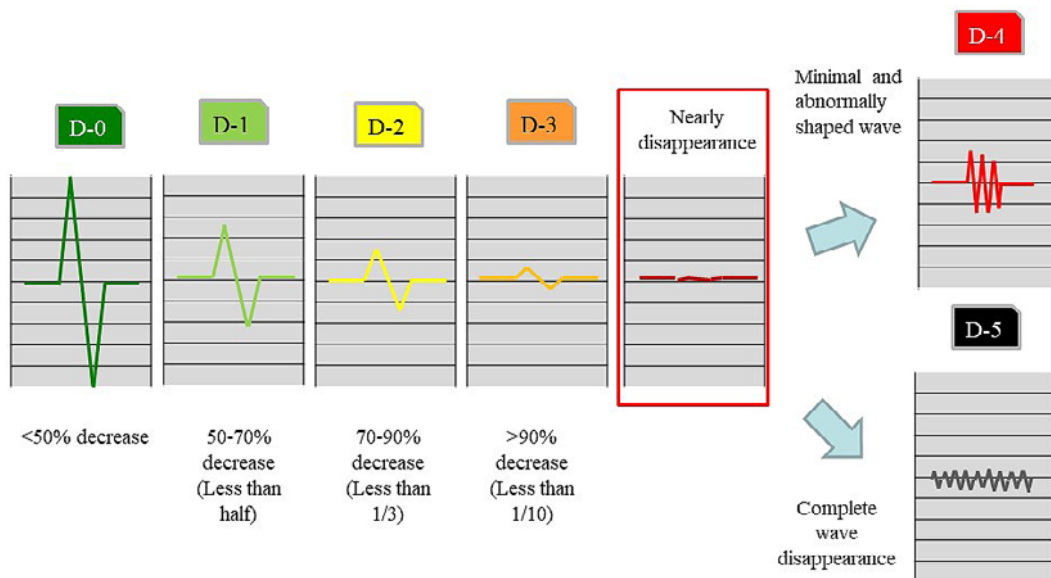
The normal grade is “D-0 (Green)” of which the wave amplitude decreases less than 50%, compared with the baseline wave amplitude.

Grade “D-1 (Lime)” of which the wave amplitude decreases more than 50%, but less than 70%, compared with the baseline.

Grade “D-2 (Yellow)” of which the wave amplitude decreases more than 70%, but less than 90%.

Grade “D-3 (Orange)” of which the wave amplitude decreases more than 90%, and the waveform is clearly visible when the wave is magnified (“>90% decrease without waveform change”).

Grade “D-4 (Red)” of which the residual amplitude value is very minimal, and the waveform is abnormally shaped



**Figure 2.** Method of grading. Caution is necessary when the waves are classified into grades D3 Orange, D4 Red, or D5 Black because the waves seem to disappear without magnification on the monitoring display. At that moment, the waves should be magnified and then evaluated into grades D3 Orange, D4 Red, or D5 Black.

even though it is visible when the wave is magnified (“a minimal and abnormally shaped wave”).

The severest grade, grade “D-5 (Black),” of which the wave has completely disappeared and cannot be detected even when the wave is magnified.

The seventh and additional grade is “D-X (Gray),” of which the TcMsEP monitoring cannot be achieved because the baseline wave cannot be detected.

Caution is necessary before categorizing waves into D-3, D-4, or D-5 because the waves seem to disappear in the monitoring display when the amplitude decreases more than 90%. The waves should be magnified in order to check whether or not the waves have actually disappeared. When the wave retains its original form, it is classified as grade D-3 (Fig. 2).

During surgery, every wave amplitude is evaluated individually, as shown in Fig. 3. Technicians input the wave amplitude numbers into a simple program using Excel software manually, and the software shows the color grade in each muscle on the computer monitor. At the same time, technicians announce the important changes in color grades to the surgeons.

In this paper, we retrospectively investigated the motor deterioration rate in the upper extremity muscles and lower extremity muscles separately. We evaluated the muscles with the severest decrease of wave amplitude in the upper/lower extremity in each patient. We checked the presence of palsy in the upper/lower extremity. Then we calculated the motor deterioration rate in each grade. For example, even when only one or two muscles are lost in the patient’s upper (or lower) extremity, the whole extremity was graded as D-5 (Black) in this study.

## Results

### Postoperative lower extremity motor deterioration (PLMD)

PLMD occurred in 9 cases among 60 IMSCT cases, and the total incidence rate was 15%.

Fig. 4a demonstrates the PLMD ratio in each grade according to the current multi-graded alarm system.

There were 6 cases at D-X (Gray), and one of them had PLMD (PLMD rate 17%).

There were 31 cases at D-0 (Green), 3 cases at D-1 (Lime), 5 cases at D-2 (Yellow), and there was no PLMD among these grades.

There were 7 cases at D-3 (Orange), and 2 of them had motor deterioration (rate 29%). There were 3 cases at D-4 (Red), and 2 of them had motor deterioration (rate 67%). There were 5 cases at D-5 (Black), and 4 of them had motor deterioration (rate 80%).

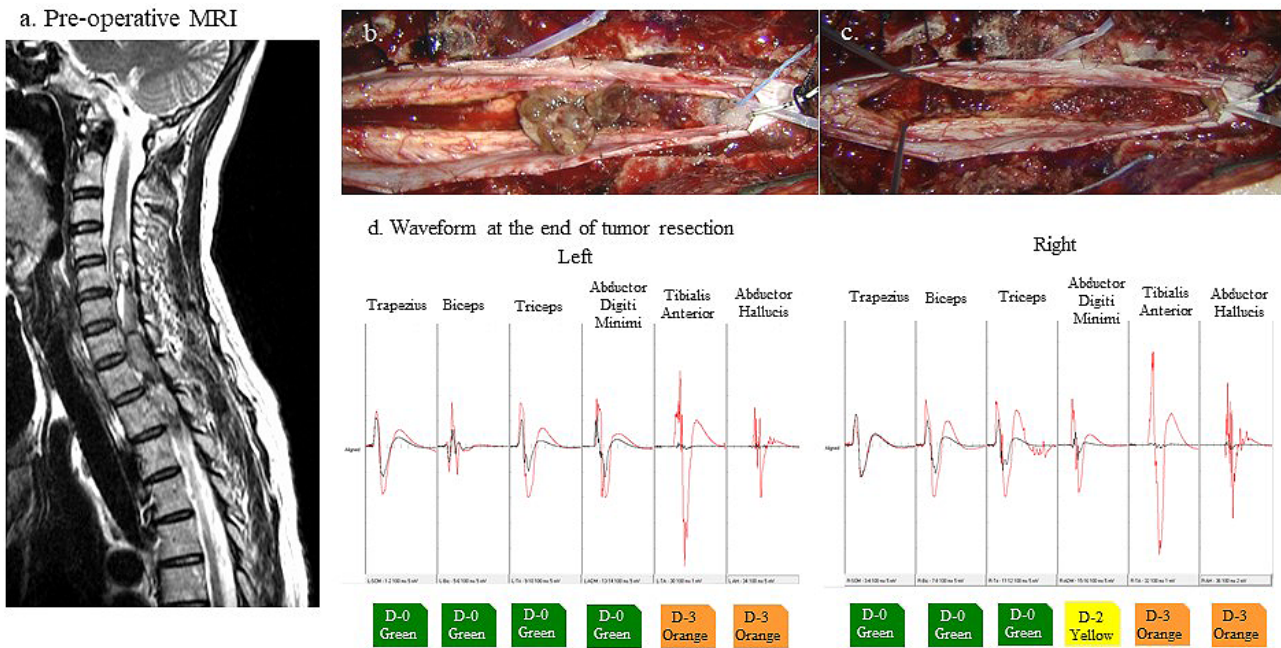
All of the PLMD was temporary, and patients recovered within 3 months.

### Postoperative upper extremity motor deterioration (PUMD)

Among the 32 cervical spine cases, 4 cases had postoperative U/E motor deterioration. As shown in Fig. 4b, there was 1 case at D-X (Gray), 20 cases at D-0 (Green), and there was no PLMD among them.

There were 2 cases at D-1 (Lime), and 1 of them had PUMD (rate 50%), although 3 cases at D-2 (Yellow) did not have PUMD.

There were 6 cases at D-3 (Orange), and 2 of them had motor deterioration (rate 33%). There was 1 case at D-4 (Red), and it had motor deterioration (rate 100%). There were no cases at D-5 (Black).



**Figure 3.** Case report: a female patient with Ependymoma.

a. Pre-operative MRI.

b-c. Intraoperative photographs during resection surgery of Ependymoma.

d. TcMsEP waves. Red wave shows baseline wave, and black wave shows the waveform at the end of surgery: The wave of right ADM is classified as grade D-2 (Yellow). The waves of bilateral TA and AH decreased a lot and cannot be seen on the same scale as a baseline wave. After magnification of the waves, they are classified as grade D-3 (Orange). After surgery, no motor deterioration occurred.

a. Postoperative lower extremity motor deterioration (PLMD)

grade	Total number	PLMD cases	rate
D-5 Black	5	4	80%
D-4 Red	3	2	67%
D-3 Orange	7	2	29%
D-2 Yellow	5	0	0%
D-1 Lime	3	0	0%
D-0 Green	31	0	0%
D-X Gray	6	1	17%

b. Postoperative upper extremity motor deterioration (PUMD)

grade	Total number	PUMD cases	rate
D-5 Black	0	0	0%
D-4 Red	1	1	100%
D-3 Orange	6	2	33%
D-2 Yellow	3	0	0%
D-1 Lime	2	1	50%
D-0 Green	20	0	0%
D-X Gray	1	0	0%

**Figure 4.** Postoperative motor deterioration ratio in each TcMsEP color grade.

a. PLMD only occurred in cases with more than a 90% wave amplitude decrease (D3 Orange, D4 Red, and D5 Black) and with the undetectable baseline wave (DX Gray). And the PLMD rate increased according to the severity of the amplitude decreases, from D3 Orange to D5 Black.

b. Most of PUMD also occurred in cases with more than a 90% wave amplitude decrease (D3 Orange, D4 Red), but one case with grade Lime had PUMD.

All of the PUMD was temporary, and patients recovered within 3 months.

**Case report: a female patient with ependymoma**

The chief complaint was finger numbness. The MRI showed that there was an intramedullary spinal cord tumor (Fig. 3a). Resection surgery was performed, and a gross to-

tal resection was achieved (Fig. 3b-c).

Fig. 3d shows the baseline TcMsEP waves (red waves) and the TcMsEP waves at the end of surgery (Black): The wave of right ADM is classified as grade D-2 (Yellow). The waves of the bilateral TA and AH decreased substantially and cannot be seen without magnification of the waves. After magnification, they are classified as grade D-3 (Orange).

After surgery, no motor deterioration occurred.

## Discussion

Our results demonstrate that there was no PLMD in less than a 90% wave amplitude decreases (from D-0 to D-2). PLMD only occurred in cases with more than a 90% wave amplitude decreases (from D-3 to D-5) and a single case with the undetectable baseline (D-X). Moreover, the PLMD rate increased according to the severity of the wave amplitude decreases (29% at D-3, 67% at D-4, 80% at D-5). These results suggest that surgeons can evaluate the risk of PLMD more precisely, according to the seven-color TcMsEP grading system.

According to the seven-color TcMsEP grading system, surgeons can receive more graded information about the risk of PMD at particular decreases of wave amplitude during surgery, and surgeons can choose a surgical strategy while considering the risk of PMD and the benefits of tumor resection.

As for PUMD, most PUMD occurred in cases with more than a 90% decrease (from D-3 to D-5), and this system is also useful to predict the occurrence of PUMD. However, caution is necessary because one case in grade D-1 had PUMD. Previously, several papers<sup>11,12)</sup> recommend a 50% alarm criterion for detecting upper extremity palsy, including postoperative C5 palsy due to injuries of the nerve roots or the gray matter of the spinal cord. The current results are consistent with the previous papers<sup>11,12)</sup>.

Another advantage of this system is the quick comprehension of the monitoring outcomes due to the corresponding colors. Within the conventional method, it is difficult to report every muscle condition precisely, and in a brief manner because (1) a lot of muscles are monitored in IMSCT surgeries, (2) each wave size is very small on the monitor, and (3) TcMsEP waves have to be compared with the baseline amplitudes in order to evaluate the outcomes.

In the current seven-color TcMsEP grading system, the corresponding colors enable quick comprehension, as presented in Fig. 3. Technicians can report every muscle condition efficiently, and surgeons can comprehend the motor deterioration risk visually and immediately, although both surgeons and technicians have to learn this system.

As stated above, by using this system, surgeons can choose a graded surgical strategy while considering the patients' backgrounds because they can know the occurrence rate of the PMD within each grade. Our recommendations for responding to each grade are as follows:

- (1) D-0 (Green, <50% decrease): there is no necessity of concern for PMD in general.
- (2) D-1 (Lime, >50% decrease): we recommend performing rescue intervention for upper extremity palsy because there are some occurrences of PUMD.
- (3) D-2 (Yellow, >70% decrease): we recommend performing rescue intervention for lower extremity palsy.
- (4) D-3 (Orange, >90% decrease): we recommend careful

evaluation before continuing surgery because there was a 29% risk of PLMD in this study.

- (5) D-4 (Red, a minimal and abnormally shaped wave): we recommend abandoning tumor resection at this stage, if possible, because there was a 67% risk of PLMD.
- (6) D-5 (Black, a complete wave disappearance): we highly recommend abandoning tumor resection at this stage because there was an 80% risk of PLMD. However, for cases in which more tumor resection is necessary, even though there is a high risk of PMD after a complete wave disappearance, we recommend that surgeons use the spinal cord evoked potentials, as Sala et al. recommended.
- (7) D-X (Gray, an undetectable baseline wave): cautious surgical procedures are recommended because motor functions are vulnerable to surgical trauma since the neural tissue is already damaged preoperatively.

There are limitations in the current study: this is a retrospective study with a limited number of IMSCT cases. A prospective study with a larger number of cases, including various surgeries, will be necessary to clarify the exact risk within each grade.

Finally, we would like to emphasize that this system is beneficial for both surgeons and monitoring technicians because technicians can quickly provide surgeons more precise TcMsEP information using the color grades. Surgeons can comprehend the risks of PMD according to the color grades so they can determine the best surgical strategy during surgery while considering the risk of PMD and the benefits of tumor resection. Therefore, it is also beneficial for patients.

## Conclusions

We developed the new seven-color grading system for TcMsEP monitoring to evaluate a more accurate risk of PMD. This system is useful to support surgeons' decisions in how to treat the wave amplitude decreases during surgery because (1) it provides precise motor deterioration risk that exists within the grades; (2) the corresponding colors enable quick comprehension of the risks.

**Conflicts of Interest:** The authors declare that there are no relevant conflicts of interest.

**Sources of Funding:** None

**Acknowledgement:** We appreciate Professor Mitsuo Ochi for encouraging the writing of this paper and we appreciate Mr. Vincent John Hykel for his English proofreading and his devoted support.

**Author Contributions:** Conception or design of the work: Yasushi Fujiwara

Acquisition of data: Kotaka, Arakawa, Ohta, Kadonishi, Nishimori, Manabe

Drafting paper: Fujiwara

Revising paper: Adachi

**Ethical Approval:** IRB code 02-03-11 Hiroshima City Asa Hospital institutional review board

**Informed Consent:** Informed consent was obtained in every patient.

## References

1. Matsuyama Y, Sakai Y, Katayama Y, et al. Surgical results of intramedullary spinal cord tumor with spinal cord monitoring to guide extent of resection. *J Neurosurg Spine*. 2009;10(5):404-13.
2. Azad TD, Pendharkar A V, Nguyen V, et al. Diagnostic utility of intraoperative neurophysiological monitoring for intramedullary spinal cord tumors. *Clin Spine Surg*. 2018;31(3):112-19.
3. Raynor BL, Bright JD, Lenke LG, et al. Significant change or loss of intraoperative monitoring data: a 25-year experience in 12,375 spinal surgeries. *Spine (Phila Pa 1976)*. 2013;38(2):E101-8.
4. Sutter M, Eggspuehler A, Grob D, et al. The validity of multimodal intraoperative monitoring (MIOM) in surgery of 109 spine and spinal cord tumors. *Eur Spine J*. 2007;16 Suppl 2:S197-208.
5. Kobayashi S, Matsuyama Y, Shinomiya K, et al. A new alarm point of transcranial electrical stimulation motor evoked potentials for intraoperative spinal cord monitoring: A prospective multicenter study from the Spinal Cord Monitoring Working Group of the Japanese Society for Spine Surgery and Related Research. *J Neurosurg Spine*. 2014;20(1):102-7.
6. Yoshida G, Ando M, Imagama S, et al. Alert Timing and Corresponding Intervention With Intraoperative Spinal Cord Monitoring for High Risk Spinal Surgery. *Spine (Phila Pa 1976)*. 2019;44(8):E470-9.
7. Langeloo DD, Lelivelt A, Louis Journée H, et al. Transcranial electrical motor-evoked potential monitoring during surgery for spinal deformity: a study of 145 patients. *Spine (Phila Pa 1976)*. 2003;28(10):1043-50.
8. Sala F, Palandri G, Basso E, et al. Motor evoked potential monitoring improves outcome after surgery for intramedullary spinal cord tumors: a historical control study. *Neurosurgery*. 2006;58(6):1129-43 discussion 1129-43.
9. Ito Z, Imagama S, Sakai Y, et al. A new criterion for the alarm point for compound muscle action potentials. *J Neurosurg Spine*. 2012;17(4):348-56.
10. Fujiwara Y, Matsuyama Y, Kobayashi S, et al. Two Stage alarm strategy for intramedullary spinal cord tumors based on the transcranial electrically stimulated muscle evoked potential monitoring: the JSSR prospective multi-center study. *J Spine Res*. 2016;7(9).
11. Sakaki K, Kawabata S, Ukegawa D, et al. Warning thresholds on the basis of origin of amplitude changes in transcranial electrical motor-evoked potential monitoring for cervical compression myelopathy. *Spine (Phila Pa 1976)*. 2012;37(15):E913-21.
12. Fujiwara Y, Manabe H, Izumi B, et al. The efficacy of intraoperative neurophysiological monitoring using Transcranial Electrically Stimulated Muscle-evoked Potentials (TcE-MsEPs) for predicting postoperative segmental upper extremity motor paresis after cervical laminoplasty. *Clin Spine Surg*. 2016;29(4):E188-95.

Spine Surgery and Related Research is an Open Access journal distributed under the Creative Commons Attribution-NonCommercial-NoDerivatives 4.0 International License. To view the details of this license, please visit (<https://creativecommons.org/licenses/by-nc-nd/4.0/>).