

Correlated non-nuclear COX2 and low HER2 expression confers a good prognosis in colorectal cancer

Fei-fei Zhou, Rong Huang, Jun Jiang, Xiao-hong Zeng, Shu-qian Zou

Department of Thoracoabdominal Radiotherapy, Cancer Center, The First People's Hospital of Foshan, Foshan, Guangdong, People's Republic China

Abstract

Background/Aims: COX2 and HER2 are shown to be critical in the regulation of cancer progression. However, the prognostic value of nuclear COX2 in colorectal cancer (CRC) and its relationship with HER2 still remains unknown. In this study, the expression and biological significance of COX2 and HER2 were evaluated in CRC at mRNA and protein levels.

Materials and Methods: RNA-Seq data of CRC were downloaded from TCGA, and 229 CRC and 50 non-cancerous subjects were enrolled in this study. Bioinformatics and immunohistochemistry analysis was performed based on the obtained data. Survival analysis was conducted to identify factors associated with overall survival of CRC patients.

Results: We showed that mRNA and protein levels of COX2 and HER2 were upregulated in CRC compared with the adjacent tissues. COX2 protein levels and nuclear COX2 expression were correlated with a poor prognosis of CRC patients. In addition, we also revealed that nuclear COX2 expression was positively associated with HER2 expression. Non-nuclear COX2 combined with low HER2 expression, was negatively correlated with Duke's stage and lymph node metastasis, predicting the best outcomes for CRC patients. In addition, our data indicated that non-nuclear COX2 combined with low HER2 expression is an independent prognostic factor for CRC after surgical resection.

Conclusion: The study suggests that nuclear COX2 in combination with HER2 can serve as potential biomarkers for the clinical diagnosis and prognosis of CRC, and targeted inhibition of COX2 and HER2 might be an alternative strategy for the management of CRC.

Keywords: Colorectal cancer, COX2, HER2, nuclear COX2, prognosis

Address for correspondence: Dr. Fei-Fei Zhou, Cancer Center, The First People's Hospital of Foshan, NO. 81 North of Lingnan Avenue, Foshan 528000, Guangdong, People's Republic China.
E-mail: zhoufeifei528000@163.com

INTRODUCTION

Colorectal cancer (CRC) is currently the third most commonly diagnosed cancers and the third most common cause of cancer-related death worldwide.^[1] In China, colorectal cancer is one of the five leading causes of cancer death among both men and women.^[2] Tumor metastasis and recurrence are the

prognostic predictors of CRC, and biomarkers that predict cancer metastasis and recurrence are gaining more attention.

Accumulating evidence has shown that COX2 and HER2 are responsible for cancer metastasis and recurrence in CRC. COX2 expression was associated with higher TNM

Access this article online	
Quick Response Code:	Website: www.saudijgastro.com
	DOI: 10.4103/sjg.SJG_46_18

This is an open access journal, and articles are distributed under the terms of the Creative Commons Attribution-NonCommercial-ShareAlike 4.0 License, which allows others to remix, tweak, and build upon the work non-commercially, as long as appropriate credit is given and the new creations are licensed under the identical terms.

For reprints contact: reprints@medknow.com

How to cite this article: Zhou Ff, Huang R, Jiang J, Zeng Xh, Zou Sq. Correlated non-nuclear COX2 and low HER2 expression confers a good prognosis in colorectal cancer. Saudi J Gastroenterol 2018;24:301-6.

class, higher Dukes' stage, and increased risk of tumor recurrence in CRC.^[3,4] Meanwhile, HER2 expression was positively correlated with distant and lymph node metastasis, and local recurrence in CRC.^[5,6] Previous studies suggested the nuclear location of COX2 in human breast carcinoma^[7] and urinary bladder cancer.^[8] However, nuclear location of COX2 and the prognostic value of nuclear COX2 in CRC remain unclear. In addition, COX2 expression was positively related with HER2 expression in CRC.^[9] However, whether nuclear COX2 expression is correlated with HER2 expression is also unknown.

In the present study, we investigated the expression and biological significance of COX2 and HER2 in CRC at mRNA and protein levels.

MATERIALS AND METHODS

Bioinformatics analysis

RNA-Seq data of colon adenocarcinoma-colorectal (COAD) were downloaded from TCGA (<http://cancergenome.nih.gov/>). The data included 647 CRC patients, of which 51 patients were with paired paracarcinoma tissues. The clinical information of only 629 patients was available on the website.

Patients and tissues

Overall, 229 CRC and 50 non-cancerous subjects with available medical records and paraffin-embedded blocks from 2008 to 2012 were enrolled in this study. All the patients received tumor resection, and tissues were obtained from patients during the surgeries. The protocol was approved by the Ethical Committee of the First People's Hospital of Foshan, and written informed consent was obtained for the research use of the materials. All clinicopathological features, including age, gender, pathologic stage, anatomic site, recurrence, and prognostic data, were retrospectively collected from the patients' clinical information. All the procedures were conducted in accordance with the approved protocols.

Immunohistochemistry

The tissue sections were dewaxed and dehydrated. The antigen retrieval was then achieved, and endogenous peroxidase activity was blocked in 3% hydrogen peroxide for 10 minutes. The slides were then cooled and blocked in normal goat serum for 10 minutes at room temperature, followed by incubation with a primary antibody for 60 minutes at room temperature. Finally, the slides were incubated with the secondary antibody and visualized using 3,3'-diaminobenzidine and hematoxylin, respectively.

Evaluation and scoring

The staining of sections was evaluated and scored by two independent pathologists blind to the study. The staining

was scored according to the intensity and percentage of the stained sections. Staining intensity was assigned as 0 (no staining), 1 (weakly staining), 2 (moderately staining), and 3 (strong staining). The percentages were estimated as follows: 1 ($\leq 25\%$), 2 (26%–50%), 3 (51%–75%), and 4 (76%–100%). The final scores were calculated as intensity score \times percentage score. For statistical analysis, a score ≤ 8 was regarded as low expression, and > 8 as high expression. Tumor cells with more than 5% nuclear staining were judged as positive nuclear expression.

Statistical analysis

All the data analysis was carried out using SPSS software (version 21.0, SPSS Inc., Chicago, USA). A non-parametric test was conducted to investigate the differential expression of each protein between the two groups of patients. Kappa test was used to achieve the correlation between HER2 and nuclear COX2. The relationships between the clinicopathological features and gene expression were evaluated using Pearson's χ^2 test. Kaplan–Meier survival curves were plotted to elucidate the relationships between gene expression and overall survival of the CRC patients. Univariate and multivariate survival analysis were performed with the Cox proportional hazards regression model to identify factors associated with the overall survival of patients. The hazard ratio (HR) and 95% confidence intervals (95% CI) were calculated for each factor. All tests were two-sided and $P < 0.05$ was considered statistically significant.

RESULTS

The mRNA levels of COX2 and HER2 are upregulated in colorectal cancer

To investigate the role of COX2 and HER2 in HCC, we assessed their mRNA expression in CRC based on the TCGA COAD dataset. RNA-Seq data from CRCs and paracarcinoma tissues showed that COX2 and HER2 expression were significantly elevated in CRC tissues compared with paracarcinoma tissues ($P < 0.001$) [Figure 1a and b], indicating their oncogenetic roles in CRCs.

Clinicopathological features of the colorectal cancer patients

The clinicopathological features of 229 CRC patients are shown in Table 1. The patients' age ranged from 31 to 80 years and the median age was 58 years. Most patients (58.2%) were male, the ratio of male patients to female patients was 1.385. Based on Duke Staging System, 104 of the CRC patients were in Duke stages A and B and 125 of them in Duke stages C and D. Therein, 146 patients had lymph node metastasis and 29 patients had distant metastasis.

Correlation between the expression of nuclear COX2, HER2, and clinicopathological features

In order to verify the findings obtained from bioinformatics analysis, we further explored COX2 and HER2 expression by immunohistochemistry, in 229 CRC cases. The analysis showed that patients presented different COX2 and HER2 expression ranging from weak staining to strong staining [Figure 2a]. Interestingly, we not only detected cytoplasmic expression of COX2 but also nuclear expression of COX2 in CRC tissues [Figure 2b]. In addition, we found that nuclear COX2 expression was positively correlated with Duke stage and lymph node metastasis, but not other parameters of the patients, including age, gender, distant metastasis, and anatomic site [Table 1]. Additionally, further analysis suggested that non-nuclear COX2 expression was positively correlated with low HER2 expression in CRCs ($P < 0.001$) [Table 2].

Survival analysis

Next, we conducted the survival analysis to explore the association between COX2, HER2 levels, and overall survival of the CRC patients. Survival analysis indicated that low COX2 expression was correlated with good prognosis for CRC patients (median survival 2.744 years versus 0.903 years) (Log-Rank, $P = 0.0253$) [Figure 3a]; however, there was no correlation between HER2 expression and prognosis for CRC patients (data not shown). Then, we determined the relationship between nuclear location of COX2 and prognosis in CRC patients, and revealed that nuclear COX2 expression predicted poor patient prognosis (median survival 0.912 years versus 2.385 years) (Log-Rank, $P = 0.0173$) [Figure 3b]. In addition, we assigned the patients into two groups: one group was named as low HER2/nuclear COX2 (-), and another group was named as others including low HER2/nuclear COX2 (+), high HER2/nuclear COX2 (-),

and high HER2/nuclear COX2 (+) status. The association between clinicopathological features of CRC patients and the expression status of nuclear COX2 and HER2 in the two groups was analyzed and the data were summarized in Table 3. Low HER2/nuclear COX2 (-) status was negatively correlated with Duke's stage and lymph node metastasis but not other clinicopathological features of the CRC patients. Low HER2/nuclear COX2 (-) status conferred a good prognosis in CRC (median

Table 1: Correlation between nuclear COX2 expression and the clinicopathological features of colorectal cancer patients

Characteristics	Total	Nuclear COX2 expression		P
		Negative, n (%)	Positive, n (%)	
Age (years)				
≤Median	115	64 (55.7%)	51 (44.3%)	0.541
>Median	114	68 (59.6%)	46 (40.4%)	
Gender				
Male	133	78 (58.6%)	55 (41.4%)	0.717
Female	96	54 (56.3%)	42 (43.7%)	
Duke's stage				
A + B	104	68 (65.4%)	36 (34.6%)	0.031
C + D	125	64 (51.2%)	61 (48.8%)	
Lymph node metastasis				
N0	83	59 (71.1%)	24 (28.9%)	0.002
N1-2	146	73 (50.0%)	73 (50.0%)	
Distant metastasis				
No	200	118 (59.0%)	82 (41.0%)	0.073
Yes	29	12 (41.4%)	17 (58.6%)	
Anatomic site				
Colon	106	65 (61.3%)	41 (38.7%)	0.296
Rectum	123	67 (54.5%)	56 (45.5%)	

Table 2: HER2 and nuclear COX2 expression in the colorectal cancer tissues

HER2 expression	Nuclear COX2 expression		Total	Kappa	P
	Negative	Positive			
Low	85 (69.1%)	38 (44.3%)	123	0.250	<0.001
High	47 (30.9%)	59 (55.7%)	106		
Total	132	97	229		

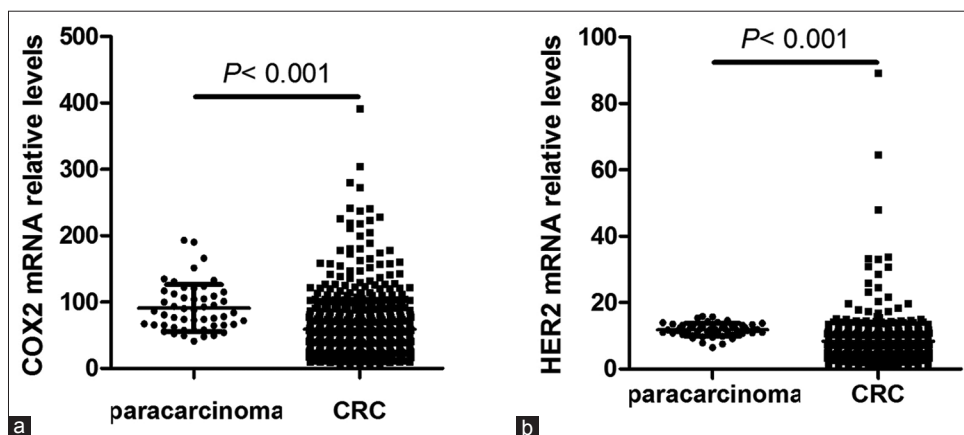


Figure 1: The bioinformatics analysis of COX2 and HER2 in tumor tissues and paracarcinoma tissues of CRC patients. (a) The comparison of COX2 expression between CRC tissues and paracarcinoma tissues. (b) The comparison of HER2 expression between CRC tissues and paracarcinoma tissues

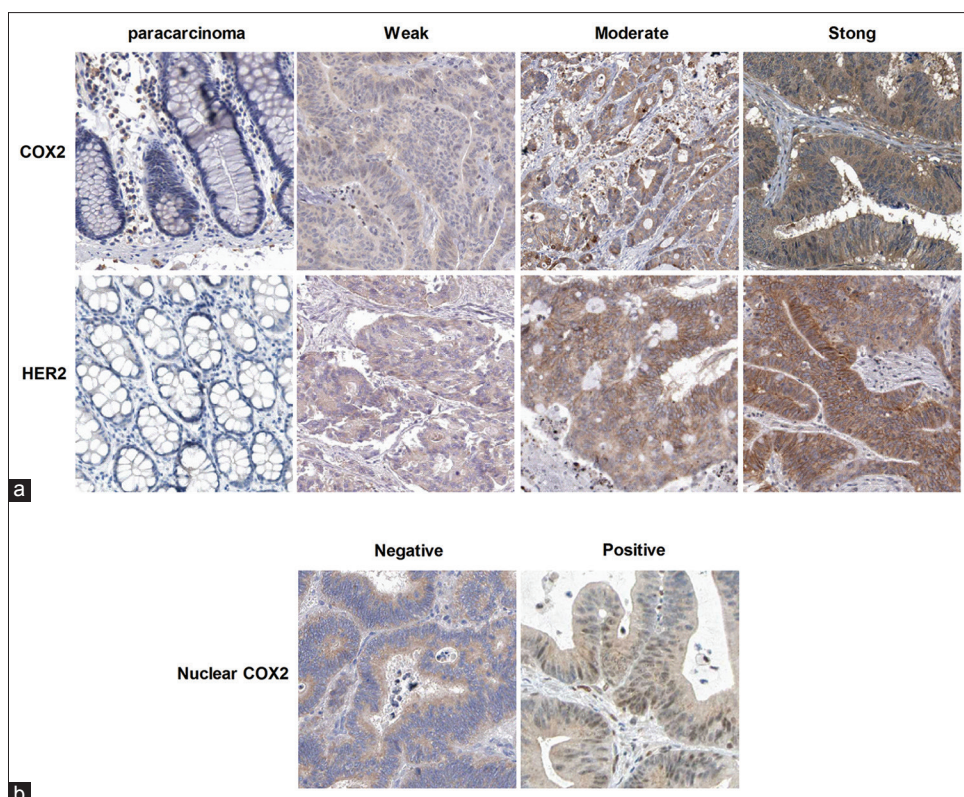


Figure 2: Representative images of COX2, nuclear COX2 and HER2 staining in tumor tissues and paracarcinoma tissues of CRC patients (original magnification $\times 400$). (a) Representative images of COX2 and HER2 staining in CRC tissues and paracarcinoma tissues. (b) Representative images of COX2 staining with and without nuclear distribution in CRC tissues

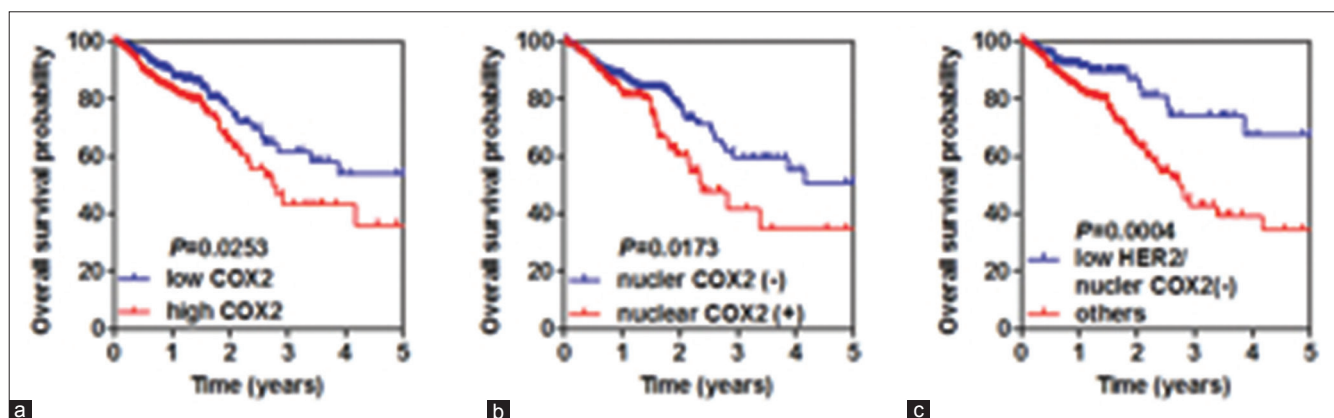


Figure 3: Kaplan-Meier survival analysis based on COX2, nuclear COX2 and nuclear COX2 combined with HER2 expression. (a) Kaplan-Meier survival analysis based on COX2 expression. (b) Kaplan-Meier survival analysis based on nuclear COX2 expression. (c) Kaplan-Meier survival analysis based on HER2 and nuclear COX2 expression

survival 2.901 years versus 0.817 years) (log-rank, $P = 0.0004$) [Figure 3c].

We further conducted a univariate and multivariate survival analysis to correlate the HER2/nuclear COX2 expression status, the clinicopathological features, and overall survival of the CRC patients. As shown in Table 4, low HER2/nuclear COX2 (-) status, younger age, Duke's stage (A + B), without lymph node metastasis, and no

distant metastasis contributed to longer overall survival of CRC patients. Moreover, the multivariate Cox proportional hazard analysis exhibited that low HER2/nuclear COX2 (-) status (HR = 0.523, 95% CI 0.285-0.959, $P = 0.036$), age (HR = 0.387, 95% CI 0.242-0.619, $P < 0.001$), Duke's stage (HR = 0.166, 95% CI 0.047-0.585, $P = 0.005$), and distant metastasis (HR = 0.431, 95% CI 0.233-0.797, $P = 0.007$) acted as independent prognostic factors for CRC patients [Table 4].

DISCUSSION

Many reports suggested that COX2 and/or HER2 are important indicators of poor patient survival in CRC. However, nuclear COX2 expression and its association with HER2 expression in CRC remains unclear. In this study, COX2 and HER2 expression, and their biological significance in CRC, were investigated. COX2 and HER2 expression were upregulated in CRC, at mRNA and

protein levels. COX2 protein levels conferred a poor prognosis for CRC patients. Moreover, we showed that nuclear translocation of COX2 was present in CRC tissues, and nuclear COX2 expression which was also correlated with high HER2 expression also contributed to the poor prognosis of CRC patients. In addition, nuclear COX2 expression with low HER2 expression was associated with the best prognosis of CRC patients.

Table 3: Relationship between HER2/nuclear COX2 combined status and clinicopathological features of colorectal cancer patients

Characteristics	Total	Low HER2/Nuclear COX2(-)	Others*	P
Age (years)		85		
≤Median	115	39 (33.9%)	76 (66.1%)	0.313
>Median	114	46 (40.4%)	68 (59.6%)	
Gender				
Male	133	52 (39.1%)	81 (60.9%)	0.465
Female	96	33 (34.4%)	63 (65.6%)	
Duke's stage				
A + B	104	49 (47.1%)	55 (52.9%)	0.004
C + D	125	36 (28.8%)	89 (71.2%)	
Lymph node metastasis				
N0	83	44 (53.0%)	39 (47.0%)	<0.001
N1-N2	146	41 (28.1%)	105 (71.9%)	
Distant metastasis				
No	200	70 (35.0%)	130 (65.0%)	0.081
Yes	29	15 (51.7%)	14 (48.3%)	
Anatomic site				
Colon	106	32 (30.2%)	74 (69.8%)	0.121
Rectum	123	53 (39.8%)	80 (60.2%)	

Others*: Low HER2/Nuclear COX2 (+), High HER2/Nuclear COX2 (-) and High HER2/Nuclear COX2 (+)

COX2, namely PTGS2, was normally located in cytoplasm and on cell membrane, and was thought to function in the biosynthesis of inflammatory prostaglandin, and acts as a peroxidase. COX2 is constitutively expressed in many tissues in physiological and pathological conditions, such as in cancers. In cancer cells, COX2 enhances the production of prostaglandin E2 (PGE2), and is positively associated with increased cell adhesion, resistance to apoptosis, proliferation, phenotypic changes, and tumor angiogenesis. It is well documented that COX2 expressions are higher in CRC than those in the paracarcinoma tissues.^[10,11] In this work, we showed that both mRNA and protein levels of COX2 were upregulated in CRC by bioinformatics and immunohistochemistry analysis. In addition, cytoplasmic and cytomembranous COX2 is associated with pathological stage, tumor recurrence, metastasis, and poor patient prognosis, and is an independent prognostic factor in CRC.^[3,12-14] Similarly, in this study, we found that COX2 protein levels were positively correlated with poor prognosis for CRC patients. Intriguingly, some studies suggested that nuclear COX2 interacted with HIF-1 α to

Table 4: Univariate and multivariate survival analysis of clinicopathological variables of colorectal cancer patients

Clinical parameters	Overall survival					
	Univariate analysis			Multivariate analysis		
	HR	95% CI	P	HR	95% CI	P
HER2/Nuclear COX2 expression	0.493	(0.332-0.732)	<0.001	0.523	(0.285-0.959)	0.036
Low HER2/Nuclear COX2 (-)						
Others						
Age (years)	0.512	(0.357-0.747)	<0.001	0.387	(0.242-0.619)	<0.001
≤Median						
>Median						
Gender	1.025	(0.708-1.486)	0.895			
Male						
Female						
Duke's stage	0.302	(0.204-0.448)	<0.001	0.166	(0.047-0.585)	0.005
A + B						
C + D						
Lymph node metastasis	0.322	(0.220-0.470)	<0.001	0.363	(0.120-1.099)	0.073
N0						
N1-N2						
Distant metastasis	0.097	(0.052-0.182)	<0.001	0.431	(0.233-0.797)	0.007
No						
Yes						
Anatomic site	1.124	(0.666-1.898)	0.661			
Colon						
Rectum						

promote bone metastasis of human breast carcinoma,^[7] and functioned as a transcription factor that was significantly associated with the expression of stemness markers in bladder cancer.^[8] Consistently, we also detected the nuclear location of COX2 in CRC, and nuclear COX2 expression was positively correlated with Duke's stage, lymph node metastasis, and the poor prognosis in CRC patients. Survival analysis further revealed that nuclear COX2 expression was an independent prognostic factor in CRC.

Interestingly, many researchers suggest that the positive association between COX2 and HER2 expression in CRC and breast carcinoma, and their expression have synergistic effects in cancer progression.^[9,15-17] In this work, we found that nuclear COX2 expression was positively associated with HER2 expression, indicating both of them played pro-tumoral roles in CRC. Importantly, we showed that patients with non-nuclear CD133 and low HER2 expression exhibited the best prognosis in CRC. Further analysis suggested that non-nuclear CD133 with low HER2 expression status correlated with Duke's stage and lymph node metastasis, and could serve as an independent prognostic factor for CRC patients. Moreover, we found that both mRNA and protein levels of HER2 were upregulated in CRC; however, HER2 overexpression did not correlate with overall survival. These results were consistent with previous observations.^[18-21]

Taken together, our work adds to the wealth of knowledge on the oncogenic roles of COX2 and HER2 in HCC. We also demonstrated that nuclear COX2 in combination with HER2 can serve as a potential biomarker for the clinical diagnosis and prognosis of CRC, and targeted inhibition of COX2 and HER2 might be an alternative strategy for the management of CRC.

Financial support and sponsorship

Nil.

Conflicts of interest

There are no conflicts of interest.

REFERENCES

- Siegel RL, Miller KD, Jemal A. Cancer Statistics, 2017. *CA Cancer J Clin* 2017;67:7-30.
- Chen W, Zheng R, Baade PD, Zhang S, Zeng H, Bray F, *et al.* Cancer statistics in China, 2015. *CA Cancer J Clin* 2016;66:115-32.
- Elzagheid A, Emaetig F, Alkikhia L, Buhmeida A, Syrjanen K, El-Faitori O, *et al.* High cyclooxygenase-2 expression is associated with advanced stages in colorectal cancer. *Anticancer Res* 2013;33:3137-43.
- Kunzmann AT, Murray LJ, Cardwell CR, McShane CM, McMenamin UC, Cantwell MM. PTGS2 (Cyclooxygenase-2) expression and survival among colorectal cancer patients: A systematic review. *Cancer Epidemiol Biomarkers Prev* 2013;22:1490-7.
- Yao YF, Du CZ, Chen N, Chen P, Gu J. Expression of HER-2 in rectal cancers treated with preoperative radiotherapy: A potential biomarker predictive of metastasis. *Dis Colon Rectum* 2014;57:602-7.
- Lu Y, Jingyan G, Baorong S, Peng J, Xu Y, Cai S. Expression of EGFR, Her2 predict lymph node metastasis (LNM)-associated metastasis in colorectal cancer. *Cancer Biomark* 2012;11:219-26.
- Maroni P, Matteucci E, Luzzati A, Perrucchini G, Bendinelli P, Desiderio MA. Nuclear co-localization and functional interaction of COX-2 and HIF-1alpha characterize bone metastasis of human breast carcinoma. *Breast Cancer Res Treat* 2011;129:433-50.
- Thanan R, Murata M, Ma N, Hammam O, Wishahi M, El Leithy T, *et al.* Nuclear localization of COX-2 in relation to the expression of stemness markers in urinary bladder cancer. *Mediators Inflamm* 2012;2012:165879.
- Wu QB, Sun GP. Expression of COX-2 and HER-2 in colorectal cancer and their correlation. *World J Gastroenterol* 2015;21:6206-14.
- Wu AW, Gu J, Li ZF, Ji JF, Xu GW. COX-2 expression and tumor angiogenesis in colorectal cancer. *World J Gastroenterol* 2004;10:2323-6.
- Mahmoud AS, Umair A, Azzeghaiby SN, Alqahtani FH, Hanounch S, Tarakji B. Expression of cyclooxygenase-2 (COX-2) in colorectal adenocarcinoma: An immunohistochemical and histopathological study. *Asian Pac J Cancer Prev* 2014;15:6787-90.
- Al-Maghrabi J, Buhmeida A, Emam E, Syrjanen K, Sibiany A, Al-Qahtani M, *et al.* Cyclooxygenase-2 expression as a predictor of outcome in colorectal carcinoma. *World J Gastroenterol* 2012;18:1793-9.
- Soumaoro LT, Uetake H, Higuchi T, Takagi Y, Enomoto M, Sugihara K. Cyclooxygenase-2 expression: A significant prognostic indicator for patients with colorectal cancer. *Clin Cancer Res* 2004;10:8465-71.
- Peng L, Zhou Y, Wang Y, Mou H, Zhao Q. Prognostic significance of COX-2 immunohistochemical expression in colorectal cancer: A meta-analysis of the literature. *PLoS One* 2013;8:e58891.
- Antonacopoulou AG, Tsamandas AC, Petsas T, Liava A, Scopa CD, Papavassiliou AG, *et al.* EGFR, HER-2 and COX-2 levels in colorectal cancer. *Histopathology* 2008;53:698-706.
- Ciris IM, Bozkurt KK, Baspinar S, Kapucuoglu FN. Immunohistochemical COX-2 overexpression correlates with HER-2/neu overexpression in invasive breast carcinomas: A pilot study. *Pathol Res Pract* 2011;207:182-7.
- Lucarelli AP, Martins MM, Montor W, Oliveira V, Galvao MA, Piato S. Cyclooxygenase-2 and human epidermal growth factor receptor type 2 (HER-2) expression simultaneously in invasive and *in situ* breast ductal carcinoma. *Sao Paulo Med J* 2011;129:371-9.
- Kruszewski WJ, Rzepko R, Ciesielski M, Szeffel J, Zielinski J, Szajewski M, *et al.* Expression of HER2 in colorectal cancer does not correlate with prognosis. *Dis Markers* 2010;29:207-12.
- Pyo JS, Kang G, Park K. Clinicopathological significance and diagnostic accuracy of HER2 immunohistochemistry in colorectal cancer: A meta-analysis. *Int J Biol Markers* 2016;31:e389-94.
- Ingold Heppner B, Behrens HM, Balschun K, Haag J, Kruger S, Becker T, *et al.* HER2/neu testing in primary colorectal carcinoma. *Br J Cancer* 2014;111:1977-84.
- Pappas A, Lagoudianakis E, Seretis C, Tsiambas E, Koronakis N, Toutouzias K, *et al.* Clinical role of HER-2/neu expression in colorectal cancer. *J BUON* 2013;18:98-104.