

Medial perirhinal cortex disambiguates confusable objects

Sasa L. Kivisaari,^{1,2} Lorraine K. Tyler,³ Andreas U. Monsch^{1,2} and Kirsten I. Taylor^{1,2,3}

1 Memory Clinic, Department of Geriatrics, University Hospital Basel, University of Basel, Basel, CH, Switzerland

2 Faculty of Psychology, University of Basel, Basel, CH, Switzerland

3 Centre for Speech, Language and the Brain, Department of Experimental Psychology, University of Cambridge, Cambridge, UK

Correspondence to: Kirsten I. Taylor

Schanzenstrasse 55,

CH-4031, Basel,

Switzerland

E-mail: ktaylor@uhbs.ch

Our brain disambiguates the objects in our cluttered visual world seemingly effortlessly, enabling us to understand their significance and to act appropriately. The role of anteromedial temporal structures in this process, particularly the perirhinal cortex, is highly controversial. In some accounts, the perirhinal cortex is necessary for differentiating between perceptually and semantically confusable objects. Other models claim that the perirhinal cortex neither disambiguates perceptually confusable objects nor plays a unique role in semantic processing. One major hurdle to resolving this central debate is the fact that brain damage in human patients typically encompasses large portions of the anteromedial temporal lobe, such that the identification of individual substructures and precise neuroanatomical locus of the functional impairments has been difficult. We tested these competing accounts in patients with Alzheimer's disease with varying degrees of atrophy in anteromedial structures, including the perirhinal cortex. To assess the functional contribution of each anteromedial temporal region separately, we used a detailed region of interest approach. From each participant, we obtained magnetic resonance imaging scans and behavioural data from a picture naming task that contrasted naming performance with living and non-living things as a way of manipulating perceptual and semantic confusability; living things are more similar to one another than non-living things, which have more distinctive features. We manually traced neuroanatomical regions of interest on native-space cortical surface reconstructions to obtain mean thickness estimates for the lateral and medial perirhinal cortex and entorhinal cortex. Mean cortical thickness in each region of interest, and hippocampal volume, were submitted to regression analyses predicting naming performance. Importantly, atrophy of the medial perirhinal cortex, but not lateral perirhinal cortex, entorhinal cortex or hippocampus, significantly predicted naming performance on living relative to non-living things. These findings indicate that one specific anteromedial temporal lobe region—the medial perirhinal cortex—is necessary for the disambiguation of perceptually and semantically confusable objects. Taken together, these results support a hierarchical account of object processing, whereby the perirhinal cortex at the apex of the ventral object processing system is required to bind properties of not just perceptually, but also semantically confusable objects together, enabling their disambiguation from other similar objects and thus comprehension. Significantly, this model combining a hierarchical object processing architecture with a semantic feature statistic account explains why category-specific semantic impairments for living things are associated with anteromedial temporal lobe damage, and pinpoints the root of this syndrome to perirhinal cortex damage.

Keywords: semantic; category-specificity; perirhinal cortex; transentorhinal cortex; Alzheimer's disease; declarative memory

Received January 26, 2012. Revised August 13, 2012. Accepted August 20, 2012

© The Author (2012). Published by Oxford University Press on behalf of the Guarantors of Brain.

This is an Open Access article distributed under the terms of the Creative Commons Attribution Non-Commercial License (<http://creativecommons.org/licenses/by-nc/3.0/>), which permits unrestricted non-commercial use, distribution, and reproduction in any medium, provided the original work is properly cited.

Introduction

The functional role of the perirhinal cortex is a highly controversial issue in current models of anterior medial temporal lobe function. Most of the debate focuses on two major claims of perirhinal cortex function. In one account, the perirhinal cortex is necessary for differentiating between perceptually and semantically ambiguous objects (Murray and Bussey, 1999; Tyler *et al.*, 2004; Taylor *et al.*, 2011). An alternative, unitary model claims that the perirhinal cortex is neither required for complex perceptual discriminations (Levy *et al.*, 2005; Shrager *et al.*, 2006) nor plays a unique role in semantic processing (Squire *et al.*, 2004); instead, the entire anterior medial temporal lobe (perirhinal cortex, entorhinal cortex and hippocampus) subserves the acquisition and recall of semantic memories (Manns *et al.*, 2003; Squire *et al.*, 2004). The testing of these opposing views of perirhinal cortex function has been hampered by the fact that in humans, lesions including the perirhinal cortex typically encompass large expanses of the anterior and anteromedial temporal lobe, such that the precise neuroanatomical locus of the functional impairments is difficult to determine. In the present study, we tested these competing accounts by relating the structural integrity of detailed native-space regions of interest for the perirhinal cortex, entorhinal cortex and hippocampus to picture naming performance using stimuli in which we varied the perceptual and semantic confusability of the objects. Participants included patients with Alzheimer's disease and amnesic mild cognitive impairment, a putative Alzheimer's disease prodrome (Petersen, 2004), who are known to exhibit various degrees of anterior medial temporal lobe atrophy (Braak and Braak, 1991; Lerch *et al.*, 2005).

The claim that perirhinal cortex is important for discriminating between visually confusable objects derives from the hierarchical account of object processing developed in non-human primates. This model of object processing claims that the complexity of neural representations increases from posterior occipital areas through ventral temporal to the anterior and anteromedial temporal regions (Ungerleider and Mishkin, 1982; Mishkin *et al.*, 1983). The perirhinal cortex represents the culmination of this object processing pathway, performing the most complex feature computations required to discriminate confusable objects, especially those with a high degree of visual feature overlap (Bussey and Saksida, 2002; Buckley and Gaffan 2006; Saksida and Bussey, 2010). For example, Buckley *et al.*, (2001) presented simultaneous visual discrimination trials to unoperated control and perirhinal cortex-lesioned monkeys. The authors found that lesioned monkeys performed normally in shape or size oddity discriminations, but performed worse than control monkeys in perceptually demanding trials with e.g. degraded stimuli (see also Buckley and Gaffan, 1998; Bussey *et al.*, 2002, 2003, 2005). In extending this model to humans, functional MRI studies have shown increased activity in the perirhinal cortex during demanding object discriminations, indicating that the perirhinal cortex is normally engaged for these tasks (Tyler *et al.*, 2004; Lee *et al.*, 2008; O'Neil *et al.*, 2009; Barense *et al.*, 2010). Evidence for the 'necessity' of the human perirhinal cortex for complex perceptual discriminations is provided by studies in patients with large anterior

medial temporal lobe lesions including the perirhinal cortex. These patients are impaired in demanding perceptual discriminations (Lee *et al.*, 2005a, b) and discriminations between visually ambiguous stimuli (Barense *et al.*, 2005, 2007) in non-mnemonic tasks. Thus, these latter studies suggest that the human anterior medial temporal lobe is critical for fine-grained visual discriminations, but do not demonstrate that the perirhinal cortex specifically is required for this perceptual function.

The perirhinal cortex receives and integrates uni- and polymodal input (Suzuki and Amaral, 1994a; Murray *et al.*, 1998), leading authors to claim that it facilitates the construction of coherent multimodal object representations corresponding to our 'semantic' object memories (Eacott *et al.*, 1994; Murray and Richmond, 2001). Based on this pattern of connectivity, a feature-based hierarchical model of human semantic memory claims that the perirhinal cortex is necessary for discriminating between not only perceptually ambiguous objects but also semantically ambiguous objects (Tyler *et al.*, 2004; Moss *et al.*, 2005; Taylor *et al.*, 2006). The degree to which a concept is semantically ambiguous can be quantified on the basis of data from large-scale property norm studies, where healthy participants list all features they can think of that belong to a concept (Cree and McRae, 2003; Randall *et al.*, 2004; McRae *et al.*, 2005; Vinson and Vigliocco, 2008). Although this methodology has its drawbacks (McRae, 2004), the regularities in the statistical properties of object features have been shown to affect behaviour on a variety of conceptual tasks (see Taylor *et al.*, 2011 for a review). A critical feature statistic is 'distinctiveness', that is, the inverse of the number of the concepts in which the feature occurs, which reflects the extent to which a feature is shared by many concepts or is distinctive to a particular concept. Although shared features are informative about the category to which a concept belongs (e.g. an object with four legs and eyes is likely to be a living thing, an animal), distinctive features (e.g. has humps) are further required to determine the object's unique identity. Indeed, Taylor *et al.* (2012) demonstrated that basic-level picture naming latencies were significantly facilitated for objects with relatively more distinctive features compared with objects with relatively more shared features. Importantly, living and non-living things systematically differ with respect to the statistical characteristics of their features. Specifically, living things are naturally ambiguous because they share many features with their category members (e.g. many animals have eyes, legs and live on farms) and have relatively few distinctive features (e.g. few animals have stripes) compared with non-living things, which consist of fewer features overall and a higher proportion of distinctive features (Humphreys and Forde, 2001; Tyler and Moss, 2001; Cree and McRae, 2003; Randall *et al.*, 2004; Moss *et al.*, 2007; Taylor *et al.*, 2007). These differences in feature statistics render living things more confusable with respect to basic-level identity.

Based on the hierarchical model of human semantic memory and the noted differences in feature statistics, Taylor *et al.* (2006) predicted that the processing of living things requires more complex feature computations underpinned by the perirhinal cortex than the processing of non-living things. Consistent with this hypothesis, greater perirhinal cortex activity was found during the crossmodal integration of living things' compared with

non-living things' features (Taylor *et al.*, 2006). Evidence consistent with the notion that the perirhinal cortex is necessary for the disambiguation of perceptually and semantically confusable objects comes from neuropsychological studies showing that widespread anterior medial temporal lobe lesions, most typically those associated with herpes simplex encephalitis, are associated with disproportionate impairments with processing the meaning of living compared with non-living things (Warrington and Shallice, 1984; Pietrini *et al.*, 1988; Moss *et al.*, 1998, 2005; Gainotti, 2000; Brambati *et al.*, 2006; Taylor *et al.*, 2009; see Humphreys and Forde, 2001 for a review). Critically, the specificity of the relationship between perirhinal cortex damage and difficulty identifying confusable living compared with less confusable non-living objects has not yet been shown in patients, as their lesions typically extend throughout the anterior medial temporal lobe and anterolateral temporal lobe (Gainotti, 2000).

An alternative, unitary model argues that the perirhinal cortex plays no special role in the disambiguation of perceptually confusable objects (Squire *et al.*, 2004; Levy *et al.*, 2005; Shrager *et al.*, 2006; Suzuki *et al.*, 2009; Squire and Wixted, 2011), that is, 'the perirhinal cortex is not necessary for making difficult visual discriminations, including discriminations between stimuli with a high degree of feature ambiguity' (Levy *et al.*, 2005, p. 64). For example, Shrager *et al.* (2006) found that patients with anterior medial temporal lobe lesions were unimpaired relative to control participants in visual discrimination tasks with perceptually ambiguous stimuli. These authors suggest that previous findings supporting the involvement of perirhinal cortex in the processing of confusable objects may be accounted for by poor control for lesion location, which may have extended anteriorly and laterally, outside the anterior medial temporal lobe (Shrager *et al.*, 2006; Squire and Wixted, 2011; but see Lee and Rudebeck, 2010). However, with respect to semantic processing, the unitary account claims that the entire anterior medial temporal lobe complex (i.e. the hippocampus, entorhinal cortex and perirhinal cortex) is required for accessing semantic memories (Manns *et al.*, 2003; Squire *et al.*, 2004) and that 'structures of the medial temporal lobe are richly interconnected (Lavenex and Amaral, 2000), and attempts to differentiate between the hippocampal region and the adjacent cortex based on sharp dichotomies... are unlikely to be successful' (Manns *et al.*, 2003, p. 131). Thus, although the unitary account claims that the perirhinal cortex is not necessary for disambiguating perceptually confusable objects, it predicts that the perirhinal cortex, together with the entorhinal cortex and hippocampus, is involved in accessing semantic memories. As semantically confusable concepts are expected to engage the semantic system more than semantically less confusable concepts, and as all anterior medial temporal lobe structures are claimed to support semantic retrieval (Manns *et al.*, 2003; Squire *et al.*, 2004), this account predicts that all anterior medial temporal lobe structures will show an effect of semantic confusability.

The present study aims to test these competing accounts of perirhinal cortex function with respect to the disambiguation of perceptually and semantically confusable objects using stringent anatomical criteria. Alzheimer's disease provides a disease model with which to test these issues, as neurofibrillary pathology associated with cognitive dysfunction begins in the medial perirhinal

cortex ('transentorhinal cortex') before spreading to downstream anterior medial temporal lobe structures and on to the rest of the cortex (Braak and Braak, 1991; Taylor and Probst, 2008). As the anterior medial temporal lobe is an anatomically highly variable region, we use *a priori* defined anatomical regions of interest, and individually quantify these in native space for each participant to acquire estimates of perirhinal cortex and entorhinal cortex thickness and hippocampal volume (Kivisaari *et al.*, in press). To obtain measures of object confusability, we used the semantic feature-based statistic data described previously (Gonnerman *et al.*, 1997; Tyler *et al.*, 2000; Tyler and Moss, 2001; McRae *et al.*, 2005). Specifically, living things tend to have many shared features (i.e. those that occur in many concepts, e.g. has four legs) and relatively few distinctive features (i.e. those that occur in few concepts, e.g. has wool) compared with non-living things (Cree and McRae, 2003; Randall *et al.*, 2004; for reviews see Tyler and Moss, 2001; Taylor *et al.*, 2007). Thus, living things are inherently more perceptually and semantically confusable at the basic-level than non-living things. This relationship is predicted to be modulated by the number of features in a concept and degree of global brain damage (Pexman *et al.*, 2002, 2003; see Plaut and Shallice, 1993 for a computational account); specifically, as non-living things have fewer features than living things (Tyler and Moss, 2001; Randall *et al.*, 2004; Taylor *et al.*, 2007), global brain damage is predicted to disproportionately affect the representations of low number of features non-living things, rendering non-living things more difficult to identify at the basic-level (Moss and Tyler, 2000; Moss *et al.*, 2002). As successful object identification depends both on the integrity of the representations and the neuroanatomical disambiguation processes available, the basic-level identification of impoverished representations of non-living things because of higher levels of global brain damage is expected to require more fine-grained analyses for their basic-level identification (compare Moss and Tyler, 2000; Moss *et al.*, 2005).

Integrating the assumptions of the feature statistic account with the hierarchical model leads to the prediction that at low levels of global brain damage, perirhinal cortex atrophy will be associated with disproportionately poorer performance with living compared with non-living objects. In the presence of higher levels of global brain atrophy, perirhinal cortex thinning is expected to be additionally associated with increasingly worse basic-level identification performance with non-living things whose representations have been degraded by global brain damage. In contrast, the unitary model predicts that the perirhinal cortex is neither involved in discriminating perceptually ambiguous objects (Levy *et al.*, 2005; Shrager *et al.*, 2006) nor does it play a unique role in accessing semantic object memories (Manns *et al.*, 2003; Squire *et al.*, 2004). Instead, the entire anterior medial temporal lobe complex is expected to support access to declarative (semantic) memory (Manns *et al.*, 2003; Squire *et al.*, 2004). Thus, as the recognition of semantically confusable objects is expected to engage the semantic system more than the recognition of semantically less confusable objects, all anterior medial temporal lobe structures are predicted to be associated with this process. We tested these competing predictions in a basic-level picture naming task with matched sets of living and non-living pictures by relating relative naming performance to the integrity of detailed

native-space neuroanatomical regions of interest for the perirhinal cortex, entorhinal cortex and hippocampus while taking into account the level of global atrophy.

Materials and methods

Participants

Forty native Swiss–German or German speaking adults participated in this study [mean age = 73.1 years, standard deviation (SD) = 6.7 years; mean education = 11.8 years, SD = 2.8 years; 50% were female subjects]. Fourteen participants were healthy control individuals recruited from two longitudinal research studies on ageing and dementia at the Memory Clinic, Department of Geriatrics at the University Hospital Basel (Monsch *et al.*, 2000). Eleven participants were diagnosed with amnesic mild cognitive impairment, a putative prodrome of Alzheimer's disease, according to the Winblad *et al.* (2004) criteria. Fifteen individuals were diagnosed with Alzheimer's disease according to the Diagnostic and Statistical Manual of Mental Disorders, fourth edition (American Psychiatric Association, 1994) and NINCDS-ADRDA criteria (McKhann *et al.*, 1984). The demographic characteristics and Mini-Mental State Examination scores (Folstein *et al.*, 1975) of all groups are shown in Table 1. The groups did not differ with respect to educational attainment or the percentage of female participants. Group differences approached significance with respect to mean age; therefore, age was covaried in all statistical participant analyses. As expected, the groups differed significantly with respect to their Mini-Mental State Examination scores. We note that patients with Alzheimer's disease were in mild stages of the disease according to this measure (Monsch *et al.*, 1995). This study was approved by the ethics committee of both the University of Basel and University Hospital Basel, and informed consent was obtained from each participant. A summary of participants' neuropsychological test performance is provided in Supplementary Table 1.

Picture naming task

Stimuli

Sixty realistic colour pictures were selected for the experiment. Half of the pictures represented objects from the living domain (i.e. animals, fruits/vegetables) and half from the non-living domain (i.e. vehicles, tools; see Supplementary Table 2 for complete list of stimuli). The stimuli were matched as closely as possible across domain on the following psycholinguistic and visual variables: concept agreement, familiarity, H-statistic, age of acquisition, lemma frequency, number of phonemes, number of letters, subjective visual complexity and two

objective measures of visual complexity, that is, file size and number of pixels in the digital picture file (Supplementary material). Because different categories of objects differ with respect to visual complexity and familiarity measures, that is, vehicles and animals contain more visual information and tend to be rated as less familiar than fruits and tools, we split each domain into two groups, such that half of the objects were visually complex (animals, vehicles) and half visually simple (fruits/vegetables, tools). Two of the test items (spade, van) were excluded from the statistical analyses because they were correctly named by <50% of the healthy control participants (i.e. 7 and 47%, respectively). Thus, the final stimulus set consisted of 15 objects each in the animal and fruit/vegetable categories, and 14 objects each in the vehicle and tool categories. Living and non-living domains differed only with respect to the H-statistic (Supplementary Table 3).

Procedure

The behavioural task began with five novel practice items (not included in the statistical analyses) followed by the 60 test stimuli. The order of items from different categories was pseudo-randomized such that there were no more than three consecutive pictures from the same domain or category and no more than four consecutive pictures from the same visual complexity level. All stimuli were presented in the centre of a computer monitor. Each trial started with a 200 ms signal tone followed by 1500 ms of silence. The picture then appeared on the computer monitor for 1000 ms, after which the participants had 3000 ms to name the picture. An intertrial interval of 2000 ms followed the response or time-out. The participants were instructed to say the name of the pictured object out loud as quickly and as accurately as possible, and to press a response key once they had begun saying the name. The experimenter recorded the participant's verbal response. Two judges scored all verbal responses as correct or incorrect, and conflicting ratings were resolved in a consensus conference. DMDX software controlled presentation timings and participant responses (Forster and Forster, 2003).

Behavioural variables and statistical analyses

As the domains had unequal numbers of items, all statistical analyses used proportion correct. To test the key predictions outlined in the 'Introduction' section, we created a domain index representing the relative performance on living compared with non-living things: [(proportion correct living – proportion correct non-living)/(proportion correct living + proportion correct non-living)] × 100. On this measure, positive scores indicated poorer performance with non-living than living things, and negative scores indicated poorer performance with living than non-living things. We analyzed the behavioural data using SPSS version 19 (SPSS Inc. and IBM company, 2010). Age was used as a covariate in all statistical analyses. The pairwise comparisons for

Table 1 Demographic characteristics and Mini-Mental State Examination scores of the healthy control, amnesic mild cognitive impairment and Alzheimer's disease groups

Demographic and neuropsychological screening variables	Diagnosis			F/ χ^2	P-value
	Healthy control	Amnesic mild cognitive impairment	Alzheimer's disease		
<i>n</i>	14	11	15		
Age (years)	71.6 (6.1)	70.8 (6.3)	76.0 (6.9)	2.6	0.09
Education (years)	12.1 (2.2)	10.5 (2.4)	12.3 (3.4)	1.7	0.2
Percentage of female subjects	35.7	54.4	60.0	1.8 ^a	0.4
Mini-Mental State Examination score	29.3 (0.7)	27.8 (1.3)	25.9 (2.8)	11.5	<0.001

^a χ^2 -test; values are mean (SD).

group were Bonferroni-corrected by the number of pairwise comparisons conducted (with a corrected α of $0.05/3 = 0.017$).

Magnetic resonance imaging acquisition and processing

Image acquisition

MRI scanning and behavioural testing were conducted on average within a 3-month period (mean interval = 2.4 months, SD = 2.4 months). All structural scans were acquired on the same 3-T MRI scanner (MAGNETOM Allegra, Siemens) at the University Hospital Basel using a high-resolution T_1 -weighted 3D MPRAGE sequence with a headcoil (inversion time = 1000 ms, repetition time = 2150 ms, echo time = 3.5 ms, flip angle = 7° ; rectangular field of view = 87.5%, acquisition matrix = 256×224 mm, voxel size = 1.1 mm isotropic).

Cortical surface reconstructions

We focused on the following *a priori* defined anatomical regions of interest in the left hemisphere to test the predictions outlined in the 'Introduction' section: (i) perirhinal cortex; (ii) entorhinal cortex; and (iii) hippocampus. Only left hemisphere regions of interest are considered here because the task required a verbal response (results for right hemisphere regions of interest are reported in the Supplementary material). Because neurofibrillary pathology in Alzheimer's disease begins in the medial perirhinal cortex (corresponding to the transentorhinal cortex: Braak and Braak, 1991; Taylor and Probst, 2008), we quantified the lateral and medial perirhinal cortex separately (see later in the text).

Cortical thickness measurements for the key anteromedial temporal lobe regions of interest were based on surface reconstructions of MPRAGE images created in FreeSurfer (Massachusetts General Hospital, Boston, MA; <http://surfer.nmr.mgh.harvard.edu>; Dale *et al.*, 1999; Fischl *et al.*, 1999) followed by anatomical surface tracings described later in the text. FreeSurfer segments the MPRAGE volumes into grey and white matter in a semi-automatic processing stream. It builds a subcortical mass to model the white matter surface, and extends it outwards by tracking the grey matter intensity gradient to form the pial surface (Dale *et al.*, 1999). The white matter and pial surfaces are represented as two meshes of connected vertices, and the thickness of the cortical mantle is defined as the distance between corresponding vertices on the two surfaces. The tissue next to the anterior medial temporal lobe structures, which interfered with the cortical surface reconstructions, was manually removed. In contrast to the cortical thickness measurements for the key anterior medial temporal lobe structures, the volume of the hippocampus (which has no meaningful thickness) was acquired with the automatic subcortical registration procedure in FreeSurfer (Fischl *et al.*, 2002).

Anatomical surface tracings

We manually labelled anatomic regions of interest for the lateral perirhinal cortex, medial perirhinal cortex (i.e. transentorhinal cortex) and entorhinal cortex on the cortical surface reconstructions described previously. Labelling followed a surface-volumetric protocol (Goncharova *et al.*, 2001; Feczko *et al.*, 2009) using the landmarks from anatomical and pathological studies of the parahippocampal gyrus (Insausti *et al.*, 1998; Taylor and Probst, 2008; Kivisaari *et al.*, in press). As surface reconstructions are susceptible to inaccuracies in the most anteromedial regions of the temporal lobe (compare Feczko *et al.*, 2009), we restricted labelling to the posterior portions of the entorhinal cortex and perirhinal cortex at the anterior border of the hippocampus (see later in the text). Surface tracings were not conducted for

one healthy control and one participant with Alzheimer's disease because of the inferior quality of their medial temporal lobe surface reconstructions. These participants were removed from all region of interest analyses.

Definition of anatomical boundaries

All landmarks were localized on coronal slices of volumes reoriented along the anterior commissure–posterior commissure axis (Fig. 1). Moving from rostral to caudal levels, the anterior border of lateral and medial perirhinal cortex used in this study (see earlier in the text) was the midpoint (i.e. largest extent) of the mamillary bodies along their rostrocaudal axis. Because of the inaccuracies in reconstruction of the angular bundle (compare Feczko *et al.*, 2009), the anterior border of the entorhinal cortex was conservatively defined as 3 mm posterior to the slice where the posterior end of the mamillary bodies was last visible. The posterior border of the lateral and medial perirhinal cortex and the entorhinal cortex was 2 mm posterior to the apex of the intralimbic gyrus (Insausti *et al.*, 1998). As the regions of interest were drawn posterior to the rostral tip of the hippocampus, the uncus notch was used as the medial border of the entorhinal cortex (Insausti *et al.*, 1998). The shoulder of the medial bank of the collateral sulcus always served as the border between the entorhinal cortex and medial perirhinal cortex (Taylor and Probst, 2008; Dickerson *et al.*, 2009b). Because the location of the transentorhinal cortex depends on the shape and depth of the collateral sulcus (Taylor and Probst, 2008), we adjusted the label borders accordingly. In the majority of cases where the collateral sulcus was ≤ 1.5 cm deep ($n = 87\%$), the border between the medial perirhinal cortex and the lateral perirhinal cortex was defined as the fundus of the collateral sulcus (Fig. 1A). The lateral border of the lateral perirhinal cortex was then the shoulder of the lateral bank of the collateral sulcus. If the collateral sulcus was > 1.5 cm deep ($n = 13\%$), the border between the medial and lateral perirhinal cortex was the midpoint between the shoulder of the medial bank of the collateral sulcus and the midpoint of the lateral bank of the collateral sulcus (Fig. 1B; Insausti *et al.*, 1998; Taylor and Probst, 2008; Kivisaari *et al.*, in press). In these instances, the lateral border of the lateral perirhinal cortex was the midpoint of the lateral bank of the collateral sulcus. In cases of bifurcated collateral sulci ($n = 13\%$), the criteria described previously were applied to the medial-most sulcus (Taylor and Probst, 2008). All manual tracings were performed by one of the authors blind to diagnosis (S.L.K.).

Estimates of global atrophy level

To estimate the overall reduction in grey matter with respect to a fixed baseline, we related the volume of the grey matter to the volume of the whole cranium. For this purpose, we used Statistical Parametric Mapping software (SPM8, Wellcome Institute of Cognitive Neurology, www.fil.ion.ucl.ac.uk) running in MATLAB 2010 (Mathworks Inc.). The images were segmented into grey matter with bias correction. Masks were manually drawn on the tissue misclassified as grey matter, and these areas were removed from the native space T_1 images. These corrected native space T_1 images were then segmented into grey matter, white matter and CSF while masking the voxels with zero intensity. Volumes of each tissue type were extracted (`get_totals65.m`; <http://www.cs.ucl.ac.uk/staff/G.Ridgway/vbm/>), and each grey matter volume was divided by the corresponding total intracranial volume (i.e. sum of grey matter, white matter and CSF volumes) to create a 'grey matter index'. Finally, these ratios were dichotomized to create a binomial 'atrophy' variable for use in the regression analyses, in which zero values indicated a grey matter index in the uppermost 26th–100th percentile (i.e. no/mild atrophy), and a value of 1 indicated a grey matter index in the bottom

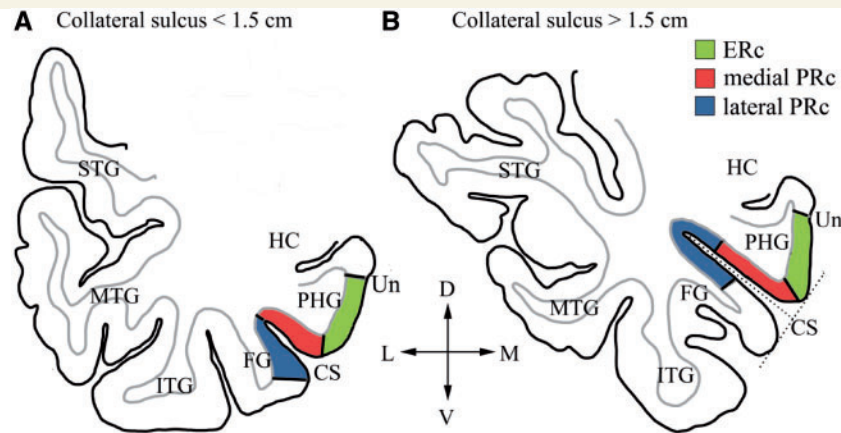


Figure 1 Anatomical border definitions of lateral perirhinal cortex (PRc), medial perirhinal cortex and entorhinal cortex (ERc) in two coronal MRI slices. The anatomical borders are indicated with solid lines perpendicular to the cortical surface. The dashed lines represent the collateral sulcus measurement (Taylor and Probst, 2008). Anatomical borders were adjusted according to the depth of the collateral sulcus, that is, (A) collateral sulcus < 1.5 cm or (B) collateral sulcus > 1.5 cm (see text for details). CS = collateral sulcus; D = dorsal; FG = fusiform gyrus; HC = hippocampus; ITG = inferior temporal gyrus; L = lateral; M = medial; MTG = middle temporal gyrus; PHG = parahippocampal gyrus; STG = superior temporal gyrus; Un = uncus notch; V = ventral.

quartile (i.e. moderate atrophy). This cut-off was chosen because the majority of our sample was either healthy or only mildly affected (i.e. healthy control and amnesic mild cognitive impairment participants), who were *a priori* assumed to have relatively low levels of global atrophy. This cut-off score resulted in the categorization of two healthy control (14%), three amnesic mild cognitive impairment (27%) and five Alzheimer's disease (33%) participants as members of the moderate atrophy group. The group means on the grey matter index are presented in Table 2.

Validity of volumetric and cortical thickness estimates

To confirm the validity of the volumetric and cortical thickness estimates, we performed two sets of global analyses. First, we correlated overall proportion correct with signal intensities in each voxel across all participants' preprocessed grey matter volumes in SPM8 (Wellcome Institute of Cognitive Neurology, www.fil.ion.ucl.ac.uk) running in MATLAB 2010 (Mathworks Inc.). Second, we correlated overall proportion correct with cortical thickness estimates across the entire left hemisphere and right hemisphere in two independent analyses in FreeSurfer (Massachusetts General Hospital, Boston, MA; <http://surfer.nmr.mgh.harvard.edu>; Dale *et al.*, 1999; Fischl *et al.*, 1999). Both sets of analyses revealed similar patterns of results, thus, confirming the quality of the data and preprocessing. The corresponding methods and results are provided as Supplementary material.

Region of interest statistical analyses

Four separate stepwise linear regression analyses were conducted to predict overall naming performance and domain index scores, one for each anatomic region of interest. Both healthy controls' and patients' data were included in the same regression analysis because clinical-neuropathological studies show that cognitively healthy mature individuals can exhibit Alzheimer's disease-related neurofibrillary pathology in the anterior medial temporal lobe (Braak and Braak, 1997; Polvikoski *et al.*, 2001; Riley *et al.*, 2002; Knopman *et al.*, 2003; Braak *et al.*, 2011), which are assumed to affect the associated functions. Indeed, cortical thinning in clinically healthy controls may signal pre-clinical Alzheimer's disease-related pathological changes (Dickerson *et al.*, 2009a). Variables were entered into each model in two steps.

The first step included only the nuisance covariates: age and left hemisphere mean thickness for models of region of interest thickness; age and grey matter volume for the model of hippocampal volume; and additionally overall naming scores in models of the domain index. The variables of interest (anatomic region of interest, atrophy variable and the interaction of these two variables) were entered into the model in the second step. The results for partial regression models are reported; thus, *F*- and *P*-values reflect whether the model (R^2) significantly improved when the covariates of interest were added to the initial model. Finally, to reduce the likelihood of a Type I error, we used an adjusted α -level that was Bonferroni-corrected by the number of independent region of interest regression analyses conducted to test the main hypotheses of the study (adjusted α level = $0.05/4 = 0.013$). Statistical analyses of the region of interest data were conducted with IBM SPSS Statistics, version 19 (SPSS Inc. and IBM company, 2010).

Results

Behavioural results

To determine whether domain influenced each group's naming performance, we performed a 3 (diagnostic group) \times 2 (domain) ANOVA across participants and over the two categories in each domain. The ANOVAs revealed a main effect of group [$F(2,153) = 22.8$, $P < 0.001$], with healthy control participants performing better than patients with amnesic mild cognitive impairment [$t(98) = 3.4$, $P < 0.017$] and patients with Alzheimer's disease [$t(114) = 7.3$, $P < 0.017$], and patients with amnesic mild cognitive impairment performing better than patients with Alzheimer's disease [$t(102) = 3.7$, $P < 0.017$]. The effect of domain [$F(1,153) = 8.1$, $P = 0.001$] was significant, reflecting a living things disadvantage for all groups. Although this main effect seemed to be driven by the two patient groups (Supplementary Table 4), the interaction between group and domain was non-significant [$F(2,153) = 1.4$, $P = 0.2$], indicating that the patient groups did not exhibit a significantly pronounced

domain-specific naming impairment relative to the healthy control participants. The groups' overall naming performance, naming scores in each domain, and corresponding domain indices are presented in Supplementary Table 4.

Brain–behaviour correlations

Overall basic-level naming performance

For completeness, we report the extent to which each anterior medial temporal lobe area was associated with overall naming performance. To examine this question, we conducted four independent stepwise linear regression analyses predicting the overall proportion correct score with each region of interest. We found that only hippocampal volume significantly predicted overall naming performance [$F(1,34) = 7.8$, $P = 0.009$; $\beta = 0.5$, $t = 2.8$, $P = 0.009$]. The lateral perirhinal cortex [$F(1,34) = 0.08$, $P = 0.8$], medial perirhinal cortex [$F(1,34) = 1.4$, $P = 0.2$] and entorhinal cortex [$F(1,34) = 2.0$, $P = 0.2$] models were non-significant.

Relative basic-level naming performance for living and non-living things

To disentangle the contribution of the perirhinal cortex, entorhinal cortex and hippocampus to the identification of perceptually and semantically confusable compared with less confusable objects, we conducted stepwise linear regression analyses predicting domain index scores with the four anatomic regions of interest. To determine the relationship between relative performance in the living and non-living domains (domain index) and the integrity of the region of interest at mild to more moderate levels of global atrophy, we included the atrophy variable and an interaction term (region of interest \times atrophy). The regression models below test whether inclusion of these three terms (region of interest, atrophy, region of interest \times atrophy) improved the initial model with only

nuisance covariates. The descriptive statistics of all regions of interest are reported in Table 2.

Only the medial perirhinal cortex thickness model significantly predicted domain index scores at the Bonferroni-corrected α level [$F(3,31) = 4.7$, $P = 0.008$]. For all other regions of interest, the inclusion of the covariates of interest did not statistically improve the model: lateral perirhinal cortex thickness [$F(3,31) = 2.1$, $P > 0.013$], entorhinal cortex [$F(3,31) = 2.9$, $P > 0.013$] and hippocampus [$F(3,31) = 2.2$, $P > 0.013$]. Therefore, only the effects of individual predictors from the medial perirhinal cortex thickness model are reported below. For completeness, the results of all individual predictors from all models are reported in Table 3.

The regression analysis with the medial perirhinal cortex thickness revealed that at no/mild levels of atrophy, medial perirhinal cortex thickness significantly positively correlated with domain index scores, indicating that thinner medial perirhinal cortices were associated with fewer correctly named living relative to non-living things. Importantly, global atrophy level significantly interacted with medial perirhinal cortex thickness: at no/mild levels of global atrophy, thinner medial perirhinal cortices were associated with poorer performance with living compared with non-living things, whereas at moderate levels of global atrophy, this effect reversed, such that thinner medial perirhinal cortices were associated with increasingly poorer naming performance with non-living compared with living things (Table 3 and Fig. 2). To ensure that these results were not driven by potential eccentricities of the healthy control group, we repeated the analysis excluding the healthy control participants. In this analysis, the effect of medial perirhinal cortex thickness ($\beta = 0.5$, $t = 2.7$, $P = 0.02$) and the interaction between medial perirhinal cortex thickness and the level of global atrophy ($\beta = -1.9$, $t = -2.4$, $P = 0.03$) remained significant. We note that 8 of 10 participants in the moderate atrophy had an overall disadvantage for living

Table 2 Means and standard deviations of left hemisphere cortical thicknesses estimates (mm) of the lateral and medial perirhinal cortex and entorhinal cortex, hippocampal volume estimates (cm³), and the global atrophy variable

Diagnostic group	<i>n</i>	Lateral perirhinal cortex	Medial perirhinal cortex	Entorhinal cortex	Hippocampus	Grey matter index
<i>n</i>		38	38	38	40	40
Healthy control subjects	14	2.8 (0.5)	2.3 (0.5)	3.5 (0.2)	3.8 (0.4)	0.36 (0.03)
Amnesic mild cognitive impairment	11	2.8 (0.5)	2.2 (0.5)	2.9 (0.3)	3.2 (0.5)	0.35 (0.03)
Alzheimer's disease	15	2.9 (0.6)	2.0 (0.5)	2.9 (0.5)	2.7 (0.4)	0.33 (0.03)

Table 3 Results of five stepwise linear regression models predicting domain index scores with cortical thickness estimates of lateral perirhinal cortex, medial perirhinal cortex and entorhinal cortex and the volume of the hippocampus. We note that only the regression model with the medial perirhinal cortex was significant

Covariate	Lateral perirhinal cortex			Medial perirhinal cortex			Entorhinal cortex			Hippocampus		
	β	<i>t</i>	<i>P</i>	β	<i>t</i>	<i>P</i>	β	<i>t</i>	<i>P</i>	β	<i>t</i>	<i>P</i>
Region of interest	0.3	2.1	0.05	0.5	3.1	0.004	0.6	2.7	0.01	0.6	2.3	0.03
Atrophy	1.6	1.5	0.1	1.9	2.6	0.01	1.0	1.1	0.3	-0.2	-0.3	0.8
Region of interest \times atrophy	-1.8	-1.7	0.1	-2.0	-2.8	0.008	-1.1	-1.2	0.2	-0.04	-0.05	1.0

The predictive strengths of the corresponding regions of interest and global atrophy and the interaction region of interest \times atrophy, are listed for each model. The nuisance variables were entered in the first step and are not shown in this table.

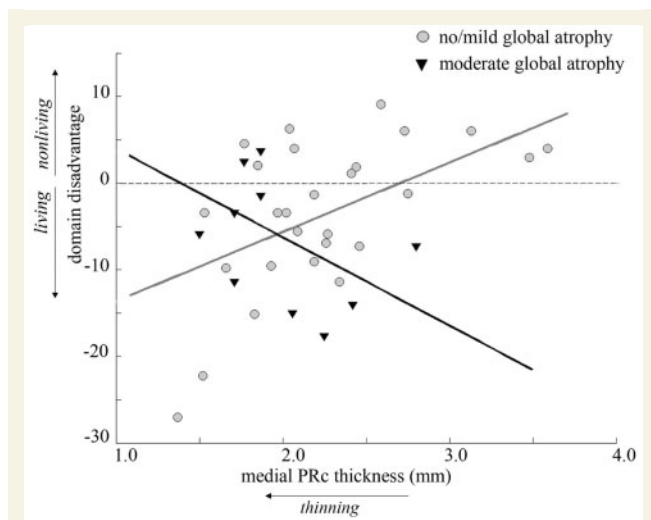


Figure 2 The scatterplot represents the relationship between estimated medial perirhinal cortex (PRc) thickness and the domain index for no/mild and moderate global atrophy levels separately (all covariates held at their mean). At no/mild levels of global atrophy, thinner medial perirhinal cortices are associated with worse performance with living than non-living things (grey line). At moderate levels of global atrophy, this relationship reverses, such that thinner medial perirhinal cortices are associated with worse performance with non-living than living things (black line). The dashed line represents equivalent performance in both domains.

things, as indicated by negative index scores (Fig. 2), such that their overall naming performance was poorer in the living than non-living domain (percentage living and non-living things correct: 74 and 84%, respectively). That is, despite an overall living things impairment within the moderate atrophy group, thinner medial perirhinal cortices were significantly associated with poorer naming of non-living compared with living things. These findings are in line with the hierarchical account, as medial perirhinal cortex thickness was specifically associated with the ability to identify concepts that are either inherently ambiguous (living things) or impoverished (non-living things in the presence of moderate global atrophy).

Two participants had low domain index scores and relatively low cortical thickness values (Fig. 2). To ensure that the results reported previously were not driven by these two participants, we repeated all regression analyses excluding the two outlying participants. We found that the medial perirhinal cortex regression model remained significant at a standard α level of 0.05 [$F(3,29) = 3.7$, $P = 0.02$], as did the effects for medial perirhinal cortex thickness ($\beta = 0.4$, $t = 2.0$, $P = 0.05$), atrophy ($\beta = 1.7$, $t = 2.0$, $P = 0.05$) and the medial perirhinal cortex \times atrophy interaction ($\beta = -1.9$, $t = -2.4$, $P = 0.02$) within this model. By comparison, the models with the lateral perirhinal cortex [$F(3,29) = 2.1$, $P = 0.1$], entorhinal cortex [$F(3,29) = 1.8$, $P = 0.2$] and hippocampus [$F(3,29) = 2.0$, $P = 0.1$] remained non-significant, as did the predictors of interest within these models (all region of interest main effects $P > 0.2$, all region of interest \times atrophy interactions $P > 0.1$). Boxplots for each region of

interest further ruled out the possibility that the pattern of results reported previously emerged because of a truncation in range for the non-significant regions of interest (Supplementary Fig. 1). Taken together, these analyses suggest that the medial perirhinal cortex supports the basic-level identification of perceptually and semantically confusable living things, and that medial perirhinal cortex integrity and the level of global atrophy indeed interact to determine the direction of the domain naming disadvantage in Alzheimer's disease. Significantly, these patterns were specific to the medial perirhinal cortex and not to the surrounding anterior medial temporal lobe areas.

Discussion

Medial perirhinal cortex thinning was associated with a disproportionate difficulty in naming living things at no/mild levels of global atrophy, and at moderate levels of global atrophy, with increasing difficulty in naming impoverished representations of non-living things, in the context of overall living things impairment. Thus, the present study demonstrated that the medial perirhinal cortex (i.e. transentorhinal cortex, Braak and Braak, 1991; Taylor and Probst, 2008) is necessary for identifying perceptually and semantically confusable concepts. Importantly, although similar behavioural performance patterns have been related to widespread anterior and anteromedial temporal lobe lesions (e.g. Taylor et al., 2009), the anatomically defined region of interest approach used here showed that the impairments in distinguishing perceptually and semantically ambiguous objects were specifically related to the medial perirhinal cortex, but not the lateral perirhinal cortex, entorhinal cortex or hippocampus. Moreover, these findings extend former reports on the involvement of the human perirhinal cortex in the disambiguation of perceptually complex objects by demonstrating that perceptually and *semantically* confusable objects require the perirhinal cortex for their discrimination and recognition. These findings, therefore, support a hierarchical account of anterior medial temporal lobe functioning (Bussey et al., 2003, 2005; Tyler et al., 2004; Taylor et al., 2011; Barense et al., 2010), in which the perirhinal cortex, at the apex of the ventral visual object processing stream and site of convergence of multimodal perceptual information, supports discriminations between perceptually and semantically confusable objects, thereby enabling the appreciation of their unique significance.

Consistent with the hypothesized role of the perirhinal cortex in disambiguating and thereby identifying perceptually and semantically ambiguous objects (Buckley and Gaffan, 1998, 2006; Buckley et al., 2001; Bussey and Saksida, 2002; Saksida and Bussey, 2010; Taylor et al., 2011), medial perirhinal cortex thinning was associated with a disproportionate difficulty in naming living things at no/mild levels of atrophy. This result indicates that perirhinal cortex atrophy disrupts the disambiguation of inherently confusable living things, which consist of a large number of shared features and few distinctive features, compared with non-living things, which consist of fewer features overall and a greater proportion of distinctive to shared features (Tyler and Moss, 2001; Cree and McRae, 2003; Randall et al., 2004). However, sparser representations of non-living things are expected to be more

susceptible to moderate levels of global atrophy than rich representations of living things, as probabilistically, the sparse representations of the non-living things lose a greater proportion of their features from global damage (Moss and Tyler, 2000; Moss *et al.*, 2000; see also Plaut and Shallice, 1993; Pexman *et al.*, 2003). Indeed, global atrophy interacted with medial perirhinal cortex thickness: medial perirhinal cortex thinning was associated with an increasing disadvantage for non-living things at moderate levels of atrophy in the context of general living things impairment. These effects remained significant even after excluding the healthy control group from the analysis, demonstrating that the primary findings were not driven by factors specific to the healthy control participants. Thus, these findings indicate that the perirhinal cortex is not involved in the identification of living things *per se*, but the identification of perceptually and semantically confusable objects, whether they are inherently confusable living things or the degraded representations of non-living things.

The unitary model of anterior medial temporal lobe function postulates that the perirhinal cortex alone does not support the perceptual discrimination of ambiguous objects (Levy *et al.*, 2005; Shrager *et al.*, 2006; Suzuki, 2009). Rather, all anterior medial temporal lobe structures are predicted to be involved in accessing semantic memory (Manns *et al.*, 2003; Squire *et al.*, 2004). As semantically confusable objects are expected to engage the semantic system more than semantically simple objects, the unitary view predicts that the integrity of all anterior medial temporal lobe structures should be associated with a disadvantage for semantically confusable objects (compare Manns *et al.*, 2003; Squire *et al.*, 2004). The present results based on strict anatomic differentiation within the anterior medial temporal lobe do not support this prediction: only the integrity of the medial perirhinal cortex, but not that of the lateral perirhinal cortex, entorhinal cortex or hippocampus, was significantly associated with a disproportionate impairment in naming confusable objects. A recent formulation of the unitary account allows for the relatively greater involvement of the perirhinal cortex (i.e. relative to the entorhinal cortex and hippocampus) in visual object memory: 'Based on anatomy, it seems reasonable to suppose that perirhinal cortex plays an important role in . . . visual recollection (e.g. when a visual stimulus is used as a retrieval cue to recollect its visual paired associate)' (Wixted and Squire, 2011, p. 212). This claim would be consistent with a greater involvement of the perirhinal cortex than the entorhinal cortex and hippocampus in overall picture naming performance. However, the present results demonstrate that overall picture naming was significantly related to hippocampal, not perirhinal cortex or entorhinal cortex integrity. Thus, the perirhinal cortex does not seem to play a special role in object recognition *per se*, but in the disambiguation and, thus, recognition of perceptually and semantically complex objects, consistent with a hierarchical account of object representations (Tyler *et al.*, 2004; Moss *et al.*, 2005; Saksida and Bussey, 2010; see also Winters *et al.*, 2008).

Studies of patients with semantic dementia localize general semantic processing to the anterolateral temporal lobe structures, such as the temporal pole (Mummery *et al.*, 2000; Levy *et al.*, 2004; Hodges and Patterson, 2007). These observations are not incompatible with the claims made here. Specifically, the anterolateral structures and the perirhinal cortex may be involved in

semantic processing, but may make qualitatively different contributions. To test this possibility and to ensure that the present findings were not driven by pathology extending into the anterolateral areas (Levy *et al.*, 2004; Squire *et al.*, 2004; Squire and Wixted, 2011), we conducted additional region of interest analyses. We used FreeSurfer's automatic surface parcellation (Desikan *et al.*, 2006) to acquire the thicknesses of the temporal poles and inferotemporal gyri of each participant, and we used analogous regression models (see 'Materials and methods' section) to examine whether the thickness of these regions predicts picture naming performance (Supplementary material). These analyses revealed that the thickness of the temporal poles, but not inferior temporal gyri, was indeed associated with the proportion of overall correctly named objects, but not with the domain index scores. Thus, although the anterolateral temporal lobe areas may play a general role in processing semantic knowledge as suggested by findings from patients with semantic dementia (Mummery *et al.*, 2000; Levy *et al.*, 2004; Squire *et al.*, 2004; Hodges and Patterson, 2007), they do not seem to play a specific role in processing perceptually and semantically ambiguous objects (see also Moss *et al.*, 2005).

Because the medial perirhinal cortex is the first region affected by neurofibrillary pathology in Alzheimer's disease (Braak and Braak, 1991; Taylor and Probst, 2008), the present result suggests that a relative difficulty naming living compared with non-living things in the context of relatively mild overall atrophy may serve as a specific early cognitive marker of the disease. Furthermore, the reverse naming pattern at moderate levels of global atrophy suggests that the living things naming impairment may be transitory. Taken together, these patterns may account for the mixed results in earlier behavioural studies of category-specific semantic impairments in Alzheimer's disease (Gonnerman *et al.*, 1997; Garrard *et al.*, 1998; Moreno-Martínez and Laws, 2008; see Laws *et al.*, 2007 for a meta-analysis) and the present behavioural results, which showed no significant group by domain interactions. Specifically, the heterogeneity in the degree and distribution of atrophy may generate competing domain effects, thereby attenuating differences between diagnostic groups. This heterogeneity is not surprising given that some cognitively healthy mature individuals exhibit early stage Alzheimer's disease pathology on post-mortem neuropathological examination (Braak and Braak, 1997; Polvikoski *et al.*, 2001; Riley *et al.*, 2002; Knopman *et al.*, 2003; Braak *et al.*, 2011). Thus, the integrity of the semantic system globally (indexed here by global atrophy) and the medial perirhinal cortex more focally, should be considered as mechanisms driving category-specific semantic impairments (Moss and Tyler, 2000; Moss *et al.*, 2000; compare Moss *et al.*, 2005).

Our findings may seem to be at odds with a study by Lee *et al.* (2006), which investigated visual discrimination performance with faces and simple computerized scenic images in seven patients with Alzheimer's disease. Using an odd-one-out task, these authors found that participants with Alzheimer's disease performed significantly poorer than their control participants on scene, but not face, discriminations. However, the ventral stream network involved in human face processing only partially overlaps with that required for non-face object processing (e.g. Kanwisher *et al.*, 1997), suggesting that face recognition relies on specialized

neural circuitry (Nelson, 2001; Pascalis and Kelly, 2009). Thus, patients' performance with faces cannot be generalized to non-face object processing. Moreover, Lee *et al.* (2006) neither explicitly manipulated the degree of feature overlap in their visual stimuli nor did they relate performance specifically to perirhinal cortex integrity. Thus, object processing impairments in their patients with Alzheimer's disease may have emerged if real and meaningful objects had been used, the extent of feature overlap manipulated and specific functional–neuroanatomical relationships tested. Interestingly, a follow-up study by the same group (Lee *et al.*, 2007) implemented these stimulus factors. In this study, (i) a lion and a dog; and (ii) a guitar and a cello, were morphed together to create different levels of visual overlap, and participants decided whether the morphed lion–dog and guitar–cello pairs were the same or different. Consistent with the present findings, the participants with Alzheimer's disease committed numerically more errors than control participants on the object discrimination trials with the highest degree of visual overlap (see Lee *et al.*, 2007, p. 2141), although this difference was not statistically tested.

The results presented here are consistent with a hierarchical view of object processing, whereby perirhinal cortex at the top of the object processing hierarchy binds perceptual and semantic features of confusable objects together to enable their identification (Murray and Richmond, 2001). Information processed in the perirhinal cortex is forwarded to the entorhinal cortex, which presumably integrates it with visuospatial information from the parahippocampal cortex and higher-order information from other association cortices (Insausti *et al.*, 1987; Suzuki and Amaral, 1994*b*; Canto *et al.*, 2008), and transmits its output to the hippocampus (Witter and Amaral, 1991). Lavanex and Amaral (2000) conceived this system as a hierarchy of associativity, in which increasingly more elaborate representations are computed (see also Mishkin *et al.*, 1997; Eichenbaum, 2000; Cowell *et al.*, 2009). In this context, the finding that hippocampal integrity predicted overall naming performance can be interpreted as reflecting recall of higher-order associative information from semantic memory, a process common to the basic-level naming of many different types of concepts.

To our knowledge, the present study is the first to show that the human medial perirhinal cortex is necessary for the disambiguation of perceptually and semantically confusable objects and, importantly, that this function distinguishes it from more medial anterior medial temporal lobe areas and lateral temporal cortex. The present results, therefore, extend those reported by Davies *et al.* (2004), who demonstrated that performance on two common clinical tests of semantic memory—animal fluency and picture naming—significantly correlated with left and right perirhinal cortex volumes, but not the volumes of the entorhinal cortex and hippocampi, in eight patients with semantic dementia (see also Hirni *et al.*, 2011). Moreover, although numerous studies have demonstrated a relationship between the perirhinal cortex and the disambiguation of perceptually confusable objects, we show here that the disambiguation capabilities of the perirhinal cortex extend to non-perceptual, semantically confusable objects. Feature-based statistical models (e.g. Tyler and Moss, 2001) provide the theoretical grounds on which to determine and, therefore,

generate predictions about an object's semantic confusability and, thus, dependence on the perirhinal cortex for disambiguation. The role of the perirhinal cortex may be characterized in terms of the processes it performs on ambiguous patterns of input (Moss *et al.*, 2005), the representations of specific types of content (Cowell *et al.*, 2010; Saksida and Bussey, 2010) or a combination of these two factors. Given that living things tend to be more perceptually and semantically ambiguous compared with non-living things, as demonstrated by feature statistic accounts (e.g. Tyler and Moss, 2001), the present results additionally provide an explanation of why the syndrome of category-specific semantic impairments for living things are associated with anterior medial temporal lobe damage (see also Moss *et al.*, 2005), and critically, pinpoint the root of this syndrome to perirhinal cortex damage.

Acknowledgements

The authors would like to thank Professor Manfred Berres for statistical assistance and Professor emeritus Alphonse Probst for his anatomical advice.

Funding

Swiss National Science Foundation Ambizione Fellowship (to K.I.T.), the Swiss Alzheimer's Association (PZ00P1_126493; to K.I.T.), Swiss Foundation for Ageing Research (financed by the Loterie Romande) (to K.I.T.), a Young Clinical Researcher Grant from the University of Basel (to K.I.T.), a Tilma Hainari Jubilee Grant from the Finnish Concordia Fund (to S.L.K.), the Swiss Federal Commission for Scholarships for Foreign Students (Berne) (to S.L.K.), European Research Council Advanced Investigator grant (249640; to L.K.T.). The MRI scans were financed by grants from the Novartis Foundation (to A.U.M.) and GlaxoSmithKline (to A.U.M.).

Supplementary material

Supplementary material is available at *Brain* online.

References

- American Psychiatric Association. Diagnostic and statistical manual of mental disorders. 4th edn. Washington, DC: American Psychiatric Association; 1994.
- Barens MD, Gaffan D, Graham KS. The human medial temporal lobe processes online representations of complex objects. *Neuropsychologia* 2007; 45: 2963–74.
- Barens MD, Henson RN, Lee AC, Graham KS. Medial temporal lobe activity during complex discrimination of faces, objects, and scenes: effects of viewpoint. *Hippocampus* 2010; 20: 389–401.
- Barens MD, Bussey TJ, Lee AC, Rogers TT, Davies RR, Saksida LM, *et al.* Functional specialization in the human medial temporal lobe. *J Neurosci* 2005; 25: 10239–46.
- Braak H, Braak E. Neuropathological staging of Alzheimer-related changes. *Acta Neuropathol* 1991; 82: 239–59.

- Braak H, Braak E. Frequency of stages of Alzheimer-related lesions in different age categories. *Neurobiol Aging* 1997; 18: 351–7.
- Braak H, Thal DR, Ghebremedhin E, Del Tredici K. Stages of the pathologic process in Alzheimer disease: age categories from 1 to 100 years. *J Neuropathol Exp Neurol* 2011; 70: 960–969.
- Brambati SM, Myers D, Wilson A, Rankin KP, Allison SC, Rosen HJ, et al. The anatomy of category-specific object naming in neurodegenerative diseases. *J Cogn Neurosci* 2006; 18: 1644–53.
- Buckley MJ, Gaffan D. Perirhinal cortex ablation impairs visual object identification. *J Neurosci* 1998; 18: 2268–75.
- Buckley MJ, Gaffan D. Perirhinal cortical contributions to object perception. *Trends Cogn Sci* 2006; 10: 100–7.
- Buckley MJ, Booth MC, Rolls ET, Gaffan D. Selective perceptual impairments after perirhinal cortex ablation. *J Neurosci* 2001; 21: 9824–36.
- Bussey TJ, Saksida LM. The organization of visual object representations: a connectionist model of effects of lesions in perirhinal cortex. *Eur J Neurosci* 2002; 15: 355–64.
- Bussey TJ, Saksida LM, Murray EA. Perirhinal cortex resolves feature ambiguity in complex visual discriminations. *Eur J Neurosci* 2002; 15: 365–74.
- Bussey TJ, Saksida LM, Murray EA. Impairments in visual discrimination after perirhinal cortex lesions: testing 'declarative' vs. 'perceptual-mnemonic' views of perirhinal cortex function. *Eur J Neurosci* 2003; 17: 649–60.
- Bussey TJ, Saksida LM, Murray EA. The perceptual-mnemonic/feature conjunction model of perirhinal cortex function. *Q J Exp Psychol B* 2005; 58: 269–82.
- Canto CB, Wouterlood FG, Witter MP. What does anatomical organization of entorhinal cortex tell us? *Neural Plast* 2008; 2008: 1–18.
- Cowell RA, Bussey TJ, Saksida LM. Functional dissociations within the ventral object processing pathway: cognitive modules or a hierarchical continuum? *J Cogn Neurosci* 2009; 22: 2460–79.
- Cowell RA, Bussey TJ, Saksida LM. Components of recognition memory: dissociable cognitive processes or just differences in representational complexity? *Hippocampus* 2010; 20: 1245–62.
- Cree GS, McRae K. Analyzing the factors underlying the structure and computation of the meaning of chipmunk, cherry, chisel, cheese, and cello (and many other such concrete nouns). *J Exp Psychol Gen* 2003; 132: 163–201.
- Dale AM, Fischl B, Sereno MI. Cortical surface-based analysis. I. Segmentation and surface reconstruction. *Neuroimage* 1999; 9: 179–94.
- Davies RR, Graham KS, Xuereb JH, Williams GB, Hodges JR. The human perirhinal cortex and semantic memory. *Eur J Neurosci* 2004; 20: 2441–6.
- Desikan RS, Ségonne F, Fischl B, Quinn BT, Dickerson BC, Blacker D, et al. An automated labeling system for subdividing the human cerebral cortex on MRI scans into gyral based regions of interest. *Neuroimage* 2006; 31: 968–80.
- Dickerson BC, Bakkour A, Salat DH, Feczko E, Pacheco J, Greve DN, et al. The cortical signature of Alzheimer's disease: regionally specific cortical thinning relates to symptom severity in very mild to mild AD dementia and is detectable in asymptomatic amyloid-positive individuals. *Cereb Cortex* 2009a; 19: 497–510.
- Dickerson BC, Feczko E, Augustinack JC, Pacheco J, Morris JC, Fischl B, et al. Differential effects of aging and Alzheimer's disease on medial temporal lobe cortical thickness and surface area. *Neurobiol Aging* 2009b; 30: 432–40.
- Eacott MJ, Gaffan D, Murray EA. Preserved recognition memory for small sets, and impaired stimulus identification for large sets, following rhinal cortex ablations in monkeys. *Eur J Neurosci* 1994; 6: 1466–78.
- Eichenbaum H. Hippocampus: mapping or memory? *Curr Biol* 2000; 10: R785–7.
- Feczko E, Augustinack JC, Fischl B, Dickerson BC. An MRI-based method for measuring volume, thickness and surface area of entorhinal, perirhinal, and posterior parahippocampal cortex. *Neurobiol Aging* 2009; 30: 420–31.
- Fischl B, Sereno MI, Dale AM. Cortical surface-based analysis. II: Inflation, flattening, and a surface-based coordinate system. *Neuroimage* 1999; 9: 195–207.
- Fischl B, Salat DH, Busa E, Albert M, Dieterich M, Haselgrove C, et al. Whole brain segmentation: automated labeling of neuroanatomical structures in the human brain. *Neuron* 2002; 33: 341–55.
- Folstein MF, Folstein SE, McHugh PR. Mini-mental state: a practical method for grading the cognitive state of patients for the clinician. *J Psychiatr Res* 1975; 12: 189–98.
- Forster K, Forster J. DMDX: a Windows display program with millisecond accuracy. *Behav Res Methods* 2003; 35: 116–24.
- Gainotti G. What the locus of brain lesion tells us about the nature of the cognitive defect underlying category-specific disorders: a review. *Cortex* 2000; 36: 539–59.
- Garrard P, Patterson K, Watson PC, Hodges JR. Category specific semantic loss in dementia of Alzheimer's type. Functional-anatomical correlations from cross-sectional analyses. *Brain* 1998; 121: 633–46.
- Goncharova II, Dickerson BC, Stoub TR, deToledo-Morrell L. MRI of human entorhinal cortex: a reliable protocol for volumetric measurement. *Neurobiol Aging* 2001; 22: 737–45.
- Gonnerman LM, Andersen ES, Devlin JT, Kempler D, Seidenberg MS. Double dissociation of semantic categories in Alzheimer's disease. *Brain Lang* 1997; 57: 254–79.
- Hirni D, Monsch AU, Gomez-Mancilla B, Taylor KI. Relative association of perirhinal and entorhinal cortex integrity with semantic and episodic memory performance: implications for early detection of Alzheimer's disease. 288.01/TT13 Neuroscience Meeting Planner. Washington, DC: Society for Neuroscience; 2011.
- Hodges JR, Patterson K. Semantic dementia: a unique clinicopathological syndrome. *Lancet Neurology* 2007; 6: 1004–14.
- Humphreys GW, Forde EM. Hierarchies, similarity, and interactivity in object recognition: 'category-specific' neuropsychological deficits. *Behav Brain Sci* 2001; 24: 453–76.
- Insausti R, Amaral DG, Cowan WM. The entorhinal cortex of the monkey: II. Cortical afferents. *J Comp Neurol* 1987; 264: 356–95.
- Insausti R, Juottonen K, Soininen H, Insausti AM, Partanen K, Vainio P, et al. MR volumetric analysis of the human entorhinal, perirhinal, and temporopolar cortices. *Am J Neuroradiol* 1998; 19: 659–71.
- Kanwisher N, McDermott J, Chun MM. The fusiform face area: a module in human extrastriate cortex specialized for face perception. *J Neurosci* 1997; 17: 4302–11.
- Kivisaari S, Probst A, Taylor KI. The perirhinal, entorhinal and parahippocampal cortices and hippocampus: an overview of functional anatomy and protocol for their segmentation in MR images. In: Ulmer S, Jansen O, editors. *fMRI—Basics and Clinical applications*. Berlin Heidelberg, Germany: Springer; in press.
- Knopman DS, Parisi JE, Salviati A, Floriach-Robert M, Boeve BF, Ivnik RJ, et al. Neuropathology of cognitively normal elderly. *J Neuropathol Exp Neurol* 2003; 62: 1087–95.
- Lavenex P, Amaral DG. Hippocampal-neocortical interaction: a hierarchy of associativity. *Hippocampus* 2000; 10: 420–30.
- Laws KR, Adlington RL, Gale TM, Moreno-Martínez FJ, Sartori G. A meta-analytic review of category naming in Alzheimer's disease. *Neuropsychologia* 2007; 45: 2674–82.
- Lee AC, Rudebeck SR. Human medial temporal lobe damage can disrupt the perception of single objects. *J Neurosci* 2010; 30: 6588–94.
- Lee AC, Scahill VL, Graham KS. Activating the medial temporal lobe during oddity judgment for faces and scenes. *Cereb Cortex* 2008; 18: 683–96.
- Lee AC, Levi N, Davies RR, Hodges JR, Graham KS. Differing profiles of face and scene discrimination deficits in semantic dementia and Alzheimer's disease. *Neuropsychologia* 2007; 45: 2135–46.
- Lee AC, Buckley MJ, Gaffan D, Emery T, Hodges JR, Graham KS. Differentiating the roles of the hippocampus and perirhinal cortex in processes beyond long-term declarative memory: a double dissociation in dementia. *J Neurosci* 2006; 26: 5198–5203.

- Lee AC, Buckley MJ, Pegman SJ, Spiers H, Scahill VL, Gaffan D, et al. Specialization in the medial temporal lobe for processing of objects and scenes. *Hippocampus* 2005a; 15: 782–97.
- Lee AC, Bussey TJ, Murray EA, Saksida LM, Epstein RA, Kapur N, et al. Perceptual deficits in amnesia: challenging the medial temporal lobe 'mnemonic' view. *Neuropsychologia* 2005b; 43: 1–11.
- Lerch JP, Pruessner JC, Zijdenbos A, Hampel H, Teipel SJ, Evans AC. Focal decline of cortical thickness in Alzheimer's disease identified by computational neuroanatomy. *Cereb Cortex* 2005; 15: 995–1001.
- Levy DA, Bayley PJ, Squire LR. The anatomy of semantic knowledge: medial vs. lateral temporal lobe. *Proc Natl Acad Sci USA* 2004; 101: 6710–15.
- Levy DA, Shrager Y, Squire LR. Intact visual discrimination of complex and feature-ambiguous stimuli in the absence of perirhinal cortex. *Learn Mem* 2005; 12: 61–6.
- Manns JR, Hopkins RO, Squire LR. Semantic memory and the human hippocampus. *Neuron* 2003; 38: 127–33.
- McKhann G, Drachman D, Folstein M, Katzman R, Price D, Stadlan EM. Clinical diagnosis of Alzheimer's disease: report of the NINCDS-ADRDA Work Group under the auspices of Department of Health and Human Services Task Force on Alzheimer's Disease. *Neurology* 1984; 34: 939–44.
- McRae K. Semantic memory: some insights from feature-based connectionist attractor networks. In: Ross BH, editor. *Psychology of learning and motivation*. San Diego, CA: Academic Press; 2004. p. 41–86.
- McRae K, Cree GS, Seidenberg MS, McNorgan C. Semantic feature production norms for a large set of living and nonliving things. *Behav Res Methods C* 2005; 37: 547–59.
- Mishkin M, Ungerleider LG, Macko KA. Object vision and spatial vision: two cortical pathways. *Trends Neurosci* 1983; 6: 414–17.
- Mishkin M, Suzuki WA, Gadian DG, Vargha-Khadem F. Hierarchical organization of cognitive memory. *Philos Trans R Soc Lond B Biol Sci* 1997; 352: 1461–7.
- Monsch AU, Foldi NS, Ermini-Fünfschilling DE, Berres M, Taylor KI, Seifritz E, et al. Improving the diagnostic accuracy of the Mini-Mental State Examination. *Acta Neurol Scand* 1995; 92: 145–50.
- Monsch AU, Thalmann B, Schneitter M, Bernasconi F, Aebi C, Camachova-Davet Z, et al. The Basel study on the elderly's search for preclinical cognitive markers of Alzheimer's disease. *Neurobiol Aging* 2000; 21 (Suppl 1): 31.
- Moreno-Martínez FJ, Laws KR. No category specificity in Alzheimer's disease: a normal aging effect. *Neuropsychologia* 2008; 22: 485–90.
- Moss HE, Tyler LK. A progressive category-specific semantic deficit for non-living things. *Neuropsychologia* 2000; 38: 60–82.
- Moss HE, Tyler LK, Devlin JT. The emergence of category-specific deficits in a distributed semantic system. In: Forde EM, Humphreys GW, editors. *Category-specificity in mind and brain*. Sussex, UK: Psychology Press; 2002. p. 115–48.
- Moss HE, Tyler LK, Taylor KI. Conceptual structure. In: Gaskell G, editor. *Oxford handbook of psycholinguistics*. Oxford: Oxford University Press; 2007. p. 217–34.
- Moss HE, Tyler LK, Durrant-Peatfield M, Bunn EM. 'Two eyes of a see-through': impaired and intact semantic knowledge in a case of selective deficit for living things. *Neurocase* 1998; 4: 291–310.
- Moss HE, Rodd JM, Stamatakis EA, Bright P, Tyler LK. Anteromedial temporal cortex supports fine-grained differentiation among objects. *Cereb Cortex* 2005; 15: 616–27.
- Mummery CJ, Patterson K, Price CJ, Ashburner J, Frackowiak RSJ, Hodges JR. A voxel-based morphometry study of semantic dementia: Relationship between temporal lobe atrophy and semantic memory. *Ann Neurol* 2000; 47: 36–45.
- Murray EA, Bussey TJ. Perceptual-mnemonic functions of the perirhinal cortex. *Trends Cogn Sci* 1999; 3: 142–51.
- Murray EA, Richmond BJ. Role of perirhinal cortex in object perception, memory, and associations. *Curr Opin Neurobiol* 2001; 11: 188–93.
- Murray EA, Malkova L, Gouler S. Crossmodal associations, intramodal associations, and object identification in macaque monkeys. In: Milner AD, editor. *Comparative neuropsychology*. Oxford: Oxford University Press; 1998. p. 51–69.
- Nelson CA. The development and neural bases of face recognition. *Inf Child Dev* 2001; 10: 3–18.
- O'Neil EB, Cate AD, Köhler S. Perirhinal cortex contributes to accuracy in recognition memory and perceptual discriminations. *J Neurosci* 2009; 29: 8329–34.
- Pascalis O, Kelly DJ. The origins of face processing in humans: phylogeny and ontogeny. *Perspect Psychol Sci* 2009; 4: 200–9.
- Petersen RC. Mild cognitive impairment as a diagnostic entity. *J Int Med* 2004; 256: 183–94.
- Pexman P, Holyk G, Monfils MH. Number-of-features effects and semantic processing. *Mem Cognition* 2003; 31: 842–55.
- Pexman P, Lupker S, Hino Y. The impact of feedback semantics in visual word recognition: number-of-features effects in lexical decision and naming tasks. *Psychon Bull Rev* 2002; 9: 542–9.
- Pietrini V, Nertempi P, Vaglia A, Revello MG, Pinna V, Ferro-Milone F. Recovery from herpes simplex encephalitis: selective impairment of specific semantic categories with neuroradiological correlation. *J Neurol Neurosurg Psychiatry* 1988; 51: 1284–93.
- Plaut DC, Shallice T. Deep dyslexia: a case study of connectionist neuropsychology. *Cogn Neuropsychol* 1993; 10: 377–500.
- Polvikoski T, Sulkava R, Myllykangas L, Notkola IL, Niinistö L, Verkkoniemi A, et al. Prevalence of Alzheimer's disease in very elderly people. *Neurology* 2001; 56: 1690–6.
- Randall B, Moss HE, Rodd JM, Greer M, Tyler LK. Distinctiveness and correlation in conceptual structure: behavioral and computational studies. *J Exp Psychol Learn Mem Cogn* 2004; 30: 393–406.
- Riley KP, Snowden DA, Markesbery WR. Alzheimer's neurofibrillary pathology and the spectrum of cognitive function: findings from the Nun Study. *Ann Neurol* 2002; 51: 567–77.
- Saksida LM, Bussey TJ. The representational-hierarchical view of amnesia: translation from animal to human. *Neuropsychologia* 2010; 48: 2370–84.
- Shrager Y, Gold JJ, Hopkins RO, Squire LR. Intact visual perception in memory-impaired patients with medial temporal lobe lesions. *J Neurosci* 2006; 26: 2235–40.
- Squire LR, Wixted JT. The cognitive neuroscience of human memory since H.M. *Annu Rev Neurosci* 2011; 34: 259–88.
- Squire LR, Stark CEL, Clark RE. The medial temporal lobe. *Annu Rev Neurosci* 2004; 27: 279–306.
- Suzuki WA. Perception and the medial temporal lobe: evaluating the current evidence. *Neuron* 2009; 61: 657–66.
- Suzuki WA, Amaral DG. Perirhinal and parahippocampal cortices of the macaque monkey: cortical afferents. *J Comp Neurol* 1994a; 350: 497–533.
- Suzuki WA, Amaral DG. Topographic organization of the reciprocal connections between the monkey entorhinal cortex and the perirhinal and parahippocampal cortices. *J Neurosci* 1994b; 14: 1856–77.
- Taylor KI, Probst A. Anatomic localization of the transentorhinal region of the perirhinal cortex. *Neurobiol Aging* 2008; 29: 1591–6.
- Taylor KI, Devereux BJ, Tyler LK. Conceptual structure: towards an integrated neuro-cognitive account. *Lang Cognitive Proc* 2011; 26: 1368–401.
- Taylor KI, Moss HE, Tyler LK. The conceptual structure account: a cognitive model of semantic memory and its neural instantiation. In: Hart J, Kraut MA, editors. *Neural basis of semantic memory*. Cambridge: Cambridge University Press; 2007. p. 265–301.
- Taylor KI, Moss HE, Stamatakis EA, Tyler LK. Binding crossmodal object features in perirhinal cortex. *Proc Natl Acad Sci USA* 2006; 103: 8239–44.
- Taylor KI, Devereux BJ, Acres K, Randall B, Tyler LK. Contrasting effects of feature-based statistics on the categorization and identification of visual objects. *Cognition* 2012; 122: 363–74.
- Taylor KI, Stamatakis EA, Tyler LK. Crossmodal integration of object features: Voxel-based correlations in brain-damaged patients. *Brain* 2009; 132: 671–83.

- Tyler LK, Moss HE, Durrant-Peatfield MR, Levy JP. Conceptual structure and the structure of concepts: a distributed account of category-specific deficits. *Brain Lang* 2000; 75: 195–231.
- Tyler LK, Moss HE. Towards a distributed account of conceptual knowledge. *Trends Cogn Sci* 2001; 5: 244–52.
- Tyler LK, Stamatakis EA, Bright P, Acres K, Abdallah S, Rodd JM, et al. Processing objects at different levels of specificity. *J Cogn Neurosci* 2004; 16: 351–62.
- Ungerleider LG, Mishkin M. Two cortical visual systems. In: Ingle DJ, Goodale M, Mansfield RJ, editors. *Analysis of visual behaviour*. Cambridge, MA: MIT Press; 1982. p. 549–86.
- Vinson D, Vigliocco G. Semantic feature production norms for a large set of objects and events. *Behav Res Methods* 2008; 40: 183–90.
- Warrington EK, Shallice T. Category specific semantic impairments. *Brain* 1984; 107 (Pt 3): 829–54.
- Winblad B, Palmer K, Kivipelto M, Jelic V, Fratiglioni L, Wahlund LO, et al. Mild cognitive impairment—beyond controversies, towards a consensus: report of the International Working Group on Mild Cognitive Impairment. *J Int Med* 2004; 256: 240–6.
- Winters BD, Saksida LM, Bussey TJ. Object recognition memory: neurobiological mechanisms of encoding, consolidation and retrieval. *Neurosci Biobehav Rev* 2008; 32: 1055–70.
- Witter MP, Amaral DG. Entorhinal cortex of the monkey: V. Projections to the dentate gyrus, hippocampus, and subicular complex. *J Comp Neurol* 1991; 307: 437–59.
- Wixted JT, Squire LR. The medial temporal lobe and the attributes of memory. *Trends Cogn Sci* 2011; 15: 210–17.