



Case Report

Terminal extensor tendon reconstruction as a reliable options for chronic mallet finger with swan neck deformity of index finger: A case report

Gede Sandjaya^b, Ido Prabowo^a, Ichsan Dana Patih^{a,*}^a Department of Orthopaedics and Traumatology, Cipto Mangunkusumo General Hospital – Faculty of Medicine of Indonesia University, Jakarta, Indonesia^b Soedarso Hospital Pontianak, Network Hospital of Department Orthopaedics and Traumatology, Cipto Mangunkusumo General Hospital, Indonesia

ARTICLE INFO

Keywords:

Chronic mallet finger
Mallet deformity
Swan-neck deformity
Terminal tendon reconstruction
Case report

ABSTRACT

Introduction: and importance: Chronic mallet finger resulted in mallet deformity or swan neck deformity are caused by imbalance of flexor and extensor mechanism. We tried to offer a reliable option of treatment by terminal tendon reconstruction using needle passer to exchange the use of K-wire which resulted in great result within 3 months of follow up.

Case presentation: 36 years old male with previous history of several trauma on his right arm and hand about three months ago; consists of distal phalangeal fracture of right index finger, right fifth metacarpal fracture, proximal phalanx fracture of right small finger, and right shaft radius fracture. After 3 months since initial injury, we focused on the right index finger which suffered in a swan neck deformity. The patient was unable to reach maximum flexion of his right index finger. We performed terminal extensor tendon reconstruction with great result after three months of follow up.

Clinical discussion: Chronic mallet finger has many different techniques of surgical intervention, such as Fowler's tenotomy, tenodesis, spiral oblique retinacular ligament (ORL) reconstruction, and arthrodesis of distal interphalangeal (DIP) joint. The surgery was indicated after failure of 4 weeks finger splinting to correct the swan neck deformity. The aim of surgery was to improve finger function, restore normal active-passive flexion of proximal (PIP) and distal interphalangeal (DIP) joint by rebalancing the extensor mechanism of finger, relieve pain, and improve cosmetic appearance.

Conclusion: Terminal extensor tendon reconstruction is a simple, reproducible and reliable option of surgical treatment in chronic mallet finger case. At minimum follow up of 3-months after surgery has showed a satisfactory result.

1. Introduction

Acute mallet finger described as hyperextension deformity at the PIP joint and flexion deformity at the DIP joint [1]. It could manifested to chronic mallet finger that resulted in mallet or swan neck deformity if not adequately treated either by conservative treatment or surgery. Acute mallet finger is classified into two types; soft tissue and bony mallet finger. All of acute reducible cases were treated by splint application, with consequent of failing of conservative treatment. The splinting against the surgery were described in literatures with wide range of result, from the failure to satisfactory cases. The open acute mallet or chronic mallet finger were treated by surgical intervention in acute condition.

Chronic mallet finger are determined by the failure to reach

satisfactory result more than 4 weeks after subsequent conservative treatment of finger splinting [2]. The conservative treatment was a finger splinting in full extension of DIP joint within 4 weeks of immobilization. The splinting of both PIP joint and DIP joint was unnecessary, while the mallet finger only requires the immobilization of DIP joint to promote healing of terminal extensor tendon. The surgical correction of acute mallet finger is described by all of the procedures of both soft tissue or bony mallet finger to treat the acute mallet finger in less than 4 weeks after initial injury. There were so many surgical techniques which has been developed to treat soft tissue mallet finger; Fowler's tenotomy [3–6], tenodesis [7,8], open fixation by suture anchor, palmaris longus tendon graft [9,10], and hemilateral band technique for the defect of extensor tendon [11]. For the bony mallet finger, there were several techniques: such as dorsal extension block pinning [12], and

* Corresponding author.

E-mail address: ichsandpatih@gmail.com (I.D. Patih).<https://doi.org/10.1016/j.amsu.2022.103924>

Received 22 April 2022; Received in revised form 30 May 2022; Accepted 2 June 2022

Available online 6 June 2022

2049-0801/© 2022 The Authors. Published by Elsevier Ltd on behalf of IJS Publishing Group Ltd. This is an open access article under the CC BY-NC-ND license (<http://creativecommons.org/licenses/by-nc-nd/4.0/>).

K-wire fixation [2]. Many studies had reported management of soft tissue in mallet finger either splinting or surgery, has the same effectiveness same goal: to be reached satisfactory result. The fact that arthrodesis of DIP joint in 10° – 20° of flexion with headless screw is a feasible option for the patients suffering from pain and dysfunction after chronic mallet finger with only 10% cases of non-union rate [13]. However, despite many different techniques used, there are many complications that ensue. Therefore, this study aims to provide a simpler yet favorable technique for treatment of chronic mallet finger. This case report has been reported in line with the SCARE criteria [14].

2. Presentation of case

We admitted 36-years-old male with previous history of multiple fracture on his right hand; consist of distal phalangeal fracture of right index finger, fifth metacarpal fracture, proximal phalangeal fracture of right small finger, and shaft radius fracture. The patient was initially treated in another institutional board. Three months after the initial injury, the patient came to our medical centre, which the history and physical examination was taken. The clinical assessment of range of motion of right index finger presented the swan neck deformity while finger extension (Fig. 1). The anterior-posterior and oblique radiograph of right hand was taken and showed the hyperextension deformity of PIP joint and flexion deformity of DIP Joint (Fig. 2).

The patient agreed to participate on this report and for publication of the images by the informed consent.

2.1. Surgical technique

We decided to perform terminal tendon reconstruction using non-absorbable suture that passed through the base of distal phalanx, passing from dorsal to volar side of base distal phalanx. Surgery was performed by our senior orthopaedic surgeon. The approach of dorsoradial aspect of finger described as “J” incision, starting from 5 mm distally to dorsal DIP crease to proximally dorsal PIP crease. Then we identified the terminal extensor tendon and separate the most distal tendon stump from the distal phalanx. We used the monofilament non-absorbable suture with size of 4.0 for the terminal extensor tendon, then we use 22G needle that stucked to the base of distal phalanx from volar to dorsal. The needle act like suture passer, which passing the suture through the needle. Then we made second suture passing through different hole in

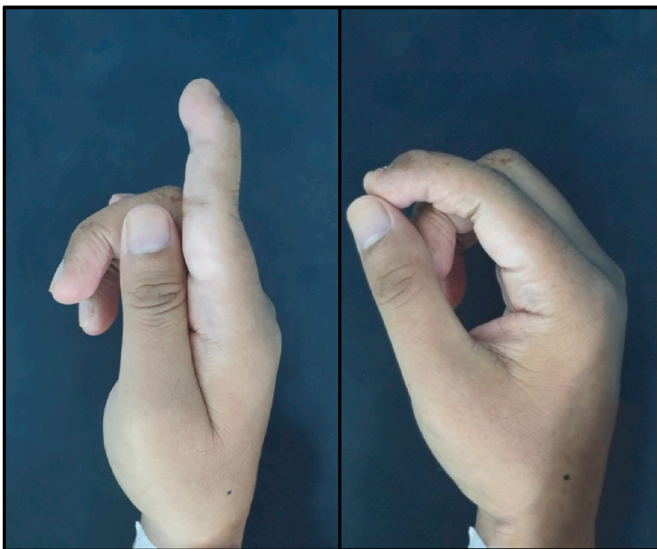


Fig. 1. The male 36 years old presented with unable to full active flexion of right index finger and swan neck deformity while in active extension of index finger.

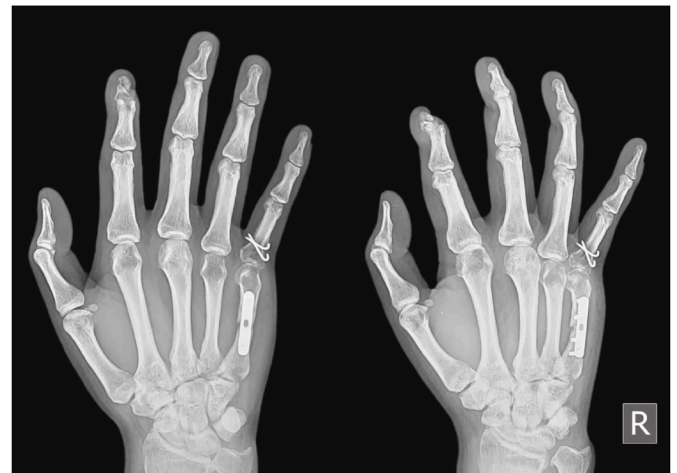

Fig. 2. The anterior-posterior and oblique radiograph of right hand. See the union of distal phalanx has been reached within 3 months and the finger now in swan neck deformity.

the same manner, and passed the suture from dorsal side to volar side of the base distal phalanx. We finish the process with secure knot that buried into the skin at volar side of hand (Fig. 3). We immobilized the finger with finger splinting for 4 weeks in full extension (Fig. 4). We made a follow up for 3 months after the surgery. The swan neck deformity was diminished at 14 days prior to surgery, then the finger splint was maintained for 4 weeks (Fig. 5). The patient could perform the full active finger flexion and extension at the end of third month prior to surgery without any pain. The function such as pinching and grasping of his right index finger was restored to normal limit. He is able to daily activities like holding a small thing like glass, pen, and door knob. The patient were very satisfied with the result.

3. Discussion

The swan neck deformity can be caused by several pathologies, such as post-traumatic, congenital, neurological, or rheumatic [15]. The swan neck deformity is the pathologic manifestation of chronic mallet finger, which the terminal extensor tendon was not heal at the original insertion as expected. It will create an extension lag which the DIP joint couldn't reach maximum DIP joint extension. The acute traumatic mallet finger presented by the terminal extensor tendon presents anatomical disruption, like the basketball player who caught a ball with the tip of finger while the PIP and DIP joint is in active extension [16]. Zancolli has classified the post-traumatic mallet finger into three categories: extrinsic, intrinsic, and articular [17,18].

The treatment options for post traumatic swan neck deformities are often different. The goal of surgery is to restore the motion of PIP and DIP joint and rebalance the force across the involved finger. Indication of non-surgical treatment of swan neck deformities including whether the patient still able to full active flexion of PIP joint, even though with the difficulty in initiating flexion from the hyperextension posture [18]. The indication of surgery of swan neck deformity for post-traumatic case are listed below [2]:

- Associated fracture of base distal phalanx (bony mallet finger)
- Open acute mallet finger (soft tissue and bony mallet finger)
- Chronic mallet finger resulted from failure conservative treatment (after finger splinting for 4 weeks)
- Patients with poor compliance to continue splinting or certain professional job (surgeons, musicians) [19].

Beside the terminal extensor tendon disruption, the involvement of oblique retinacular ligament (ORL) is well described by Zancolli in

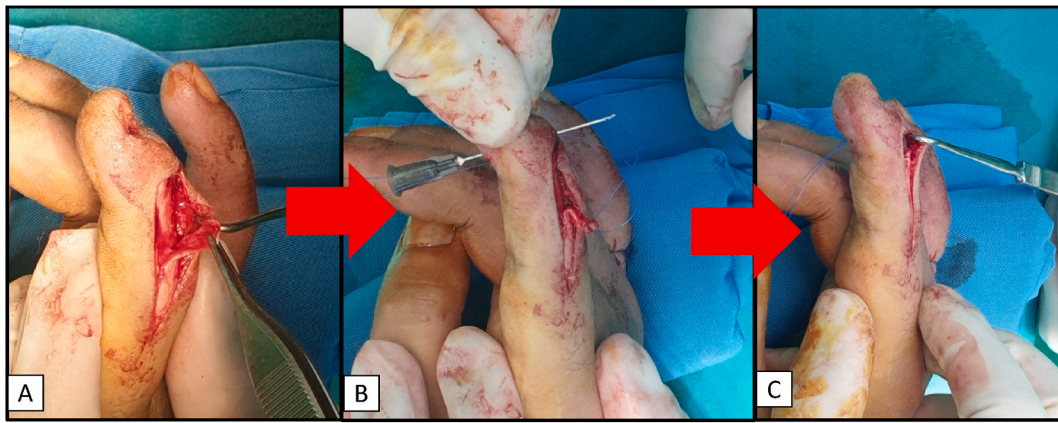


Fig. 3. Steps of terminal extensor tendon reconstruction: A. Approach to the dorsoradial side of index finger. B. The 22G needle act as suture passer, and suture are passed twice with two different holes. C. The suture pulled the terminal extensor tendon to its original insertion.

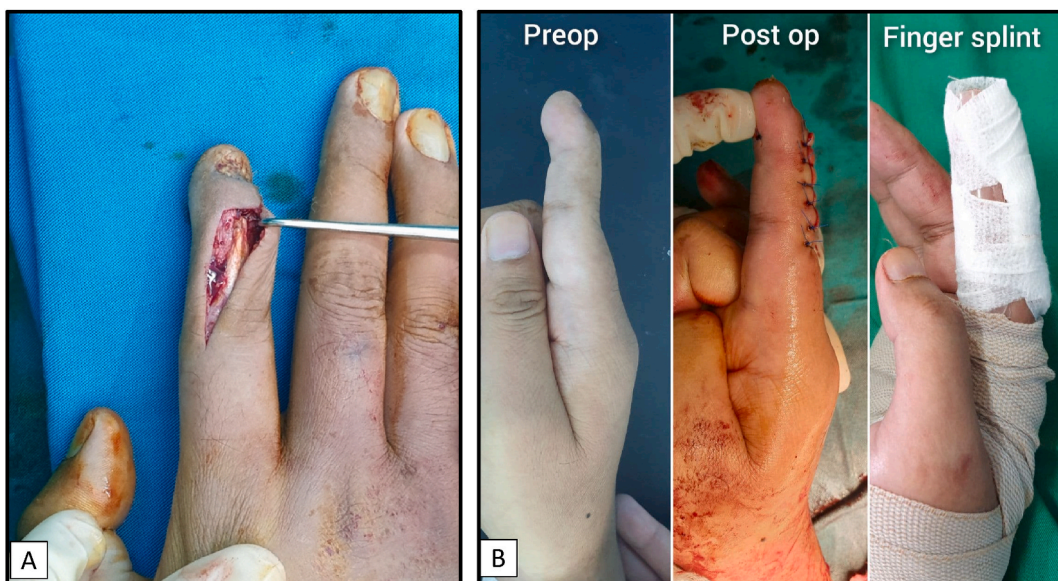


Fig. 4. A. Final construction. The suture was secured with secure knot at the volar side of base distal phalanx. B. The finger was splinted for 4 weeks in full extension.

cadaveric study [17]. The study of ORL reconstruction secondary to chronic mallet finger is based on the function of ORL; to stabilize the lateral band on dorsally to proximal phalanx during active or passive range of motion of PIP and DIP joint [20].

Chronic mallet finger has many options of surgical treatment according to the severity of case and patient's individual:

- Fowler's tenotomy: Central slip's tenotomy to rebalance the extensor mechanism of finger.
- Tenodesis: Direct repair with dorsal DIP skin imbrication (the skin and terminal extensor tendon was sutured together)
- Spiral ORL reconstruction: Recreating the extensor mechanism of DIP joint with spiral configuration of free tendon graft positioned volar to the PIP joint and dorsal to the DIP joint and fixed with suture anchor or a pull-out button. the palmaris tendon or plantaris tendon graft were commonly used [20,21].
- Arthrodesis of DIP joint: painful and dysfunction of involved finger is the main indication of arthrodesis of DIP joint. The used of K-wire or headless screw to fixed the DIP joint at 10°–20° of flexion are common.

In our case, we used the simple and reliable technique to fixed the

terminal extensor tendon into the dorsal base of distal phalanx using the non-absorbable suture with size 4.0 and the suture are passed with needle that pierced into the bone from dorsal to volar base of distal phalanx. With the restore of anatomical insertion of terminal extensor tendon, the native balance mechanism of flexor and extensor mechanism of finger was also restored. The distal stump of terminal extensor tendon has to be either intact or good condition, also there were no presence of tendon gap between the base of distal phalanx and terminal extensor tendon to made this technique well applied.

Another surgical treatments to correct the swan neck deformity is littler tenodesis, by detaching the proximal part of ulnar lateral band and relocating it under Cleland ligament and suture it back into the detached site [22]. A retrospective study conducted by Froelich et al. included 12 patients that underwent reconstruction of swan neck deformities after non-constrained PIP joint arthroplasties using partial flexor digitorum superficialis (FDS) hemitenodesis. This study showed 7 of 12 patients were in satisfactory result, however there was one failure secondary to implant loosening [23]. Another retrospective study conducted by Hamada et al. also included seven cases of rare swan neck deformity resulting from chronic radial collateral ligament (RCL) injury of PIP joint. Patients underwent reconstruction by ulnar slip of FDS that were transected and mobilized to RCL to prevent hyperextension of PIP joint

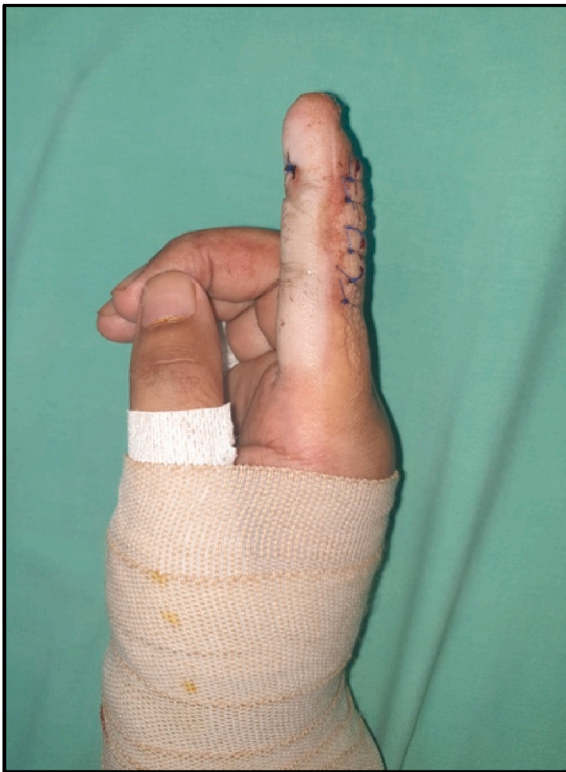

Fig. 5. Fourteen days after the surgery, the swan neck deformity was resolved and the finger splint was maintained for 2 weeks more with total of 4 weeks splinting.

with the resolved of swan neck deformities on all cases [24].

However, the complication of surgery is inevitable. The infections, hardware failure (K-wire, non-absorbable suture, headless screw failure), persistent extension lag that cause damage and carry the patients into additional surgeries [19]. The poor result also recorded in patients with delayed treatment of acute mallet more than 4 weeks prior to injury, more than 50° of extension lag, and for the patients that has short thick finger, age over 60 years, and non-compliant use of splinting [25].

4. Conclusion

Terminal extensor tendon reconstruction using non-absorbable suture that passed from dorsal to volar base of distal phalanx is a reliable option for chronic mallet finger with swan neck deformity in post-traumatic case. The understanding of normal balance and anatomical consideration of extensor mechanism of finger, the etiology of deformity, indication of non-surgical and surgical treatment, the patient's compliance and the available options of both non-surgical and surgical treatment modalities are mandatory to achieve the appropriate course of treatment and satisfactory functional result.

Ethical approval

This study has received ethical approval from our institution.

Sources of funding

None declared.

Authors contribution

Gede Sandjaya: Concept, design, surgeon, data analysis or interpretation, clinical studies, manuscript editing and review.

Ido Prabowo: Concept, design, surgeon, data analysis or interpretation, clinical studies, manuscript editing and review.

Ichsan Dana Patih: Concept, design, surgeon, data collection, manuscript editing and review.

Guarantor

None declared.

Consent

Written informed consent was obtained from the patient for publication of this case report and accompanying images.

Provenance and peer review

Not commissioned, externally peer-reviewed.

Declaration of competing interest

None declared.

References

- [1] P.M. Fox, J. Chang, Treating the proximal interphalangeal joint in swan neck and boutonniere deformities, *Hand Clin.* 34 (2) (2018) 167–176.
- [2] S.R. Alla, N.D. Deal, I.J. Dempsey, Current concepts: mallet finger, *Hand* 9 (2) (2014) 138–144.
- [3] W.H. Bowers, L.C. Hurst, Chronic mallet finger: the use of Fowler's central slip release, *J Hand Surg Am* 3 (4) (1978) 373–376.
- [4] R. Hiwatari, K. Kuniyoshi, M. Aoki, K. Hashimoto, T. Suzuki, K. Takahashi, Fractional Fowler tenotomy for chronic mallet finger: a cadaveric biomechanical study, *J Hand Surg Am* 37 (11) (2012) 2263–2268.
- [5] M. Asghar, R.H. Helm, Central slip tenotomy for chronic mallet finger, *Surgery* 11 (5) (2013) 264–266.
- [6] J.D. Chao, V. Sarwahi, Y.S.S. Da Silva, M.P. Rosenwasser, R.J. Strauch, Central slip tenotomy for the treatment of chronic mallet finger: an anatomic study, *J Hand Surg Am* 29 (2) (2004) 216–219.
- [7] E.K. Shin, D.S. Bae, Tenodermodesis for chronic mallet finger deformities in children, *Tech. Hand Up. Extrem. Surg.* 11 (4) (2007) 262–265.
- [8] T. Kardestuncer, D.S. Bae, P.M. Waters, The results of tenodermodesis for severe chronic mallet finger deformity in children, *J. Pediatr. Orthop.* 28 (1) (2008) 81–85.
- [9] Y.P. Gu, S.M. Zhu, A new technique for repair of acute or chronic extensor tendon injuries in zone 1, *J. Bone Joint. Surg. Br.* 94 (5) (2012) 668–670.
- [10] M.J. Concannon, G.M. Bazell, C.L. Puckett, Immediate reconstruction of distal extensor tendon loss with a tendon graft, *Operat. Tech. Plast. Reconstr. Surg.* 7 (1) (2000) 16–19.
- [11] C. Savvidou, S. Thirkannad, Hemilateral band technique for reconstructing gap defects in the terminal slip of the extensor tendon, *Tech. Hand Up. Extrem. Surg.* 15 (3) (2011) 177–181.
- [12] F. Takase, K. Yamasaki, T. Kokubu, Y. Mifune, A. Inui, R. Kuroda, Treatment of chronic bony mallet fingers by dorsal extension block pinning with percutaneous curettage, *Case Rep. Orthop.* 2018 (2018).
- [13] M.J. Desai, J.P. Wanner, D.H. Lee, E.M. Gauger, Failed extensor tendon repairs: extensor tenolysis and reconstruction, *JAAOS-J. Am. Acad. Orthop. Surg.* 27 (15) (2019) 563–574.
- [14] R.A. Agha, T. Franchi, C. Sohrabi, G. Mathew, A. Kerwan, A. Thoma, et al., The SCARE 2020 guideline: updating consensus surgical CAse REport (SCARE) guidelines, *Int. J. Surg.* 84 (2020) 226–230.
- [15] C. Brulard, A. Sauvage, O. Mares, G. Wavreille, C. Fontaine, Treatment of rheumatoid swan neck deformity by tenodesis of proximal interphalangeal joint with a half flexor digitorum superficialis tendon. About 23 fingers at 61 months follow-up, *Chir. Main* 31 (3) (2012) 118–127.
- [16] G. Checucci, M. Biondi, M. Faccio, P. Zampetti, M. Galeano, M. Ceruso, Acute traumatic swan neck deformity: a case report of the oblique retinacular ligament lesion, *J. Hand Surg. (Asian-Pacific)* 22 (3) (2017) 359–362.
- [17] E.A. Zancolli, *Structural and Dynamic Bases of Hand Surgery*, second ed., JB Lippincott Co, Philadelphia, 1979.
- [18] K.E. McKeon, D.H. Lee, Posttraumatic boutonniere and swan neck deformities, *JAAOS-J. Am. Acad. Orthop. Surg.* 23 (10) (2015) 623–632.
- [19] G.A. Lamaris, M.K. Matthew, The diagnosis and management of mallet finger injuries, *Hand* 12 (3) (2017) 223–228.
- [20] K. Elzinga, K.C. Chung, Managing swan neck and boutonniere deformities, *Clin. Plast. Surg.* 46 (3) (2019) 329–337.
- [21] W.B. Kleinman, D.P. Petersen, Oblique retinacular ligament reconstruction for chronic mallet finger deformity, *J Hand Surg Am* 9 (3) (1984) 399–404.
- [22] N. Borisch, P. Haubmann, Littler tenodesis for correction of swan neck deformity in rheumatoid arthritis, *Operat. Orthop. Traumatol.* 23 (3) (2011) 232–240.

- [23] J.M. Froelich, M. Rizzo, Reconstruction of swan neck deformities after proximal interphalangeal joint arthroplasty, *Hand* 9 (1) (2014) 93–98.
- [24] Y. Hamada, H. Takai, R. Satoh, N. Hibino, Y. Ueda, Y. Minamikawa, Swan neck deformity due to chronic radial collateral ligament injury of the little finger proximal interphalangeal joint, *J. Hand Surg. (European)* 43 (5) (2018) 513–517.
- [25] V.M. Makhlof, N. Al Deek, Surgical treatment of chronic mallet finger, *Ann. Plast. Surg.* 66 (6) (2011) 670–672.