




Aline Soares Garcez <sup>a,\*</sup>,  
Vitória Regina Pedreira de Almeida Rego <sup>a</sup>,  
Thadeu Santos Silva <sup>b</sup>

<sup>a</sup> *Dermatology Service, Hospital Universitário Professor Edgard Santos, Universidade Federal da Bahia, Salvador, BA, Brazil*

<sup>b</sup> *Dermatology Service, Escola Bahiana de Medicina e Saúde Pública, Salvador, BA, Brazil*

\* Corresponding author.

E-mail: [line\\_garcez@hotmail.com](mailto:line_garcez@hotmail.com) (A.S. Garcez).

Received 5 November 2019; accepted 17 February 2020

<https://doi.org/10.1016/j.abd.2020.02.007>

0365-0596/ © 2020 Sociedade Brasileira de Dermatologia.

Published by Elsevier España, S.L.U. This is an open access article under the CC BY license (<http://creativecommons.org/licenses/by/4.0/>).

## Necrolytic migratory erythema associated with painful plantar keratoderma. A new diagnostic clue for this paraneoplastic syndrome?<sup>☆,☆☆</sup>



Dear Editor,

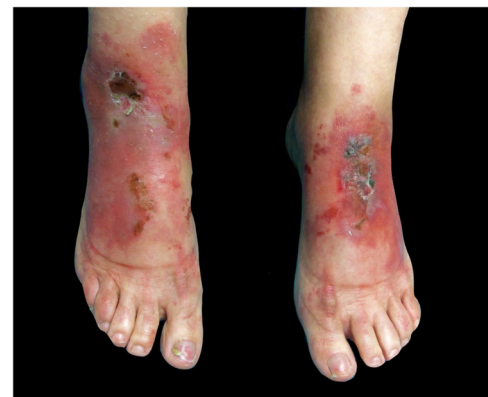The presence of recurrent skin lesion outbreaks in intertriginous areas and lower extremities, during years of evolution, may be a presenting form of necrolytic migratory erythema (NME), which is a paraneoplastic skin disease that is associated with malignant glucagonoma in 90% of cases.<sup>1</sup>

This report presents the case of a 59-year-old woman with a history of keratoconjunctivitis, asthenia, and constipation. She was referred to evaluate recurrent skin lesions with four years of evolution. She was affected by erythematous, scaly plaques and hyperpigmentation in the legs, gluteal area, groin area, thighs, and elbows, with no associated systemic symptoms (Fig. 1). She provided several skin biopsies, which had been diagnosed as toxicoderma and eczema, but the patient denied taking drugs. A new biopsy showed an epidermis with a marked pale central area due to the presence of apoptotic keratinocytes of vacuolated appearance below a layer of extensive hyperkeratosis and parakeratosis (Fig. 2). This gave a “tricolor flag” image, which is suggestive of vitamin deficiency. In addition, a deficit of zinc and fatty acids was observed, and, after starting vitamin and zinc supplements, the patient remained asymptomatic for eight months. Nevertheless, she subsequently presented more severe outbreaks with blisters, edema, and scaling predominantly on the dorsum of the feet, associated with a very painful plantar keratoderma (Fig. 3).

With the suspicion of NME and high levels of glucagon, an abdominal CT scan was made showing a 4 cm mass in the pancreas, and the presence of a malignant glucagonoma was confirmed by pathological anatomy. The skin lesions completely resolved after tumor resection. However, one year later she developed liver metastasis with no recurrence of skin lesions.

Although malignant glucagonoma may be accompanied by systemic symptoms such as diarrhea, weight loss, newly

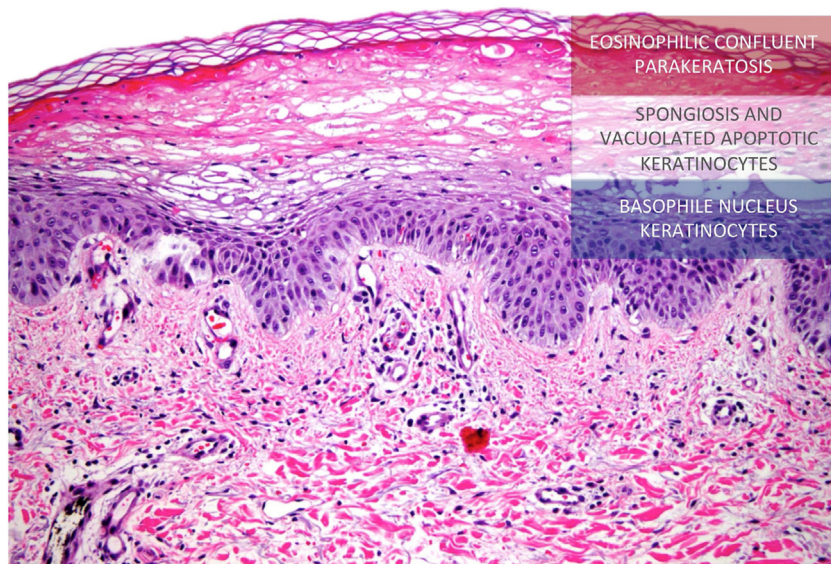
developed diabetes, normocytic anemia, zinc deficiency, or fatty acid or amino acid deficiency, *etc.*, NME may be the first and only glucagonoma symptom.<sup>2,3</sup> The pathogenesis of NME can be explained due to the fact that hyperglucagonemia stimulates hepatocyte gluconeogenesis and lipolysis leading to hypoaminoacidemia. Liver dysfunction results in decreased albumin, which is the main carrier of zinc and fatty acids, and thus contributes to fatty acid and zinc deficiency. Glucagon also causes vitamin B and nutrient deficiencies, such as zinc deficiency, which may contribute to increased levels of arachidonic acid, prostaglandins, and leukotrienes, and thus predisposing individuals to develop inflammatory skin lesions, such as NME, and the classic epidermal necrolysis seen in the histology.<sup>1</sup> The evolution of skin lesions in outbreaks, which are sometimes self-healing, the nonspecific histology in some cases, and the long evolution of the lesions are the reason for the diagnostic delay.<sup>3</sup> It should be noted that the “tricolor flag” histological image is associated not only with skin lesions due to nutritional deficits and acral necrolytic erythema, but also with the advanced cutaneous lesions of NME.<sup>4</sup> It is also important to highlight the presence of a painful plantar keratoderma, which was not found to be associated with this syndrome in the literature, and which was completely resolved with the removal of the neoplasm. Even though malignant glucagonoma is a slow-growing tumor, more than 50% of the cases at diagnosis already have metastatic involvement.<sup>5</sup> For this reason, it is crucial to highlight the importance of an early diagnosis of this clinical presentation, which can lead to preventing the appearance of metastases leading to a worse prognosis. In conclusion, this report describes patient with recurrent skin lesions,



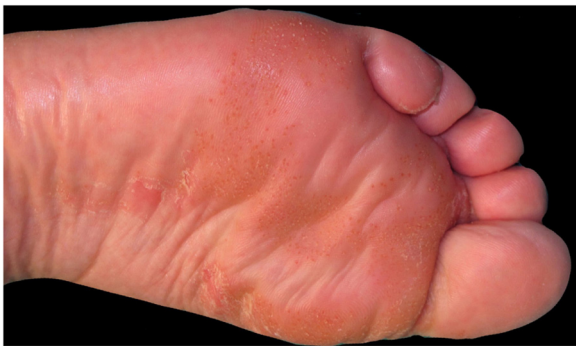**Figure 1** Erythematous, scaly, erosive, and crusty lesions on the dorsum of the feet.

<sup>☆</sup> How to cite this article: Gracia-Darder I, Ramos D, Boix-Vilanova J, Bauzá-Alonso AF. Necrolytic migratory erythema associated with painful plantar keratoderma. A new diagnostic clue for this paraneoplastic syndrome? *An Bras Dermatol.* 2020;95:666–8.

<sup>☆☆</sup> Study conducted at the Department of Dermatology, Son Espases University Hospital, Palma de Mallorca, Balears, Spain.



**Figure 2** Histology of the lesions. Atrophic epidermis can be seen with moderate spongiosis and a central area with marked pallor due to the presence of apoptotic keratinocytes of vacuolated appearance below a more superficial layer of extensive hyperkeratosis and parakeratosis, producing a "tricolor flag" appearance (Hematoxylin & eosin,  $\times 20$ ).



**Figure 3** Plantar hyperkeratotic patches with reddish dots.

where the histological findings were the key to establishing the diagnosis, as the only manifestation of a malignant glucagonoma.

### Financial support

None declared.

### Authors' contributions

Inés Gracia Darder: Approval of the final version of the manuscript; conception and planning of the study; drafting and editing of the manuscript; collection, analysis, and interpretation of data; participation in study design; intellectual participation in the propaedeutic and/or therapeutic conduct of the studied cases; critical review of the literature; critical review of the manuscript.

Daniel Ramos: Approval of the final version of the manuscript; conception and planning of the study; drafting and editing of the manuscript; collection, analysis, and interpretation of data; participation in study design; intel-

lectual participation in the propaedeutic and/or therapeutic conduct of the studied cases; critical review of the literature; critical review of the manuscript.

Julián Boix Vilanova: Approval of the final version of the manuscript; conception and planning of the study; drafting and editing of the manuscript; collection, analysis, and interpretation of data; participation in study design; intellectual participation in the propaedeutic and/or therapeutic conduct of the studied cases; critical review of the literature; critical review of the manuscript.

Ana Francisca Bauzá Alonso: Approval of the final version of the manuscript; conception and planning of the study; drafting and editing of the manuscript; collection, analysis, and interpretation of data; participation in study design; intellectual participation in the propaedeutic and/or therapeutic conduct of the studied cases; critical review of the literature; critical review of the manuscript.

### Conflicts of interest

None declared.



### Acknowledgments

The authors are very grateful to Dr. Saus of the Pathological Anatomy Department for his valuable help in the histology diagnosis.

### References

1. John AM, Schwartz RA. Glucagonoma syndrome: a review and update on treatment. *J Eur Acad Dermatol Venereol.* 2016;30:2016–22.
2. Liu JW, Qian YT, Ma DL. Necrolytic migratory erythema. *JAMA Dermatol.* 2019 [Epub ahead of print].

- Tolliver S, Graham J, Kaffenberger BH. A review of cutaneous manifestations within glucagonoma syndrome: necrolytic migratory erythema. *Int J Dermatol*. 2018;57:642–5.
- Toberer F, Hartschuh W, Wiedemeyer K. Glucagonoma-associated necrolytic migratory erythema: the broad spectrum of the clinical and histopathological findings and clues to the diagnosis. *Am J Dermatopathol*. 2019;41:e29–32.
- Tremblay C, Marcil I. Necrolytic migratory erythema: a forgotten paraneoplastic condition. *J Cutan Med Surg*. 2017;21:559–61.

Inés Gracia-Darder \*, Daniel Ramos , Julián Boix-Vilanova , Ana Francisca Bauzá-Alonso 

Department of Dermatology, Son Espases University Hospital, Palma de Mallorca, Baleares, Spain

\* Corresponding author.

E-mail: [ines.gracia@ssib.es](mailto:ines.gracia@ssib.es) (I. Gracia-Darder).

Received 19 November 2019; accepted 29 February 2020

<https://doi.org/10.1016/j.abd.2020.02.011>

0365-0596/ © 2020 Sociedade Brasileira de Dermatologia.

Published by Elsevier España, S.L.U. This is an open access article under the CC BY license (<http://creativecommons.org/licenses/by/4.0/>).

## Ecthyma gangrenosum and severe transitory neutropenia in an immunocompetent girl<sup>☆,☆☆</sup>



Dear Editor,

Ecthyma gangrenosum (EG) is a rare cutaneous lesion, principally caused by *Pseudomonas aeruginosa*, through either primary infection or hematogenous spread. Other pathogenic agents responsible have also been described, such as *Aeromonas hydrophila*, *Staphylococcus aureus*, and *Aspergillus* spp., among others.<sup>1,2</sup> It generally develops in patients with sepsis or immunosuppression, in a context of hematological malignancies or immunosuppressive therapy. It presents with erythematous/violaceous or hemorrhagic lesions that evolve into a central necrotic ulcer with an erythematous halo, preferentially situated on the buttocks and legs.<sup>1</sup> This report presents the case of a previously healthy baby girl with genital EG and the subsequent development of a severe transitory neutropenia.

A previously healthy 17-month-old girl presented with a hemorrhagic blister on the left side of her vulva. It had started seven days before, with perilesional erythema (Fig. 1) that progressively developed ulceration and edema. There was no fever or other systemic symptoms. She was treated with oral cefpodoxime and clindamycin. As there was no improvement after 72 hours, she was hospitalized and referred to dermatology. On physical examination, the patient was in good general condition with stable hemodynamics and no fever. She had a skin ulcer on the left labia majora with a maximum diameter of 1.7 cm and well-defined borders. There was fibrin at its base, much swelling, and perilesional induration, sensitive to the touch (Fig. 2). A hemogram was carried out which showed 5,840 leucocytes/mm<sup>3</sup>, an absolute neutrophil count (ANC) of 876 mm<sup>3</sup>, and C-reactive protein of 33 mg/dL. Polymerase chain reaction (PCR) tests of the lesion for herpes simplex viruses 1 and 2, cytomegalovirus, varicella-zoster virus, and the Epstein-Barr virus were all negative. Blood, fun-

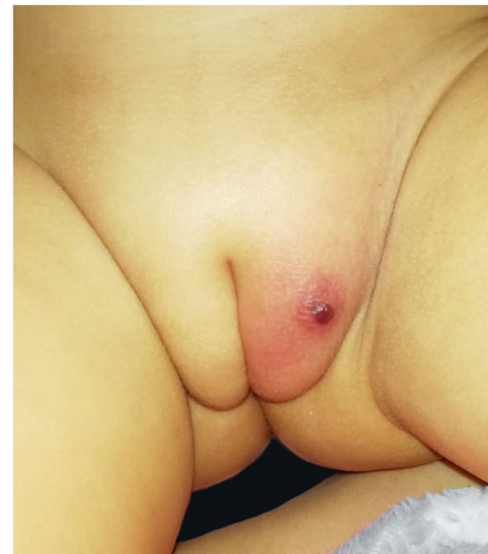

Figure 1 Hemorrhagic blister on vulva, two days of evolution.

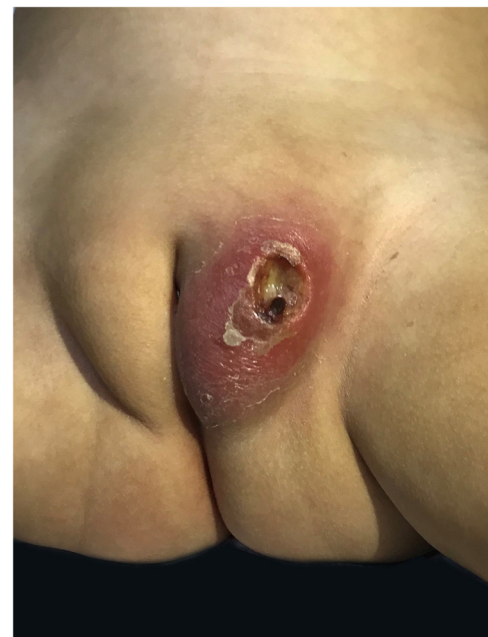

Figure 2 Skin ulcer in labia majora, seven days of evolution.

<sup>☆</sup> How to cite this article: Vargas-Mora P, García S, Aranibar L, Valenzuela F. Ecthyma gangrenosum and severe transitory neutropenia in an immunocompetent girl. *An Bras Dermatol*. 2020;95:668–9.

<sup>☆☆</sup> Study conducted at the Department of Dermatology, Faculty of Medicine, University of Chile. Santiago, Chile.