

Classic Peripheral Signs of Subacute Bacterial Endocarditis

Yooyoung Chong, M.D., Sung Joon Han, M.D., Youn Ju Rhee, M.D.,
Shin Kwang Kang, M.D., Ph.D., Jae Hyeon Yu, M.D., Ph.D., Myung Hoon Na, M.D., Ph.D.

Department of Thoracic and Cardiovascular Surgery, Chungnam National University School of Medicine

A 50-year-old female patient with visual disturbances was referred for further evaluation of a heart murmur. Fundoscopy revealed a Roth spot in both eyes. A physical examination showed peripheral signs of infective endocarditis, including Osler nodes, Janeway lesions, and splinter hemorrhages. Our preoperative diagnosis was subacute bacterial endocarditis with severe aortic regurgitation. The patient underwent aortic valve replacement and was treated with intravenous antibiotics for 6 weeks postoperatively. The patient made a remarkable recovery and was discharged without complications. We report this case of subacute endocarditis with all 4 classic peripheral signs in a patient who presented with visual disturbance.

Key words: 1. Endocarditis
2. Subacute bacterial

Case report

A 50-year-old female patient with visual disturbance was referred to Chungnam National University Hospital by an ophthalmologist for further evaluation of a cardiac murmur. The patient had experienced blurred vision and pain in both eyes for 5 days, and had a history of pain in the lower legs that had lasted for 3 months, coinciding with a persistent mild fever. A skin rash with tenderness was present on the palms and the soles of the feet and had lasted for 2 months. The patient had previously received 2 weeks of acupuncture treatments of the neck and back at an Oriental medical clinic in an attempt to reduce pain. In addition, the patient had been taking non-steroidal anti-inflammatory drugs for 2 months as prescribed by a local clinic, but the mild fever persisted and did not improve.

The patient had a chronically ill, anemic appearance, and presented with a mild fever (37.8°C), ta-

chypnea, and a blood pressure of 110/80 mmHg. An ophthalmic examination revealed reduced visual acuity in both eyes; fundoscopy showed bilateral Roth spots and optic disc edema with retinal hemorrhages (Fig. 1). A physical examination showed Osler nodules (Fig. 2), Janeway lesions (Fig. 3), and splinter hemorrhages (Fig. 4). Chest auscultation revealed a diastolic decrescendo murmur at the right and left upper sternal border. The neurologic examination was unremarkable.

The laboratory examination showed marked leukocytosis (21,000/mm³, 88% neutrophils, and 7% lymphocytes) and a C-reactive protein level of 13 mg/L. Urinalysis revealed microscopic hematuria and proteinuria. An electrocardiogram showed a normal sinus rhythm and a chest X-ray showed bilateral pleural effusions.

Brain magnetic resonance imaging revealed a subarachnoid hemorrhage in the frontal and right occipital lobes, as well as multifocal microhemorrhages in the bilateral cerebellum and the left occipital, left pa-

Received: September 1, 2015, Revised: October 5, 2015, Accepted: October 5, 2015, Published online: October 5, 2016

Corresponding author: Myung Hoon Na, Department of Thoracic and Cardiovascular Surgery, Chungnam National University Hospital, Chungnam National University School of Medicine, 282 Munhwa-ro, Jung-gu, Daejeon 35015, Korea (Tel) 82-42-280-7378 (Fax) 82-42-280-7373 (E-mail) thomasna@cnu.ac.kr

© The Korean Society for Thoracic and Cardiovascular Surgery. 2016. All right reserved.

© This is an open access article distributed under the terms of the Creative Commons Attribution Non-Commercial License (<http://creativecommons.org/licenses/by-nc/4.0>) which permits unrestricted non-commercial use, distribution, and reproduction in any medium, provided the original work is properly cited.

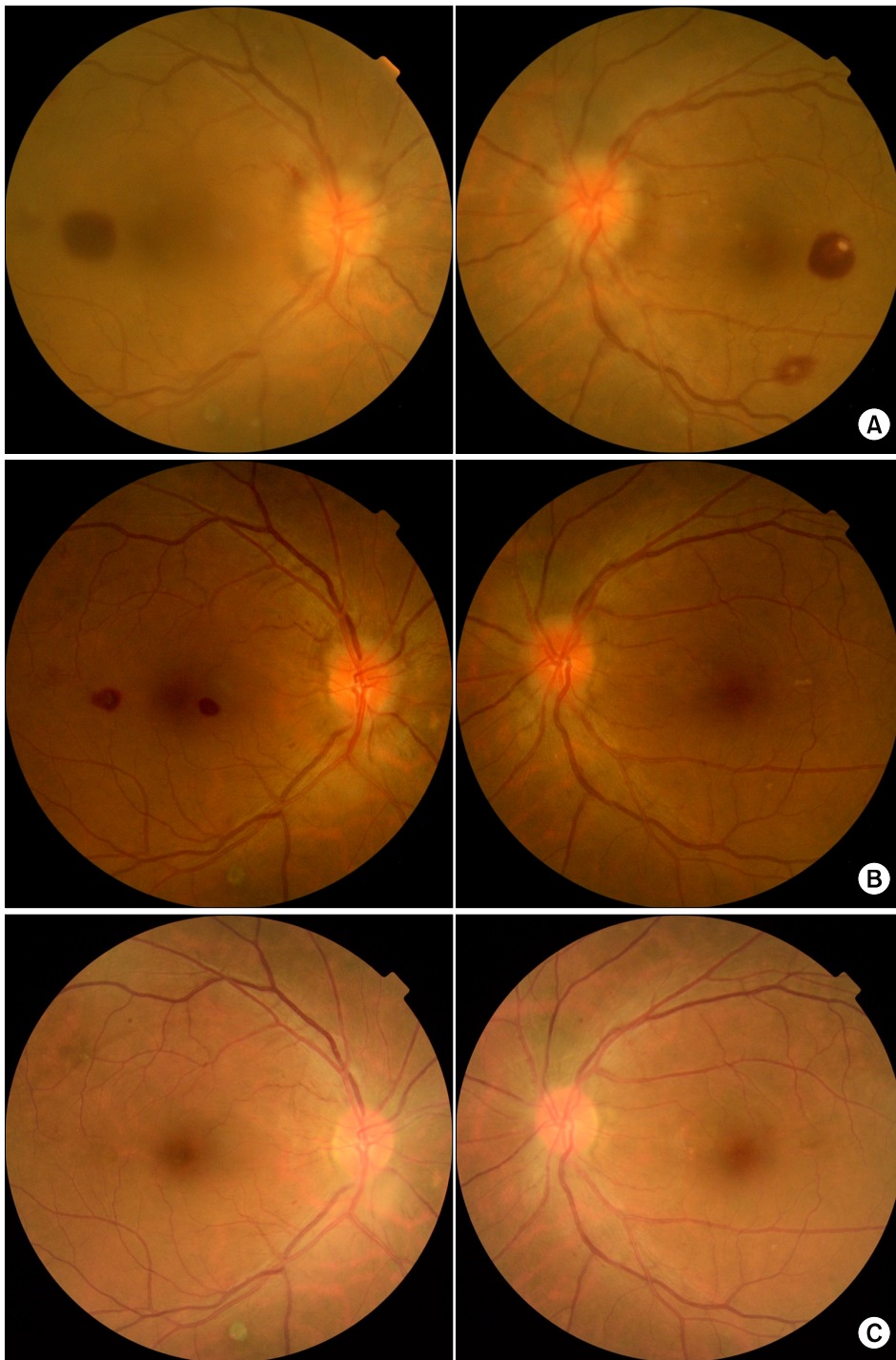


Fig. 1. Fundoscopic findings of Roth spots. (A) Preoperative findings. (B) 2 weeks postoperatively. (C) 6 weeks postoperatively.

rietal, and left frontal lobes. Transthoracic and transesophageal echocardiograms showed combined severe aortic regurgitation and 8×21-mm and 6×20-mm echogenic masses with high mobility attached to the left ventricular sides of the right and left coronary

cusps, respectively. Empirical intravenous antibiotics were started. A peripheral blood culture showed *Streptococcus parasanguis*.

On the fourth day in the hospital, the patient underwent aortic valve replacement. Cardiopulmonary

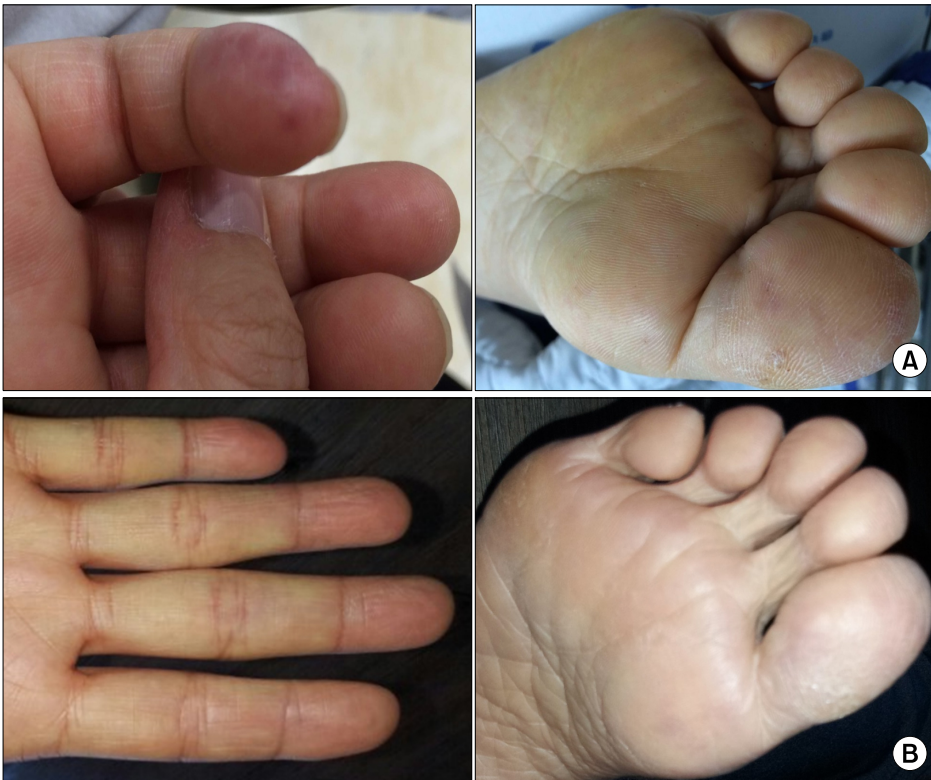

Fig. 2. Osler nodes. (A) Preoperative findings. (B) 6 weeks postoperatively.

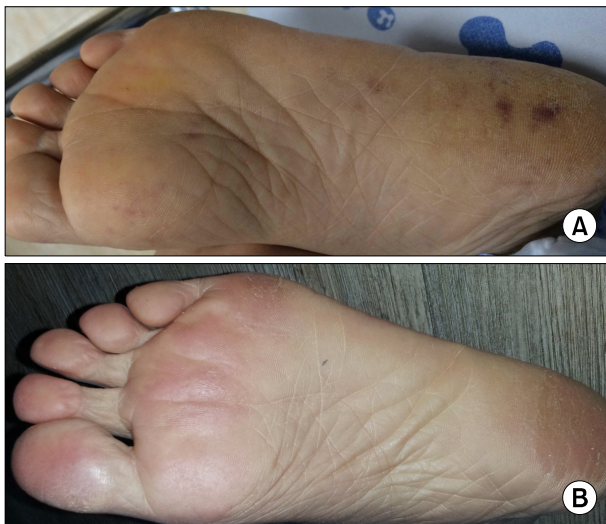

Fig. 3. Janeway lesions. (A) Preoperative findings. (B) 6 weeks postoperatively.

bypass was established with aortic and bicaval cannulation. After transverse aortotomy, we found huge vegetations on 3 aortic cusps and a small aortic wall abscess in the aortic wall above the noncoronary cusp. The aortic valve was severely damaged, so we

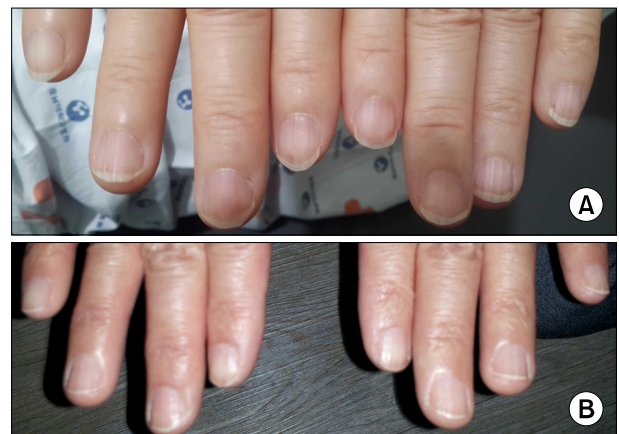

Fig. 4. Splinter hemorrhage. (A) Preoperative findings. (B) 6 weeks postoperatively.

performed aortic valve replacement with a mechanical prosthetic valve. The aortic wall abscess was debrided and reinforced with pledgeted sutures.

Postoperative care and follow-up examinations were performed, including a weekly blood culture, echocardiogram, fundoscopic exams, and 6 weeks of intravenous antibiotics. The pain in the patient's palms, soles, and lower limbs resolved on postoperative day

(POD) 4, and the skin lesions resolved after 2 weeks. The visual complications started to improve on POD 2 and had completely resolved on POD 7. A fundoscopic examination showed that the hemorrhages with Roth spots remained present for 4 weeks postoperatively, but were nearly absorbed by the 6th week postoperatively. The patient was discharged after 6 weeks of intravenous antibiotics and routine follow-up at our outpatient division. No complications were observed during the 2-month follow-up period.

Discussion

Infective endocarditis is characterized by inflammation of the endothelium of the heart; it most commonly affects heart valves. Numerous microorganisms are known to cause this condition. Symptoms are usually nonspecific and include fever, chills, anorexia, myalgia, and dyspnea [1]. The clinical signs of endocarditis are numerous and nonspecific; heart murmur is the most common sign. The peripheral signs can be useful in diagnosis but are less commonly used because of advancements in diagnostic modalities [1].

There are four peripheral signs of endocarditis: Roth spots, Osler nodes, Janeway lesions, and splinter hemorrhages. The Swiss pathologist Moritz Roth first described these eponymous spots in 1872 [2]. Roth spots appear as white-centered retinal hemorrhages on a fundoscopic examination. The white center of a Roth spot is thought to be a leucocyte accumulation or platelet-fibrin plug. Although Roth spots are a classic peripheral sign of endocarditis, they are also present in other conditions, including hematologic malignancies, connective tissue diseases, vasculitis, anemia, hypertension, diabetes mellitus, human immunodeficiency virus infections, and intracranial hemorrhages [2].

The prognosis of Roth spots in septic conditions is poor. However, previous reports have stated that early interventions with medical or surgical modalities achieved good results [3]. Our patient experienced relief from the visual disturbances in the first postoperative week.

The Canadian physician Sir William Osler first described Osler nodes in 1893 [3]. They are painful erythematous lesions of the hands and feet. The pathogenesis of Osler nodes is unclear, but is thought to involve the deposition of immune complexes. The no-

des are a classic sign of late-phase subacute bacterial endocarditis. However, Osler nodes are also found in other conditions, including bacteremia, septic endarteritis, typhoid fever, disseminated gonococcal infection, and systemic lupus erythematosus. The usual sites of Osler nodes are the pads of the fingers and toes, but occasionally they appear on the mucous membranes, limbs, and trunk. With adequate intravenous antibiotics, Osler nodes resolve without any sequelae within 3 days [4]. In this case, we found painful nodular lesions on the patient's palms and soles, which were relieved 4 days postoperatively.

Janeway lesions are non-tender, small, erythematous, or hemorrhagic macular lesions. Microabscesses of the dermis may develop into Janeway lesions. The lesions are similar to Osler nodes, but some notable differences are present. First, they are not tender; second, they are not of immunological origin; and lastly, they present on the palms and soles rather than on the pads of the fingers and toes [5]. We found Janeway lesions on the patient's palms and soles, and they resolved within 4 days after surgery.

Splinter hemorrhages are tiny blood clots that run vertically under the nails. They are a non-specific sign of endocarditis and are also seen in scleroderma, trichinosis, systemic lupus erythematosus, rheumatoid arthritis, psoriasis, antiphospholipid syndrome, hematological malignancy, and trauma [6].

Sandre and Shafran [7] reported the incidence of peripheral signs of endocarditis as follows: 3% for Roth spots, 6.7% for Osler nodes, 2.2% for Janeway lesions, and 39% for splinter hemorrhages, but no report has previously described a patient with all 4 peripheral signs. We report here a case of subacute infective endocarditis with all 4 classic peripheral signs.

Conflict of interest

No potential conflict of interest relevant to this article was reported.

References

1. Mylonakis E, Calderwood SB. *Infective endocarditis in adults*. N Engl J Med 2001;345:1318-30.
2. Fred HL. *Little black bags, ophthalmoscopy, and the Roth spot*. Tex Heart Inst J 2013;40:115-6.

3. Jackson TL, Eykyn SJ, Graham EM, Stanford MR. *Endogenous bacterial endophthalmitis: a 17-year prospective series and review of 267 reported cases.* Surv Ophthalmol 2003;48:403-23.
4. Von Gemmingen GR, Winkelmann RK. *Osler's node of sub-acute bacterial endocarditis: focal necrotizing vaculitis of the glomus body.* Arch Dermatol 1967;95:91-4.
5. Farrior JB, Silverman ME. *A consideration of the differences between a Janeway's lesion and an Osler's node in infectious endocarditis.* Chest 1976;70:239-43.
6. Robertson JC, Braune ML. *Splinter haemorrhages, pitting, and other findings in fingernails of healthy adults.* Br Med J 1974;4:279-81.
7. Sandre RM, Shafran SD. *Infective endocarditis: review of 135 cases over 9 years.* Clin Infect Dis 1996;22:276-86.