



Snake envenomation in three cats in South Korea

Jeong-Min Lee^{1,2} , Mi-Kyung Park¹, Gi-Ppeum Lee², Joong-Hyun Song¹ and Kun-Ho Song¹

Journal of Feline Medicine and Surgery Open Reports
1–5

© The Author(s) 2023

Article reuse guidelines:

sagepub.com/journals-permissions

DOI: 10.1177/20551169231173582

journals.sagepub.com/home/jfmsopenreports

This paper was handled and processed by the European Editorial Office (ISFM) for publication in *JFMS Open Reports*



Abstract

Case series summary Three cats in South Korea were diagnosed with snake envenomation based on the appearance and location of bite wounds. Two cats were envenomed by the *Gloydius* species and one by an unidentified species. Clinical signs were detected, including local bite-site swelling, haemorrhagic discharge and necrosis. All three cats were given supportive treatment. An antivenom was administered to one cat, and the cat showed no adverse reactions. All cats survived, but skin necrosis remained a complication of the snake envenomation. This was observed during the 1-year follow-up period.

Relevance and novel information Cats with snake envenomation are extremely rare in South Korea, and information regarding clinical details are limited. This study is the first to describe the clinical details and prognosis of feline snake envenomation in South Korea.

Keywords: Antivenom; necrosis; snake bite; South Korea

Accepted: 15 April 2023

Introduction

Snake envenomation is considered a potentially fatal medical emergency in human and veterinary medicine. In South Korea, approximately 3000 people are bitten every year by venomous snakes, and five people die due to snake envenomation.¹ There is little published information in South Korea about the incidence of snake envenomation in veterinary medicine. However, two studies in South Korea revealed a mortality rate for venomous snakebites in dogs of 1.7% and 7%, respectively.^{2,3} There are four major species responsible for venomous snakebites in South Korea: *Gloydius ussuriensis*, *Gloydius brevicaudus*, *Gloydius intermedius* and *Rhabdophis tigrinus*.^{1–3} Toxins in snake venom can cause coagulotoxicity, myotoxicity and neurotoxicity with various clinical signs, including coagulopathy, muscle pain and altered mentation.⁴

Snake envenomation in feline medicine is rarely reported because cats are bitten less frequently than other animals, including dogs, because of their cautiousness.⁵ Moreover, the tendency of cats to hide when envenomed can make it difficult for owners to find envenomed

cats.⁵ In this study we report extremely rare cases of feline snake envenomation in South Korea. To the authors' knowledge, this is the first case report describing the clinical features, treatment and prognosis of snake envenomation in cats in South Korea.

Case series description

Case 1

A 1-year-old, 5.2-kg, male, neutered, Korean shorthair cat presented with local swelling on the right thoracic limb and an increased respiratory rate. This indoor/outdoor cat lived in a rural area, and the owner could not

¹College of Veterinary Medicine, Chungnam National University, Daejeon, South Korea

²Korea Animal Medical Center, Cheongju, South Korea

Corresponding author:

Kun-Ho Song DVM, PhD, Department of Veterinary Internal Medicine, College of Veterinary, Chungnam National University, Daejeon 34134, South Korea
Email: songkh@cnu.ac.kr



Creative Commons Non Commercial CC BY-NC: This article is distributed under the terms of the Creative Commons

Attribution-NonCommercial 4.0 License (<https://creativecommons.org/licenses/by-nc/4.0/>) which permits non-commercial use, reproduction and distribution of the work without further permission provided the original work is attributed as specified on the SAGE and Open Access pages (<https://us.sagepub.com/en-us/nam/open-access-at-sage>).

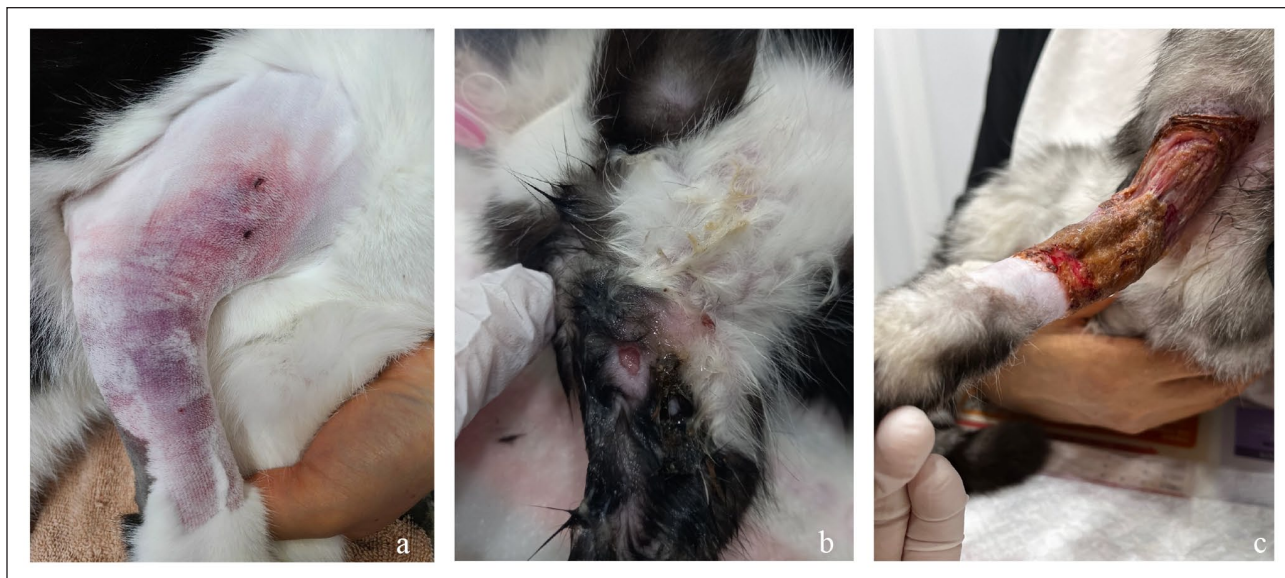


Figure 1 Photographs of the cats with snake envenomation: (a) fang mark, cutaneous erythema and local swelling at the bite site of cat 1; (b) fang mark, local oedema and haemorrhagic discharge of cat 2; and (c) tissue necrosis and ulceration at the bite site of cat 3

verify when the cat first showed clinical signs. Physical examination revealed cutaneous erythema and fang marks on the right thoracic limb (Figure 1). Its mentation was normal, and vital signs were normal except for tachypnoea. A complete blood count (CBC), serum biochemistry, venous blood gas, D-dimer and peripheral blood smear were obtained. The CBC was normal except for mild thrombocytopenia (234×10^9 cells/l; reference interval [RI] 300–500). The serum chemistry and venous blood gas analysis revealed no abnormalities except for elevated creatine kinase (1494 U/l; RI 87–309), hyperphosphatemia (7.5 mg/dl; RI 2.6–6.0) and mild hyperkalaemia (4.9 mEq/l; RI 3.3–4.5). The D-dimer level was elevated (0.5 μ l/ml; RI 0–0.3), and a peripheral blood smear revealed echinocytosis.

After identifying the fang marks, the snake envenomation signs were treated with intravenous administration of one vial of antivenom. In addition, the cat received fluid therapy, 0.4 mg/kg butorphanol, 10 mg/kg ampicillin twice daily, 15 mg/kg metronidazole twice daily and 0.5 mg/kg vitamin K1 twice daily for supportive treatment. Clinical improvements in tachypnoea, local swelling and cutaneous erythema were observed 24 h after the treatment, including the antivenom. An adverse reaction to the antivenom was not observed in this case. The patient continued to improve and was discharged 90 h after presentation (Table 1).

Case 2

A 2-month-old, 0.45-kg, male, Korean shorthair kitten was presented for right forelimb lameness 3 days after a witnessed *Gloydius brevicaudus* envenomation. The patient was an outdoor kitten living in the countryside. On

physical examination, the kitten showed fang marks accompanied by local swelling, haemorrhagic discharge and cutaneous erythema of the right thoracic limb (Figure 1). Initial diagnostics included CBC and serum chemistry, and these were evaluated based on the paediatric reference interval, exhibiting leucocytosis (30.3×10^9 cells/l; RI 5.5–19.5). The D-dimer result (0.1 mg/dl; RI 0–0.3) was within the reference interval.⁶ It was decided that the kitten was to be managed conservatively as an outpatient, with irrigation, gauze dressing and 15 mg/kg amoxicillin/clavulanate twice daily. In addition, 24 h of Elizabethan (EB) collar wearing was advised to prevent grooming of the bite site, reduce further damage and promote wound healing. After 7 days of consecutive supportive management, the kitten no longer showed local swelling or haemorrhagic discharge at the bite site. It did not experience complications during the 7-month follow-up period.

Case 3

A 3-month-old, 0.7-kg, female, Korean shorthair kitten was presented for a *Gloydius intermedius* envenomation. This was an outdoor kitten, and the owner observed the snake biting the right axillary part of the patient. Wound dressing was performed immediately after the snakebite in another local animal hospital, and the fang mark was confirmed 5 days before presentation. Upon the initial examination, the patient was alert and responsive. The right axillary region had haemorrhagic discharge, cutaneous erythema and ulceration, but fang marks were not observed due to severe skin lesions (Figure 1). The owner declined additional diagnostic examination. Supportive treatment was prescribed, including wound dressing and 15 mg/kg amoxicillin/clavulanate twice daily. Two

Table 1 CBC results of case 1

CBC	Day 1	Day 2	Day 3	Day 4	Reference interval
WBC (K/ μ l)	9.9	12.9	8.3	9.2	5.5–19.5
RBC (M/ μ l)	11.1	9.48	8.59	10.7	5.2–10
HGB (g/dl)	16.5	14.2	12.8	16.2	8.5–15
Haematocrit (%)	44	38	34	43	30–40
MCV (fl)	40	40	40	40	39–55
MCH (pg)	15	15	15	15	13–17
MCHC (g/dl)	37	37	38	38	30–36
Platelet (K/ μ l)	234	119	218	243	300–500

CBC = complete blood count; WBC = white blood cell; RBC = red blood cell; HGB = haemoglobin; MCV = mean cell volume; MCH = mean cell haemoglobin; MCHC = mean cell haemoglobin concentration

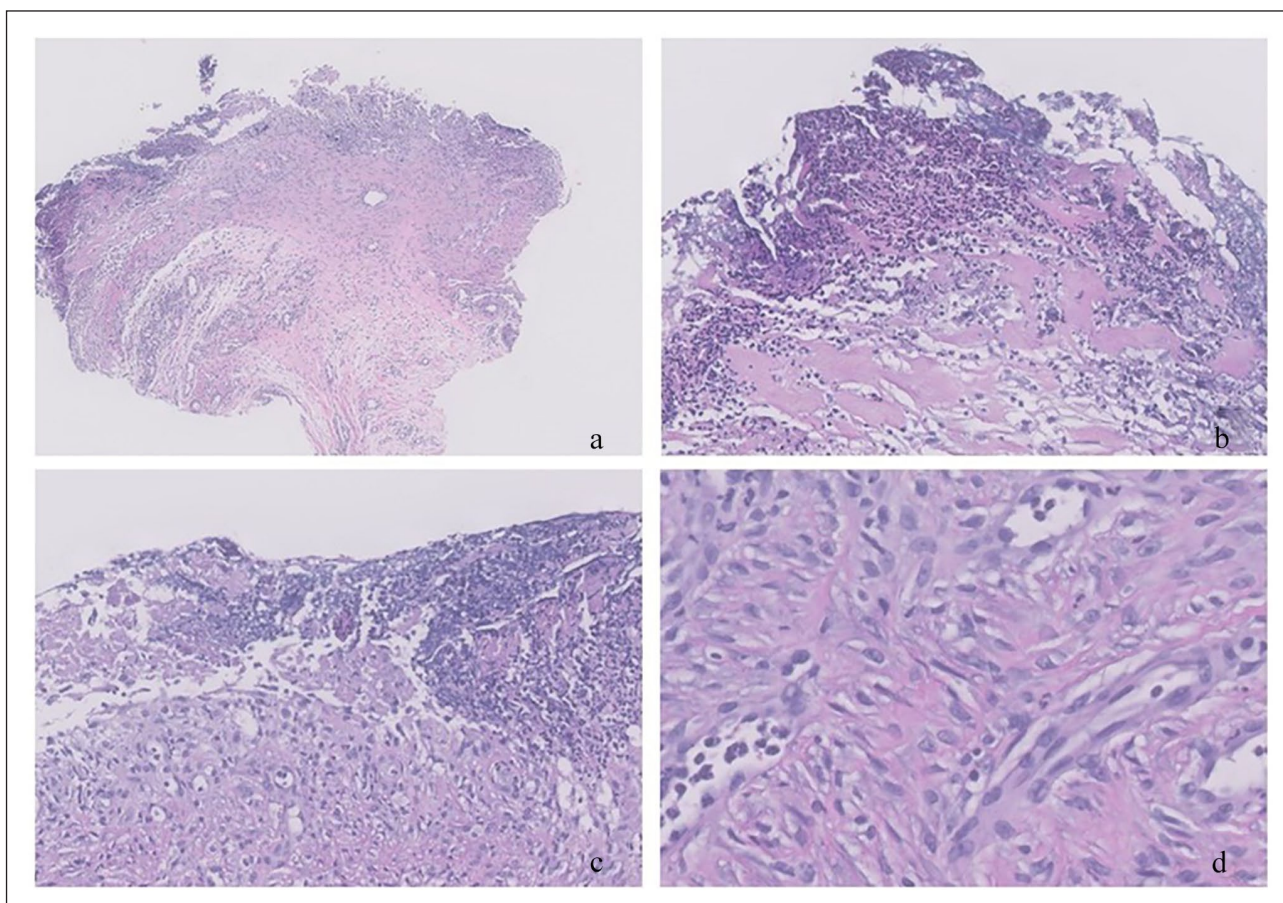


Figure 2 Histopathology of skin necrosis of cat 3, showing necrotic and mineralised debris with neutrophilic inflammation. Haematoxylin and eosin staining: (a) $\times 50$ magnification; (b) $\times 200$ magnification; (c) $\times 200$ magnification; and (d) $\times 400$ magnification

months after the snake envenomation, CBC and serum chemistry were evaluated based on the paediatric reference range, and the results were within the reference range except for mild anaemia and an elevated feline serum amyloid A (FSAA) level (78.6 μ g/ml; RI 0–5).⁶ The owner regularly dressed the wound, but the skin did not improve and showed necrosis accompanied by mineral and neutrophilic inflammation based on histopathology.

Skin necrosis remained a complication of the snake envenomation and was observed during the 1-year follow-up period (Figure 2).

Discussion

To our knowledge, this is the first case report that describes naturally occurring snake envenomation in cats in South Korea. Due to the limited information on cats diagnosed

with snake envenomation, the current management of envenomed cats is based on human or canine studies.⁷ There are a few studies on cats envenomed by *Vipera palaestinae*, which is native to Israel, and a rattlesnake native to Southern California.^{5,8} However, because snakes show distinct envenomation characteristics depending on the species, region and prey they eat, it is important to analyse the characteristics of local snakes.^{4,5,8} In this report, the bite sites were localised to the right forelimb in all three cats. Our findings are consistent with other feline envenomation studies, in which a forelimb was the most frequent bite site. However, they differ from studies on snake envenomation in dogs, where bite sites were localised to the head and face.^{2,3} Proper identification of the snake species is important, because the antivenom available in South Korea is only effective for *Gloydius* species envenomation.⁹ Of the snakebites reported in humans in South Korea, only 6% were identified at the genus level, revealing 96.6% of *Gloydius* species and 3.4% of *Rhabdophis* species. In this report, two of the three cats were identified as being envenomed by *Gloydius intermedius* and *Gloydius brevicaudus*, respectively.

Toxins in snake venom have various toxic effects, including coagulotoxic, myotoxic and neurotoxic effects, which result in local and systemic clinical signs.^{2,4} In humans in South Korea, local clinical symptoms, including local swelling, pain, redness and necrosis, and systemic clinical signs, including haematochezia, gastrointestinal bleeding, vomiting and myokymia, have been reported.¹⁰ In dogs in South Korea, local oedema, erythema, haemorrhagic discharge, necrosis, hypotension and respiratory distress have been reported.^{2,3} In this report, all cats showed local swelling and cutaneous erythema, one cat showed tachypnoea and two cats showed haemorrhagic discharge, consistent with the clinical signs reported for canine snake envenomation in South Korea.^{2,3} Thrombocytopenia was observed in the case 1 cat, accompanied by echinocytosis.

Coagulopathy is an important clinical effect of envenomation by the *Gloydius* and *Rhabdophis* species, which are indigenous to South Korea. In this study, no cats showed clinical deterioration, including massive haemorrhage, and no cats received a blood transfusion due to coagulopathy. D-dimer was measured in two cats, and one cat showed thrombocytopenia that manifested in an elevated D-dimer concentration. In contrast, the other cat with a normal platelet count showed a D-dimer concentration within the reference interval. In this case report, coagulation assays, including prothrombin time (PT), activated partial thromboplastin time (aPTT), fibrinogen and thromboelastography were not performed due to the owners' refusals or financial restrictions. In this study, a substantially high creatine kinase level was identified in one case after snake envenomation. It suggested that muscle damage was a

possible clinicopathological feature after snake envenomation.² Wound necrosis is often associated with snake envenomation. A cat treated only with antibiotics and wound dressing showed chronic complications manifested by skin necrosis. Guidelines for treating venomous snakebites in humans recommend surgical debridement of necrotic tissue.¹¹ Removing as much necrotic tissue as possible until the healthy tissue is detected is also recommended.¹¹ However, surgical debridement was not performed in our study due to the owners' refusal.

An antivenom is the only effective treatment for managing snake envenomation. The quality of antivenom varies among products and countries, which causes clinicians to hesitate before using it. One study in South Korea reported an adverse reaction characterised by nausea, diaphoresis, hypotension and dizziness in 4.1% of human patients.⁹ In this report, one cat treated with antivenom showed no adverse reactions, and its clinical signs recovered 24 h after administration. Systemic antibiotic administration after snake envenomation is controversial among clinicians. International skin and soft tissue infection guidelines recommend using amoxicillin/clavulanate to prevent secondary infection from animal bites.¹² However, some authors suggest treatment with antibiotics only in cases of severe local signs, including necrosis.¹³ In addition, one study recommended a third-generation cephalosporin for treating snakebite wounds because 60% of snakebite infections resist amoxicillin/clavulanate, and 66% resist a second-generation cephalosporin.¹³

This report has some limitations. First, no cats were presented to the emergency services immediately after snake envenomation. Thus, we could not conduct serial measurements of patients' physical and clinicopathological examination results. Second, coagulation examinations, including PT, aPTT and fibrinogen, were not possible due to the owners' refusal or financial constraints. Third, adequate pain relief was not applied to the patients with snake envenomation. As snake envenomation causes severe pain, adjunctive analgesics such as fentanyl, ketamine and α_2 -adrenoreceptor agonists should be considered for patients with snake envenomation.^{7,14} Fourth, the effectiveness of antivenom, antibiotics and vitamin K1 was challenging to assess in this report. Consequently, further studies are needed to evaluate the efficacy of antivenom, vitamin K1 and antibiotics.

Conclusions

This is the first case report describing the clinical details of snake envenomation in cats in South Korea. No cats died, but one cat showed persistent skin necrosis as a complication. Additional research is warranted to investigate the diagnosis and management of snake envenomation in cats in South Korea.

Conflict of interest The authors declared no potential conflicts of interest with respect to the research, authorship, and/or publication of this article.

Funding The authors received no financial support for the research, authorship, and/or publication of this article.

Ethical approval The work described in this manuscript involved the use of non-experimental (owned or unowned) animals. Established internationally recognised high standards ('best practice') of veterinary clinical care for the individual patient were always followed and/or this work involved the use of cadavers. Ethical approval from a committee was therefore not specifically required for publication in *JFMS Open Reports*. Although not required, where ethical approval was still obtained, it is stated in the manuscript.

Informed consent Informed consent (verbal or written) was obtained from the owner or legal custodian of all animal(s) described in this work (experimental or non-experimental animals, including cadavers) for all procedure(s) undertaken (prospective or retrospective studies). No animals or people are identifiable within this publication, and therefore additional informed consent for publication was not required.

ORCID iD Jeong-Min Lee  <https://orcid.org/0000-0003-2920-7171>

References

- Shin Y, Jang Y and Borzée A. **Snakebite envenomings in the Republic of Korea from the 1970s to the 2020s: a review.** *Toxicon* 2021; 196: 8–18.
- Lee JM, Song JH and Song KH. **A retrospective evaluation of snake envenomation in dogs in South Korea (2004–2021).** *Toxins (Basel)* 2022; 14: 565.
- Kim D, Kim S, Kim JK, et al. **Clinical features and management of snake bites in 70 dogs in Korea.** *J Vet Sci* 2022; 23: e81.
- Park EJ, Choi S, Kim HH, et al. **Novel treatment strategy for patients with venom-induced consumptive coagulopathy from a pit viper bite.** *Toxins (Basel)* 2020; 12: 295.
- Lenchner I, Aroch I, Segev G, et al. **A retrospective evaluation of Vipera palaestinae envenomation in 18 Cats: (2006–2011).** *J Vet Emerg Crit Care* 2014; 24: 437–443.
- Michael EP and Michelle AK. *Small animal pediatrics. 1st ed.* Saint Louis, MO: Elsevier Saunders, 2011, pp 305–327.
- Yankin I, Schaer M, Johnson M, et al. **Persistent pit viper envenomation in a cat.** *JFMS Open Rep* 2017; 3: 2.
- Hoose JA and Carr A. **Retrospective analysis of clinical findings and outcome of cats with suspected rattlesnake envenomation in Southern California: 18 cases (2007–2010).** *J Vet Emerg Crit Care* 2013; 23: 314–320.
- Shim JS, Kang H, Cho Y, et al. **Adverse reactions after administration of antivenom in Korea.** *Toxins (Basel)* 2020; 12: 507.
- Lim H, Kang HG and Kim KH. **Antivenom for snake bite in Korea.** *J Korean Med Assoc* 2013; 56: 1091–1103.
- Rha JH, Kwon SM, Oh JR, et al. **Snakebite in Korea: a guideline to primary surgical management.** *Yonsei Med J* 2015; 56: 1443–1448.
- Stevens DL, Bisno AL, Chambers HF, et al. **Practice guidelines for the diagnosis and management of skin and soft tissue infections: 2014 update by the Infectious Diseases Society of America.** *Clin Infect Dis* 2014; 59: 147–159.
- Resiere D, Gutiérrez JM, Névière R, et al. **Antibiotic therapy for snakebite envenoming.** *J Venom Anim Toxins Incl Trop Dis* 2020; 26: e20190098.
- Gilliam LL and Brunner J. **North American snake envenomation in the dog and cat.** *Vet Clin North Am Small Anim Pract* 2011; 41: 1239–1259.