



Case report

Reconstruction of traumatic medial malleolus loss using the bone sliding technique: A case report

Danlei Huang, Jun Wang, Zhiyang Ye, Haoyuan Liu, Jianming Huang*

Department of Orthopedics, Chengong Hospital (the 73th Group Military Hospital of People's Liberation Army) affiliated to Xiamen University, Xiamen 361000, People's Republic of China

ARTICLE INFO

Keywords:

Medial malleolus loss
Bone sliding technique
Ankle reconstruction
Walking function
Joint stability
Case report

ABSTRACT

Introduction: Open injury of the medial malleolus is relatively rare, and it can cause instability of the ankle joint and affect the walking function of the lower extremity. We describe an original plan for the reconstruction of medial malleolus defects using the bone sliding technique and report as follows.

Case presentation: A 48-year-old female presented with an isolated open injury to her right ankle by a traffic accident. The skin of the medial ankle was severely contaminated with mud, and the medial malleolus, part of the Talus's cartilage and soft tissue, were defective. The anterior tibial artery was cut, and the anterior and posterior tibial tendons were ruptured.

Conclusion: We describe the reconstruction of the medial malleolus using a bone sliding technique. At two years follow-up, she had a good outcome with a nearly painless, stable ankle with functional plantarflexion but restricted dorsiflexion. The original method is a new choice for the reconstruction of the medial malleolus.

1. Introduction and importance

The medial malleolus is one of the essential stable structures of the ankle joint, Open injury of the medial malleolus is relatively rare, and it can cause instability of the ankle joint and affect the walking function of the lower extremity. The primary reconstruction method of medial malleolus defects, including iliac bone graft transplanting, fibular graft transplanting, and so on, But these operation methods were too complicated. Meanwhile, it will lead to an additional injury of the iliac crest and fibula. We describe an original plan for the reconstruction of medial malleolus defects using the bone sliding technique and report as follows. This case was reported according to the SCARE criteria [1].

2. Case presentation

A 48-year-old female presented with an isolated open injury to her right ankle by a traffic accident. She is a type 1 diabetes for several years, long term oral hypoglycemic treatment (unknown) and good blood glucose control. The skin of the medial ankle was severely contaminated with mud, and the skin cover was acceptable (Fig. 1). The medial malleolus, part of the Talus's cartilage, and soft tissue were defective. The

anterior tibial artery was cut, and the anterior and posterior tibial tendons were ruptured (Figs. 2–4). In this case, the surgeon (Huang JM) had planned to reconstruct the medial malleolus by using the bone sliding technique. After thorough debridement, the extended incision was made from the medial malleolus to the proximal side, and the distal end of the medial tibia was exposed with the periosteum carefully protected. The periosteum was cut about 2.5 * 6 cm (Fig. 5), then the size of the bone block was made about 2.5 * 6 * 1 cm (Fig. 6). The distal end of the bone block was modified to simulating the shape of the medial malleolus (Fig. 7). The periosteum was transplanted to cover the cartilage defects of the Talus and 2 cm distal end of the bone block (Figs. 6 and 8). Then the bone block was sliding to the distal end of the tibia to reconstruct the medial malleolus (Fig. 9). The reconstructed medial malleolus length is about 2 cm, and the proximal end of the bone block was fixed with two cannulated screws. After reconstructed the bone structure, sutured and trimmed the broken ends of posterior tibial tendon and flexor longus tendon by using Kessler, at the meantime, strengthened the suture intermittently. Sutured the broken Achilles tendon with the same method, and the tension is good after suture.

* Corresponding author.

E-mail address: gianming@qq.com (J. Huang).<https://doi.org/10.1016/j.ijscr.2021.106677>

Received 30 September 2021; Received in revised form 28 November 2021; Accepted 5 December 2021

Available online 8 December 2021

2210-2612/© 2021 The Authors. Published by Elsevier Ltd on behalf of IJS Publishing Group Ltd. This is an open access article under the CC BY-NC-ND license

<http://creativecommons.org/licenses/by-nc-nd/4.0/>.

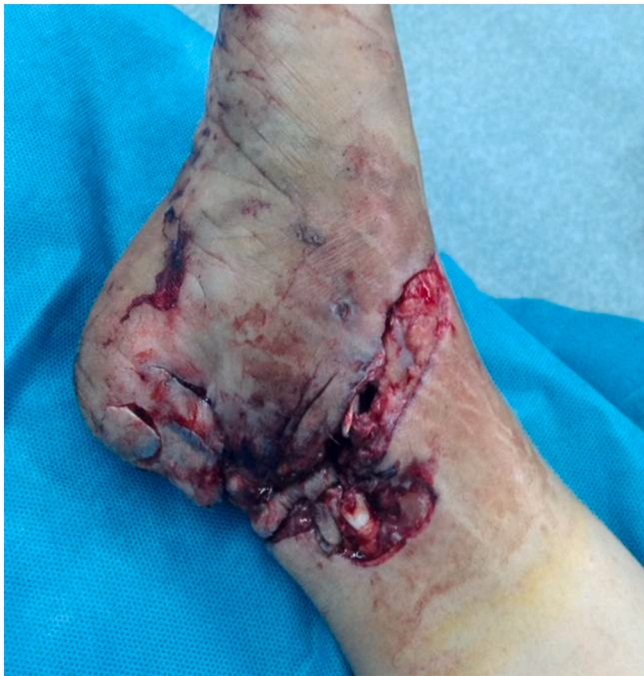

Fig. 1. The skin of medial ankle was severe contaminated with mud, and the skin cover was acceptable.

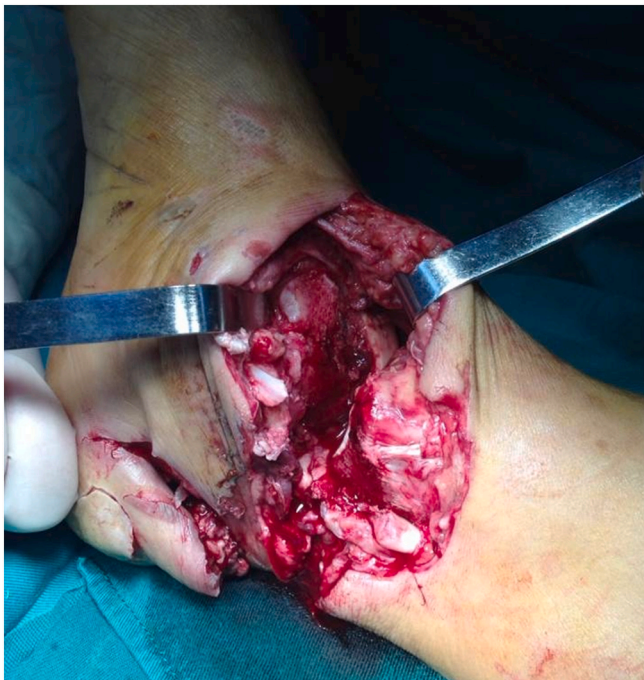

Fig. 2. The medial malleolus, Part of the Talus's cartilage and soft tissue were defect. The anterior tibial artery was cut, and the anterior and posterior tibial tendons were ruptured.

3. Results

At two years follow-up, the patient had no complaints about any difficulties in walking, although with nearly 0 degrees of dorsiflexion and 30 degrees of plantar flexion. The radiographs from the 6-month follow-up showed consolidation of the sliding bone block (Fig. 10-11). The patient had obtained a stable ankle with her gait painlessly and unaided. She was satisfied with her walking function. The AOFAS score [2] was 86.

4. Clinical discussion

The ankle joint is a weight-bearing joint, mainly rely on the bone and ligament structure to provide its stability. The medial malleolus defect is not common in the clinic and usually associated with a defect of the triangular ligament. The main method of the reconstruction of joint stability includes ligament and bone structure reconstruction. In 1994, Boyer [3] reported 1 case of the medial malleolus, ligament, and skin soft-tissue defect, he used tendon graft to reconstruct the medial stability, and good clinical results were obtained. In 2000, Mayr [4] reported the application of autologous free iliac bone with epiphyseal cartilage to repair the defect of medial malleolus in children. The result was excellent, and the graft for the medial malleolus reconstruction still had the growing ability. In 2010, Manasseh [5] reported a case of reconstruction of medial malleolus using autologous iliac bone graft with a satisfying result. In 2012, Abbo [6] used the free iliac bone and fascia graft to reconstruct the defect of medial malleolus and deltoid ligament. He thought that the morphology of iliac bone and medial malleolus were similar, and the fusion of bone graft could be easier. Also, the reconstruction of the triangle ligament defect with a fascia strip could achieve a better result. Instead, Wu [7,8] used a free fibular with biceps femoris tendon to reconstruct the medial malleolus and triangular ligament.

The disadvantages of the reconstruction method mention above were large trauma, complicated procedure, and the defects of the ilium and fibular. We describe a new method of medial malleolus reconstruction using the bone sliding technique. The procedure was simple and had no additional trauma.

The distal end of the sliding bone block can well simulate the medial malleolus. At the same time, the covering of cartilage defect with periosteum has a certain ability to produce cartilage under the condition of stress [9], which may play an important role in repairing cartilage damage.

In this case, there was no absorption of the sliding bone block at two years follow-up. The patient had obtained a stable ankle after reconstruction of medial malleolus without reconstruction of the deltoid ligament. This kind of technique resulted in a stiff, but painless foot. She was satisfied with the final function.

In conclusion, the reconstruction of medial malleolus using the bone sliding technique is a new method described above, which is an easier technique and can obtain a good functional result.

Ethical approval

This is a case report; therefore, it did not require ethics committee review and ethical endorsement. But we have got her permission to publish her data.

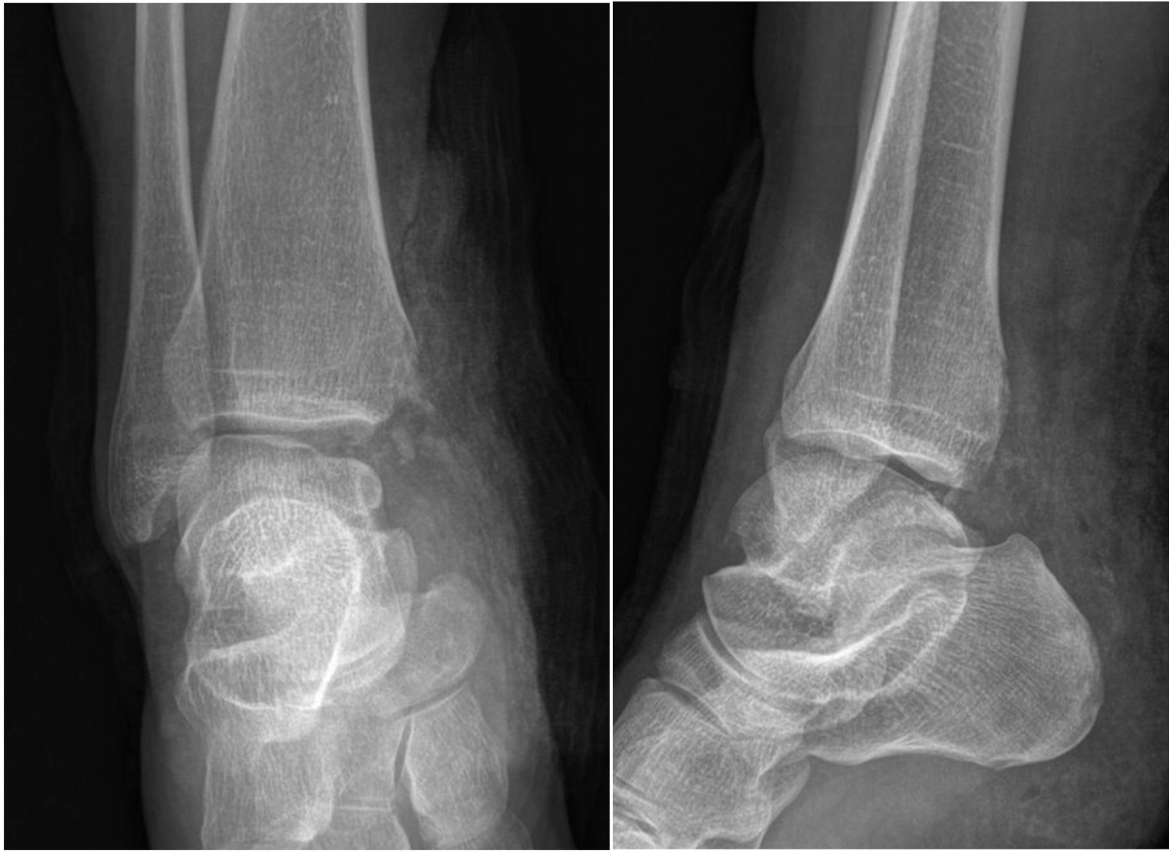

Fig. 3-4. Pre-operation X ray with loss of medial malleolus.

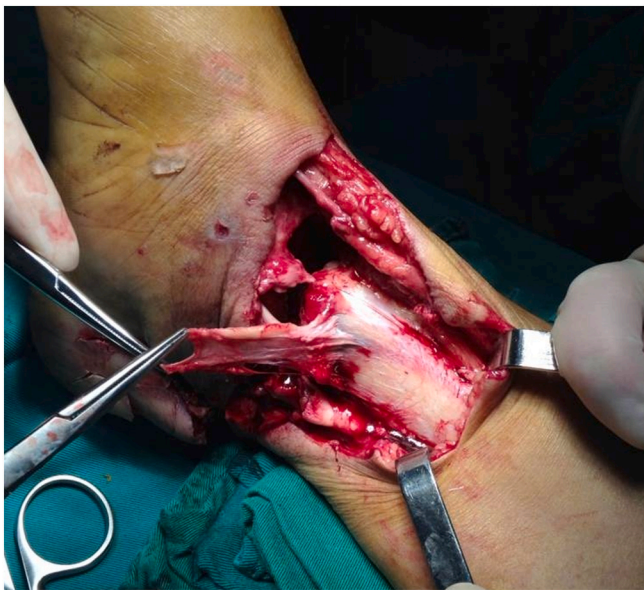

Fig. 5. The periosteum was cut 2.5 * 6 cm in size.

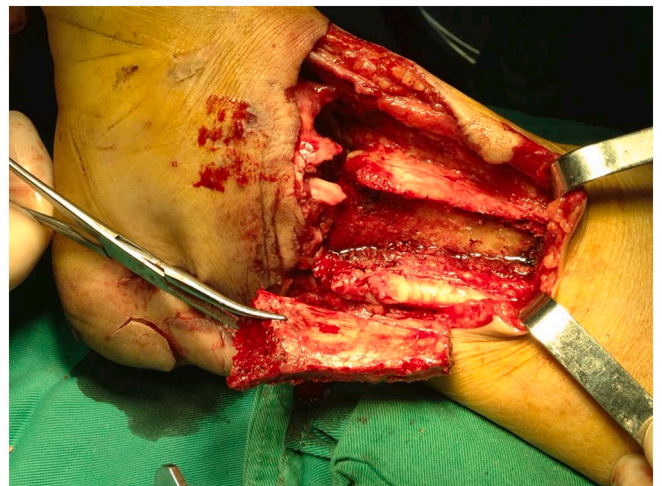

Fig. 6. The size of bone block was made about 2.5 * 6 * 1 cm.

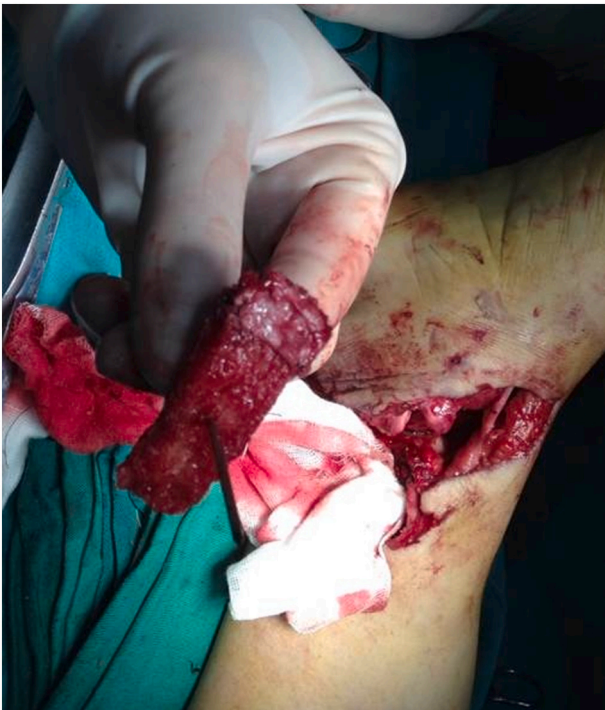

Fig. 7. The distal end of the bone block was modified to simulating the shape of the medial malleolus, and the periosteum was transplanted to cover 2 cm distal end of the bone block to simulate the medial malleolus cartilage.

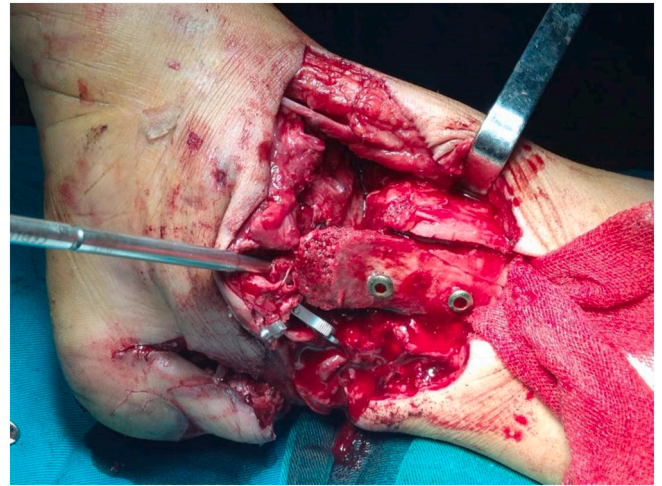


Fig. 9. The bone block was sliding to the distal end of the tibia to reconstruct the medial malleolus and fixed with 2 cannulated screws.

Sources of funding

Xiamen Superior Sub-construction project of Arthroscopic minimally invasive Orthopedics department. Xiamen Key Specialty construction project of Traumatic Orthopedics department.

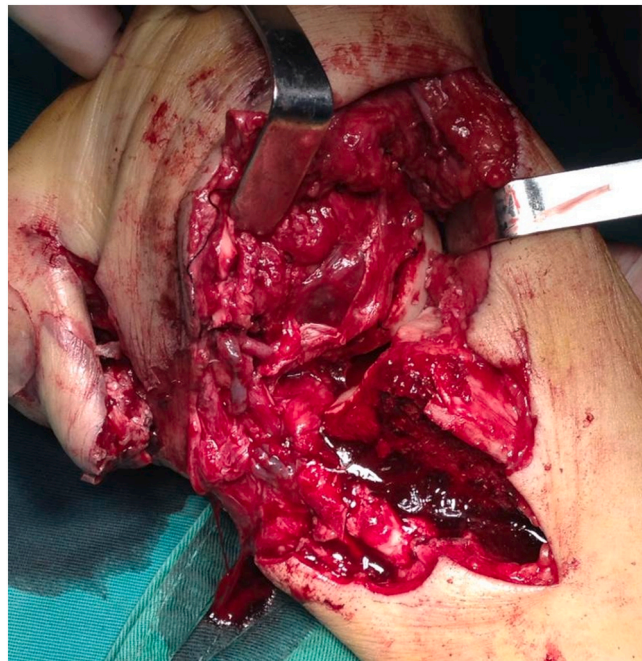

Fig. 8. The periosteum was transplanted to cover the cartilage defects of the talus.

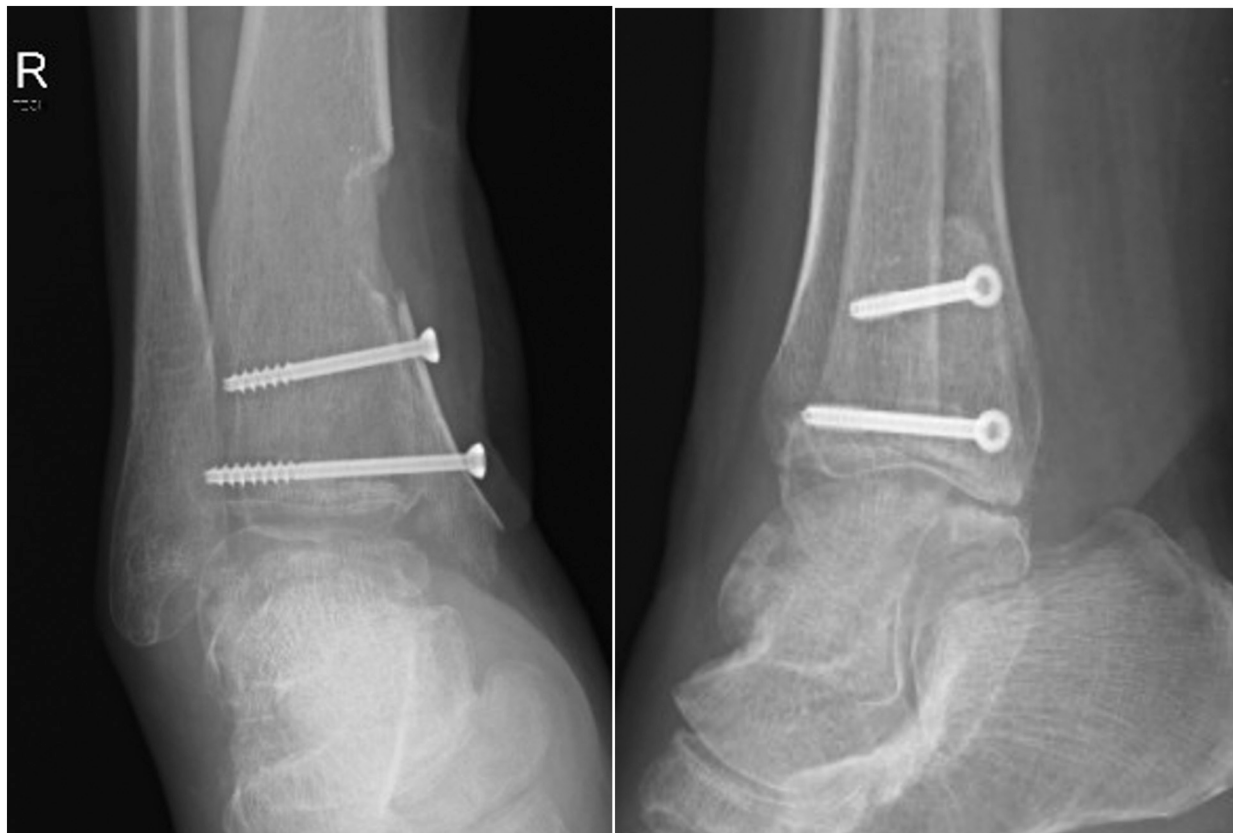

Fig. 10-11. The radiographs from 6-month follow-up showed consolidation of the sliding bone block.

Author contribution

Danlei Huang, Preparation of case report, Literature review, Writing paper.

Jun Wang, Preparation of case report, Writing the paper.

Zhiyang Ye, Preparation of case report, Writing the paper.

Haoyuan Liu, Preparation of case report, Writing the paper.

Jianming Huang, Preparation of case report, Writing the paper. performed the procedure.

Consent

Written informed consent was obtained from the patient for publication of this case report and accompanying images. A copy of the written consent is available for review by the Editor-in-Chief of this journal on request.

Research registration number

N/A

Guarantor

Jianming Huang.

Provenance and peer review

Not commissioned, externally peer reviewed.

Declaration of competing interest

The authors declare that there is no conflict of interest in the publication of this paper.

References

- [1] R.A. Agha, T. Franchi, C. Sohrabi, G. Mathew, A. Kerwan, The SCARE 2020 guideline: updating consensus surgical CAse REport (SCARE) guidelines, *Int. J. Surg.* 84 (2020) 226–230.
- [2] H.B. Kitaoka, I.J. Alexander, R.S. Adelaar, J.A. Nunley, M.S. Myerson, M. Sanders, Clinical rating systems for the ankle-hindfoot, midfoot, hallux, and lesser toes, *Foot Ankle Int.* 15 (7) (1994) 349–353.
- [3] M.I. Boyer, V. Bowen, P. Weiler, Reconstruction of a severe grinding injury to the medial malleolus and the deltoid ligament of the ankle using a free plantaris tendon graft and vascularized gracilis free muscle transfer: case report, *J. Trauma* 36 (3) (1994) 454–457.
- [4] J.M. Mayr, G.R. Pierer, W.E. Linhart, Reconstruction of part of the distal tibial growth plate with an autologous graft from the iliac crest, *J. Bone Joint Surg. Br.* 82 (4) (2000) 558–560.
- [5] M. Nithyananth, V.M. Cherian, T.S. Jepeganiam, Reconstruction of traumatic medial malleolus loss: a case report, *Foot Ankle Surg.* 16 (2) (2010) e37–e39.
- [6] O. Abbo, F. Accadbled, J.M. Laffosse, J.S. De Gauzy, Reconstruction and anticipatory Langenskiöld procedure in traumatic defect of tibial medial malleolus with type 6 physeal fracture, *J. Pediatr. Orthop. B* 21 (5) (2012) 434–438.
- [7] S.P. Wu, F.H. Zhang, F.B. Yu, R. Zhou, Medial malleolus and deltoid ligament reconstruction in open ankle fractures with combination of vascularized fibular head osteo-tendinous flap and free flap transfers, *Microsurgery* 29 (8) (2009) 630–635.
- [8] S.P. Wu, Clinical study of reconstructing the medial malleolus with free grafting of fibular head composite tendon bone flap, *Chin. J. Traumatol.* 11 (1) (2008) 34–36.
- [9] J.L. van Susante, A.B. Wymenga, P. Buma, Potential healing benefit of an osteoperiosteal bone plug from the proximal tibia on a mosaicplasty donor-site defect in the knee. An experimental study in the goat, *Arch. Orthop. Trauma Surg.* 123 (9) (2003) 466–470.