

This is an Open Access article licensed under the terms of the Creative Commons Attribution-NonCommercial-NoDerivs 3.0 License (www.karger.com/OA-license), applicable to the online version of the article only. Distribution for non-commercial purposes only.

Histological Remission during Corticosteroid Therapy of Overlapping Nonalcoholic Steatohepatitis and Autoimmune Hepatitis: Case Report and Literature Review

Shinichiroh Fukuda^a Atsumasa Komori^{a, b} Masahiro Itoh^{a, b}
Yumi Mihara^a Satoru Hashimoto^a Sung Kwan Bae^{a, b}
Shinya Nagaoka^a Seigo Abiru^a Hiroshi Yatsushashi^{a, b}
Hiromi Ishibashi^{a, b}

^aClinical Research Center, National Hospital Organization Nagasaki Medical Center, and ^bDepartment of Hepatology, Nagasaki University Graduate School of Biomedical Sciences, Omura, Japan

Key Words

Nonalcoholic steatohepatitis · Autoimmune hepatitis · Corticosteroid therapy · Histological remission

Abstract

Concurrence of nonalcoholic steatohepatitis (NASH) with autoimmune hepatitis (AIH) is a rare condition that is challenging to diagnosis, due to the relatively high prevalence of autoantibodies in NASH. It is also difficult to determine the most effective treatment as corticosteroids are likely to worsen NASH despite being effective in the treatment of AIH. In this case report, we present a female diagnosed with NASH-AIH overlap with accompanying diabetes mellitus, who successfully achieved normalization of serum alanine aminotransferase levels following prednisolone therapy and weight loss. A follow-up liver biopsy performed 40 months after the initial diagnosis showed only minimal inflammatory infiltrates in the portal area without any NASH histology. Resolution of NASH, in conjunction with a reduction in hepatic fibrosis, might suggest that prednisolone itself does not aggravate steatohepatitis, but rather prevents disease progression. Appropriate immunosuppressive treatment may therefore be an important component of the optimum therapy for NASH-AIH overlap.

Introduction

Concurrence of more than one disease in the liver (thereafter ‘overlap’) may have a significant impact on disease progression. Due to a progressive increase in the prevalence of nonalcoholic fatty liver disease (NAFLD) associated with ‘endemic’ obesity, overlapped NAFLD, especially in its necroinflammatory form of nonalcoholic steatohepatitis (NASH), has gained clinical relevance in the diagnosis and prognosis of chronic liver disease. In fact, patients with chronic hepatitis C and NASH have more advanced stages of fibrosis accompanied by more severe metabolic syndrome than those with chronic hepatitis C or chronic hepatitis C and nonalcoholic steatosis [1]. Regarding overlap with other forms of chronic liver disease, NASH-autoimmune hepatitis (AIH) overlap syndrome has received special attention for several reasons. First, histological diagnosis of NASH-AIH overlap is absolutely required, owing to previous reports that autoantibodies were present in about one quarter of patients with NAFLD [2] and that without liver biopsy [3], almost all the female patients were incorrectly diagnosed with AIH. Second, the optimum treatment regimen to achieve biochemical remission has been difficult to standardize; corticosteroids are likely to worsen NASH [4] but improve AIH-related necroinflammation [5]. Third, the natural course and postintervention prognosis remain to be characterized. To our knowledge, 8 cases of biopsy-proven NAFLD-AIH overlap syndrome have been reported to date [2, 3, 6], 3 with NASH and 5 with NAFLD (the latter without detailed information on the presence of steatohepatitis). Among these, 2 cases of NASH-AIH overlap were treated with corticosteroid, but histological changes as revealed by follow-up liver biopsies have not yet been reported [6].

In this report we describe a patient with NASH-AIH overlap who successfully achieved histological remission of AIH as well as resolution of NASH with a combination of prednisolone therapy and weight loss. This is the first report demonstrating that corticosteroids improve the prognosis of NASH-AIH overlap.

Case Report

A 57-year-old female patient was referred to our hospital with a 2-year history of low-grade but gradually progressing aminotransferase elevation. On admission, clinical examination was normal but blood tests revealed elevated liver enzymes, i.e., AST 174 IU/l (normal <37 IU/l), ALT 302 IU/l (normal <39 IU/l), ALP 263 IU/l (normal <359 IU/l), and γ -GTP 120 IU/l (normal <75 IU/l). Her serum autoantibody profile was as follows: anti-nuclear antibody 1,280 \times (speckled), anti-smooth muscle antibody 80 \times , and anti-SS-A 64 \times , but anti-mitochondria antibody was negative. Serum IgG was increased to 2,370 mg/dl (normal <1,700 mg/dl) and human leukocyte antigen was found to be DR3/DR4⁺. Viral markers for HBV and HCV were both negative. Elevated fasting blood glucose (123 mg/dl) coupled with increased HbA1c (7.3%) indicated comorbid diabetes mellitus. The homeostasis model assessment of insulin resistance (HOMA-R) was 11.4, though the patient was not significantly obese (body mass index was 23.6). She had no history of regular alcohol consumptions. As abdominal CT scan and ultrasonography both suggested the presence of fatty liver, subsequent liver biopsy was required to narrow down the differential diagnosis that included NAFLD, AIH, and their concurrence. Liver histology ([fig. 1](#)) revealed severe interface hepatitis with mononuclear cells infiltrates including plasma cells. Steatosis and pericellular/bridging fibrosis were also prominent, accompanied by hepatocyte ballooning, implicating concurrence with the histological features of steatohepatitis.

A diagnosis of NASH-AIH overlap was made (AIH score was 18, i.e., definite, together with NASH grade 2/stage 3 according to the Blunt classification system), and 30 mg of prednisolone per day p.o. was initiated. Prednisolone exacerbated the patient’s diabetes during the 1st week of treatment, necessitating the administration of rapid-acting insulin. As aminotransferase levels began to decrease shortly after the

initiation of treatment, prednisolone was gradually tapered to 15 mg/day over 6 months until liver enzymes normalized. The patient also lost 6 kg during this period. Prednisolone was further tapered to 5 mg/day over the next 12 months, without any hepatitis flare-up. Ursodeoxycholic acid 600 mg/day p.o. was then added to prednisolone as maintenance therapy, and rapid-acting insulin was subsequently replaced with an oral hypoglycemic agent. Follow-up liver tissue examination performed 40 months after diagnosis revealed only minimal inflammatory infiltrates in the portal area without any histological evidence of steatohepatitis (fig. 2). The fibrosis score established by Ishak et al. [7] decreased from 4 at diagnosis to 1, while the NAFLD activity score [8] (scale developed by the NASH Clinical Research Network) decreased from 6 to 2.

Discussion

In this report we present a NASH-AIH overlap patient who successfully achieved histological remission of both AIH and NASH following prednisolone therapy. To our knowledge, this report is the first to document the detailed clinical course of NASH-AIH overlap during prednisolone therapy, accompanied by documentation of histological improvement.

Information regarding treatment regimen was presented in 6 out of 8 NAFLD-AIH overlap cases in the literature [2, 3, 6]: 2 patients were given prednisolone combined with diet therapy, resulting in a partial biochemical response [6]. On the other hand, 1 out of 2 patients treated with ursodeoxycholic acid and modified diet was reported to show normalized aminotransferases [3]. The remaining 2 cases were not treated, in 1 case due to coexisting diabetes and dyslipidemia despite the presence of definite AIH [2]. Due to the anti-inflammatory action of glucocorticoid, fibrosis in AIH commonly improves or does not progress during therapy [9–11]. Reflecting glucocorticoids' cell- and tissue-specific mode of action through the glucocorticoid receptor, these compounds are also steatogenic in both clinical and experimental settings [12]. Persistently elevated glucocorticoid levels have been associated with fatty liver development and their consequent phenotype in NAFLD [13]. Moreover, dose-dependent association of glucocorticoid with secondary NASH was demonstrated in patients with systemic lupus erythematosus [14], and hepatic fat accumulation has been documented in patients with Cushing's syndrome. In accordance with clinical findings, Lemke et al. [15] recently reported that liver-specific glucocorticoid receptor knock-down by shRNA, through induction of transcriptional repressor hairy enhancer of split 1 (Hes1), caused a pronounced decrease in hepatic triglyceride levels in the livers of obese *db/db* mice.

The above findings raise concerns about the use of glucocorticoids in the treatment of NAFLD-AIH overlap. In our case the clinical benefit of prednisolone's immunosuppressive and fibrolytic action clearly outweighed its steatogenic properties. Our findings thus emphasize the need of appropriate immunosuppressive treatment even in comorbid AIH and NASH, though interindividual differences and genetic susceptibility may affect the glucocorticoids' steatogenic actions. It should be noted that our study used a shorter duration and lower total dosage of prednisolone administration for AIH compared to that for systemic lupus erythematosus, and this may not exacerbate concurrent NASH if it is accompanied with appropriate diet therapy, the gold standard treatment for NASH.

Loria et al. [6] reported that 3 out of 84 NAFLD patients (3.6%) were diagnosed with true NASH-AIH overlap after liver biopsy, whereas 1 out of 212 Japanese NAFLD

patients (0.5%) had definite AIH [3]. Given ethnic differences in susceptibility to the development of NASH-AIH overlap, the increasing prevalence of NAFLD worldwide probably makes NASH-AIH overlap more clinically relevant. Obviously, the false diagnosis of overlapped AIH in female NASH patients who have not undergone liver biopsy should be avoided, but true diagnosis of NASH-AIH accompanied by appropriate corticosteroid induction is needed to prevent disease progression.

We presented a patient with NASH-AIH overlap who achieved histological remission as a result of prednisolone therapy. Future prospective studies and the accumulation of definite cases are needed to validate the effectiveness of corticosteroid therapy for NASH-AIH overlap.

Acknowledgements

This study was supported in part by Grants-in-Aid for Clinical Research from National Hospital Organization, Grants-in-Aid for Scientific Research from the Ministry of Health, Labor and Welfare of Japan, and Grants-in-Aid for Scientific Research from the Japan Society for the Promotion of Science.

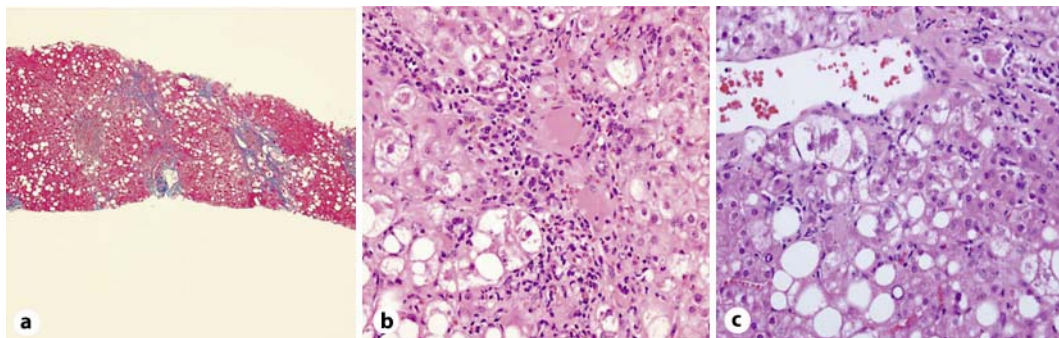


Fig. 1. Liver histology before therapy. **a** Azan stain (10×). Steatosis and pericellular/bridging fibrosis were prominent. Over 33% of the surface area was affected by steatosis of grade 2/stage 3 by the Blunt classification. **b** H&E stain (100×). Severe interface hepatitis with mononuclear cell infiltrates including plasma cells was revealed in the portal area. **c** H&E stain (100×). Hepatocyte ballooning, Mallory bodies, and infiltration of neutrophils to hepatic parenchyma are apparent around the central vein. The NAFLD activity score was calculated to be 6.

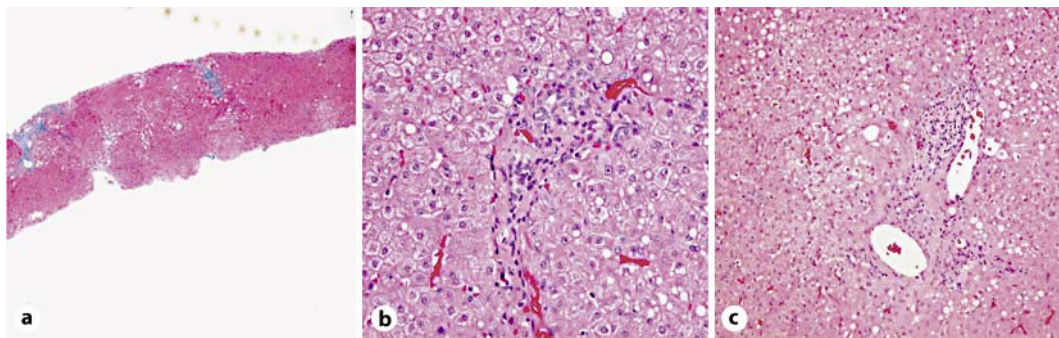


Fig. 2. Follow-up liver histology 40 months after diagnosis. **a** Azan stain (10×). Pericellular/bridging fibrosis was decreased. **b** H&E stain (100×). Interface hepatitis was improved, and only minimal inflammatory infiltrates are disclosed in the portal area. **c** H&E stain (40×). The NAFLD activity score had improved from 6 to 2, with no histological evidence of steatohepatitis around the central vein.

References

- 1 Bedossa P, Moucari R, Chelbi E, Asselah T, Paradis V, Vidaud M, Cazals-Hatem D, Boyer N, Valla D, Marcellin P: Evidence for a role of nonalcoholic steatohepatitis in hepatitis C: A prospective study. *Hepatology* 2007;46:380–387.
- 2 Adams LA, Lindor KD, Angulo P: The prevalence of autoantibodies and autoimmune hepatitis in patients with nonalcoholic fatty liver disease. *Am J Gastroenterol* 2004;99:1316–1320.
- 3 Yatsuji S, Hashimoto E, Kaneda H, Taniai M, Tokushige K, Shiratori K: Diagnosing autoimmune hepatitis in nonalcoholic fatty liver disease: is the International Autoimmune Hepatitis Group scoring system useful? *J Gastroenterol* 2005;40:1130–1138.
- 4 Matsumoto T, Yamasaki S, Arakawa A, Abe K, Abe H, Kon K, Kobayashi S, Takasaki Y: Exposure to a high total dosage of glucocorticoids produces non-alcoholic steatohepatitis. *Pathol Int* 2007;57:388–389.
- 5 Czaja AJ, Manns MP: Advances in the diagnosis, pathogenesis, and management of autoimmune hepatitis. *Gastroenterology* 2010;139:58–72.
- 6 Loria P, Lonardo A, Leonardi F, Fontana C, Carulli L, Verrone AM, Borsatti A, Bertolotti M, Cassani F, Bagni A, Muratori P, Ganazzi D, Bianchi FB, Carulli N: Non-organ-specific autoantibodies in nonalcoholic fatty liver disease: prevalence and correlates. *Dig Dis Sci* 2003;48:2173–2181.
- 7 Ishak K, Baptista A, Bianchi L, et al: Histological grading and staging of chronic hepatitis. *J Hepatol* 1995;22: 696–699.
- 8 Kleiner DE, Brunt EM, Van Natta M, Behling C, Contos MJ, Cummings OW, Ferrell LD, Liu YC, Torbenson MS, Unalp-Arida A, Yeh M, McCullough AJ, Sanyal AJ: Design and validation of a histological scoring system for nonalcoholic fatty liver disease. *Hepatology* 2005;41:1313–1321.
- 9 Czaja AJ, Carpenter HA: Decreased fibrosis during corticosteroid therapy of autoimmune hepatitis. *J Hepatol* 2004;40:646–652.
- 10 Czaja AJ, Carpenter HA: Progressive fibrosis during corticosteroid therapy of autoimmune hepatitis. *Hepatology* 2004;39:1631–1638.
- 11 Malekzadeh R, Mohamadnejad M, Nasseri-Moghaddam S, Rakhshani N, Tavangar SM, Sohrabpour AA, Tahaghoghi S: Reversibility of cirrhosis in autoimmune hepatitis. *Am J Med* 2004;117:125–129.
- 12 Herzig S: Glucocorticoids, metabolism and metabolic diseases. *Mol Cell Endocrinol* 2007;275:43–61.
- 13 Targher G, Bertolini L, Rodella S, Zoppini G, Zenari L, Falezza G: Associations between liver histology and cortisol secretion in subjects with nonalcoholic fatty liver disease. *Clin Endocrinol* 2006;64:337–341.
- 14 Nanki T, Koike R, Miyasaka N: Subacute severe steatohepatitis during prednisolone therapy for systemic lupus erythematosus. *Am J Gastroenterol* 1999;94:3379.
- 15 Lemke U, Kronen-Herzig A, Berriel Diaz M, Narvekar P, Ziegler A, Vegiopoulos A, Cato AC, Bohl S, Klingmuller U, Sreaton RA, Muller-Decker K, Kersten S, Herzig S: The glucocorticoid receptor controls hepatic dyslipidemia through Hes1. *Cell Metab* 2008;8:212–223.