

## Stage IV Wilms Tumor Treated by Korean Medicine, Hyperthermia and Thymosin- $\alpha_1$ : A Case Report

Donghyun Lee<sup>a</sup> Sung Su Kim<sup>a</sup> Shin Seong<sup>a</sup> Wonjun Cho<sup>b</sup>  
Hyejin Yu<sup>b</sup>

<sup>a</sup>Soram Hospital of Korean Medicine, and <sup>b</sup>Soram Bio-Research Institute, Seoul, Republic of Korea

### Key Words

Wilms tumor · Korean medicine therapy · Hangamdan S · Soramdan S · Spiam HC · Hyperthermia · Thymosin- $\alpha_1$

### Abstract

**Introduction:** Wilms tumor is one of general solid cancers that occur in children, which carries a death rate of 7–8 in a million. The cure rate of Wilms tumor in the recent 30 years has dramatically been improved, but a proper remedy is still not prepared enough in terms of application in tumor therapy upon recurrence after radiotherapy, surgery and chemotherapy. We present an integrative medical remedy – hyperthermia and thymosin- $\alpha_1$  treatment focused on herbal remedy – since there have been cases in which this remedy contributed to remission in the liver-transferred part in the 4th phase of Wilms tumor and stable maintenance of metastatic lung lesion. **Case Presentation:** Our patient, a female Korean mongoloid outpatient, was treated from October 25, 2014, to July 22, 2015. The herbal remedy consisted of 8 ml inhalation of Soram nebulizer solution q.d., Soramdan S 8 g p.o., Hangamdan S 1 g p.o., t.i.d., Cheongjangtang 10–30 ml, and Spiam HC 8 g p.o. The integrative medical therapy was done with hyperthermia therapy (oncothermia) and 1.6 mg of thymosin- $\alpha_1$  treatment (Zadaxin) i.m. According to the CT result on July 15th, 2015, the liver metastasis was not seen anymore, while the lung metastasis was maintained stably without tumor progress. **Conclusions:** Accompanying integrative medical therapy with herbal remedy in the treatment of Wilms tumor showing progress patterns after surgery and chemotherapy can be meaningful as a new remedy.

© 2016 The Author(s)  
Published by S. Karger AG, Basel

## Introduction

Wilms tumor is also called nephroblastoma and is one of general solid tumors occurring in children, with a death rate of 7–8 in a million population [1]. The cure rate of Wilms tumor has improved dramatically in the past 30 years owing to a remedy combining radiotherapy, drug therapy, and surgery. The 5-year event-free survival and overall survival reach 77.2 and 87.5%, respectively, according to a recent report [2]. Nonetheless, there are no other proper remedies apart from radiotherapy and chemotherapy as ways to cure Wilms tumor in case of tumor progress.

Thus, our intention was to report the case where a metastatic lung tumor was maintained stably, while the metastatic part of the liver was in remission after a complementary hyperthermia therapy (oncothermia) and thymosin- $\alpha_1$  (TA1) treatment (Zadaxin) together with a herbal remedy. This therapy was implemented after the patient's refusal to undergo chemotherapy following recurrence of Wilms tumor. The tumor was initially treated with chemotherapy, surgery and radiotherapy but recurred despite re-surgery and additional anticancer chemotherapy.

## Case Presentation

The patient was a 17-year-old mongoloid Korean girl who had been diagnosed with Wilms tumor in another hospital. The tumor was found due to left kidney rupture in May 2012. After the diagnosis, left radical nephrectomy, actinomycin D, radiotherapy and vincristine + doxorubicin + actinomycin D chemotherapy were applied for 5 months in the hospital. However, a multiple wedge resection was done in the LUL and LLL parts since multiple metastasis occurred in the lung in June 2014. Then, vincristine + ifosfamide + carboplatin + etoposide were applied (table 1). However, in October 2014, a PET-CT scan revealed a newly developed metastatic tumor in the right hepatic lobe. Possibly, seeding tumors in the medial margin of the spleen and a fissure in the ligamentum venosum newly developed as well.

The patient was recommended to have anticancer chemotherapy again by the hospital but she rejected it, and instead, she started a herbal treatment as an outpatient in the same hospital. The patient received 8 ml inhalation of Soram nebulizer solution, Soramdan S, HAD S, Cheongjangtang therapy, Spiam HC, oncothermia thermotherapy, and Zadaxin injection 2–3 times a week for 9 months (table 2). As a result, the chest showed consistency in the overall stable disease status of metastatic nodules in the right lung and LUL, and the metastatic part of the liver showed remission while constantly improving as seen on the CT scans of November 8th 2014, January 7th 2015, April 8th 2015, and July 15th 2015 (table 3; fig. 1).

## Discussion

Accompaniment of surgery, radiotherapy, and anticancer chemotherapy can be helpful in increasing the survival rate long term in Wilms tumor, but it often leads to severe complications in adulthood [3]. Therefore, decreasing the treatment burden and improving patient outcome are still required [4]. Application of a herbal remedy, hyperthermia therapy (oncothermia), and TA1 treatment (Zadaxin) in Wilms tumor patients who visited the hospital showed a meaningful therapeutic effect with a stable maintenance of metastatic lung lesions and remission in the metastatic part of the liver.

Methods of herbal remedies are inhalation of Soram nebulizer solution, oral herbal medicine, and rectal injection. Inhalation of Soram nebulizer solution is a method that fumigates the liquid extracted from the steam of herbs and injects it into the nasal cavity. The oriental oral medicine and Cheongjangtang were made in the form of a pill, steam liquid, and capsule made of single or multiple herbs in a pharmacy, so that they could be absorbed by the patient's body through rectal injection or simple oral administration. Soram nebulizer solution is made from wild ginseng and *Cordyceps sinensis*. 200 g of roughly 6-year-old wild *Panax ginseng* is washed under running water, decocted in 2,000 ml distilled water, and the decoction is distilled to produce 1,500 ml of fluid. 200 g of *C. sinensis* is washed under running water, decocted in 2,000 ml distilled water, and the decoction is distilled to produce 1,500 ml of fluid. The two fluids are mixed at a ratio of 1:1, filtered with 0.45- and 0.2- $\mu\text{m}$  filters, and then sterilized in 8-ml vials. Each nebulizer therapy was done with this solution and an ultrasonic nebulizer (OMRON, NE-U17) for 20 min. Soramdan S was what was mixed with wild ginseng at a temperature above 120°C and finely ground *P. ginseng*, which is processed at high pressure, at a 7:3 ratio, then mixed well with the same amount of mixed honey and with mixed power mixed at a 2:1:1:2 ratio into 8-gram pills, wrapped in gold foil. HAD S was made from *Cordyceps militaris*, *P. ginseng* radix, *Commiphora myrrha*, calculus bovis, margarita, processed *Boswellia carteri*, processed *Panax notoginseng* radix, and processed *Crematstra appendiculata* tuber at a ratio of 3:2:2:2:2:2:4:4. These were ground and put into 500-mg capsules. Spiam HC was made from *P. ginseng*, *Salvia miltiorrhiza*, *Sanguisorba officinalis*, and *Artemisia capillaris* Thunberg with honey at a 1:1 ratio; then, it was made into a pill, wrapped in gold foil. For Cheongjangtang, the rhizome of *P. ginseng* was removed, cleaned well, and processed for 3 h at 120°C through autoclave. 600 mg of the processed *P. ginseng* was cleaned again, decocted with 6 liters of sterilized distilled water to obtain 5 liters of decoction liquid. This was diluted with sterilized distilled water, adjusting salinity to 0.9%.

*P. ginseng* is the representative herb with antitumor effect. It is processed at high temperature and pressure, and is included in the Soram nebulizer solution, Soramdan S, Spiam HC, and Cheongjangtang that were administered to our patient. It has been shown that treatment of cancer cells in vivo and in vitro with Rg3 results in the reduction of proliferation, metastasis, and mortality [5–7]. Upon processing ginseng with heat at 120°C, most peaks of ginsenosides Rb1, Rb2, Rc, and Rd disappeared and the presence of less polar ginsenosides 20(S,R)-Rg3, Rk1, and Rg5 was newly detected [8]. Lee et al. [9] reported about recurrence control and metastasis decrease in lymph nodes in patients with metastatic breast cancer as well as decrease in the metastatic part of the lung of patients with metastatic bladder infection after ingestion of HAD S and administration of Soram nebulizer solution. Spiam HC is composed of *P. ginseng*, *S. miltiorrhiza*, *S. officinalis*, and *A. capillaris* Thunberg. *S. miltiorrhiza* contains przewaquinone C, which is known to have anticancer activity. Fractions of *S. miltiorrhiza* were reported to have excellent anticancer effects in in vitro and in vivo experiments [10]. The hydrothermal extract of *S. officinalis* has antiproliferative effects and apoptotic activity in HSC4 and HN22 human oral cancer cells; moreover, a water-soluble polysaccharide extracted from the root of *S. officinalis* L is reported to increase immunity as well as inhibit tumor cells [11]. Feng et al. [12] reported about the potential antiproliferative effect of water-soluble polysaccharide fraction extracted from *A. capillaris* Thunberg on human nasopharyngeal carcinoma.

A great number of studies show that hyperthermia inhibits angiogenesis, enhances chemo- and radiosensitivity, and induces a high concentration of drugs within a tumor [13]. Oncothermia is a local-regional hyperthermia treatment for oncological applications.

Zadaxin is a pure, synthetic preparation of thymalfasin (TA1), an amino-terminal acetylated peptide of 28 amino acids which circulates in the blood naturally and is instrumental in

the host's immune response to fight cancer. Zadaxin stimulates anticancer natural killer cells [14]. It directly inhibits the in vitro growth of certain cancer cells [15].

As our case study shows, the integrative medical therapy consisting of oriental medicine, oncothermia, and Zadaxin contributed to metastatic part remission and inhibition of Wilms tumor progress after unsuccessful surgery and chemotherapy. This case report is meaningful as it demonstrates that oriental medicine combined with oncothermia and Zadaxin has a therapeutic effect on tumors and it can complement radiotherapy or anticancer chemotherapy. Caution should be exercised when making conclusions on the effect of oriental medicine, oncothermia, and Zadaxin therapy on Wilms tumor based on just this report. More clinical research is warranted to provide evidence for the validity of this complementary treatment.

### Conclusion

Our patient was diagnosed with Wilms tumor and was treated with chemotherapy and radiation. However, the PET-CT test revealed that a metastatic tumor in the right hepatic lobe newly developed. The patient visited the hospital to receive Korean medicine, which was composed of inhalation of the Soram nebulizer solution, oral herbal medicine and rectal injection. She also received hyperthermia therapy and TA1 treatment at the same time. According to the results of the simultaneous treatments, the patient's state showed stable maintenance of the metastatic lung lesion and remission in the metastatic part of the liver.

### Statement of Ethics

The authors have no ethical conflicts to disclose.

### Disclosure Statement

The authors have no conflicts of interest to declare.

### References

- 1 Israels T, Moreira C, Scanlan T, Molyneux L, Kampondeni S, Hesselting P, et al: SIOP PODC: clinical guidelines for the management of children with Wilms tumour in a low income setting. *Pediatr Blood Cancer* 2013;60:5–11.
- 2 Pritchard-Jones K, Moroz V, Vujanic G, Powis M, Walker J, Messahel B, et al: Treatment and outcome of Wilms' tumour patients: an analysis of all cases registered in the UKW3 trial. *Ann Oncol* 2012;23:2457–2463.
- 3 Davenport KP, Blanco FC, Sandler AD: Pediatric malignancies: neuroblastoma, Wilm's tumor, hepatoblastoma, rhabdomyosarcoma, and sacrococcygeal teratoma. *Surg Clin North Am* 2012;92:745–767.
- 4 Tao YF, Lu J, Du XJ, Sun LC, Zhao X, Peng L, et al: Survivin selective inhibitor YM155 induce apoptosis in SK-NEP-1 Wilms tumor cells. *BMC Cancer* 2012;12:619.
- 5 Fishbein AB, Wang CZ, Li XL, et al: Asian ginseng enhances the anti-proliferative effect of 5-fluorouracil on human colorectal cancer: comparison between white and red ginseng. *Arch Pharm Res* 2009;32:505–513.
- 6 Wang CZ, Aung HH, Zhang B, et al: Chemopreventive effects of heat-processed *Panax quinquefolius* root on human breast cancer cells. *Anticancer Res* 2008;28:2545–2551.
- 7 Xu TM, Cui MH, Xin Y, et al: Inhibitory effect of ginsenoside Rg3 on ovarian cancer metastasis. *Chin Med J* 2008;121:1394–1397.

Lee et al.: Stage IV Wilms Tumor Treated by Korean Medicine, Hyperthermia and Thymosin- $\alpha_1$ : A Case Report

- 8 Chen J, Peng H, Ou-Yang X, et al: Research on the antitumor effect of ginsenoside Rg3 in B16 melanoma cells. *Melanoma Res* 2008;18:322–329.
- 9 Lee DH, Seong S, Kim SS, Woo CR, Han JB: A case of lung metastatic bladder cancer treated by Korean medicine therapy alone. *Case Rep Oncol* 2014;7:534–540.
- 10 Yang BJ, Huang XL, Zhou QR: The structures of four minor diterpene quinones przewaquinones C, D, E and F from the root of *Salvia przewalskii* Maxim var *mandarinorum* (Diels) Stib. *Acta Pharmaceutica Sinica* 1984;19:294–298.
- 11 Shin JA, Kim JS, Kwon KH, Nam JS, Jung JY, Cho NP, Cho SD: Apoptosis effect of hot water extract of *Sanguisorba officinalis* L. in human oral cancer cell. *Oncol Lett* 2012;4:489–494.
- 12 Feng GF, Wang XQ, You CX, Cheng XH, Han ZL, Zong L, Zhou CY, Zhang MK: Antiproliferative potential of *Artemisia capillaris* polysaccharide against human nasopharyngeal carcinoma cells. *Carbohydr Polym* 2013;92:1040–1045.
- 13 Sumiyoshi K, Strebel FR, Rowe RW, Bull JM: The effect of whole-body hyperthermia combined with ‘metronomic’ chemotherapy on rat mammary adenocarcinoma metastases. *Int J Hyperthermia* 2003;19:103–118.
- 14 Rasi G, Silecchia G, Sinibaldi-Vallebona P: Anti-tumor effect of combined treatment with thymosin alpha 1 and interleukin-2 after 5-fluorouracil in liver metastases from colorectal cancer in rats. *Int J Cancer* 1994;57:701–705.
- 15 Moody TW, Fagarasan M, Zia F, Cesnjaj M, Goldstein AL: Thymosin alpha 1 down-regulates the growth of human non-small cell lung cancer cells in vitro and in vivo. *Cancer Res* 1993;53:5214–5218.

**Table 1.** Treatment progress before implementation of integrative medicine

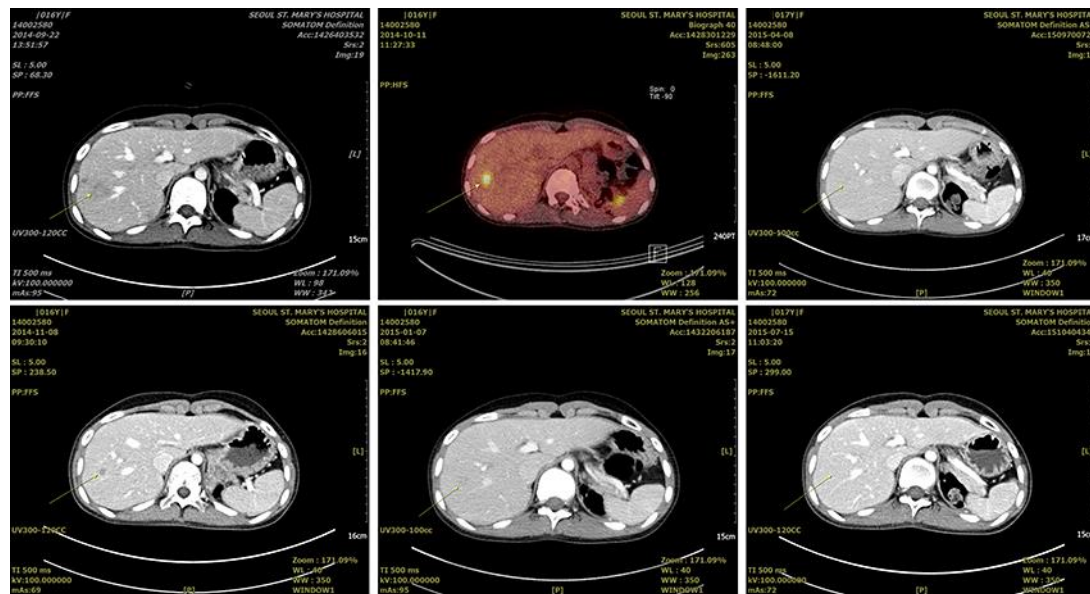
Date	Treatment
11.5.2012	Left radical nephrectomy
22.5.2012	Actinomycin D #1
24.5.2012–9.6.2014	RTx #12
28.9.2012–6.11.2012	Vincristine + doxorubicin + actinomycin D #14
13.6.2014	Wedge resection LUL, LLL
3.7.2014–3.9.2014	Vincristine + ifosfamide + carboplatin + etoposide #3
10.9.2014	Vincristine #1

**Table 2.** Prescriptions from October 25, 2014, to July 22, 2015

Order	Prescription	Frequency
1st prescription (‘14.10.25~11.19)	Soram nebulizer solution 8 ml inhalation q.d. Soramdan S 8 g p.o.	3 times a week 3 times a week
2nd prescription (11.20~11.29)	Soram nebulizer solution 8 ml inhalation q.d. Soramdan S 8 g p.o. Hangamdan S 1 g p.o. t.i.d. Oncothermia therapy	2 times a week 3 times a week daily 2 times a week
3rd prescription (12.2~12.16)	Soram nebulizer solution 8 ml inhalation q.d. Cheongjangtang 30 ml Hangamdan S 1 g p.o. t.i.d. Oncothermia therapy	3 times a week 3 times a week daily 3 times a week
4th prescription (‘14.12.18~‘15.1.22)	Soram nebulizer solution 8 ml inhalation q.d. Spiam HC 8 g p.o. Cheongjangtang 30 ml Hangamdan S 1 g p.o. t.i.d. Oncothermia therapy Zadaxin 1.6 mg i.m.	3 times a week 3 times a week 3 times a week daily 3 times a week 2 times a week
5th prescription (1.24~2.26)	Soram nebulizer solution 8 ml inhalation q.d. Spiam HC 8 g p.o. Cheongjangtang 10 ml Hangamdan S 1 g p.o. t.i.d. Oncothermia therapy Zadaxin 1.6 mg i.m.	2 times a week 2 times a week 2 times a week daily 2 times a week 2 times a week
6th prescription (3.4~4.30)	Soram nebulizer solution 8 ml inhalation q.d. Cheongjangtang 10 ml Hangamdan S 1 g p.o. t.i.d. Oncothermia therapy Zadaxin 1.6 mg i.m.	2 times a week 2 times a week daily 2 times a week 2 times a week
7th prescription (6.3~7.22)	Soram nebulizer solution 8 ml inhalation q.d. Hangamdan S 1 g p.o. t.i.d.	2 times a week daily

**Table 3.** Radiological image reading

Date and method	Image reading
22.9.2014 CT	Interval progression of a multifocal ill-defined low-density lesion in both hemili- CT
11.10.2014 PET-CT	Metastatic tumor in the right hepatic lobe, newly developed Possibly, seeding tumors in the medial margin of the spleen and fissure for liga- mentum venosum, newly developed DDx, chronic cholecystitis
8.11.2014 CT	Overall stable disease status of metastatic nodules in the right lung and LUL Interval regression of a few, ill-defined low-density nodular lesions in left hemili- ver S2, right hemiliver S5/8
7.1.2015 CT	Overall stable disease status of metastatic nodules in the right lung and LUL Partial response of R/O hepatic metastasis in S5/8 of the liver
8.4.2015 CT	Overall stable disease status of metastatic nodules in the right lung and LUL Further decreased extent of R/O hepatic metastasis in S5/8 of the liver
15.7.2015 CT	Overall stable disease status of metastatic nodules in the right lung and LUL No visible liver mass in S5 of the liver



**Fig. 1.** Chest CT scans of the patient.