

Available online at [www.sciencedirect.com](http://www.sciencedirect.com)

ScienceDirect

journal homepage: <http://Elsevier.com/locate/radcr>

## Case Report

## Ruptured superficial femoral artery aneurysm: a case report

Soniya Pinto MD<sup>a,\*</sup>, Mansi Jantre MD<sup>b</sup>, Michael Prendergast MD<sup>c</sup><sup>a</sup> Department of Diagnostic Radiology, St. Vincent's Hospital, 123 Summer St, Worcester, MA 01608, USA<sup>b</sup> Department of Neuroradiology, Seth GS Medical College & KEM Hospital, Mumbai, Maharashtra 400012, India<sup>c</sup> Department of General Surgery, Presence St. Francis Hospital, Evanston, IL, USA

## ARTICLE INFO

## Article history:

Received 19 December 2016

Accepted 22 January 2017

Available online 24 February 2017

## ABSTRACT

A 96-year-old male presented with left lower extremity pain, swelling, and vascular compromise. Computed tomographic angiography revealed an actively rupturing distal superficial femoral artery aneurysm. The patient underwent prompt aneurysm excision with graft interposition and had a successful postoperative outcome. Our case illustrates the critical role of imaging in establishing a definitive diagnosis and preventing mortality. © 2017 the Authors. Published by Elsevier Inc. under copyright license from the University of Washington. This is an open access article under the CC BY-NC-ND license (<http://creativecommons.org/licenses/by-nc-nd/4.0/>).

## Introduction

Superficial femoral artery aneurysms are rare clinical disorders with most literature on the subject consisting of case reports and series [1–5]. The largest retrospective series of 27 cases by Perini et al. [4] recommended computed tomography angiography (CTA) for diagnostic evaluation. The most commonly performed procedure in this series was an aneurysmectomy with prosthetic graft reconstruction [4]. Our case elegantly illustrates the timely use of CTA, the surgical approach, and postoperative care of a patient with a ruptured superficial femoral artery aneurysm.

## Case report

A 96-year-old male with a past medical history of hypertension, hyperlipidemia, and arthritis presented to the emergency room with 5 days of left lower extremity pain. He was

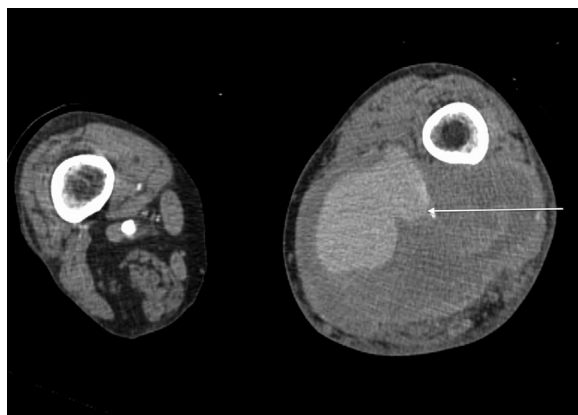
previously ambulatory with a walker. His pertinent medications included a daily low-dose aspirin and atorvastatin.

On examination, his vitals were within normal limits. He had a palpable left femoral pulse and marked left thigh fullness. The foot was cool to the level of the ankle with no palpable or audible pedal pulses. Movements of the ankle and knee were restricted and painful. He had a palpable right femoral and popliteal pulse with audible right pedal pulses. Based on his physical examination and marked anemia, there was clinical concern for a ruptured femoral artery aneurysm. He underwent a CTA of the left lower extremity, which revealed a 15 × 10 cm mass in the posteromedial thigh at the junction of the superficial femoral and popliteal arteries with active contrast extravasation (Fig. 1). The distal vessels could not be evaluated due to insufficient contrast beyond this region (Fig. 2). These findings indicated an actively rupturing aneurysm that warranted immediate surgical intervention.

At the time of surgery, the superficial femoral artery was controlled proximal to the aneurysm. The aneurysm

\* Corresponding author.

E-mail address: [soniapinto173@gmail.com](mailto:soniapinto173@gmail.com) (S. Pinto).  
<http://dx.doi.org/10.1016/j.radcr.2017.01.020>1930-0433/© 2017 the Authors. Published by Elsevier Inc. under copyright license from the University of Washington. This is an open access article under the CC BY-NC-ND license (<http://creativecommons.org/licenses/by-nc-nd/4.0/>).



**Fig. 1 – CTA showing active contrast extravasation in the left posteromedial thigh at the junction of the superficial femoral and popliteal arteries (arrow). CTA, computed tomography angiography.**

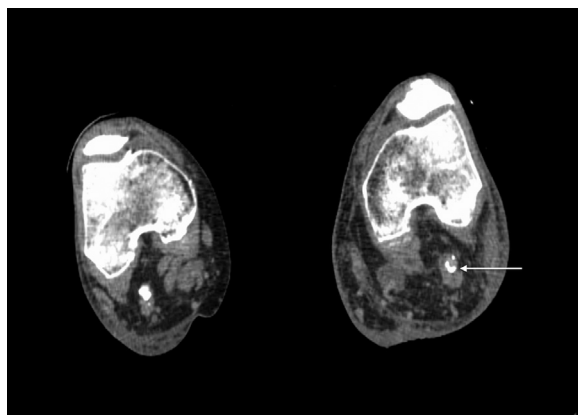
cavity was entered, and a large amount of laminated thrombus was removed. The distal popliteal artery beyond the ruptured aneurysm was controlled with a balloon catheter.

At this point, a distal angiogram was shot to assess the runoff vessels. The popliteal artery was patent down to the trifurcation, and all 3 runoff vessels were visualized in the proximal leg (Fig. 3). However, there was significant chronic disease involving all 3 vessels in the mid to distal leg.

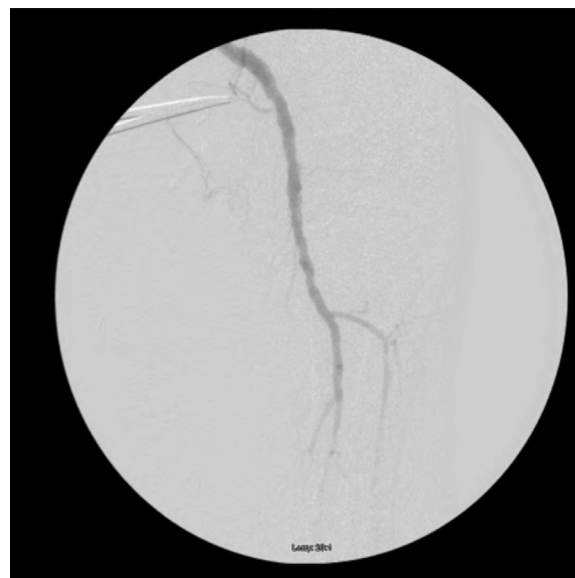A 7-mm ringed synthetic graft was used. Completion angiogram showed a widely patent anastomosis and outflow into the popliteal artery and the 3 runoff vessels. The foot filled via collaterals.

At the end of the procedure, the patient had audible signals in the anterior and posterior tibial arteries.

On postoperative day 1, he was successfully extubated. On postoperative day 2, he was transferred to the surgical floor and he ambulated with assistance. On postoperative day 4, he was discharged to a subacute rehab facility. On follow-up a month later, he was ambulating with minimal support.



**Fig. 2 – CTA showing lack of contrast in the left calcified popliteal artery distal to the ruptured aneurysm (arrow). CTA, computed tomography angiography.**



**Fig. 3 – Intraoperative angiography showing a patent popliteal artery up to the level of the trifurcation with chronic disease in the runoff vessels.**

## Discussion

Superficial femoral artery aneurysms comprise approximately 15% of all femoral artery aneurysms [1–4]. By definition, these aneurysms are greater than twice the normal arterial diameter (7.2 mm in males and 6.2 mm in females) [6]. Due to the deep anatomic location of the artery, they are apparent only when very large (>8 cm) and symptomatic, as illustrated by the above case [1]. A review of 27 symptomatic cases over a 12-year period by Perini et al. [4] noted that the disease predominated in males with a mean age of 78 years. Leon et al. [1] and Bonelli et al. reported that superficial femoral artery aneurysms are most often located in the middle third of the artery with rare extension into Hunter's canal. Several reviewers, including Leon et al. [1], Perini et al. [4], and Atallah et al. [7], reported rupture as the most frequent mode of presentation with an occurrence rate of 30%–50% [6]. Other less common presentations include thrombosis with distal ischemia (13%–19%) and distal embolization (9%–14%) [7]. In addition, Diethrich and Papazoglou [8] noted a strong association of superficial femoral artery aneurysms with abdominal aortic aneurysms (30%–40%). The case above illustrates the most common presentation of a ruptured superficial femoral artery aneurysm in a patient with a high-risk demographic profile. However, the unusual location of the aneurysm and lack of additional peripheral vascular disease are unique features of this case and stress the importance of a high clinical index of suspicion.

Dighe and Thomas [3] noted that CTA is the most commonly employed diagnostic study, which can determine the size and location of the aneurysm and aid in operative planning. Other modalities including B mode ultrasound and magnetic resonance imaging (MRI) have been used with varying accuracy [3]. It is often difficult to differentiate a

partially thrombosed aneurysm from soft tissue tumors with ultrasound and MRI [3]. Current sectional properties of MRI with sensitivity to motion have enabled differentiation of the two only when there is partial flow across a thrombosed aneurysm [5]. Conventional angiogram is of limited utility, as it often cannot differentiate an arterial occlusion from a thrombosed aneurysmal dilatation [5,9]. It also poses a significant contrast risk to elderly, frail patients [2].

Our case stresses the importance of appropriate imaging selection and recognition of findings to prevent a delay in surgical treatment.

Surgical treatment methods of symptomatic superficial femoral artery aneurysms include aneurysmal excision with graft interposition, aneurysm exclusion with bypass, and ligation of the aneurysm sac [1,4,10]. Ligation is, however, not an option for ruptured aneurysms [1,4].

An early report by Cutler et al. reported 5 cases of symptomatic femoral artery aneurysms: 1 was ligated, 3 were treated with long vein bypass grafts, and 1 with a short vein bypass graft [10]. The only long-term success was the short vein graft replacement in their series [10].

By contrast, a review of 27 symptomatic cases by Perini et al. reported aneurysmal excision with prosthetic graft reconstruction in 16, aneurysm exclusion with bypass in 7, ligation in 3, and primary amputation in 1 case. This review reported survival rates of up to 88% at 6 months and 62% at 5 years following all 3 types of surgical repair [4]. Graft patency rates of 90% at 6 months and 85% at 5 years were reported [4]. Secondary amputation rates were relatively low [7%] and were either secondary to the lack of adequate distal targets for revascularization or postoperative graft thrombosis [4].

Another series of 11 cases by Jarrett et al. [2] employed aneurysmal excision with prosthetic graft material in 8 patients and with autologous saphenous vein in 3 patients. Autologous saphenous vein was the conduit of choice in patients with distal atherosclerotic disease requiring below knee femoropopliteal bypasses [2]. They reported a 100% survival rate in both groups [2].

In the case above, we opted for aneurysmal excision and interposition with a 7-mm ringed prosthetic graft. The convenient size match of the graft with the native vessel and the above knee femoropopliteal anastomosis dictated this decision. Our patient made a favorable functional recovery, and graft patency was maintained at 1-month follow-up.

Given the rarity of this disease, there is currently no evidence-based cutoff for surgical repair of asymptomatic superficial femoral artery aneurysms. However, the general consensus is that an aneurysm greater than 2.5 cm in diameter should be repaired [1]. Atallah et al. [7] reported that

saccular aneurysms should be operated on once diagnosed, in accordance with the treatment of saccular aneurysms elsewhere. Smaller asymptomatic true aneurysms, particularly in high-risk patients, can be serially followed with CTA, with intervention reserved for cases where symptoms develop or the lesion enlarges by more than two times [1].

## Conclusion

In the above case, we highlighted the stepwise approach to clinical evaluation, diagnosis, and management of a rare but potentially fatal entity. Our case report is unique in its lack of association with prior symptomatic peripheral vascular disease and other peripheral aneurysms. Our report is a valuable addition to radiologic and surgical literature in terms of guiding clinical management and improving outcomes.

## REFERENCES

- [1] Leon LR, Taylor Z, Psalms SB, Mills JL. Degenerative aneurysms of the superficial femoral artery. *Eur J Vasc Endovasc Surg* 2008;35(3):332–40.
- [2] Jarrett F, Makaroun MS, Rhee RY, Bertges DJ. Superficial femoral artery aneurysms: an unusual entity? *J Vasc Surg* 2002;36(3):571–4.
- [3] Dighe S, Thomas P. Ruptured superficial femoral artery aneurysm treated by simple ligation. *Singapore Med J* 2008;49(6):e151–2.
- [4] Perini P, Jean-Baptiste E, Vezzosi M, Raynier JL, Mottini F, Batt M, et al. Surgical management of isolated superficial femoral artery degenerative aneurysms. *J Vasc Surg* 2014;59(1):152–8.
- [5] Ormstad K, Solheim K. Ruptured aneurysm of the superficial femoral artery. *Scand J Thorac Cardiovasc Surg* 1975;9(3):181–2.
- [6] Hardy DG, Eadie DG. Femoral aneurysms. *Br J Surg* 1972;59(8):614–6.
- [7] Atallah C, Al Hassan HK, Neglén P. Superficial femoral artery aneurysm—an uncommon site of aneurysm formation. *Eur J Vasc Endovasc Surg* 1995;10(4):502–4.
- [8] Diethrich EB, Papazoglou K. Endoluminal grafting for aneurysmal and occlusive disease in the superficial femoral artery: early experience. *J Endovasc Ther* 1995;2(3):225–39.
- [9] Wolf YG, Kobzantsev Z, Zelmanovich L. Size of normal and aneurysmal popliteal arteries: a duplex ultrasound study. *J Vasc Surg* 2006;43(3):488–92.
- [10] Cutler BS, Darling RC. Surgical management of arteriosclerotic femoral aneurysms. *Surgery* 1973;74(5):764–73.