



Contents lists available at [ScienceDirect](https://www.sciencedirect.com)

AAACE Clinical Case Reports

journal homepage: www.aaaceclinicalcasereports.com



Case Report

Pycnodysostosis: A Growth Hormone Responsive Skeletal Dysplasia

Hafsa Omer Sulaiman, BBiomedSc, MBBS¹,
Nandu Kumar Sidramappa Thalange, MBBS, BSc, FRCPCH^{2,*}

¹ St. George's University of London, London, UK

² Department of Endocrinology, Al Jalila Children's Hospital, Dubai, UAE

ARTICLE INFO

Article history:

Received 19 November 2020

Received in revised form

21 February 2021

Accepted 23 February 2021

Available online 4 March 2021

Key words:

pycnodysostosis

pituitary hypoplasia

growth hormone deficiency

ABSTRACT

Objective: Pycnodysostosis is commonly associated with growth hormone (GH) deficiency and responds well to GH therapy with achievement of normal or near-normal height and restoration of body proportions.

Case Report: A 22-month-old extremely short (−4.05 height standard deviation score) disproportionate boy with skeletal dysplasia presented to clinic. Skeletal survey, genetic panel, magnetic resonance imaging, and an insulin-like growth factor generation tests were performed.

Results: Skeletal survey showed increased bone density with classic features of pycnodysostosis, subsequently confirmed to be due to a deleterious homozygous frameshift mutation in *CTSK*. Uniquely among skeletal dysplasias, GH deficiency is a common association, secondary to pituitary hypoplasia. Magnetic resonance imaging confirmed pituitary hypoplasia and he subsequently underwent an insulin-like growth factor generation test that demonstrated biochemical responsiveness to GH therapy. This was thought to be safer than a classic GH stimulation test, in view of his very small size. Subsequently, his height has markedly improved on GH therapy. His height is now −2.25 SD, with an annualized growth velocity of 9.65 cm/y over a period of 18 months.

Conclusion: It is important to consider GH therapy in children with pycnodysostosis, with the greatest benefit seen in children started at a young age.

© 2021 AAACE. Published by Elsevier Inc. This is an open access article under the CC BY-NC-ND license (<http://creativecommons.org/licenses/by-nc-nd/4.0/>).

Introduction

Pycnodysostosis, also known as “Toulouse-Lautrec syndrome,” is named from the Greek for dense, defective bones. It is a rare autosomal recessive disorder, with a prevalence of 1 in 1.7 million people worldwide. It was first described by Maroteaux and Lamy¹ in 1962. The renowned 19th-century French artist Henri de Toulouse-Lautrec is thought to have had this condition. It is caused by mutations in *CTSK*, which encodes the enzyme cathepsin K, a member of the cysteine protease family, and results in a lysosomal storage disorder.¹ Pycnodysostosis presents with severe, disproportionate short stature, frequent fractures with increasing age, and widespread skeletal abnormalities causing craniosynostosis,

respiratory-sleep disorders, and dental problems.² In contrast to other skeletal dysplasias, hypopituitarism with growth hormone (GH) deficiency is common, and GH treatment is effective in restoring height and body proportions.^{2,3} We describe the case of a boy with pycnodysostosis, treated with GH, who has achieved a remarkable improvement in height.

Case Report

“J” was a 22-month-old boy, born at term to first-cousin parents following an uncomplicated pregnancy and normal delivery. His birth weight was 3.12 kg but he required neonatal intensive care for 5 days due to meconium aspiration and jaundice requiring phototherapy. He had failure to thrive, which resolved with supplemental feeding, though his growth in length remained consistently poor. His developmental milestones were otherwise normal.

His parents attended the endocrinology clinic because they noticed that he was much shorter than his 14-month-old cousin. His supine length was 74.5 cm (<0.01th percentile, −4.05 height standard deviation score [SDS]) and weight was 10.44 kg (14th

Abbreviations: GH, growth hormone; IGF-1, insulin-like growth factor-1; IGFBP-3, insulin-like growth factor binding protein-3; MRI, magnetic resonance imaging.

* Address correspondence and reprint requests to Dr Nandu Kumar Sidramappa Thalange, Department of Endocrinology, Al Jalila Children's Hospital, PO Box 7662, Dubai, UAE.

E-mail address: nandu.thalange@ajch.ae (N.K.S. Thalange).

<https://doi.org/10.1016/j.aaace.2021.02.006>

2376-0605/© 2021 AAACE. Published by Elsevier Inc. This is an open access article under the CC BY-NC-ND license (<http://creativecommons.org/licenses/by-nc-nd/4.0/>).

percentile, -1.06 SDS) (Fig. 1). He was notably disproportionate, with a relatively large head, gaping fontanelle, marked lumbar lordosis, and short limbs. A clinical diagnosis of skeletal dysplasia was made. Skeletal survey showed increased bone density with skeletal abnormalities, including Wormian bones, widening of the parieto-occipital sutures, frontal bossing and obtuse angle of the mandible, but normal teeth (Fig. 2A). In the limbs, acro-osteolysis of the small bones of the fingers and toes was seen, with short, stubby metacarpals and shortening of the long bones (Fig. 2B and C), which are diagnostic of pycnodysostosis. Confirmatory genetic testing showed a previously reported deleterious homozygous frameshift mutation in exon 4 of *CTSK* [c.338delG].

Pycnodysostosis is characterized by GH deficiency.^{2,3} He therefore underwent pituitary magnetic resonance imaging (MRI), which showed pituitary hypoplasia (Fig. 3). Baseline insulin-like growth factor-1 (IGF-1) and IGF binding protein-3 (IGFBP-3) were in the low normal range and considered consistent with partial GH deficiency. An IGF generation test (GH $1 \mu\text{g}/\text{kg}/\text{d}$ for 4 days with IGF-1 and IGFBP-3 measurements at baseline and on day 5) demonstrated GH responsiveness in IGF-1 and IGFBP-3 (Table), although the response was modest. We did not perform a GH provocation test as it was felt unnecessary, given the underlying diagnosis of pycnodysostosis (known to be GH-responsive) and MRI findings, coupled with his very small size (10.44 kg), which would have made the test very onerous for him. Accordingly, we embarked on a therapeutic trial of GH ($1 \mu\text{g}/\text{kg}/\text{d}$; 0.5 mg). Initially, after starting GH, parents reported limb pains and increased fatigue, but these settled within a few weeks. Otherwise, we observed no adverse effects of therapy. Vitamin D and thyroid function were normal. After the initial period of rapid catch-up growth, growth has slowed somewhat.

After 18 months, his height has improved to -2.25 SDS (1.24th percentile) (Fig. 4). His most recent IGF-1 in July 2020 was $141.6 \mu\text{g}/\text{L}$ (normal range 18.9–116.0; $+3.06$ SDS) on a dose of $1 \mu\text{g}/\text{kg}/\text{d}$ (0.6

mg), indicating a better IGF response to GH than initially seen with his IGF generation test. His bone age was congruent with his chronological age (Greulich & Pyle bone age 3.42 years at chronological age 3.5 years) (Fig. 5), indicating his growth has not been at the expense of advanced bone age. Written consent was obtained from the parents for the case report.

Discussion

We report successful GH treatment of pycnodysostosis in a 22-month-old boy. He has showed a remarkable improvement with GH therapy, having gained $+1.80$ standard deviations in height over 18 months of GH therapy. Pycnodysostosis commonly presents with severe short stature, and untreated, a limited final height of 130 to 150 cm, with worse growth seen in girls.² The authors note that girls typically have low birth weight and length (<3 rd percentile) and worse height prognosis with or without treatment (final height SDS -4.1 vs -2.9 in males).

Increased bone density, characteristic changes in the skull, and acro-osteolysis are pathognomonic of the condition. Some other features that were shared by our patient and the cohort study by Bizaoui et al² were Wormian bones (18%), open fontanel (81%), frontal bossing (84%), and lumbar lordosis or other spinal deformity (8%). Our patient has normal psychomotor development, but a significant proportion of cases have developmental delay (5 of 17 cases in a recent report).²

Other features that are common in children with pycnodysostosis but not yet seen in our patient due to his young age are frequent pathologic fractures and tooth abnormalities, which typically manifest after 10 to 11 years of age.² The differential diagnosis list includes cleidocranial dysostosis, osteogenesis imperfecta, and osteopetrosis,⁴ and confirmatory genetic testing is recommended.²

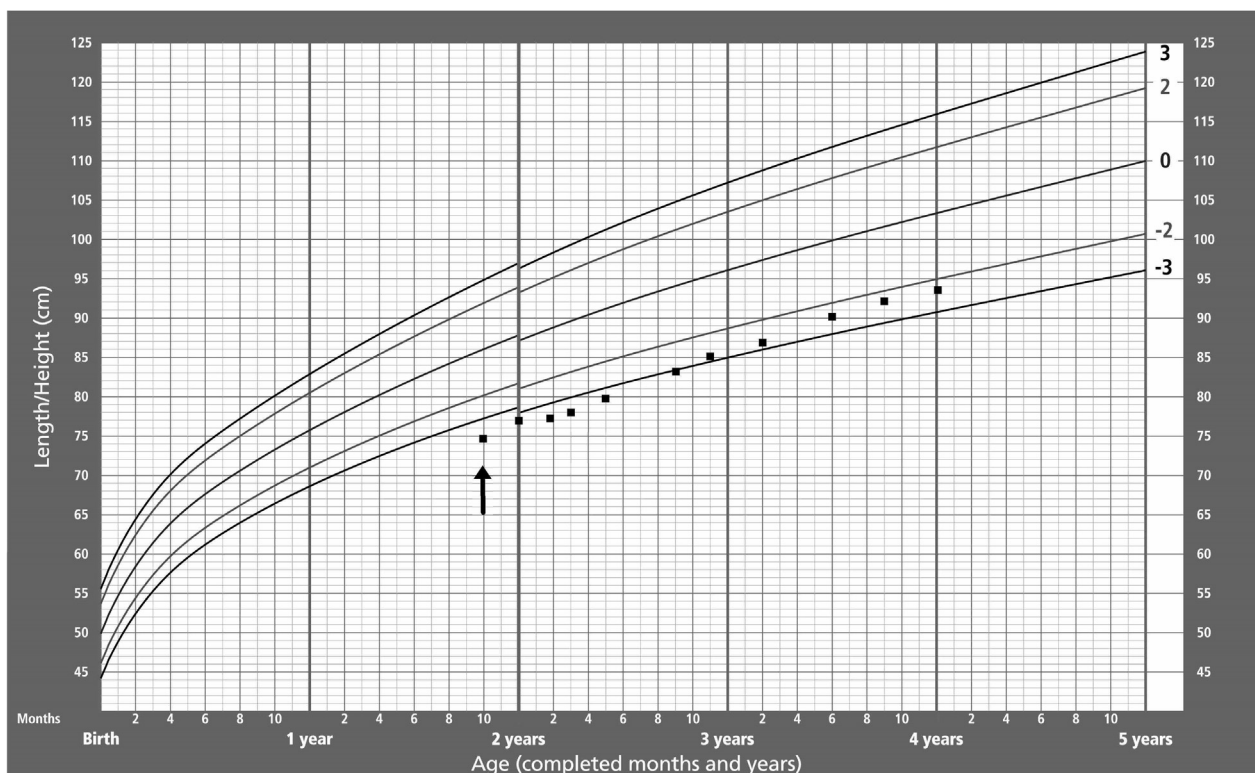


Fig. 1. Patient growth curve arrow indicates when he presented to clinic -4.05 SDS, aged 2.83 years. SDS = standard deviation score.

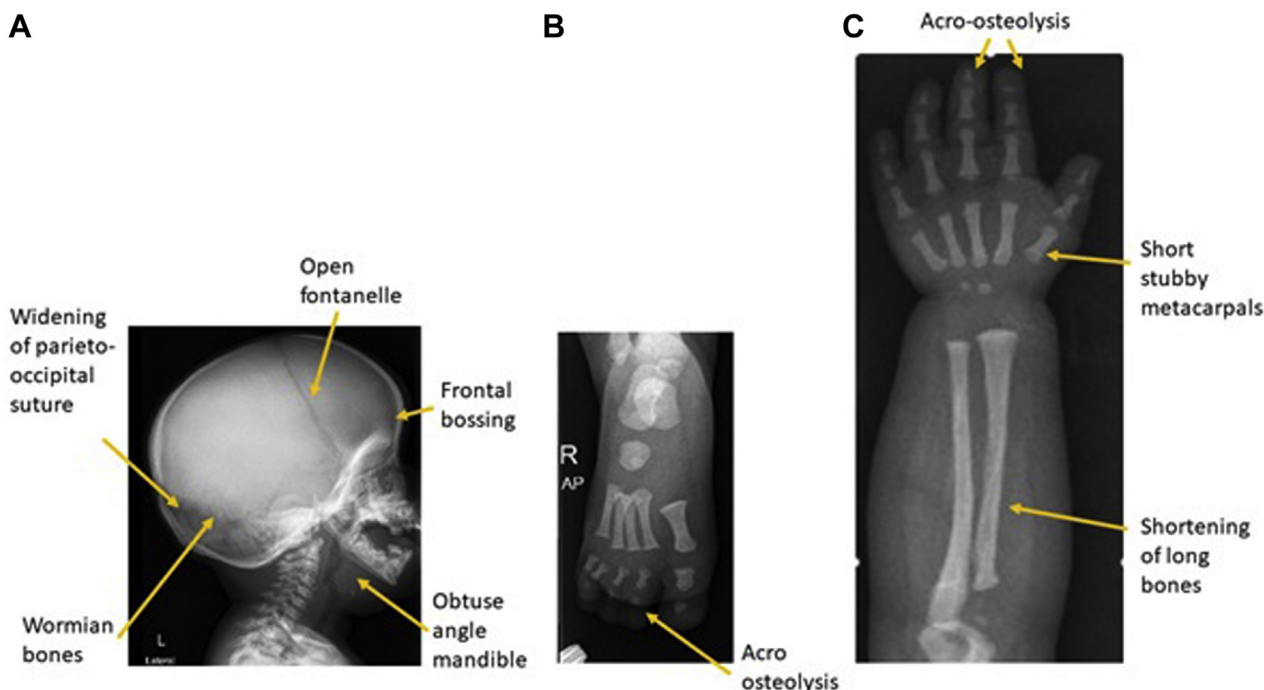


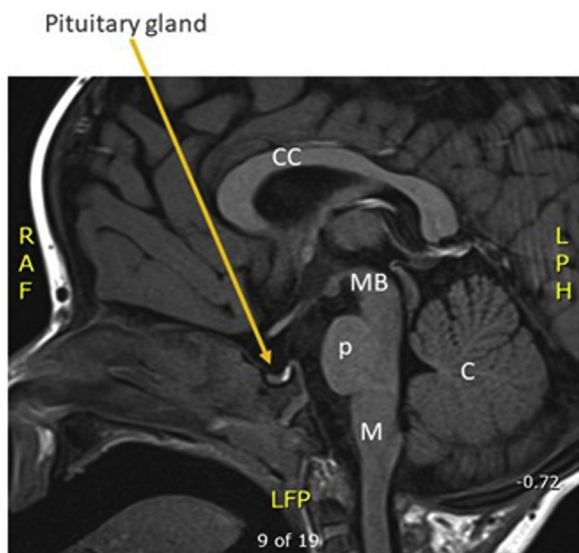
Fig. 2. Patient skeletal survey showing characteristic features of pycnodysostosis: mild diffuse increased density of all the bones: skull x-ray (A) shows the widening of parieto-occipital sutures with open posterior and anterior fontanelles and frontal bossing of the skull; Wormian bones are noted in parieto-occipital and mastoid sutures; relatively small mandible with obtuse angle; iliac bones are broad with widened acetabular roofs; long bones show increased density but with preserved corticomедullary differentiation; mild symmetrical shortening of the long bones; acro-osteolysis of second and third digits of hands (B) with similar findings seen in both feet involving the digits with tufting of the great toe. (C) Short stubby metacarpals are seen.

Pycnodysostosis is caused by a homozygous mutation in *CTSK*, which encodes the enzyme cathepsin K, a lysosomal cysteine protease, highly expressed in osteoclasts. Cathepsin K breaks down

bone matrix proteins, type I and II collagen, osteopontin, and osteonectin,⁵ and is also required for degradation of tooth enamel matrix.² Osteoclasts of patients with pycnodysostosis mobilize bone mineral but cannot degrade collagen. Affected subjects with homozygous *CTSK* mutations show variability in the reduction in osteoclast activity, leading to heavy, brittle, poorly organized bone,⁶ with more severe genotypes appearing at a younger age.² Deletion of exon 4, as identified in our patient, was shown to completely abrogate protein expression in a previously described case.²

Uniquely, among skeletal dysplasias, pycnodysostosis is associated with GH deficiency. It is conjectured that the increased bone density in the skull hinders development of the pituitary gland,⁷ resulting in pituitary hypoplasia and GH deficiency.⁸

Effects of early and late GH therapy were studied in growth hormone deficient rats for 4 weeks. Craniofacial development was markedly improved in juvenile rats, but no benefit in terms of craniofacial growth was seen during puberty. GH administration has a positive impact on linear growth and body disproportion in children with pycnodysostosis.^{2,3} These effects may in part be due to GH-mediated effects on osteoclast differentiation and activity.⁹



Key:
 CC - Corpus Callosum P - pons C - cerebellum
 MB - midbrain M - medulla

Fig. 3. Magnetic resonance imaging scan of the sagittal view of the brain showing striking pituitary hypoplasia, a recognized finding in pycnodysostosis.

Table
 Pre- and Post-GH IGF-1 and IGFBP-3 Following Four Days of Physiologic Doses of Growth Hormone (1µg/m²/day)

Laboratory Investigations	Day 1	Day 5	Response
Insulin-like growth factor-1 [µg/L] SDS]	50 [-1.56	71	+ 42%
Insulin-like growth factor binding protein-3 [µg/L] SDS]	1661 [-1.70	2073	+ 25%

SDS = standard deviation score.

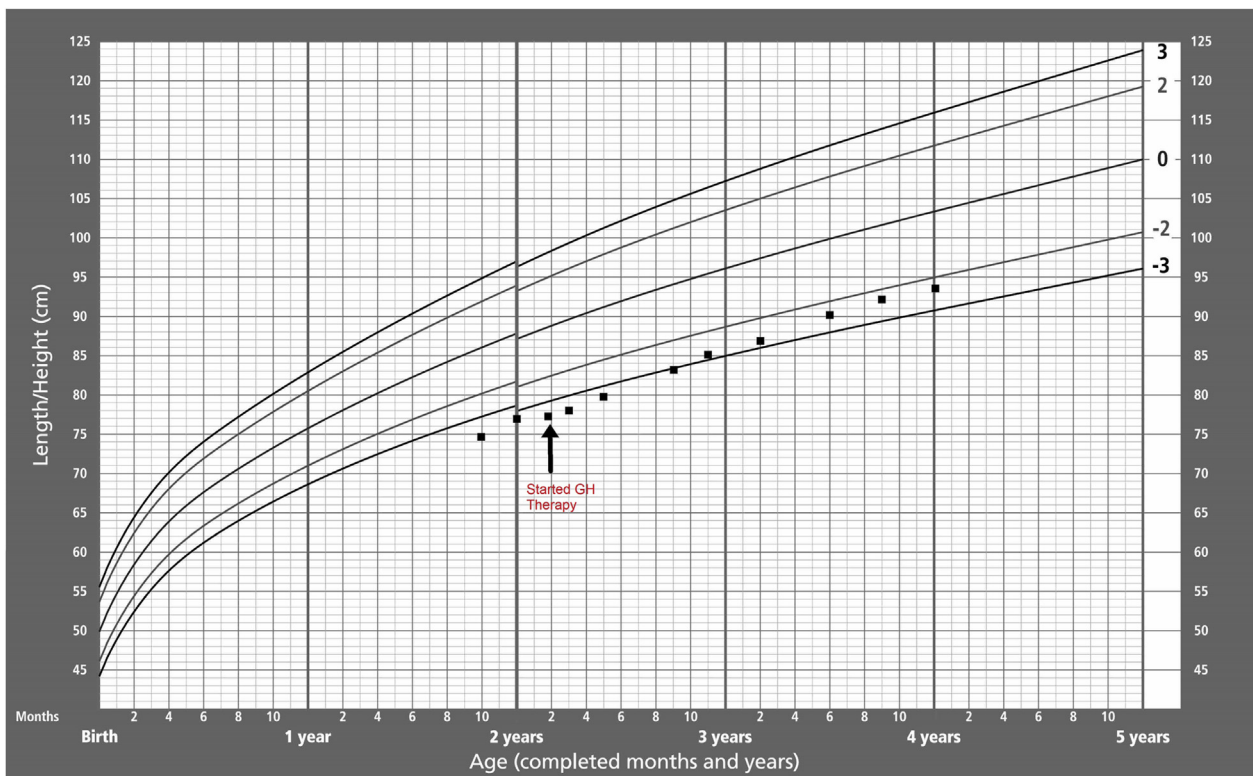


Fig. 4. Patient growth curve after growth hormone therapy showing an increase in height from -4.05 SDS to -2.25 SDS at his last review, aged 3.5 years. SDS = standard deviation score.

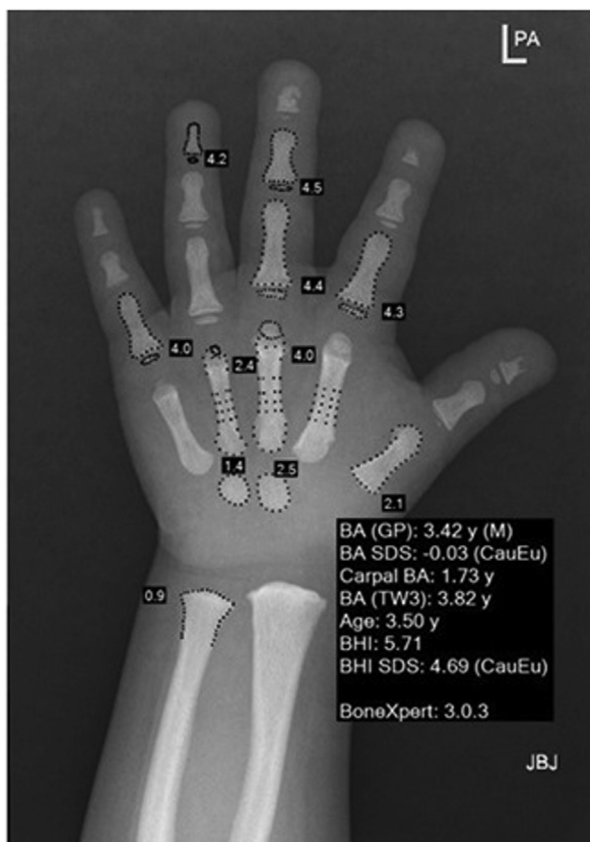


Fig. 5. Bone age x-ray at the age of 3.5 years showing congruent bone age (Greulich & Pyle bone age 3.42 years, -0.03 SDS) and very dense osteosclerotic bones with acroosteolysis affecting the third and fourth terminal phalanges, characteristic of pycnodysostosis. SDS = standard deviation score.

Some children achieve normal or near-normal stature following GH treatment.¹⁰ When the diagnosis is not made in a timely way and GH treatment instituted, final height is extremely poor—particularly in females. Schmidt et al¹¹ recently described such a case in an adult female who reached a final height of only 128 cm. Therefore, in patients with pycnodysostosis it is important to consider GH therapy as early as possible. Early use of GH is associated with attainment of normal or near-normal adult height^{2,10}; however, it is not possible to generalize the height benefit of GH treatment as not all children respond, particularly if treated late. A recently reported Danish study¹² found that 5 of 6 treated children attained a final height >150 cm. There are no reports of ongoing GH replacement for adults with pycnodysostosis.

Having confirmed the diagnosis of pycnodysostosis with documented pituitary hypoplasia on MRI (Fig. 3), we elected not to proceed to a formal GH provocation test, as this would be very onerous in such a small child and likely would not change our management. Instead, we preferred to do an IGF generation test (Table), which showed a rise of 42% and 25% in IGF-1 and IGFBP-3 respectively, consistent with physiologic responsiveness to GH. When last evaluated, in July 2020, IGF-1 was supraphysiological ($+3.06$ SDS), indicating a more impressive biochemical response with long-term therapy.

The patient experienced no notable adverse effects of GH treatment, and there are no reports of adverse events from GH therapy in children with pycnodysostosis.

After 18 months of GH therapy, the patient’s height had risen to a near-normal -2.25 SDS, indicating an excellent response to GH treatment. GH therapy appears to substantially restore long-bone growth, thereby correcting the skeletal disproportion,^{2,10} with the greatest benefit seen with early initiation of therapy, as in our case.

In children treated at a younger age, substantial craniofacial catch-up growth is reported and is particularly noticeable around

the mandible and posterior cranial base.^{12,13} Cantu et al¹² reported that craniofacial growth with GH therapy is maximal in the first 2 years of life, indicating that earlier treatment is beneficial. Some complications of patients with pycnodysostosis, such as sleep apnea, are believed to arise from the craniofacial defects, notably grooved palate and mid-lower facial hypoplasia,¹⁴ which are typically GH-responsive.

In summary, as illustrated by our case, pycnodysostosis stands in contrast to other skeletal dysplasias in being associated with pituitary hypoplasia and GH deficiency. GH treatment is effective in restoration of normal or near-normal height and body proportions and improves craniofacial abnormalities, thus potentially reducing other comorbidities such as sleep apnea. The diagnosis of pycnodysostosis is now regarded as an indication for GH therapy,^{2,10,15} and available evidence points to early use of GH being of key importance to achieving good outcomes.

Acknowledgment

The author (Hafsa Omer Sulaiman) thanks Dr Nandu Thalange for believing in them and giving them learning opportunities and their family for always having their back no matter where life takes them.

Disclosure

The authors have no multiplicity of interest to disclose.

References

1. Maroteaux P, Lamy M. The malady of Toulouse-Lautrec. *JAMA*. 1965;191(9):715–717.
2. Bizaoui V, Michot C, Baujat G, et al. Pycnodysostosis: natural history and management guidelines from 27 French cases and a literature review. *Clin Genet*. 2019;96(4):309–316.
3. Soliman AT, Ramadan MA, Sherif A, Bedair E-SMA, Rizk MM. Pycnodysostosis: clinical, radiologic, and endocrine evaluation and linear growth after growth hormone therapy. *Metabolism*. 2001;50(8):905–911.
4. Barnard B, Hiddema W. Pycnodysostosis with the focus on clinical and radiographic findings. *SA J Radiol*. 2012;16(2):74–76.
5. Bossard MJ, Tomaszek TA, Thompson SK, et al. Proteolytic activity of human osteoclast cathepsin K. Expression, purification, activation, and substrate identification. *J Biol Chem*. 1996;271(21):12517–12524.
6. Chavassieux P, Asser Karsdal M, Segovia-Silvestre T, et al. Mechanisms of the anabolic effects of teriparatide on bone: insight from the treatment of a patient with pycnodysostosis. *J Bone Miner Res*. 2008;23(7):1076–1083.
7. Gowen M, Lazner F, Dodds R, et al. Cathepsin K knockout mice develop osteopetrosis due to a deficit in matrix degradation but not demineralization. *J Bone Miner Res*. 1999;14(10):1654–1663.
8. Murray RA, Maheshwari HG, Russell EJ, Baumann G. Pituitary hypoplasia in patients with a mutation in the growth hormone-releasing hormone receptor gene. *AJNR Am J Neuroradiol*. 2000;21(4):685–689.
9. Nishiyama K, Sugimoto T, Kaji H, Kanatani M, Kobayashi T, Chihara K. Stimulatory effect of growth hormone on bone resorption and osteoclast differentiation. *Endocrinology*. 1996;137(1):35–41.
10. Rothenbühler A, Piquard C, Gueorguieva I, Lahlou N, Linglart As, Bougneres P. Near normalization of adult height and body proportions by growth hormone in pycnodysostosis. *J Clin Endocrinol Metab*. 2010;95(6):2827–2831.
11. Schmidt GS, Schacht JP, Knee TS, Shakir MKM, Hoang TD. Pycnodysostosis (osteopetrosis acro-osteolytica). *AAE Clin Case Rep*. 2020;6(5):e257–e261.
12. Cantu G, Buschang PH, Gonzalez JL. Differential growth and maturation in idiopathic growth-hormone-deficient children. *Eur J Orthod*. 1997;19(2):131–139.
13. Kjellberg H, Wikland KA. A longitudinal study of craniofacial growth in idiopathic short stature and growth hormone-deficient boys treated with growth hormone. *Eur J Orthod*. 2007;29(3):243–250.
14. Gray ML, Su A, Cruciata G, Som PM. Pycnodysostosis in an adult: a case report and review of the literature. *Ear Nose Throat J*. 2019;98(10):627–628.
15. Doherty MA, Langdahl BL, Denmark IV, Haagerup A. Clinical and genetic evaluation of Danish patients with pycnodysostosis. *Eur J Med Genet*. 2021;64(2):104135.