

# A Review of the Current State and Future Directions for Management of Scalp and Facial Vascular Malformations

Emma Hartman,<sup>1</sup> Daniel M. Balkin,<sup>2</sup> Alfred Pokmeng See<sup>1</sup>

*Department of Neurosurgery,<sup>1</sup> Boston Children's Hospital, Harvard Medical School, Boston, MA, USA*

*Department of Plastic & Oral Surgery,<sup>2</sup> Boston Children's Hospital, Harvard Medical School, Boston, MA, USA*

Vascular malformations are structural abnormalities that are thought to result from errors in vasculogenesis and angiogenesis during embryogenesis. Vascular malformations of the scalp present unique management challenges due to aesthetic and functional implications. This review examines the pathophysiology, clinical presentation, and management techniques for six common types of vascular malformations of the face and scalp : infantile hemangioma, capillary malformations, venous malformations, lymphatic malformations, arteriovenous malformations, and arteriovenous fistulas. These lesions range from common to rare, and have very different natural histories and management paradigms. There has been increasing understanding of the molecular pathways that are altered in association with these vascular lesions and these molecular targets may represent novel strategies of treating lesions that have historically been approached from a structural perspective only.

**Key Words :** Vascular malformation · Capillary hemangioma · Arteriovenous malformation · Lymphatic abnormalities.

## INTRODUCTION

Vascular malformations are structural abnormalities that are thought to result from errors in vasculogenesis and angiogenesis during embryogenesis<sup>9)</sup>. Vascular malformations of the scalp present unique management challenges due to aesthetic and functional implications. This review examines the pathophysiology, clinical presentation, and management techniques for six common types of vascular malformations.

Infantile hemangioma is the most common type of vascular malformation in infants. It is a benign tumor composed of rapidly proliferating blood vessels. Infantile hemangiomas typically appear shortly after birth or in the first few months

of life and grow rapidly during the first year. They often involute and shrink over time without treatment. The exact incidence and prevalence of infantile hemangioma are disputed<sup>24)</sup>. Recent research suggests that between 400 to 500 in 10000 newborns are affected by infantile hemangiomas<sup>27)</sup>. Sixty percent of infantile hemangiomas are located in the head or neck region<sup>23)</sup>. Infantile hemangiomas occur more frequently in infants who are Caucasian, female, premature, products of multiple gestation, or had placental abnormalities or low birth weights or older mothers<sup>2,6,20)</sup>. Transcervical chorionic villus sampling during pregnancy is postulated to associate with infantile hemangioma<sup>21)</sup>.

Capillary malformations are flat, pink to red birthmarks

• Received : February 6, 2024 • Revised : April 6, 2024 • Accepted : April 16, 2024

• Address for correspondence : **Alfred Pokmeng See**

Department of Neurosurgery, Boston Children's Hospital, Harvard Medical School, 300 Longwood Ave., Hunnewell 237, Boston, MA 02115, USA  
Tel : +1-617-919-1379, Fax : +1-617-730-7636, E-mail : Pokmeng.See@Childrens.harvard.edu, ORCID : <https://orcid.org/0000-0003-3634-4692>

This is an Open Access article distributed under the terms of the Creative Commons Attribution Non-Commercial License (<http://creativecommons.org/licenses/by-nc/4.0>) which permits unrestricted non-commercial use, distribution, and reproduction in any medium, provided the original work is properly cited.

that occur due to an abnormal development of tiny blood vessels near the surface of the skin. Port-wine stains (PWSs) are a specific type of capillary malformation characterized by a deep red or purple color. These birthmarks persist throughout life and may darken or thicken over time. Approximately 30 to 50 in 10000 newborns present with capillary malformations<sup>29</sup>. Capillary malformations affect 25 million people worldwide and 70–80% of people with capillary malformations have them on their head or neck. Capillary malformations affect males and females equally but without particular ethnic or racial predisposition<sup>29,30</sup>.

Venous malformations involve abnormally developed veins. They appear as soft, bluish masses that can enlarge over time. The growth may be associated with trauma, treatments, or changes in hormones during adolescence. Venous malformations can affect the skin, subcutaneous tissues, or deeper structures. They are often compressible and may become painful or tender in association with thrombosis. Venous malformations have an incidence of 1 to 2 in 10000 newborns and a prevalence of 1.5%<sup>11,46</sup>. No demographic predisposition for venous malformations has been identified.

Lymphatic malformations result from abnormal development of lymphatic vessels. They can present as fluid-filled cystic masses or soft, compressible swellings. They typically do not involve any discoloration, differentiating them from the other malformations. Lymphatic malformations are typically present at birth or become apparent during early childhood. They can cause cosmetic concerns and, depending on the size and location, may lead to functional impairments. Their incidence is approximated to be 2.5 to 5 in 10000 newborns<sup>38</sup>. Approximately 75% of the lesions are located in the head and neck region<sup>52</sup>. No ethnic or gender group is at higher risk<sup>7</sup>.

Arteriovenous malformations (AVMs) involve a tangle of abnormal blood vessels connecting arteries and veins. Although AVMs can occur in various parts of the body, they can also affect the scalp. Scalp AVMs may present as pulsatile masses with a bruit (audible sound) and may lead to symptoms such as headaches, bleeding, or neurologic deficits. Asymptomatic deeper AVMs often go unnoticed, making it difficult to estimate prevalence and incidence rates. Recent studies suggest that 10 in 10000 Americans have a symptomatic AVM, although the actual prevalence rate is much higher due to clinically undetected AVMs<sup>1</sup>. Only 12% of AVMs are

expected to become symptomatic<sup>1</sup>. Scalp AVMs account for 8.1% of all AVMs<sup>47</sup>. There is no gender disparity in incidence or clinical course of AVMs<sup>1</sup>.

Arteriovenous fistulas (AVFs) are abnormal connections between arteries and veins without the intervening capillary network. They can occur in the scalp and cause a pulsatile mass. AVF may be congenital or acquired due to trauma or surgery. There is a lack of reliable data on AVF occurrence rates<sup>41</sup>.

## GENETICS AND PATHOGENESIS

A number of vascular malformations have underlying genetic mechanisms, but these variants are not found in every patient (Table 1).

The exact pathogenesis of infantile hemangioma is unknown<sup>17</sup>. A common theory is that they arise from dysregulated differentiation of embryonic cells during vasculogenesis, even though hemangiomas are absent at birth<sup>15</sup>. According to one proposed mechanism, vascular endothelial growth factor receptor-1 (VEGFR1) expression is reduced in the endothelial cells of hemangioma patients due to reduced activity of the beta1 integrin pathway<sup>22</sup>. This results in the upregulation of VEGFR2 and its downstream pathways, which promotes endothelial migration and proliferation, resulting in hemangioma formation<sup>22,48</sup>. Missense mutations in genes encoding VEGFR and tetraspanin-enriched microdomains 8 (TEM8) were also found to inhibit integrin activity, interfering with normal cell signaling and resulting in abnormal growth. Other implicated pathways include placental insufficiency or preeclampsia activating hypoxia signaling, with increased hypoxia-inducible factor 1- $\alpha$  (HIF1 $\alpha$ ), insulin-like growth factor 2 (IGF-2), and glucose transporter 1 (GLUT-1), which also signals downstream VEGF-A<sup>40</sup>. Approximately 80% of infantile hemangioma patients have solitary lesions while the other 20% have multifocal disease<sup>13</sup>.

Scalp capillary malformations are known to result from irregular increases in blood flow to the scalp, but their exact pathogenesis is unclear. There are two major hypotheses as to the pathogenesis of capillary malformations – nerve denervation or genetic mutation. While capillary malformations has been associated with denervation in multiple studies, a causal connection has not been established<sup>35</sup>. Recent research has

largely focused on the upregulation of mitogen-activated protein kinase (MAPK) and phosphoinositide-3-kinase protein kinase B (PI3K-AKT) signaling, which induce angiogenesis, as a potential cause of capillary malformations. This theory has been supported by the discovery of somatic Ras GTPase-activating protein 1 (RASA1) and guanine nucleotide-binding protein (GNAQ) mutations in capillary malformations, which are thought to activate MAPK and PI3K pathways<sup>35</sup>. These pathways increase proliferation of precursor endothelial cells, pericytes, and fibroblasts<sup>44</sup>. The undifferentiated vasculature may develop recurrent bleeding of nodules and darken over time. Association with Sturge-Weber syndrome may be observed with particular trigeminal nerve distribution involvement by hemangioma, brain cortical atrophy and manifestation of seizures or developmental delay. They may follow the patterns of the trigeminal nerve when manifesting on the face, differentiating them from venous malformations. It may also be observed in a constellation with venous and lymphatic malformations in Klippel-Trenaunay syndrome, or with AVMs in capillary malformation-arteriovenous malformation syndrome (CM-AVM).

Venous malformations are caused by somatic mutations of *TEK*, which encodes tyrosine kinase receptor tyrosine kinase with immunoglobulin-like and EGF-like domains 2 (TIE2) in endothelial cells<sup>45</sup>. These mutations increase TIE2 autophosphorylation and activate the MAPK pathway, dysregulating

angiogenesis and producing venous malformations<sup>34</sup>. It is unclear why germline mutations cause focal lesions, although there is also thought to require a second hit, which may occur along the phosphatidylinositol-4,5-bisphosphate 3-kinase catalytic subunit alpha (PIK3CA) or AKT pathways. The TIE2 mutation alone may alter spatial chemotaxis of surrounding vascular cells with changes in permeability or vessel structural integrity, while a second hit may induce cell senescence. Altered TIE2 signaling does not appear to induce proliferation; the growth of venous malformations over time is thought to be due to hydrostatic pressure. It may be observed in a constellation with capillary and lymphatic malformations in Klippel-Trenaunay syndrome.

Lymphatic malformations are caused by errors in the development of the lymphatic system during embryonic development. Solitary lymphatic malformations are associated with the PIK3CA and AKT mutations. PIK3CA encodes the p110 $\alpha$  subunit of PI3K and when mutated, activates excessive signaling which induces endothelial cell proliferation and activation of the AKT pathway, which promotes endothelial cell migration during lymphangiogenesis<sup>28</sup>. Additionally, VEGFC/VEGFR3, known to play an integral role in lymphatic malformation growth in mice models, have been shown to be upregulated in lymphatic malformation patients. Half of lymphatic malformations are discovered at birth and 90% of lymphatic malformations manifest within the first 2 years of life<sup>19</sup>.

**Table 1.** Syndromes and genetic mutations associated with each type of vascular malformation

	Syndrome	Genetic Mutation
Infantile hemangioma	Von Hippel-Lindau, Maffucci, PHACE	VEGFR1, VEGFR2, TEM8
Capillary malformation (port-wine stain)	Sturge-Weber, capillary malformation-arteriovenous malformation (CM-AVM) I/II	RASA1, GNAQ, PIK3CA, MAPK
Venous malformation	Blue rubber bleb nevus, PROS	TIE2/TEK, PIK3CA
Lymphatic malformation	CLOVES, Klippel-Trenaunay, proteus, PROS	VEGFR3, PIK3CA, AKT1
Arteriovenous malformation	Parkes-Weber, hereditary hemorrhagic telangiectasia (HHT), Osler-Weber-Rendu (OWR), Wyburn-Mason, Sturge-Weber, CM-AVM I/II, PROS	NOTCH3/4, ACVRL1, ENG, RASA1, KRAS, MAP2K1, BRAF, SMAD4, EPHB4 <sup>35-37</sup>
Arteriovenous fistula	Klippel-Trenaunay-Weber, Cobb	RASA1

PHACE : Posterior fossa malformation, Hemangioma, Arterial anomaly, Coarctation of the aorta/cardiac defect, and Eye abnormality, VEGFR : vascular endothelial growth factor receptor, TEM8 : tetraspanin-enriched microdomains 8, RASA1 : Ras GTPase-activating protein 1, GNAQ : guanine nucleotide-binding protein, PIK3CA : phosphatidylinositol-4,5-bisphosphate 3-kinase catalytic subunit alpha, MAPK : mitogen-activated protein kinase 1, PROS : PIK3CA-related overgrowth spectrum, TIE2 : tyrosine kinase with immunoglobulin-like and EGF-like domains 2, TEK : tyrosine kinase with immunoglobulin-like and EGF-like domains 2, CLOVES : Congenital Lipomatous Overgrowth, Vascular malformations, Epidermal nevis, Spinal/Skeletal anomalies/Scoliosis, AKT1 : protein kinase B, ACVRL1 : activin receptor-like kinase 1, ENG : endoglin, KRAS : Kirsten rat sarcoma virus, MAP2K1 : dual specificity mitogen-activated protein kinase kinase 1, BRAF : serine/threonine-protein kinase B-Raf, SMAD4 : mothers against decapentaplegic homolog 4, EPHB4 : ephrin type-B receptor 4

AVMs usually form before or shortly after birth and grow throughout life. Many pathways have been suggested for AVM formation, but their role in extracranial AVM formation has not been thoroughly investigated. Researchers have linked AVMs with insufficient transforming growth factor-beta due to mutations in signaling genes *SMAD4* and *ENG*<sup>53</sup>. Furthermore, some studies have linked overexpression of genes like *NOTCH 3* and *4*, *ACVRL1*, *EPHB4* and *RASA1* as well as mutations in *MAP2K1*, *KRAS*, and *BRAF* genes to the vasculogenesis of AVMs<sup>35-37</sup>. Most scalp AVMs are supplied by branches from the external carotid artery, such as the superficial temporal artery<sup>47</sup>.

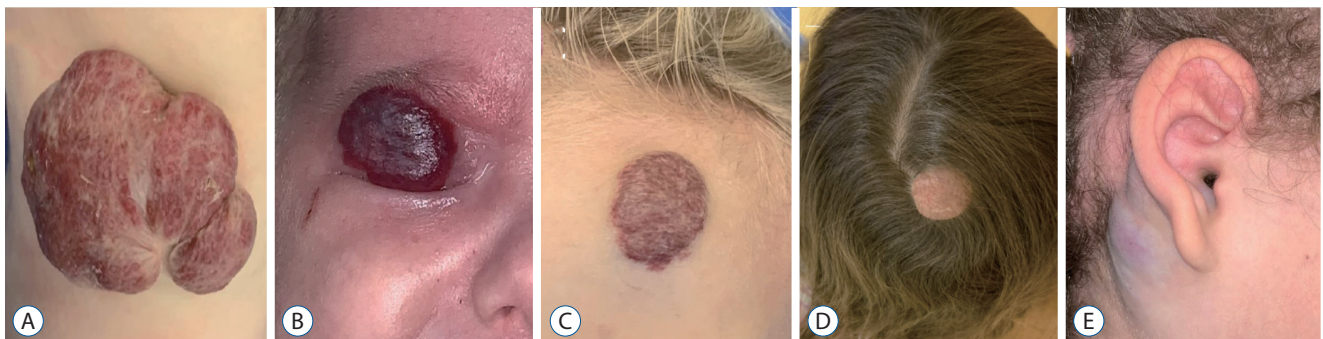
AVFs can be caused by disruption of the arterial wall and its vasa vasorum with endothelial proliferation to adjacent veins<sup>4</sup>. In one series, 90% of scalp AVFs involved the superficial temporal artery and 71% had one dominant feeding superficial temporal artery<sup>51</sup>. Local ischemia and minor trauma

also plays a role in the enlargement of AVFs.

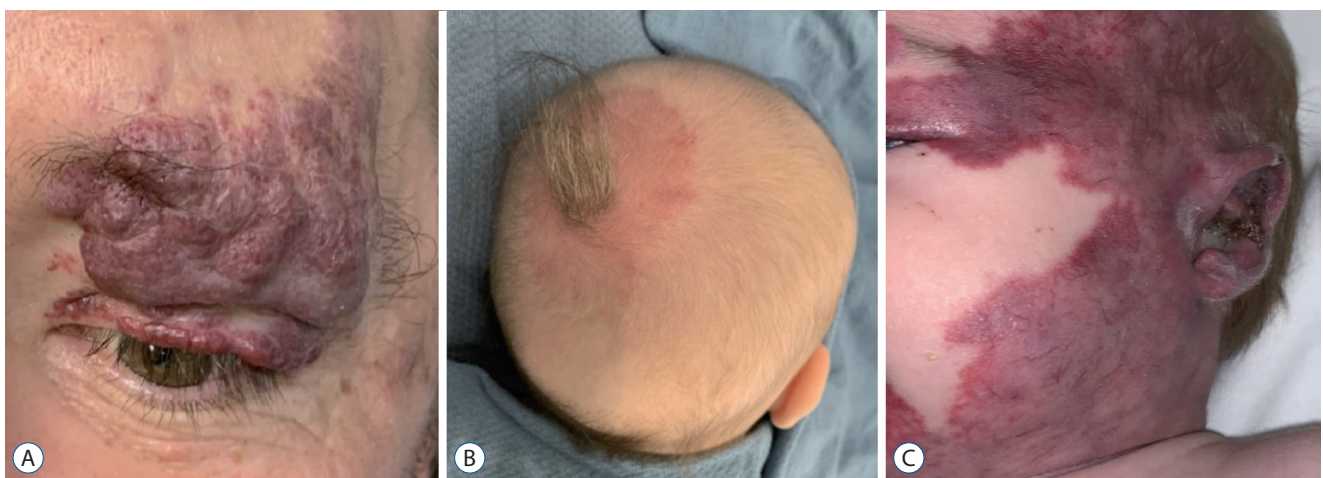## CLINICAL PRESENTATION & DIAGNOSTIC EVALUATION

Many vascular malformations can be diagnosed clinically. Some of these conditions benefit from imaging, which can provide indications for treatment<sup>3</sup>. Ultrasonography, computed tomography (CT), or magnetic resonance imaging (MRI) are non-invasive imaging modalities. They can also be used with contrast (ultrasound, CT, and MRI) or with labeling techniques (MRI) to illustrate flow or vessel structure, such as with CT angiography (CTA) or MR angiography (MRA).

Infantile hemangiomas present at birth. They experience most of their growth in the first few weeks of life, with 80% of superficial growth completed by 3 months of age<sup>27</sup>. Infantile



**Fig. 1.** Infantile hemangioma can vary. A : Involuting infantile hemangioma. B : Proliferating infantile hemangioma. C and D : Involved infantile hemangioma of the forehead (fibrofatty residuum). E : Non-involving congenital hemangioma.



**Fig. 2.** Capillary malformations have varied appearance in (A-C). In (B), it is associated with a heterotopic neural nodule (atretic cephalocele).

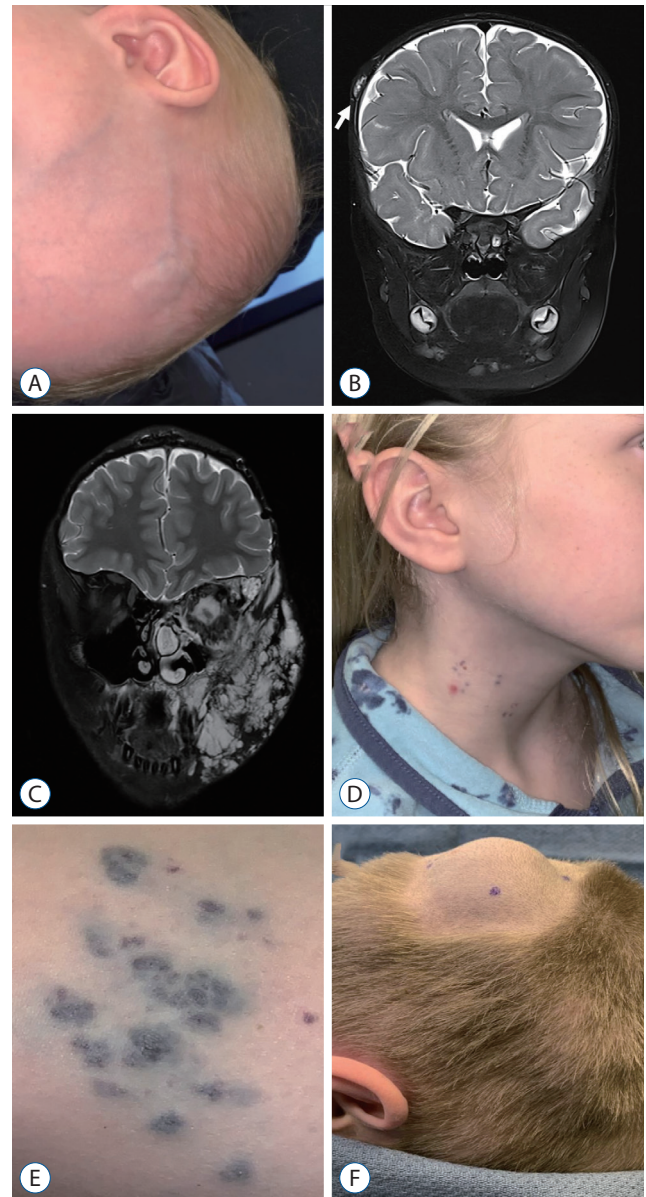
hemangiomas can be diagnosed clinically, but in unclear cases, ultrasonography, CT, or MRI can help (Fig. 1). On ultrasound, they have arterial waveforms and are generally hypochoic, with intervening solid tissue. On MRI, compared to surrounding muscle, they are T1-isointense, T2-hyperintense, and avidly enhancing<sup>31</sup>. Differential diagnoses include congenital hemangioma, which are mature tumors at birth and do not proliferate over the first weeks of life as infantile hemangiomas do, and capillary malformations/PWS, which do not involute over time like infantile hemangiomas<sup>39</sup>. Unfortunately imaging does not effectively differentiate infantile from congenital hemangiomas.

Capillary malformations are congenital and lifelong<sup>35</sup>. Lesions darken progressively, initially presenting as flat red macules in childhood and developing into often-raised purple nodules by middle age due to soft tissue hypertrophy (Fig. 2)<sup>35</sup>. In later years, these vascular nodules may experience spontaneous bleeding or hemorrhage<sup>35</sup>. These can be diagnosed clinically due to their characteristic appearance, although they may be differentially diagnosed as infantile hemangioma. Imaging modalities such as MRI can be helpful in diagnosing associated syndromes such as Sturge-Weber<sup>35</sup>. A key distinction from a malignant vascular lesion, kaposiform hemangioendothelioma may be subcutaneous fat stranding on MRI, which is sometimes described as a sunburst pattern<sup>343</sup>. The majority of facial capillary malformations (approximately 90%) are unilateral in a trigeminal dermatomal distribution<sup>35</sup>.

Venous malformations can be diagnosed clinically<sup>39</sup>. They are often visible at birth and grow over time (Fig. 3). Rapid growth is often spurred by traumatic injury, hormonal changes (pregnancy or puberty), or infection<sup>10,39</sup>. They can form as a sponge-like mass or dilated venous channels. As slow flow lesions, venous malformations often thrombose, forming phleboliths which are easily detected on ultrasound and color Doppler<sup>10</sup>. Dynamic compression can demonstrate compressible venous spongiform tissue. MRI and MRA are useful for defining the extent of the disease, which is important as treatment options are determined based on the extent of the lesion as well as location<sup>10</sup>. On T1-weighting, they are hypointense or isointense; on T2-weighting they are hyperintense; they avidly enhance<sup>37</sup>. Treatment should be reserved for symptomatic or cosmetically disfiguring malformations<sup>36</sup>.

Most lymphatic malformations appear at birth, but are asymptomatic throughout early childhood. Zhou et al.<sup>52</sup> reported

that 50–75% of lymphatic malformations can be diagnosed at birth, with 80–90% of the remaining cases diagnosed by the age of 2 years. Lymphatic malformations can be diagnosed



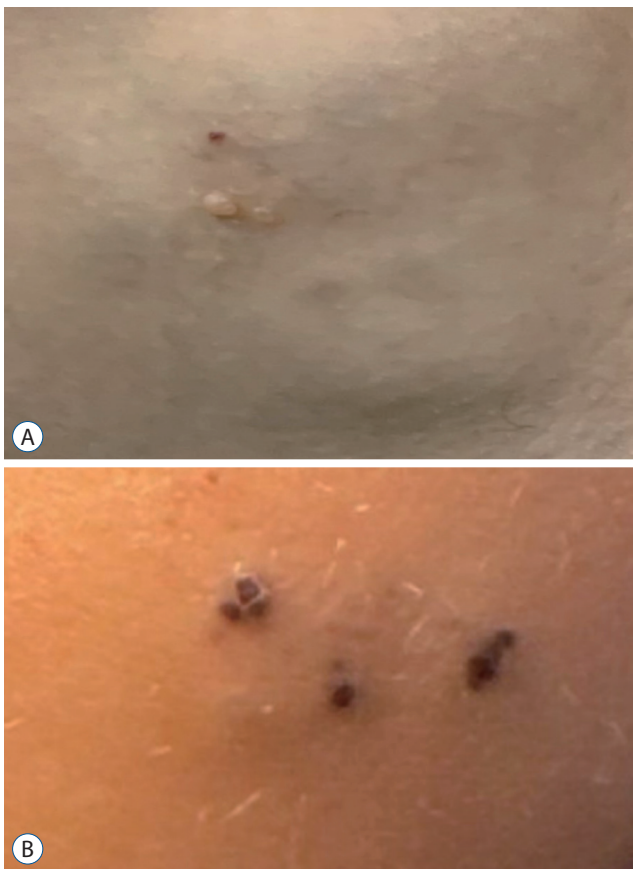
**Fig. 3.** Venous malformation can have varied cutaneous appearance. A : Venous malformation of the right forehead is engorged when patient held in dependent position. The coronal T2 magnetic resonance imaging (MRI) shows hyperintense signal (B, arrow). C : A T2 MRI shows a large venous malformation of the left face and neck with similar T2 hyperintensity over a much larger region. D : A glomovenous malformation is visible on the neck. E : Cutaneous appearance of venous malformation. F : An engorged venous malformation associated with sinus pericranii in this intraoperative view of the occipital region in a patient positioned prone with the hair clipped.

clinically without imaging (Fig. 4). The need for intervention is determined by the emergence of symptoms such as tissue distortion, frequent bleeding, and cellulitis<sup>10</sup>. When imaging is obtained, ultrasound may show macrocystic lymphatic malformations as septated cystic hypoechoic lesions, while MRI may show T1-hypointensity and T2-hyperintensity and potentially intracystic fluid levels<sup>49</sup>. Microcystic lesions may have hyperchoic cysts with T1-hypointensity and T2-hyperintensity.

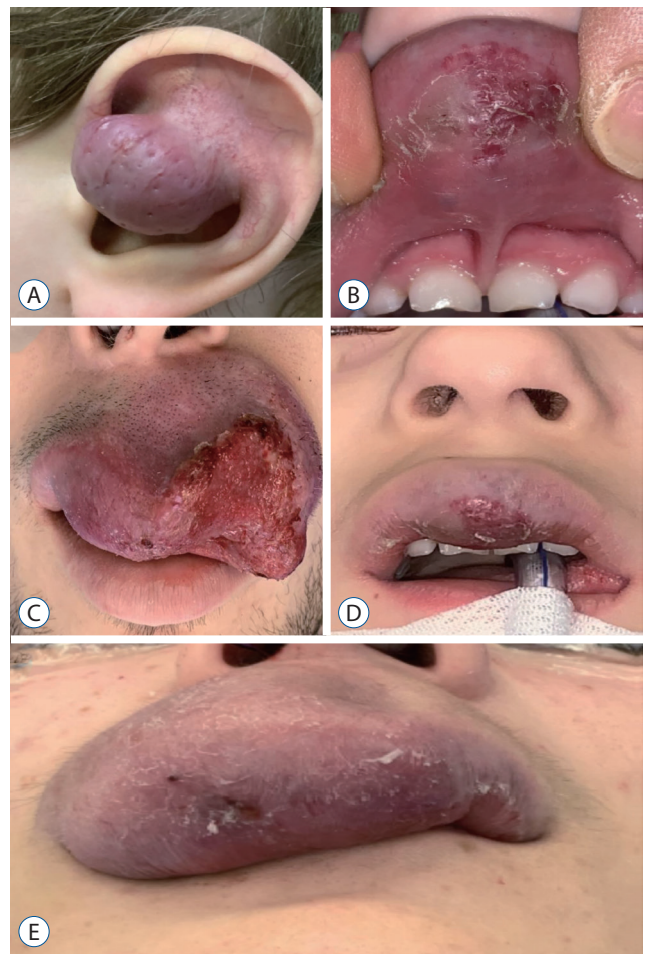
While many AVMs of the scalp are present at birth, most are asymptomatic until adulthood<sup>14</sup>. Asymptomatic AVMs are usually discovered as incidental findings on imaging<sup>14</sup>. AVMs continue to grow in size throughout life. As AVMs grow, they often cause symptoms such as pain, disfigurement, or bleeding. These symptoms typically intensify due to trauma, pregnancy, or hormonal changes (Fig. 5)<sup>14</sup>. History and physical exams can also be used to assess AVM patients for associated syndromes (Table 1)<sup>53</sup>. Ultrasound can show high flow with color Doppler and MRI with MRA can be helpful in distinguishing AVMs from low flow lesions<sup>16,32</sup>. AVMs do

not have intervening soft tissue mass but can cause thickening of the overlying skin. CTA may be another a useful methodology for mapping AVM architecture, but requires high ionizing radiation and entails a higher possibility of anaphylactic reaction to contrast medium in patients<sup>8,16</sup>. Catheter angiography, or digital subtraction angiography is usually performed during planned embolization treatment.

AVFs may be congenital or acquired. Clinical symptoms include pain, throbbing headaches, scalp necrosis and bruits<sup>12</sup>. Most congenital AVFs do not become symptomatic until patients reach mid-adulthood<sup>4</sup>. AVFs are known to experience rapid growth during puberty, menstruation, and pregnancy<sup>12</sup>. The gold standard for diagnosing high flow lesions like AVFs is digital subtraction angiography, although MRI can also provide quick and accurate imaging<sup>33</sup>. The high-flow nature can be severe enough as to lead to high-output cardiac failure.



**Fig. 4.** A and B : Lymphatic malformation with cutaneous vesicles.



**Fig. 5.** Arteriovenous malformation of the ear (A), mucosa of the lip (B), upper lip (C-E).

## MANAGEMENT STRATEGIES

Many of these vascular malformations require a multidisciplinary approach to management. Patients can often benefit from conservative management, intervention, or an adjuvant therapy.

Infantile hemangiomas are usually managed conservatively by interdisciplinary teams consisting of specialists from dermatology, hematology-oncology, and facial plastic and reconstructive surgery, ophthalmology, otolaryngology, and pediatric surgery<sup>25</sup>. In most cases of infantile hemangioma, no intervention is needed and the malformation involutes by 5–7 years of age<sup>23</sup>. Treatment is considered when infantile hemangiomas become life-threatening (by causing cardiac or respiratory distress), functionally-impairing, or anatomically distorting<sup>27</sup>. Oral propranolol is the first-line treatment and should be administered in early infancy<sup>27</sup>. Results have been observed rapidly, but it is recommended that patients stay on propranolol for a minimum of 6 months and commonly a year<sup>27</sup>. Topical, systemic, or intralesional steroids are also common treatment agents for infantile hemangioma. In severe cases, surgical intervention may be needed. The main risk of surgery is blood loss in this young population<sup>23</sup>. Pulse dye laser (PDL) treatment, uses lasers of a 595 nm wavelength that is preferentially absorbed by hemoglobin to selectively destroy superficial blood vessels without thermally damaging adjacent healthy tissue and has been used in cases of ulceration or superficial telangiectasias<sup>23,35</sup>.

The management options for capillary malformations are limited and known to produce marginal success. PDL is the leading treatment for capillary malformations<sup>35</sup>. While PDL can reliably destroy blood vessels less than or equal to 300  $\mu\text{m}$  below the skin's surface, it cannot irreversibly destroy capillary malformations deeper in the skin. Other laser wavelengths including 755 nm (alexandrite), 800–940 nm (diode), and 1064 (Nd: YAG) are used to target these deeper blood vessels<sup>35</sup>. However, these laser treatments are usually unsuccessful, with complete clearance only occurring in less than 10% of patients treated<sup>35</sup>.

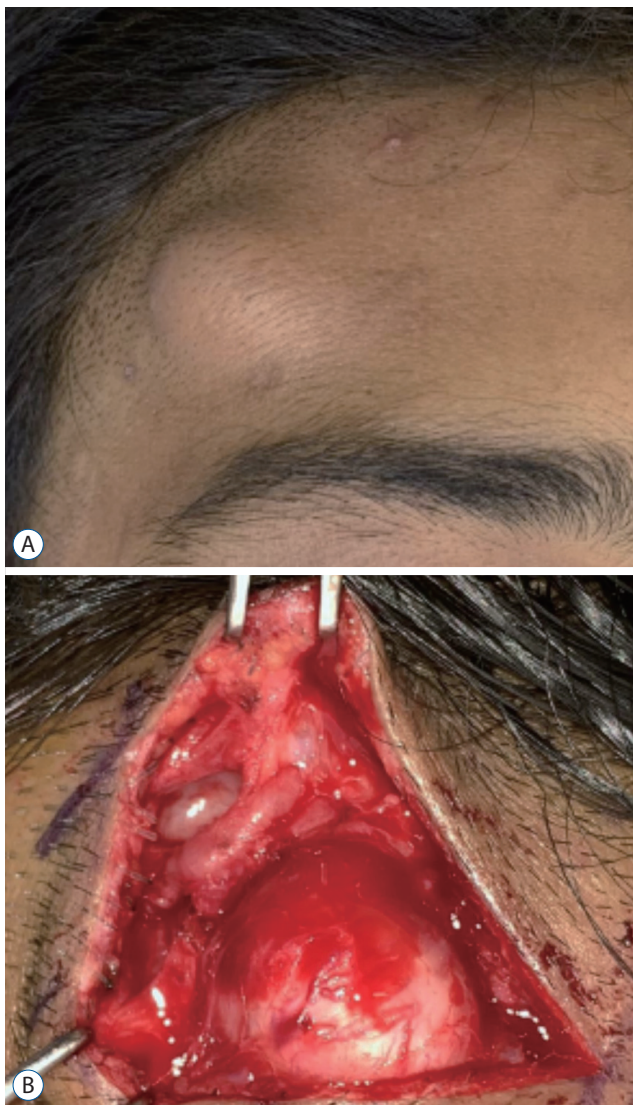Venous malformations are not usually life threatening, but affect quality of life due to cosmetic appearance and pain from thrombosis and inflammation<sup>50</sup>. Venous malformations are often treated by interventional radiologists through sclerotherapy with absolute ethanol or 3% sodium tetradecyl sul-

fate<sup>10</sup>. This approach is effective, but risks include skin necrosis, nerve damage, or system toxicity. Surgical ligation of efferent veins can be used to improve sclerotherapy results. Surgery is often used as a second-line therapy when residual venous malformations or resistant lesions remain after sclerotherapy. A proper resection can be complicated, so surgery is rarely used as a first-line therapy<sup>10</sup>.

Lymphatic malformations are benign lesions, but do not resolve spontaneously. They continue to grow throughout life and often cause cosmetic and functional impairment of the neck and mouth through infection, trauma, and bleeding<sup>52</sup>. Lymphatic malformations are difficult to resect surgically as they infiltrate normal tissue in vital anatomical structures in the head and neck<sup>52</sup>. Complete resection is often impossible due to regeneration and surgical interventions usually have poor outcomes, resulting in secondary deformities and further affecting patients' quality of life<sup>10,52</sup>. Sclerotherapy and laser therapy are the most common interventions for lymphatic malformations and are sometimes used jointly for treatment<sup>52</sup>. Sclerotherapy is not curative, but is effective in the management of macrocystic lymphatic malformation<sup>10,52</sup>.

The central concern of AVM management is whether it is riskier to leave the AVM untreated or to intervene. There is currently no data from randomized controlled clinical trials to guide decision-making. AVMs are most commonly managed through surgical resection. Angiography and other imaging provide anatomical and hemodynamic detail crucial to determining if a patient is a surgical candidate. Resection offers a chance at a cure while risking infection, sepsis, hemorrhage, and recurrence<sup>5</sup>. Risk of hemorrhage can be reduced through pre-operative endovascular embolization of nidus and feeders<sup>14</sup>. Endovascular embolization can also serve as a standalone treatment, although it is associated with a higher risk of recurrence. Other risks include embolization of non-target arteries, local inflammation, and visibility of the embolic agent in superficial lesions<sup>14</sup>.

AVF are managed by interdisciplinary teams from pediatrics, dermatology, plastic surgery, radiology, and neurosurgery. Indications for treatment include prevention of hemorrhage, cosmetic improvement, and pain relief (i.e., headache, tinnitus, etc.)<sup>4,12</sup>. AVFs are most commonly treated through surgical excision (Fig. 6). Ligation of the feeding vessels, transarterial and transvenous embolization, injection of sclerosant into the nidus, and electrothrombosis are also used to treat



**Fig. 6.** Traumatic arteriovenous fistula of the forehead with visible mass but no evidence of venous congestion here (A) and intraoperative exposure (B).

AVF, but are known to produce worse outcomes than surgery<sup>12)</sup>.

## COMPLICATIONS AND PROGNOSIS

The biggest concern for infantile hemangioma is usually cosmetic outcomes. In some cases, after involution, infantile hemangiomas produce fibro-fatty residuum that cause deformities. These deformities can usually be surgically corrected with restoration of function and good cosmetic outcome<sup>23)</sup>.

Capillary malformations treatments have high failure rates as the malformation vessels often regenerate and revascularize within months in response to laser-induced necrosis<sup>35)</sup>. There have been attempts to improve outcomes by combining PDL with anti-angiogenic drugs such as timolol, imiquimod, and sirolimus to block this post-intervention regeneration. Results in clinical trials varied from no improvement to slight improvement<sup>35)</sup>. In most cases of capillary malformations, cosmetic outcomes are poor and some discoloration remains for life. Many capillary malformations patients consequently suffer from loss of self-esteem and psychological distress, affecting their quality of life<sup>35)</sup>.

The only established curative treatment for lymphatic malformation is surgical resection, which often fails due to high likelihood of post-surgical resurgence and high risk of complication due to infiltration of normal and functionally important tissue<sup>52)</sup>. Additionally, sclerosants used to manage lymphatic malformations can cause irreversible damage to the surrounding endothelium, inducing inflammation and fibrosis<sup>10)</sup>.

AVMs managed conservatively can cause headache, tinnitus, epilepsy, cerebral ischemia, and necrosis<sup>42)</sup>. Additionally, infection, sepsis, hemorrhage and necrosis may occur as complications of AVM surgery<sup>18)</sup>. Incomplete treatment of an AVM, even in cases of combined resection and embolization, is the most common cause of recurrence<sup>32)</sup>. There are high chances of recurrence in AVMs, especially large AVMs, after embolization<sup>26)</sup>. There are many reports of late AVM recurrences up to 18 years after surgical resection<sup>32)</sup>.

Risks of AVF surgery include hemorrhage at time of incision and poor outcomes such as partial necrosis of the scalp due to excessive devascularization or recurrence due to incomplete vascularization. Nevertheless, through careful surgical technique, most patients can experience a positive surgical outcome<sup>12)</sup>.

## FUTURE DIRECTIONS AND RESEARCH PROSPECTS

There are currently 155 active U.S. Food and Drug Administration clinical trials focused on vascular malformations. There are six infantile hemangioma studies, 15 capillary malformation studies, 33 venous malformation studies, 34 AVM



**Table 2.** Active clinical trials in vascular malformations targeting specific molecular pathways (as registered in ClinicalTrials.gov)

Clinical trial ID	Malformation target type	Mechanism	Therapy
NCT05871970	Lymphatic malformation	IL-2, IL-6, IL-8, IL-10, IL-12, IFN- $\gamma$ , and TNF- $\alpha$ activator	Inactivated group A streptococcus pyogenes
NCT05171894	Port-Wine stain	Histamines, thromboxane, and TNF- $\alpha$ activator	Hemoporphin-mediated green light photodynamic therapy
NCT01873131	Hemangioma	Beta-blocker	Topical timolol maleate gel
NCT05125471	Arteriovenous malformations	MEK Inhibitor	Cobimetinib
NCT05983159	Venous malformation, lymphatic malformation	MEK Inhibitor for fast flow malformations, PIK3CA inhibitor for slow flow malformations	Mirdametinib and alpelisib
NCT05577754	Capillary malformation	PI3K inhibitor	Alpelisib
NCT05948943	Lymphatic malformation – PIK3CA-mutated	PI3K inhibitor	Alpelisib
NCT04861064	Venous malformation, lymphatic malformation	mTOR inhibitor	Sirolimus
NCT05050149	Lymphatic malformation	mTOR inhibitor	PTX-022 (Sirolimus) topical gel 3.9%
NCT03972592	Lymphatic malformation	mTOR inhibitor	Topical 0.1% sirolimus gel
NCT04128722	Lymphatic malformation	mTOR inhibitor	Sirolimus oral liquid product 1 mg/mL
NCT06160739	Lymphatic malformation	mTOR inhibitor	Sirolimus 1 mg oral tablet
NCT04921722	Lymphatic malformation	mTOR inhibitor	Sirolimus, topical and oral
NCT02042326	Arteriovenous malformations	mTOR inhibitor	Sirolimus

IL : interleukin, IFN : interferon, TNF : tumor necrosis factor, MEK : mitogen-activated protein kinase kinase, PIK3CA : phosphatidylinositol-4,5-bisphosphate 3-kinase catalytic subunit alpha, PI3K : phosphoinositide 3-kinase, mTOR : mammalian target of rapamycin

studies, and 63 AVF studies. However, most of these pertain to devices in the physical occlusion of the malformations, as minor modifications to existing embolization strategies. Fewer studies target the underlying molecular mechanisms of the malformations. There are 14 active studies related to molecular interventions for vascular malformations (Table 2).

## CONCLUSION

Early diagnosis and management by a multidisciplinary team is crucial for patients with scalp and facial vascular malformations as treatment or careful observation can prevent hemorrhages, growth, or the need for more invasive procedures. Given rapid advances in molecular diagnostics and targeted molecular therapeutics, there may be significant changes in the management of scalp and facial vascular malformations in the next few years.

## AUTHOR'S DECLARATION

### Conflicts of interest

No potential conflict of interest relevant to this article was reported.

### Informed consent

This type of study does not require informed consent. De-identified photographs were derived from retrospective review of medical records.

### Author contributions

Conceptualization : APS; Data curation : EH, DMB, APS; Formal analysis : APS; Writing - original draft : EH, APS; Writing - review & editing : EH, DMB, APS

### Data sharing

None

## Preprint

None

## ORCID

Emma Hartman <https://orcid.org/0009-0008-9153-0483>  
Daniel M. Balkin <https://orcid.org/0000-0003-1201-9908>  
Alfred Pokmeng See <https://orcid.org/0000-0003-3634-4692>

## References

1. Ajiboye N, Chalouhi N, Starke RM, Zanaty M, Bell R : Cerebral arteriovenous malformations: evaluation and management. **ScientificWorld-Journal** 2014 : 649036, 2014
2. Anderson KR, Schoch JJ, Lohse CM, Hand JL, Davis DM, Tollefson MM : Increasing incidence of infantile hemangiomas (IH) over the past 35 years: correlation with decreasing gestational age at birth and birth weight. **J Am Acad Dermatol** 74 : 120-126, 2016
3. Arnold R, Chaudry G : Diagnostic imaging of vascular anomalies. **Clin Plast Surg** 38 : 21-29, 2011
4. Badejo L, Rockwood P : Traumatic arteriovenous fistula of the scalp. Case report. **J Neurosurg** 66 : 773-774, 1987
5. Cenzato M, Boeris D, Piparo M, Fratianni A, Piano MA, Dones F, et al. : Complications in AVM Surgery in Esposito G, Regli L, Cenzato M, Kaku Y, Tanaka M, Tsukahara T (eds) : **Trends in Cerebrovascular Surgery and Interventions**. Cham : Springer, 2021
6. Chamli A, Aggarwal P, Jamil RT, Litaïem N : Hemangioma in **StatPearls**. Treasure Island : StatPearls Publishing, 2024
7. Cheng J, Liu B, Farjat AE, Routh J : National characteristics of lymphatic malformations in children: inpatient estimates and trends in the United States, 2000 to 2009. **J Pediatr Hematol Oncol** 40 : 221-223, 2018
8. Cheng YC, Chen HC, Wu CH, Wu YY, Sun MH, Chen WH, et al. : Magnetic resonance angiography in the diagnosis of cerebral arteriovenous malformation and dural arteriovenous fistulas: comparison of time-resolved magnetic resonance angiography and three dimensional time-of-flight magnetic resonance angiography. **Iran J Radiol** 13 : e19814, 2016
9. Cohen MM Jr : Vascular update: morphogenesis, tumors, malformations, and molecular dimensions. **Am J Med Genet A** 140 : 2013-2038, 2006
10. Cox JA, Bartlett E, Lee EI : Vascular malformations: a review. **Semin Plast Surg** 28 : 58-63, 2014
11. Eifert S, Villavicencio JL, Kao TC, Taute BM, Rich NM : Prevalence of deep venous anomalies in congenital vascular malformations of venous predominance. **J Vasc Surg** 31 : 462-471, 2000
12. Fisher-Jeffes ND, Domingo Z, Madden M, de Villiers JC : Arteriovenous malformations of the scalp. **Neurosurgery** 36 : 656-660; discussion 660, 1995
13. Fishman SJ, Mulliken JB : Vascular anomalies. A primer for pediatricians. **Pediatr Clin North Am** 45 : 1455-1477, 1998
14. Ghodduzi Johari H, Shahriarirad R, Erfani A, Darabi MH : High flow scalp arteriovenous malformation: a case report. **World J Plast Surg** 9 : 228-231, 2020
15. Greenberger S, Bischoff J : Pathogenesis of infantile haemangioma. **Br J Dermatol** 169 : 12-19, 2013
16. Gupta V, Chugh M, Walia BS, Vaishya S, Jha AN : Use of CT angiography for anatomic localization of arteriovenous malformation nidal components. **AJNR Am J Neuroradiol** 29 : 1837-1840, 2008
17. Haggstrom AN, Lammer EJ, Schneider RA, Marcucio R, Frieden IJ : Patterns of infantile hemangiomas: new clues to hemangioma pathogenesis and embryonic facial development. **Pediatrics** 117 : 698-703, 2006
18. Hasturk AE, Erten F, Ayata T : Giant non-traumatic arteriovenous malformation of the scalp. **Asian J Neurosurg** 7 : 39-41, 2012
19. Healy J, Balcazar JA, Rivera L, Ruas V : Rapid lymphatic malformation expansion: Imaging, association with asymptomatic Streptococcus infection, multidisciplinary management, and therapeutic approach. **Radiol Case Rep** 18 : 3162-3168, 2023
20. Hemangioma Investigator Group; Haggstrom AN, Drolet BA, Baselga E, Chamlin SL, Garzon MC, et al. : Prospective study of infantile hemangiomas: demographic, prenatal, and perinatal characteristics. **J Pediatr** 150 : 291-294, 2007
21. Holmes LB : Chorionic villus sampling and hemangiomas. **J Craniofac Surg** 20 Suppl 1 : 675-677, 2009
22. Jinnin M, Medici D, Park L, Limaye N, Liu Y, Boscolo E, et al. : Suppressed NFAT-dependent VEGFR1 expression and constitutive VEGFR2 signaling in infantile hemangioma. **Nat Med** 14 : 1236-1246, 2008
23. Khan IS, Kiehna EN, Satti KF, Ehtesham M, Ghiassi M, Singer RJ : Surgical management of large scalp infantile hemangiomas. **Surg Neurol Int** 5 : 41, 2014
24. Kilcline C, Frieden IJ : Infantile hemangiomas: how common are they? A systematic review of the medical literature. **Pediatr Dermatol** 25 : 168-173, 2008
25. Krowchuk DP, Frieden IJ, Mancini AJ, Darrow DH, Blei F, Greene AK, et al. : Clinical practice guideline for the management of infantile hemangiomas. **Pediatrics** 143 : e20183475, 2019
26. Kumar R, Sharma G, Sharma BS : Management of scalp arterio-venous malformation: case series and review of literature. **Br J Neurosurg** 26 : 371-377, 2012
27. Léauté-Labrèze C, Harper JL, Hoeger PH : Infantile haemangioma. **Lancet** 390 : 85-94, 2017
28. Lee SY, Loll EG, Hassan AS, Cheng M, Wang A, Farmer DL : Genetic and molecular determinants of lymphatic malformations: potential targets for therapy. **J Dev Biol** 10 : 11, 2022
29. Liu L, Li X, Zhao Q, Yang L, Jiang X : Pathogenesis of port-wine stains: directions for future therapies. **Int J Mol Sci** 23 : 12139, 2022
30. Malm M, Carlberg M : Port-wine stain--a surgical and psychological problem. **Ann Plast Surg** 20 : 512-516, 1988
31. Meyer JS, Hoffer FA, Barnes PD, Mulliken JB : Biological classification of

- soft-tissue vascular anomalies: MR correlation. **AJR Am J Roentgenol** **157** : 559-564, 1991
32. Mohamed WN, Abdullah NN, Muda AS : Scalp arteriovenous malformation : a case report. **Malays J Med Sci** **15** : 55-57, 2008
  33. Nagpal K, Ahmed K, Cuschieri R : Diagnosis and management of acute traumatic arteriovenous fistula. **Int J Angiol** **17** : 214-216, 2008
  34. Nätyнки M, Kangas J, Miinalainen I, Sormunen R, Pietilä R, Soblet J, et al. : Common and specific effects of TIE2 mutations causing venous malformations. **Hum Mol Genet** **24** : 6374-6389, 2015
  35. Nguyen V, Hochman M, Mihm MC Jr, Nelson JS, Tan W : The pathogenesis of port wine stain and Sturge Weber syndrome: complex interactions between genetic alterations and aberrant MAPK and PI3K activation. **Int J Mol Sci** **20** : 2243, 2019
  36. Noshier JL, Murillo PG, Liszewski M, Gendel V, Gribbin CE : Vascular anomalies: a pictorial review of nomenclature, diagnosis and treatment. **World J Radiol** **6** : 677-692, 2014
  37. Olivieri B, White CL, Restrepo R, McKeon B, Karakas SP, Lee EY : Low-flow vascular malformation pitfalls: from clinical examination to practical imaging evaluation--part 2, venous malformation mimickers. **AJR Am J Roentgenol** **206** : 952-962, 2016
  38. Perkins JA, Manning SC, Tempero RM, Cunningham MJ, Edmonds JL Jr, Hoffer FA, et al. : Lymphatic malformations: current cellular and clinical investigations. **Otolaryngol Head Neck Surg** **142** : 789-794, 2010
  39. Richter GT, Friedman AB : Hemangiomas and vascular malformations: current theory and management. **Int J Pediatr** **2012** : 645678, 2012
  40. Rodríguez Bandera AI, Sebaratnam DF, Wargon O, Wong LF : Infantile hemangioma. Part 1: epidemiology, pathogenesis, clinical presentation and assessment. **J Am Acad Dermatol** **85** : 1379-1392, 2021
  41. Sakai K, Kitagawa T, Nakano Y, Saito T, Suzuki K, Kondo H, et al. : Surgical resection of scalp arteriovenous fistulas after neurosurgical operation: a case report. **Interdiscip Neurosurg** **27** : 101409, 2022
  42. Shi Y, Liu P, Liu Y, Quan K, Li P, Li Z, et al. : Case report: endovascular treatment of two scalp arteriovenous malformation cases via direct percutaneous catheterization: a case series. **Front Neurol** **13** : 945961, 2022
  43. Tamai N, Hashii Y, Osuga K, Chihara T, Morii E, Aozasa K, et al. : Kasabach-Merritt phenomenon. **Skeletal Radiol** **39** : 1043-1046, 2010
  44. Tan W, Wang J, Zhou F, Gao L, Yin R, Liu H, et al. : Coexistence of Eph receptor B1 and ephrin B2 in port-wine stain endothelial progenitor cells contributes to clinicopathological vasculature dilatation. **Br J Dermatol** **177** : 1601-1611, 2017
  45. Uebelhoer M, Nätyнки M, Kangas J, Mendola A, Nguyen HL, Soblet J, et al. : Venous malformation-causative TIE2 mutations mediate an AKT-dependent decrease in PDGFB. **Hum Mol Genet** **22** : 3438-3448, 2013
  46. Vikkula M, Boon LM, Mulliken JB : Molecular genetics of vascular malformations. **Matrix Biol** **20** : 327-335, 2001
  47. Wali S, Alsolmi A, Babgi M, Alqurashi A, Alghamdi D, Bajunaid K, et al. : Scalp arteriovenous malformation with dual bilateral arterial feeders: case report and review of literature. **Interdiscip Neurosurg** **27** : 101431, 2022
  48. Wang X, Bove AM, Simone G, Ma B : Molecular bases of VEGFR-2-mediated physiological function and pathological role. **Front Cell Dev Biol** **8** : 599281, 2020
  49. White CL, Olivieri B, Restrepo R, McKeon B, Karakas SP, Lee EY : Low-flow vascular malformation pitfalls: from clinical examination to practical imaging evaluation--part 1, lymphatic malformation mimickers. **AJR Am J Roentgenol** **206** : 940-951, 2016
  50. Zhang X, Zhao X, Wu P, Zhao Z, Liu M, Wang YA : Prevalence and associated factors of anxiety and depression among patients with oromaxillofacial venous malformations. **Ann Palliat Med** **10** : 8642-8650, 2021
  51. Zheng F, Augustus Pitts H, Goldbrunner R, Kriscsek B : Traumatic arteriovenous fistula of the scalp in the left temporoparietal region with intra- and extracranial blood supply. **Case Rep Vasc Med** **2016** : 8671472, 2016
  52. Zhou Q, Zheng JW, Mai HM, Luo QF, Fan XD, Su LX, et al. : Treatment guidelines of lymphatic malformations of the head and neck. **Oral Oncol** **47** : 1105-1109, 2011
  53. Zyc S, Davidson CL, Sampath R : Arteriovenous Malformations in **StatPearls**. Treasure Island : StatPearls Publishing, 2024