

Curve evolution during bracing in children with scoliosis secondary to early-onset neurofibromatosis type 1: indicators of rapid curve progression

Ben-Long Shi, Yang Li, Ze-Zhang Zhu, Sai-Hu Mao, Zhen Liu, Xu Sun, Yong Qiu

Department of Spine Surgery, Affiliated Drum Tower Hospital of Nanjing University Medical School, Nanjing, Jiangsu 210008, China.

Abstract

Background: Scoliosis secondary to neurofibromatosis type 1 (NF1) in children aged <10 years is an important etiology of early-onset scoliosis (EOS). This study was performed to investigate the curve evolution of patients with EOS secondary to NF1 undergoing bracing treatment and to analyze high-risk indicators of rapid curve progression.

Methods: Children with EOS due to NF1 who underwent bracing treatment from 2010 to 2017 were retrospectively reviewed. The angle velocity (AV) at each visit was calculated, and patients with rapid curve progression (AV of >10°/year) were identified. The age at modulation and the AV before and after modulation were obtained. Patients with ($n = 18$) and without rapid curve progression ($n = 10$) were statistically compared.

Results: Twenty-eight patients with a mean age of 6.5 ± 1.9 years at the initial visit were reviewed. The mean Cobb angle of the main curve was $41.7^\circ \pm 2.4^\circ$ at the initial visit and increased to $67.1^\circ \pm 8.6^\circ$ during a mean follow-up of 44.1 ± 8.5 months. The overall AV was $6.6^\circ \pm 2.4^\circ$ /year for all patients. At the last follow-up, all patients presented curve progression of >5°, and 20 (71%) patients had progressed by >20°. Rapid curve progression was observed in 18 (64%) patients and was associated with younger age at the initial visit and a higher incidence of modulation change during follow-up ($t = 2.868$, $P = 0.008$ and <0.001 , respectively). The mean AV was $4.4^\circ \pm 1.2^\circ$ /year before modulation and $11.8^\circ \pm 2.7^\circ$ /year after modulation ($t = 11.477$, $P < 0.010$).

Conclusions: Curve progression of >10°/year is associated with younger age at the initial visit, and modulation change indicated the occurrence of the rapid curve progression phase.

Keywords: Bracing treatment; Early-onset scoliosis; Modulation; Neurofibromatosis type 1; Rapid curve progression

Introduction

Scoliosis secondary to neurofibromatosis type 1 (NF1) in children aged <10 years, an important etiology of early-onset scoliosis (EOS), is a great challenge for spine surgeons.^[1,2] Non-fusion techniques such as growing rods have been widely applied in this cohort with strong evidence showing their benefits in continuous pulmonary and spinal growth. However, the need for multiple surgical exposures and the risks of infection, premature fusion, implant failure, and other complications associated with these techniques are significantly concerning to patients and their parents.^[2,3]

In clinical practice, non-operative techniques including serial casting and bracing have been traditionally recommended for patients with EOS characterized by mild to moderate curves.^[1,4] In addition, bracing treatment has served as the only effective conservative strategy for patients with moderate deformities who refuse surgical interven-

tion.^[5] Unfortunately, rapid curve progression is much more common in patients with NF1-associated EOS even when these patients have fully abided by the professional instructions regarding brace-wearing, leading to a relatively high risk of failed bracing treatment.^[6] This has raised an urgent query regarding the causes of this frustrating prognosis. The current study was therefore designed (1) to investigate the curve evolution of children with early-onset NF1-associated scoliosis undergoing bracing treatment and (2) to analyze the possible high-risk indicators of rapid curve progression during bracing treatment.

Methods

Ethical approval

This study was conducted in accordance with the *Declaration of Helsinki*. Ethical approval of this study

Access this article online

Quick Response Code:



Website:
www.cmj.org

DOI:
10.1097/CM9.0000000000001606

Ben-Long Shi and Yang Li contribute equally to this work.

Correspondence to: Dr. Yong Qiu, Department of Spine Surgery, Affiliated Drum Tower Hospital of Nanjing University Medical School, Nanjing, Jiangsu 210008, China
E-Mail: scoliosis2002@sina.com

Copyright © 2021 The Chinese Medical Association, produced by Wolters Kluwer, Inc. under the CC-BY-NC-ND license. This is an open-access article distributed under the terms of the Creative Commons Attribution-NonCommercial-NoDerivatives 3.0 License, where it is permissible to download and share the work provided it is properly cited. The work cannot be changed in any way or used commercially.

Chinese Medical Journal 2021;134(16)

Received: 23-12-2020 Edited by: Ning-Ning Wang

was obtained from the Clinical Research Ethics Committee of our university hospital (No. 2017-112-08). Written informed consent was obtained from all patients or their guardian before their enrolment in this study.

Patients

Patients with scoliosis who underwent bracing treatment from 2010 to 2017 in our center were retrospectively reviewed. The inclusion criteria were (1) satisfaction of the diagnostic criteria for NF1 as established by the Consensus Development Conference on Neurofibromatosis,^[7] (2) non-dystrophic scoliosis (with fewer than three dystrophic features) at the initial visit, (3) age of <10 years, (4) >75% compliance with bracing treatment as evaluated by the patient's recall of the average number of hours per day during which the brace was worn, and (5) regular follow-up for at least 2 years. The exclusion criteria were (1) any previous spinal surgery and (2) abnormalities of maturation, height, or both lower extremities.

Bracing strategy

At the initial visit, an individual file was created for each patient, and his or her age, sex, Risser sign, and curve magnitude were recorded. Initially, each patient was instructed to wear a brace for 22 h/day with follow-up at an advised interval of 6 months to monitor the change in the curve magnitude. At each visit, all patients underwent a full-length standard X-ray examination of the whole spine. Adjustments in the brace size and wearing time and the decision regarding whether to undergo brace weaning or surgical intervention were made based on the dynamic change in the Cobb angle of the main curve. When the Cobb angle progressed by >50° and continuous rapid curve progression was anticipated, surgical intervention was recommended to the patients and their parents. However, for patients who strongly refused surgical treatment because of individual or financial considerations, bracing treatment was continued. Brace weaning was recommended for patients with a <1-cm change in standing height between two consecutive measurements, Risser stage ≥4, and >2 years post-menarche.

Radiographic measurements

The Cobb angle of the main curve at each visit was measured, and the angle velocity (AV) (average progression of Cobb angle per year) and deformity angular ratio (DAR)^[8] were further calculated. Rapid curve progression was defined as AV of >10°/year in the current study. The following dystrophic features were assessed on whole spinal radiographs: (1) penciling of three or more ribs, (2) grade 3+ vertebral rotation as measured by the Nash–Moe method, (3) vertebral scalloping, (4) vertebral wedging, (5) spindling of the transverse process, and (6) a focal, short-segmented curve involving six or fewer vertebrae. Patients with three or more of these features were considered to have a dystrophic curve.^[9] In addition, the tendency to acquire new dystrophic features during longitudinal follow-up was defined as modulation change,^[10] and the age at modulation was recorded. The AV before and after modulation was further calculated.

Statistical analysis

SPSS software version 18.0 (SPSS, Inc., Chicago, IL, USA) was applied for the statistical analysis. Descriptive results are expressed as mean ± standard deviation. Patients with and without rapid curve progression were compared using the Chi-square test and Fisher exact test or the independent-sample *t*-test. Differences between pre-modulation and post-modulation were investigated with the paired-sample *t*-test. A statistically significant difference was defined as $P < 0.050$.

Results

General data

Thirty-three patients were retrospectively identified, among whom 28 patients (18 female and ten male patients) with a mean age of 6.5 ± 1.9 years at the initial visit were finally included in this study. Five (15%) patients were excluded from the analysis because of an insufficient follow-up time or irregular bracing treatment. The age at diagnosis was <7 years in 19 (68%) patients. At the initial visit, the Risser sign was 0 in all patients. No dystrophic features were observed in nine (32%) patients, whereas 1 to 2 dystrophic features were observed in 19 (68%) patients at the initial visit. During follow-up, 21 (75%) patients presented modulation change (acquisition of ≥1 dystrophic features) at a mean age of 8.9 ± 2.1 years, including six patients before the age of 7 years. The most common dystrophic features of modulation change were rib penciling (79%), vertebral wedging (71%), and rotation (68%); other dystrophic features were vertebral scalloping (46%), spindling of the transverse process (25%), and focal short-segmented curve (14%). At the last follow-up, a dystrophic curve was observed in all 21 patients with modulation change, while the remaining seven patients still had non-dystrophic curvature. A total of 22 (79%) patients underwent posterior spinal correction and fusion surgery, and the mean age at surgery was 10.3 ± 1.3 years (range, 8.5–12.5 years). Bracing treatment with close observation was performed in the other six patients.

Details of AV

The mean Cobb angle of the main curve was $41.7^\circ \pm 2.4^\circ$ (range, 35°–50°) at the initial visit and increased to $67.1^\circ \pm 8.6^\circ$ (range, 50°–88°) during a mean follow-up of 44.1 ± 8.5 months (range, 24–66 months). The overall AV was $6.6^\circ \pm 2.4^\circ/\text{year}$ for all patients. At the last follow-up, all patients presented curve progression of >5°, and 20 (71%) patients progressed by >20° (range, 21°–41°). Rapid curve progression was observed in 18 (64%) patients during the whole follow-up period.

Indicators of rapid curve progression

The comparison analysis demonstrated a significantly younger age at the initial visit and a higher incidence of modulation change during follow-up in patients with than those without rapid curve progression ($t = 2.868$, $P = 0.008$, and $P < 0.001$, respectively) [Table 1]. There

Table 1: Comparison between patients with and without rapid curve progression.

Indicators	With rapid curve progression (n = 18)	Without rapid curve progression (n = 10)	Statistical	P
Age at initial visit (years)	5.6 ± 1.9	8.1 ± 2.7	2.868*	0.008
Cobb angle of main curve at initial visit (°)	43.6 ± 6.6	38.3 ± 6.8	2.015*	0.543
DAR at initial visit (°/level)	8.0 ± 2.9	7.7 ± 3.3	0.250*	0.812
Curve type (thoracic/thoracolumbar/lumbar)	11/5/2	6/2/2	0.512 [†]	0.774
Number of patients with 1–2 dystrophic changes at initial visit	11	6	–	0.632 [‡]
Modulation during follow-up (with/without)	18/0	3/7	–	<0.001 [‡]

Data are presented as mean ± standard deviation or number of patients. * *t* value. [†]Chi-squared value. [‡]Fisher exact test. DAR: Deformity angular ratio.

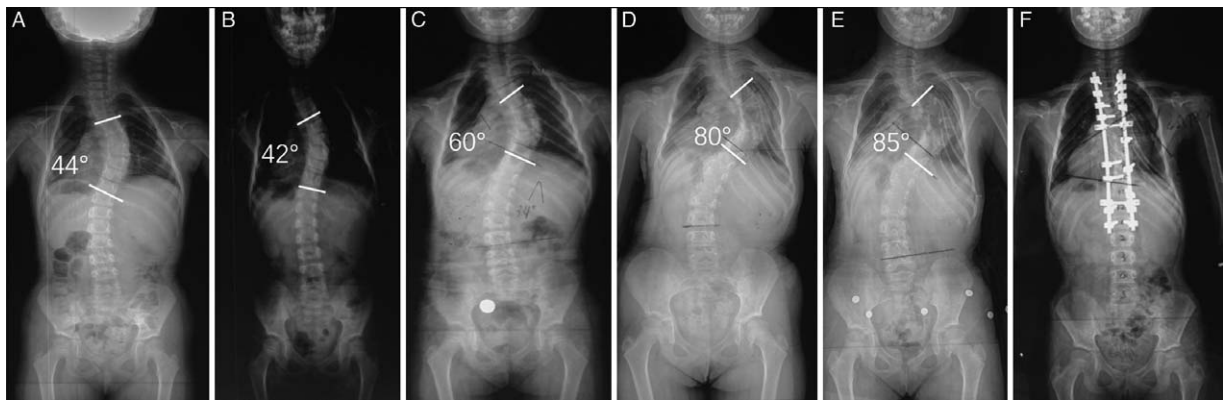


Figure 1: A 4.5-year-old girl was diagnosed with NF1-associated scoliosis. (A) The Cobb angle of the main curve was 44° at the initial visit, and bracing treatment was recommended. (B) The main curve had slightly decreased to 42° at the 6-month follow-up. (C) However, it had gradually increased to 60° with the presence of rib penciling, vertebral rotation, and wedging at the 2-year follow-up. (D) At the 4-year follow-up, the curve had rapidly progressed to 80°. (E) At the 4.5-year follow-up, the coronal curve had progressed to 85°. (F) The patient finally underwent posterior spinal correction surgery at 9 years of age. NF1: Neurofibromatosis type 1.

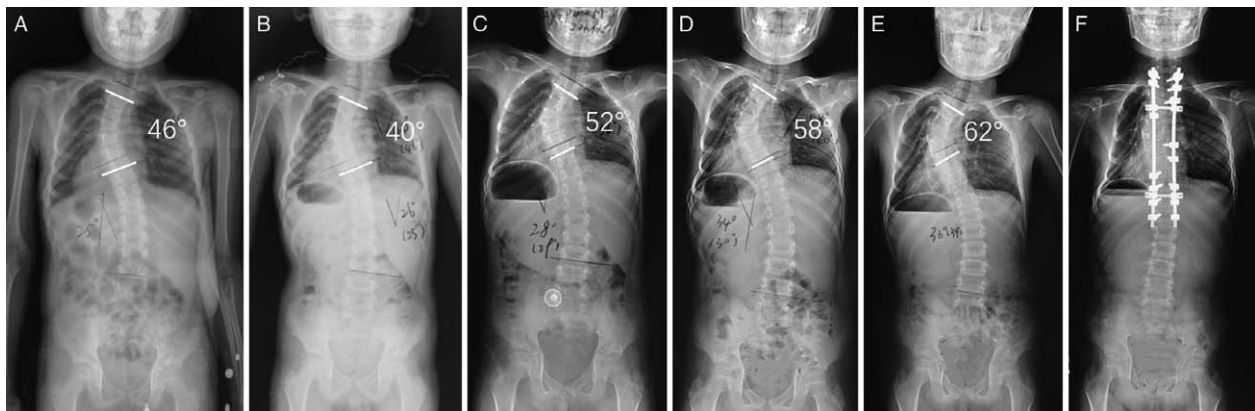


Figure 2: A 9-year-old boy was diagnosed with NF1-associated scoliosis. (A) The Cobb angle of the main curve was 46° at the initial visit, and bracing treatment was recommended. (B) The main curve had slightly decreased to 40° at the 6-month follow-up. (C) Modulation change was observed with the presence of rib penciling and the main thoracic curve had gradually increased to 52° at the 2.5-year follow-up. The main thoracic curve had progressed to (D) 58° at the 3-year follow-up and to (E) 62° at the 3.5-year follow-up. (F) The patient finally underwent posterior spinal correction surgery at 13 years of age. NF1: Neurofibromatosis type 1.

was no significant difference in the Cobb angle at the initial visit, DAR, curve type, number of patients with dystrophic features at the initial visit, or Cobb angle at modulation between the groups ($P > 0.050$ for all) [Table 1]. Among the 21 patients with modulation change, the mean AV was $4.4^\circ \pm 1.2^\circ/\text{year}$ before modulation and $11.8^\circ \pm 2.7^\circ/\text{year}$ after modulation ($t = 11.477$, $P < 0.010$). Representative cases are shown in Figures 1 and 2.

Discussion

The first 10 years of life is widely accepted as a critical period for spinal growth and pulmonary development, and spinal deformities secondary to multiple etiologies in this younger population definitely have profound physiologic effects on the patients. Considering the limitations of non-fusion techniques,^[1-3] bracing treatment seems to be more friendly to continuous spinal growth.^[4] However, despite

the relatively inspiring outcomes in patients with idiopathic scoliosis,^[5,11] bracing treatment seems to be less helpful and more controversial in patients with NF1-associated scoliosis.^[6]

A few studies to date have focused on the curve evolution of NF1-associated scoliosis in relatively small samples of patients.^[6,12,13] Winter *et al*^[6] evaluated ten patients with dystrophic curves undergoing Milwaukee brace treatment, and the patients' average age at brace prescription was 7.8 years. The average Cobb angle increased from 53° to 80° with a mean AV of 7.7°/year during a 3.5-year follow-up. Calvert *et al*^[12] reported that patients with severe anterior vertebral scalloping showed scoliosis progression of an average of 23°/year. The current study involved 28 patients with NF1-associated non-dystrophic scoliosis at the initial visit. Their mean age was 6.5 years and their mean Cobb angle was 41.7° at the initial visit. During the mean 44.1-month longitudinal follow-up, curve progression of >5° was observed in all patients, and the Cobb angle of the main curve was 67.1° at the last follow-up. These disappointing preliminary results imply that patients with NF1-associated scoliosis have a significantly high risk of curve progression; this is true even for patients with idiopathic-like NF1-associated scoliosis, which is markedly different from idiopathic scoliosis.

Previous studies^[14-18] have revealed that among patients with idiopathic scoliosis, those with younger chronologic age, Risser stage 0, and a larger curve magnitude have a higher risk of failed bracing outcomes. In the current study, rapid curve progression was defined as AV of >10°/year, and the comparison analysis demonstrated a significantly younger age at the initial visit in patients with rapid curve progression during follow-up ($P = 0.008$); these findings are in accordance with the published results. Although the Cobb angle of the main curve at the initial visit showed an increasing trend in patients with rapid curve progression, there was no significant difference between the groups ($P = 0.543$). We believe that the relatively small sample size was likely responsible for the lack of a significant difference.

Modulation is a special phenomenon in patients with NF1-associated scoliosis and is defined as the tendency to acquire dystrophic features during longitudinal follow-up.^[10] Durrani *et al*^[10] reported that the age of 7 years is the watershed of modulation. Modulation change ultimately occurred in 81% of patients with NF1-associated scoliosis who were <7 years old during the natural history of their disease condition, and those with penciling of three or more ribs showed a mean annual progression of 12° (compared with a mean annual progression of 5° in the non-modulated group).^[10] In this study, 19 patients were diagnosed with NF1-associated scoliosis before 7 years of age, whereas only six (31.6%) patients exhibited modulation before 7 years of age. The average AV of the main curve was 4.4°/year before modulation and 11.8°/year after modulation, and a significant difference was observed ($P < 0.010$). Therefore, modulation change strongly indicated the occurrence of rapid curve progression. Notably, however, the causal relationship between modulation and rapid curve progression should undergo in-depth investigation in further studies. According to the

natural history reported by Durrani *et al*,^[10] we assume that the age at the time of modulation change is delayed to some extent presumably with the help of bracing, further contributing to a slight hindrance of the curve progression.

Durrani *et al*^[10] also found that the rib penciling acquired during the modulation period was the only indicator of rapid curve progression, and clinical progression was almost a certainty when a curve was accompanied by either three penciled ribs or a combination of three dystrophic features. They observed that the most common dystrophic features were rib penciling (62%), vertebral rotation (51%), and vertebral scalloping (41%). However, Lykissas *et al*^[9] investigated 56 patients with dystrophic NF1-associated scoliosis and found that the most frequent dystrophic features were paraspinal tumors (63%), vertebral scalloping (55%), and vertebral wedging (52%). In our study, the most common dystrophic features during modulation were rib penciling, vertebral wedging, and vertebral rotation, similar to the results reported by Durrani *et al*.^[10]

This study had several limitations. First, this study was limited by the inherent shortcomings of retrospective studies. Second, the relatively small sample size and lack of a control group decrease the persuasiveness of the conclusion. No further statistical analysis, such as correction analysis or logistic regression analysis, was performed because of the small sample size. Third, because patients usually only underwent X-ray roentgenography examinations at each follow-up, other dystrophic features such as paraspinal tumors and dural ectasia as confirmed by magnetic resonance imaging or computed tomography were overlooked in this study. Thus, the boundary between dystrophic and non-dystrophic pathology may be obscure. Finally, the relatively high Cobb angle at the initial visit indicated a higher risk of curve progression during follow-up, leading to inextricable deviations in the results.

This study focus on the curve evolution of NF1-associated EOS with bracing treatment. Although wearing a brace was considered the only conservative option for patients who strongly refused surgery, irreversible curve progression of >5° was observed in all patients, and 71.4% of patients had progressed by >20° at the last follow-up. Curve progression of >10°/year during follow-up was associated with younger age at the initial visit, and modulation highly indicated the occurrence of the rapid curve progression phase. The main goal of bracing treatment in patients with NF1-associated scoliosis is to delay the performance of surgical intervention; however, patients should be thoroughly informed of the potential risks and anticipated failure of bracing treatment.

Funding

This work was supported by the Development Project of Nanjing Science and Technology Commission and Foundation (No. YKK16119) and the Jiangsu Province 333 Talent Grant (No. 2016-III-0114).

Conflicts of interest

None.

References

1. Yang S, Andras LM, Redding GJ, Skaggs DL. Early-onset scoliosis: a review of history, current treatment, and future directions. *Pediatrics* 2016;137:1–12. doi: 10.1542/peds.2015-0709.
2. Jain VV, Berry CA, Crawford AH, Emans JB, Sponseller PD. Growing Spine Study Group. Growing rods are an effective fusionless method of controlling early-onset scoliosis associated with neurofibromatosis type 1 (NF1): a multicenter retrospective case series. *J Pediatr Orthop* 2017;37:e612–e618. doi: 10.1097/bpo.0000000000000963.
3. Studer D, Hasler CC. Long term outcome of vertical expandable prosthetic titanium rib treatment in children with early onset scoliosis. *Ann Transl Med* 2020;8:25. doi: 10.21037/atm.2019.09.158.
4. Thorsness RJ, Faust JR, Behrend CJ, Sanders JO. Nonsurgical management of early-onset scoliosis. *J Am Acad Orthop Surg* 2015;23:519–528. doi: 10.5435/jaaos-d-14-00019.
5. Zhu Z, Xu L, Jiang L, Sun X, Qiao J, Qian BP, *et al*. Is brace treatment appropriate for adolescent idiopathic scoliosis patients refusing surgery with Cobb angle between 40 and 50 degrees. *Clin Spine Surg* 2017;30:85–89. doi: 10.1097/BSD.0b013e3182a1de29.
6. Winter RB, Moe JH, Bradford DS, Lonstein JE, Pedras CV, Weber AH. Spine deformity in neurofibromatosis. A review of one hundred and two patients. *J Bone Joint Surg Am* 1979;61:677–694. doi: 10.2106/00004623-197961050-00006.
7. Neurofibromatosis. Conference statement. National Institutes of Health Consensus Development Conference. *Arch Neurol* 1988;45:575–578.
8. Wang XB, Lenke LG, Thuet E, Blanke K, Koester LA, Roth M. Deformity angular ratio describes the severity of spinal deformity and predicts the risk of neurologic deficit in posterior vertebral column resection surgery. *Spine (Phila Pa 1976)* 2016;41:1447–1455. doi: 10.1097/BRS.0000000000001547.
9. Lykissas MG, Schorry EK, Crawford AH, Gaines S, Rieley M, Jain VV. Does the presence of dystrophic features in patients with type 1 neurofibromatosis and spinal deformities increase the risk of surgery? *Spine (Phila Pa 1976)* 2013;38:1595–1601. doi: 10.1097/BRS.0b013e31829a7779.
10. Durrani AA, Crawford AH, Chouhdry SN, Saifuddin A, Morley TR. Modulation of spinal deformities in patients with neurofibromatosis type 1. *Spine (Phila Pa 1976)* 2000;25:69–75. doi: 10.1097/00007632-200001010-00013.
11. Yrjonen T, Ylikoski M, Schlenzka D, Poussa M. Results of brace treatment of adolescent idiopathic scoliosis in boys compared with girls: a retrospective study of 102 patients treated with the Boston brace. *Eur Spine J* 2007;16:393–397. doi: 10.1007/s00586-006-0167-z.
12. Calvert PT, Edgar MA, Webb PJ. Scoliosis in neurofibromatosis. The natural history with and without operation. *J Bone Joint Surg Br* 1989;71:246–251. doi: 10.1302/0301-620X.71B2.2494186.
13. Crawford AH, Herrera-Soto J. Scoliosis associated with neurofibromatosis. *Orthop Clin North Am* 2007;38:553–562. doi: 10.1016/j.ocl.2007.03.008.
14. Sanders JO, Browne RH, McConnell SJ, Margraf SA, Cooney TE, Finegold DN. Maturity assessment and curve progression in girls with idiopathic scoliosis. *J Bone Joint Surg Am* 2007;89:64–73. doi: 10.2106/jbjs.f.00067.
15. Sanders JO. Maturity indicators in spinal deformity. *J Bone Joint Surg Am* 2007;89:14–20. doi: 10.2106/jbjs.f.00318.
16. Emans JB, Kaelin A, Bancel P, Hall JE, Miller ME. The Boston bracing system for idiopathic scoliosis. Follow-up results in 295 patients. *Spine (Phila Pa 1976)* 1986;11:792–801. doi: 10.1097/00007632-198610000-00009.
17. Nault ML, Parent S, Phan P, Roy-Beaudry M, Labelle H, Rivard M. A modified Risser grading system predicts the curve acceleration phase of female adolescent idiopathic scoliosis. *J Bone Joint Surg Am* 2010;92:1073–1081. doi: 10.2106/jbjs.h.01759.
18. Peng Y, Wang SR, Qiu GX, Zhang JG, Zhuang QY. Research progress on the etiology and pathogenesis of adolescent idiopathic scoliosis. *Chin Med J* 2020;133 4:483–493. doi: 10.1097/CM9.0000000000000652.

How to cite this article: Shi BL, Li Y, Zhu ZZ, Mao SH, Liu Z, Sun X, Qiu Y. Curve evolution during bracing in children with scoliosis secondary to early-onset neurofibromatosis type 1: indicators of rapid curve progression. *Chin Med J* 2021;134:1983–1987. doi: 10.1097/CM9.0000000000001606