

# Analysis between Retromandibular and Periangular Transmasseteric Approach for Fixation of Condylar Fracture - A Prospective Study

Saloni Gupta, Vishal Bansal, Apoorva Mowar, Jayendra Purohit<sup>1</sup>, Mohit Bindal

Department of Oral and Maxillofacial Surgery, Swami Vivekanand Subharti University, Meerut, Uttar Pradesh, <sup>1</sup>Department of Oral and Maxillofacial Surgery, College of Dental Science, Amargadh, Gujarat, India

## Abstract

**Introduction:** Condylar fractures make up for an average of 17.5%–52% of all mandibular fractures. The aim of the present study was to compare the ease, success, and complications between retromandibular and periangular transmasseteric approaches when used for open reduction and internal fixation of condylar fractures. **Materials and Methods:** A total 20 cases with condylar fracture, ten each for retromandibular and periangular transmasseteric approach, were included in the study. Patients were evaluated at 1 week, 1 month, 3 months, and 6 months. Postoperative occlusion, maximum mouth opening, range of movement, facial nerve function, visibility, convenience of plating, and time taken for exposure, fixation, and closure were recorded. Incidence of complications such as wound dehiscence, wound infection, hematoma, sialocele formation, Frey's syndrome, and hypertrophic scars were also evaluated. **Results:** The mean exposure time in the retromandibular approach was 10 min 31 s and 9 min 17 s in the periangular transmasseteric approach. The incidence of facial nerve injury was 2 of 10 patients in the retromandibular group and 3 of 10 patients in the periangular transmasseteric group, all of which resolved within 6 months. The incidence of sialocele was 2 of 10 in the retromandibular group. The time taken for exposure of the fracture site was statistically significant between the two approaches ( $P = 0.048$ ) with longer time required for retromandibular approach. **Discussion:** It can be summarized that both the approaches are comparable and well suited for surgical management of condylar fractures. It was observed that in displaced condylar neck fractures, greater difficulty was experienced in the periangular transmasseteric approach than the retromandibular approach.

**Keywords:** Condylar fracture, periangular transmasseteric, retromandibular

## INTRODUCTION

Condylar fractures make up for an average of 17.5%–52% of all mandibular fractures.<sup>[1]</sup> The most common causes of condylar fractures include road traffic accidents, personal violence, and fall from height.<sup>[2]</sup> It has been noted that the condylar fractures are the most controversial fractures regarding their management.<sup>[3]</sup> The decision for open reduction and fixation relies on the age of the patient, unilateral or bilateral fracture, level and displacement of the fracture, and presence of teeth.<sup>[1]</sup> Despite being the choice of most surgeons, the closed reduction has certain disadvantages such as malunion, deranged occlusion, and inappropriate function of the temporomandibular joint (TMJ).<sup>[4]</sup> Open reduction and internal fixation (ORIF) facilitates rapid return to pretraumatic function and a protected airway in asthmatic or epileptic patients.<sup>[5]</sup>

The reported complications associated with surgical approach include infection, neurovascular injury, and scar formation.<sup>[6]</sup>

Earlier Zide and Kent introduced indications for open reduction of condylar fractures.<sup>[7]</sup> Other established criteria include severely displaced ( $>45^\circ$  in the coronal or sagittal plane) fracture, 2–5 mm overlap leading due to shortening of the

**Address for correspondence:** Dr. Saloni Gupta,  
Department of Oral and Maxillofacial Surgery, Swami Vivekanand Subharti  
University, Meerut, Uttar Pradesh, India.  
E-mail: salonig.sg@gmail.com

**Received:** 30-01-2020

**Revised:** 06-04-2020

**Accepted:** 17-04-2020

**Published:** 23-12-2020

This is an open access journal, and articles are distributed under the terms of the Creative Commons Attribution-NonCommercial-ShareAlike 4.0 License, which allows others to remix, tweak, and build upon the work non-commercially, as long as appropriate credit is given and the new creations are licensed under the identical terms.

**For reprints contact:** WKHLRPMedknow\_reprints@wolterskluwer.com

**How to cite this article:** Gupta S, Bansal V, Mowar A, Purohit J, Bindal M. Analysis between retromandibular and periangular transmasseteric approach for fixation of condylar fracture - A prospective study. *Ann Maxillofac Surg* 2020;10:353-60.

### Access this article online

#### Quick Response Code:



**Website:**  
www.amsjournal.com

**DOI:**  
10.4103/ams.ams\_28\_20

ramus when no other means can correct the deformity (class three molar relation and apertognathia).<sup>[8]</sup>

Numerous surgical approaches have been proposed for the treatment of condylar fractures: submandibular, preauricular, retroauricular, periangular, rhytidectomy, intraoral, retromandibular, and combinations thereof. An ideal surgical approach for the treatment of mandibular condyle fractures should have good accessibility and visibility with minimal trauma to the neurovascular structures which can be avoided with an endoscopic intraoral route.<sup>[9,10]</sup>

The purpose of this study was to compare the accessibility according to the level of fracture and complications encountered in retromandibular and periangular transmasseteric approach.

## MATERIALS AND METHODS

This prospective study included a total of 20 cases with a condylar fracture who reported to the Department of Oral and Maxillofacial Surgery of a teaching hospital in Meerut. The patients were randomly allotted into two groups of ten fractures each. Group 1 represented retromandibular approach, whereas Group 2 represented periangular transmasseteric approach. The study was conducted in accordance with the World Medical Association Declaration of Helsinki. Patients were evaluated clinically and radiographically pre- and postoperatively at regular interval till 6 months. Patient's demographic data, level of fracture, maximum mouth opening, malocclusion, and TMJ function were recorded. Operators graded the visibility and convenience of plating. Visibility was graded as good when anterior and posterior border and the superoinferior view of the surgical field was adequate, fair when the visibility of the anterior border was compromised, and poor when the exposure was too limited to visualize the fracture line. The time taken for exposure of the surgical site and fixation was recorded. Postoperative complications such as infection, wound dehiscence, sialoceles formation, Frey's syndrome, scar formation, and paralysis of the facial nerve were recorded.

### Surgical technique

#### *Retromandibular approach (Group 1)*

A standard retromandibular approach described by Hinds and Girotti in 1967 was followed.<sup>[11]</sup> A 3–4 cm incision, 5 mm below the earlobe, was made parallel to the posterior border of the mandible. A blunt dissection was carried out in superomedial direction till the capsule of the parotid gland and a suture was passed through the two cut sides to facilitate watertight closure and thereby prevent sialoceles formation [Figure 1]. The gland was bluntly dissected with a curved hemostat in an anteromedial direction, parallel to the direction of the branches of the facial nerve. After identification of the posterior border of the mandible, pterygomasseteric sling was incised. The fibers of masseter muscle were stripped to gain exposure of the fracture site till sigmoid notch.

#### *Periangular transmasseteric approach (Group 2)*

A technique defined by Wilson *et al.* for transmasseteric approach was followed which is approximately 4 cm long curvilinear incision, 5 mm below and along the angle of the mandible<sup>[12,13]</sup> [Figure 2]. After skin incision, dissection was continued in the subcutaneous plane, upward and superficial to the platysma till the zygomatic arch. The thin platysma muscle is held with tissue holding forceps and incised obliquely to expose the masseteric fascia overlying the masseter belly [Figure 3]. The area adjacent to the anterior edge of the parotid gland is relatively free of the branches of the facial nerve and hence ideal for further dissection. The parotid tissue was retracted posteriorly with retractors positioned horizontally, and the belly of masseter muscle was incised parallel to the fibers of the branches of the facial nerve to expose the periosteum. The periosteum was incised and the direction of retractor changed vertically to retract masseter in an upward pull manner to expose the fractured segment.

The fixation of the fracture segments was performed as per the Meyer's line of osteosynthesis with either two miniplates or geometric three-dimensional plates<sup>[14]</sup> [Figures 4 and 5].

## RESULTS

The present study included 15 (75%) males and five (25%) females with a mean age of  $29.2 \pm 12.6$  (range, 15–53 years). Road traffic accident was the most common (60%) cause, followed by fall from height in 30% of the cases and interpersonal violence in 10% of the cases.

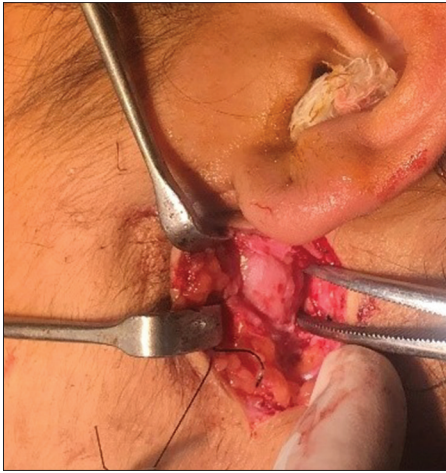Fourteen cases were associated with parasymphysis fracture, one case with contralateral mandibular body fracture, and one case with an ipsilateral zygomaticomaxillary complex fracture. Four cases reported with isolated condylar fractures. Bilateral condylar fracture was observed in four cases.

Group 1 included one (5%) condylar head, seven (35%) condylar neck, and two (10%) condylar base fractures. Group 2 included two (10%) condylar neck and eight (40%) condylar base fractures [Table 1].

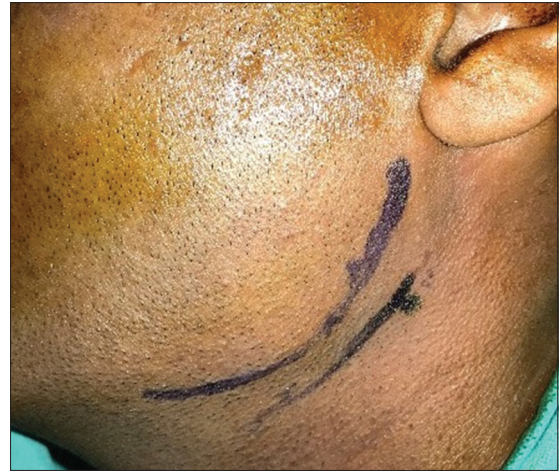Deviation with medial overlapping segments was seen in three (15%) cases, deviation with lateral overlapping segments in 11 (55%) cases, and deviation without overlapping in six (30%)

**Table 1: Fracture level**

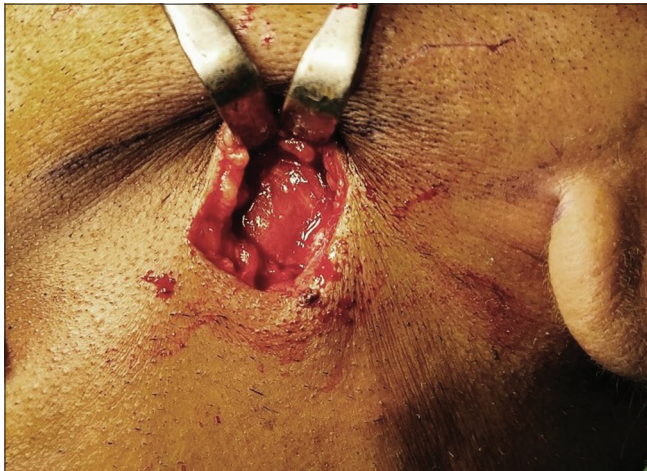Level of fracture	Frequency (number of cases)	Total (%)
Condylar head		
Group 1	1	1 (5)
Group 2	0	
Condylar neck		
Group 1	7	9 (45)
Group 2	2	
Condylar base		
Group 1	2	10 (50)
Group 2	8	



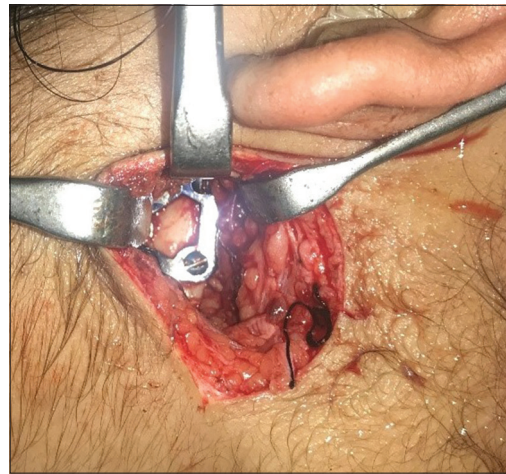
**Figure 1:** Suture through the substance of parotid capsule in the retromandibular approach



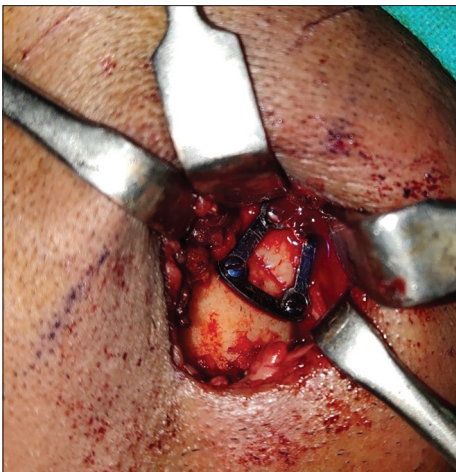**Figure 2:** Incision marking for periangular transmasseteric incision



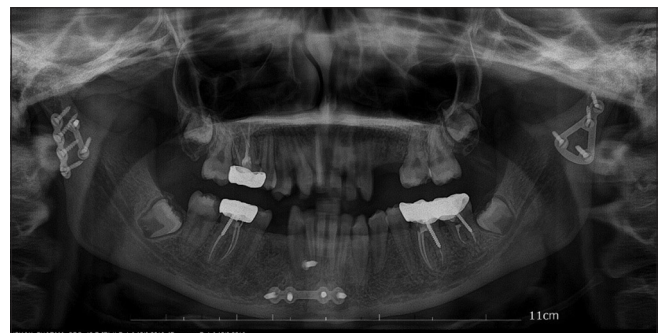
**Figure 3:** Exposure of masseter muscle in the periangular transmasseteric approach



**Figure 4:** Fixation of fracture site with delta plate in the retromandibular approach



**Figure 5:** Fixation of fracture site with trapezoidal condylar plate in the periangular transmasseteric approach



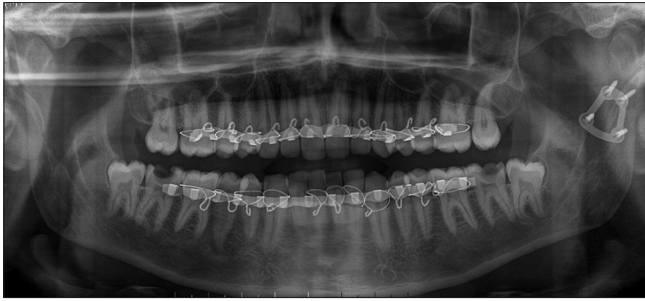
**Figure 6:** Bilateral fracture fixation with two miniplates and delta plate through retromandibular approach (radiograph)

cases. It was observed that Group 1 included three fractures with medial overlap, six fractures with lateral overlap, and one with no

overlap between the segments. Group 2 included five fractures with lateral overlap and five fractures with no overlap [Table 2].

In Group 2, lateral overlap  $>5$  mm was observed in five cases and five cases experienced anteromedial displacement  $>40^\circ$ .

The visibility and accessibility in Group 1 was good for 70% of the cases, fair in 20% of the cases with a medially displaced



**Figure 7:** Fixation with trapezoidal condylar plate through periangular transmasseteric approach (radiograph)

condylar neck fracture, and poor in 10% of the cases with a medially displaced condylar head fracture. The convenience of plating in Group 1 was good for 60% of the cases, fair in 30% of the cases, and poor in 10% of the cases [Table 3].

In Group 2, visibility and accessibility was good for 30% of the cases, fair in 60% of the cases, and poor in 10% of the cases. The convenience of plating in Group 2 was good for 30% of the cases, fair in 20% of the cases, and poor in 50% of the cases of condylar neck fracture with displacement.

Miniplates were utilized for fixation in eight cases of Group 1 and Group 2 each. Delta plates were used in two cases of Group 1. Trapezoidal condylar plate and strut plate were used in one case each of Group 2 on random selection [Figures 6 and 7].

The mean exposure time for Group 1 was 631 s and Group 2 was 557 s. The exposure time differed significantly ( $P = 0.048$ ) between the two surgical approaches, but the difference was not clinically significant. However, the difference in reduction and fixation time did not differ significantly between the two surgical techniques [Table 4].

The mean postoperative maximum mouth opening after 6 months in Group 1 was  $35.1 \pm 10$  mm and  $40.9 \pm 5$  mm in Group 2. During the 1<sup>st</sup> week postoperative evaluation, minor occlusal discrepancies were noticed in seven cases which were corrected with guiding elastics. On 1-month evaluation, occlusion was satisfactory in all the patients.

Scar perception was observed to be imperceptible (good) in 30% of Group 1 and slightly perceptible (fair) in rest of the cases. It was imperceptible (good) in 60% the cases of Group 2, slightly perceptible (fair) in 30% of the cases, and perceptible (poor) in 10% of the cases.

### Facial nerve injury

On postoperative facial nerve assessment, the zygomatic, buccal, and marginal mandibular branch of the facial nerve was involved in two cases of Group 1, whereas buccal and marginal mandibular branch of the facial nerve was involved in three cases of Group 2. Facial nerve recovery was observed in all the cases on 3-month follow-up except in one case of Group 1 which was associated with development of TMJ ankylosis.

Wound infection was seen in two cases of Group 2 which resolved under antibiotic coverage. Wound dehiscence

**Table 2: Deviation and displacement**

Change	Group 1	Group 2	Total (%)
Deviation with medial overlapping segments	3	0	3 (15.0)
Deviation with lateral overlapping segments	6	5	11 (55.0)
Displacement without overlapping	1	5	6 (30.0)
Total			20 (100.0)

**Table 3: Visibility and convenience of plating**

	Good	Fair	Poor	P
Visibility				
Group 1	7	2	1	>0.05
Group 2	3	6	1	(0.231)
Convenience of plating				
Group 1	6	3	1	>0.05
Group 2	3	2	5	(0.305)

was observed in one case of Group 2 which resolved with resuturing. Sialocele formation was observed in two cases of Group 1 which was managed with aspiration, pressure dressing, and antisialogogues for 2–4 weeks.

## DISCUSSION

Various approaches have been described as per the level of fracture in recent literature. Newman observed that the majority of the affected patients were in the second and third decades of life.<sup>[15]</sup> In the present study, the age ranged between 15 and 53 years, with an average age of 29 years. Wong and Badar illustrate that males commonly experienced condylar fracture.<sup>[16-18]</sup> The present study revealed that males are affected more commonly than females (3:1). Sawazaki *et al.* mentioned that road traffic accident was the most common cause of condylar fracture (55.33%).<sup>[19]</sup> In the present study, road traffic accidents were encountered in 60% of the cases, fall from height in 30% of the cases, and interpersonal violence in 10% of the cases. This consensus also tallies with a study by Ellis *et al.* which states that motor vehicle accidents attribute to 36.1%, fall: 36.3%, and assaults: 24.3% of condylar fractures.<sup>[20]</sup> Condylar fractures are generally caused by indirect force and considered as coup-contrecoup injuries. In a study performed by Mahgoub *et al.*, condylar fractures were associated with anterior mandibular fractures in 52.5%, angle 12.5%, body fractures 10%, and isolated condylar fracture in 25% of the cases.<sup>[21]</sup> In the present study, 75% of condylar fractures were associated with parasymphysis or mandibular body fractures and 20% of the cases experienced isolated condylar fracture. Unilateral condyle fractures are seldom associated with fractures of the zygomatic complex which was observed in one (5%) case, this can be explained due to direct lateral traumatic force and fracture of slender condylar neck.<sup>[22]</sup>

In a review of 175 condylar fractures by Reddy *et al.*, 50% of the cases were subcondylar, 31.45% were condylar neck,

**Table 4: Comparison of time taken between the groups**

Variable	Paired differences				Significant (two-tailed)
	Mean difference	SD	95% CI of the difference		
			Lower	Upper	
Pair 1: Exposure time	228.2	362.3	-31.0	487.4	0.048
Pair 2: Reduction time	-49.6	512.7	-416.3	317.1	0.767
Pair 3: Fixation time	-165.8	611.3	-603.1	271.5	0.413

SD=Standard deviation; CI=Confidence interval

and 18.54% were condylar head fractures.<sup>[23]</sup> Author observed 50% condylar base, 45% condylar neck, and 5% condylar head fracture, which is proportionate with the incidence in studies by Reddy *et al.* and Zachariades *et al.*<sup>[8]</sup>

Medial displacement of condylar fracture is commonly encountered due to the pull of lateral pterygoid muscle. Zachariades *et al.* reported medial displacement in 77% of the cases, lateral in 23% of the cases, and no contact in 7% of the cases.<sup>[8]</sup> In the current study, deviation with medial overlapping segments was seen in 15%, lateral overlapping in 55%, and deviation without overlapping in 30% of the cases.

Magnetic resonance imaging of condylar fracture may reveal medial displacement of the disc, especially in sagittal fracture. If it is not treated early, it can be associated with formation of fibrous adhesions between two raw surfaces leading to ankylosis.<sup>[24]</sup> In the present study, one case with medially displaced condylar head fracture required extracorporeal approach via retromandibular incision who developed TMJ ankylosis. Xiang *et al.* observed that surgically treated condylar fractures developed postoperative ankylosis in 5% of the cases which was limited to condylar head fracture with a damaged disc.<sup>[25]</sup>

Narayanan suggested that when the displacement is  $>35^\circ$  in either the coronal or the sagittal plane, there is compromised blood supply which requires ORIF to prevent malunion.<sup>[26]</sup> In the present study, six cases showed a deviation  $>40^\circ$ . Vertical overlap  $>4$  mm treated by the closed method can lead to persistent telescoping of the ramus, occlusal cant, and facial asymmetry.<sup>[27]</sup> Bindal *et al.* observed that if overlapping is  $<3.25 \pm 0.6$  mm, facial symmetry was not greatly affected.<sup>[28]</sup> In the current study, 14 cases had overlap  $>5$  mm which were managed by ORIF.

Good anatomical reduction leads to early return to function due to adaptation of dental and neuromuscular components.<sup>[29]</sup> Yang and Patil and Devlin *et al.* reported minor occlusal discrepancies in 8.5% of the cases and 4.7% of the cases, respectively, in retromandibular approach.<sup>[30,31]</sup> Özkan *et al.* reported one case of deteriorated occlusion, whereas Narayanan *et al.* reported satisfactory occlusion in all the cases treated with transmasseteric approach.<sup>[32,33]</sup> In the present study, two patients of the retromandibular group and five patients of the periangular transmasseteric group had minor occlusal discrepancy which were easily corrected with guiding elastics for a period of 7–15 days and did not require any surgical intervention.

Parihar *et al.* in a comparative study observed better mean mouth opening in the transparotid group (41.67 mm) than the periangular transmasseteric group (40.8) after 6 months.<sup>[34]</sup> The results of the present study in terms of mouth opening were more or less similar to the above-mentioned study which was 31–46 mm in retromandibular group (except one case which developed TMJ ankylosis) and 32–49 mm in periangular transmasseteric group.

The extracorporeal approach for fixation of severely displaced condylar fracture fragments was introduced by Nam in 1981 for accurate anatomical reduction.<sup>[35]</sup> It is commonly associated with complications such as avascular necrosis, condylar resorption, arthrosis due to the loss of periosteal blood supply, detachment from the lateral pterygoid muscle, and injury to the disc.<sup>[36]</sup> In the present study, one case with a condylar head fracture in retromandibular group required an extracorporeal approach and later presented with clinical and radiographic sign of TMJ ankylosis.

Adequate visualization of the anterior and posterior borders of the condylar segments as well as position of the condylar head in the glenoid fossa is the prerequisite for accurate anatomical reduction and fixation. Yang and Patil observed adequate visibility in 29% of condylar neck and 71% of subcondylar fractures with retromandibular approach and excellent accessibility.<sup>[30]</sup> Accessibility to the fracture site is required for proper instrumentation, anatomical reduction, protection of the surrounding vital structures, and fixation. Narayanan *et al.* observed that the periangular transmasseteric approach offers excellent access to the fractured condyle.<sup>[33]</sup>

In the present study, the visibility and accessibility in retromandibular group was good for 70% of the cases, fair in 20% of displaced condylar neck fractures, and poor in 10% of condylar head fractures. Ease of fixation was adequate for miniplates as well as delta plates except one case of condylar head which required extracorporeal approach. In the periangular transmasseteric group, visibility and accessibility was good for 30% of the cases, fair in 60% of the displaced condylar fracture with medial or lateral displacement, and poor in 10% of the high condylar neck fractures. Inadequate visibility was observed when the fracture segment was displaced medially and in condylar neck fracture despite use of miniplates, trapezoidal condylar plate, or strut plate. Surgeons also observed that perpendicular placement of screws in the fractured proximal stump was difficult in condylar neck fracture

compared to retromandibular approach. This shortcoming can be overcome by the application of the angulated system.

Excessive duration of exposure not only increases the chances of infection but also increases fatigue for the surgeons. In the current study, the mean time for exposure with retromandibular and periangular approach was 10 min 31 s and 9 min 17 s, respectively, which was statistically significant ( $P = 0.048$ ) but not clinically. In a study by Kshirsagar *et al.*, the average duration of surgery was 32 min with retromandibular approach.<sup>[37]</sup> Trost *et al.* observed that the mean time taken for surgery was 45 min with high cervical periangular transmasseteric anteroparotid approach.<sup>[38]</sup> In the present study, the mean time taken for completion of surgical procedure was 43 min 40 s and 46 min 5 s in retromandibular approach and periangular approach, respectively, which was comparable with Kshirsagar *et al.* and Trost *et al.*<sup>[37,38]</sup>

Bouchard and Perreault reported 11.9% of the cases of infection associated with retromandibular approach, whereas in the present study no case of infection was observed with retromandibular approach.<sup>[39]</sup> Trost *et al.* reported 2.6% incidence of infection with periangular approach, whereas in the present study, wound infection was encountered in 20% of the cases which resolved with debridement and antibiotic coverage.<sup>[38]</sup> Among these cases, one patient with a history of substance abuse and alcoholism required second surgery for debridement and removal of implant. Koshy *et al.* reported that the incidence of infection increases (60%–72%) after ORIF in chronic smokers, alcoholics, and substance abusers.<sup>[40]</sup>

Bouchard and Perreault and Yang and Patil reported 3.4% and 8% incidence of salivary fistulae formation, respectively, with retromandibular approach.<sup>[30,39]</sup> In the present study, sialocele formation was observed in 20% of the cases of retromandibular group and none in periangular group, as the dissection through the substance of parotid gland was avoided. During the initial phase of the study, two cases of sialocele formation were encountered, and thereafter, care was taken to perform water tight closure of parotid capsule by passing a suture through the capsule during dissection which allows meticulous closure. After undertaking this maneuver, no case of sialocele was noticed.

Ellis *et al.* reported unesthetic scars in 7.5% of cases with retromandibular approach.<sup>[41]</sup> Parihar *et al.* observed hypertrophic scar formation in 17% of cases of transparotid approach and none in periangular approach.<sup>[34]</sup> As the retromandibular approach is designed to place the incision in the posterior ramal shadow, none of the patients in the present study complained about esthetics of scar. On operator observation, imperceptible scar (good) was noticed in 30% of the cases and slightly perceptible (fair) in 70% of the cases. In the periangular approach, on patient's observation, scar was imperceptible (good) in 60% of the cases and slightly perceptible (fair) in 30% of the cases. One patient who was more concerned about esthetics of scar despite it being hidden in the neck crease, but he declined secondary revision.

The chances of injury to the branches of the facial nerve is a common limitation of surgical approaches to the condylar process. The preauricular approach has been associated with a wide range of incidence of facial nerve injury (3.2%–42.9%).<sup>[42,43]</sup> The submandibular approach is preferred for reduction and fixation of low subcondylar and mandibular angle fractures but with reported (5.3%–48.1%) incidence of facial nerve injury.<sup>[44]</sup> Intraoral approaches may put the facial nerve at risk, particularly with the use of transfacial trocars.<sup>[45]</sup>

Bouchard and Perreault reported a 22% incidence of temporary facial nerve paresis with retromandibular approach which recovered within 6 months. Only one case was reported with permanent facial nerve palsy after 5 years.<sup>[39]</sup> The incidence of permanent facial nerve injury is rare and has been reported by Handschel *et al.* in submandibular approach and Iizuka *et al.*<sup>[46,47]</sup> Yang and Patil and Bhutia *et al.* reported 16.6% and 20% incidence of facial nerve injury with retromandibular approach, respectively.<sup>[30]</sup> The buccal nerve was most frequently involved followed by the marginal mandibular nerve which took around 6 months to recover.<sup>[48]</sup>

Wilson *et al.* described the transmasseteric approach, which reduced the occurrence of salivary fistula and damage to the facial nerve.<sup>[12]</sup> According to Yang and Bhutia *et al.*, the increased incidence of facial nerve injury was encountered when the fractured condylar segment was medially displaced or dislocated out of the glenoid fossa, as the reduction puts greater traction on branches of the facial nerve leading to neuropraxia or axonotmesis.<sup>[30,48]</sup> According to Raveh *et al.*, excessive traction by the retractors or electrocauterization of vessels close to the facial nerve primarily causes injury to the nerve.<sup>[49]</sup> Functional recovery in neuropraxia occurs within 0–12 weeks. However, during the postoperative period, as edema increases, the inflow of nutrients to the nerve decreases. This results in axonal death (axonotmesis) and retrograde degeneration. However, the endoneurium stays intact and axons regrow through the channels which leads to late recovery of function (3–6 months).<sup>[50]</sup>

In the present study on postoperative facial nerve assessment, the zygomatic, buccal, and marginal mandibular branches were injured in two cases of retromandibular approach which recovered within 3 months except in one case which was also associated with the development of signs of TMJ ankylosis.

Trost *et al.* showed that the damage to the facial nerve can be minimized if a transmasseteric approach is used.<sup>[38]</sup> During the periangular transmasseteric approach, the masseter muscle is exposed as it lies covered with the parotidomasseteric fascia, at this point of dissection, the branches of facial nerve run underneath the masseteric fascia. As the masseter is incised and retracted posteriorly and superiorly, the branches of facial nerve which lie under the fascia may get injured due to traction. In case of parotid hypertrophy, incision of the masseter can extend under the gland further increasing the likelihood of injury to the branches of the facial nerve.<sup>[13]</sup> In the present study, the periangular transmasseteric group required greater retraction

in displaced fractures of the condylar neck and base which resulted in transient traction injury of buccal and marginal mandibular branches in three cases.

This study is in conjunction with the observations of Neff that the periangular approach is most suited for the management of condylar fractures up to the height of sigmoid notch with minimal injury to the facial nerve.<sup>[51]</sup> On the other hand, the retromandibular approach can be applied for condylar fracture reduction with minimal morbidity to the facial nerve irrespective of the level of fracture as has been reported by Al-Moraissi *et al.*<sup>[52]</sup>

## CONCLUSION

The results of the present study conclude that both the approaches are equally effective for ORIF of condylar base fractures but displaced condylar neck fractures, the retromandibular approach is preferable due to limited access and difficult instrumentation with periangular transmasseteric approach. Large sample size and multicentric study may further shed light on the findings of the current study.

## Declaration of patient consent

The authors certify that they have obtained all appropriate patient consent forms. In the form, the patients have given their consent for their images and other clinical information to be reported in the journal. The patients understand that their names and initials will not be published and due efforts will be made to conceal their identity, but anonymity cannot be guaranteed.

## Financial support and sponsorship

Nil.

## Conflicts of interest

There are no conflicts of interest.

## REFERENCES

- Balaji SM. Modified endaural approach for the treatment of condylar fractures: A review of 75 cases. *Indian J Dent Res* 2016;27:305-11.
- Silvenoinen U, Iizuka T, Lindqvist C, Oikarinen K. Different patterns of condylar fractures: An analysis of 382 patients in a 3-year period. *J Oral Maxillofac Surg* 1992;50:1032-7.
- Villarreal PM, Monje F, Junquera LM, Mateo J, Morillo AJ, González C. Mandibular condyle fractures: Determinants of treatment and outcome. *J Oral Maxillofac Surg* 2004;62:155-63.
- Zhou JH, Ren CQ. A preauricular long-corniform approach for open reduction and internal fixation of mandibular condylar fractures. *J Craniomaxillofac Surg* 2013;41:359-66.
- Haug RH, Assael LA. Outcomes of open versus closed treatment of mandibular subcondylar fractures. *J Oral Maxillofac Surg* 2001;59:370-5.
- Choi KY, Yang JD, Chung HY, Cho BC. Current concepts in the mandibular condyle fracture management Part II: Open reduction versus closed reduction. *Arch Plast Surg* 2012;39:301-8.
- Zide MF, Kent JN. Indications for open reduction of mandibular condyle fractures. *J Oral Maxillofac Surg* 1983;41:89-98.
- Zachariades N, Mezitis M, Mourouzis C, Papadakis D, Spanou A. Fractures of the mandibular condyle: A review of 466 cases. Literature review, reflections on treatment and proposals. *J Craniomaxillofac Surg* 2006;34:421-32.
- Shi J, Yuan H, Xu B. Treatment of mandibular condyle fractures using a modified transparotid approach via the parotid mini-incision: Experience with 31 cases. *PLoS One* 2013;8:e83525.
- Ebenezer V, Ramalingam B. Comparison of approaches for the rigid fixation of sub-condylar fractures. *J Maxillofac Oral Surg* 2011;10:38-44.
- Hinds EC, Girotti WJ. Vertical subcondylar osteotomy: A reappraisal. *Oral Surg Oral Med Oral Pathol* 1967;24:164-70.
- Wilson AW, Ethunandan M, Brennan PA. Transmasseteric antero-parotid approach for open reduction and internal fixation of condylar fractures. *Br J Oral Maxillofac Surg* 2005;43:57-60.
- Lutz JC, Clavert P, Wolfram-Gabel R, Wilk A, Kahn JL. Is the high submandibular transmasseteric approach to the mandibular condyle safe for the inferior buccal branch? *Surg Radiol Anat* 2010;32:963-9.
- Meyer C, Kahn JL, Boutemi P, Wilk A. Photoelastic analysis of bone deformation in the region of the mandibular condyle during mastication. *J Craniomaxillofac Surg* 2002;30:160-9.
- Newman L. A clinical evaluation of the long-term outcome of patients treated for bilateral fracture of the mandibular condyles. *Br J Oral Maxillofac Surg* 1998;36:176-9.
- Wong KH. Mandible fractures: A 3-year retrospective study of cases seen in an oral surgical unit in Singapore. *Singapore Dent J* 2000;23:6-10.
- Badar MA, Syed SA. Etiology of mandibular condylar fractures; a study from tertiary care hospital of Lahore. *Pak Oral Dent J* 2014;34:42-5.
- Mohamad AM. Transmasseteric anteroparotid approach for mandibular condylar fractures-merits and demerits. *Egypt J Plast Reconstr Aesthet Surg* 2011;35:227-32.
- Sawazaki R, Lima Júnior SM, Asprino L, Moreira RW, de Moraes M. Incidence and patterns of mandibular condyle fractures. *J Oral Maxillofac Surg* 2010;68:1252-9.
- Ellis E, Moos KF, El-Attar A. Ten years of mandibular fractures: An analysis of 2,137 cases. *Oral Med Oral Pathol Oral Surg*. 1985;59:120-9.
- Mahgoub MA, El-Sabbagh AH, Abd El-Latif EA, Elhadidy MR. Condylar fractures: Review of 40 cases. *Ann Maxillofac Surg* 2018;8:19-27.
- Oikarinen KS. Surgical versus nonsurgical treatment of unilateral dislocated low subcondylar fractures. Discussion. *J Oral Maxillofac Surg* 1994;52:360.
- Reddy NV, Reddy PB, Rajan R, Ganti S, Jhavar DK, Potturi A, *et al.* Analysis of patterns and treatment strategies for mandibular condyle fractures: Review of 175 condyle fractures with review of literature. *J Maxillofac Oral Surg* 2013;12:315-20.
- He D, Cai Y, Yang C. Analysis of temporomandibular joint ankylosis caused by condylar fracture in adults. *J Oral Maxillofac Surg* 2014;72:763.e1-9.
- Xiang GL, Long X, Deng MH, Han QC, Meng QG, Li B. A retrospective study of temporomandibular joint ankylosis secondary to surgical treatment of mandibular condylar fractures. *Br J Oral Maxillofac Surg* 2014;52:270-4.
- Narayanan V. Anterior parotid-transmasseteric approach for fixation and reduction of condylar fractures. *Int J Oral Maxillofac Surg* 2007;36:1072-3.
- Marker P, Nielsen A, Bastian HL. Fractures of the mandibular condyle. Part 2: Results of treatment of 348 patients. *Br J Oral Maxillofac Surg* 2000;38:422-6.
- Bindal M, Joshi A, Bhat A, Anehsur V. Are facial asymmetry and condylar displacement associated with ramal height and treatment outcomes in unilateral condylar fracture when managed by the closed method? *J Oral Maxillofac Surg* 2019;77:789.
- Ellis E 3<sup>rd</sup>, Throckmorton G. Facial symmetry after closed and open treatment of fractures of the mandibular condylar process. *J Oral Maxillofac Surg* 2000;58:719-28.
- Yang L, Patil PM. The retromandibular transparotid approach to mandibular subcondylar fractures. *Int J Oral Maxillofac Surg* 2012;41:494-9.
- Devlin MF, Hislop WS, Carton AT. Open reduction and internal fixation of fractured mandibular condyles by a retromandibular approach: Surgical morbidity and informed consent. *Br J Oral Maxillofac Surg* 2002;40:23-5.
- Özkan HS, Sahin B, Görgü M, Melikoglu C. Results of transmasseteric anteroparotid approach for mandibular condylar fractures. *J Craniofac*

- Surg 2010;21:1882-3.
33. Narayanan V, Ramadorai A, Ravi P, Nirvikalpa N. Transmasseteric anterior parotid approach for condylar fractures: Experience of 129 cases. *Br J Oral Maxillofac Surg* 2012;50:420-4.
  34. Parihar VS, Bandyopadhyay TK, Chattopadhyay PK, Jacob SM. Retromandibular transparotid approach compared with transmasseteric anterior parotid approach for the management of fractures of the mandibular condylar process: A prospective randomised study. *Br J Oral Maxillofac Surg* 2019;57:880-5.
  35. Nam IW. The condylar head and upper condylar neck fractures treated by Nam's method (III). *J Korean Acad Oral Surg* 1981;7:81-90.
  36. Gali R, Devireddy SK, Venkata KK, Kanubaddy SR, Nemaly C, Dasari M. Preauricular transmasseteric anteroparotid approach for extracorporeal fixation of mandibular condyle fractures. *Indian J Plast Surg* 2016;49:59-65.
  37. Kshirsagar R, Singh V, Pawar S, Shah R. Retromandibular approach in the management of condylar fractures by open reduction and internal fixation a prospective study. *Natl J Maxillofac Surg* 2015;6:180-4.
  38. Trost O, Trouilloud P, Malka G. Open reduction and internal fixation of low subcondylar fractures of mandible through high cervical transmasseteric anteroparotid approach. *J Oral Maxillofac Surg* 2009;67:2446-51.
  39. Bouchard C, Perreault MH. Postoperative complications associated with the retromandibular approach: A retrospective analysis of 118 subcondylar fractures. *J Oral Maxillofac Surg* 2014;72:370-5.
  40. Koshy JC, Feldman EM, Chike-Obi CJ, Bullocks JM. Pearls of mandibular trauma management. *Semin Plast Surg* 2010;24:357-74.
  41. Ellis E 3<sup>rd</sup>, McFadden D, Simon P, Throckmorton G. Surgical complications with open treatment of mandibular condylar process fractures. *J Oral Maxillofac Surg* 2000;58:950-8.
  42. Hammer B, Schier P, Prein J. Osteosynthesis of condylar neck fractures: A review of 30 patients. *Br J Oral Maxillofac Surg* 1997;35:288-91.
  43. Tang W, Gao C, Long J, Lin Y, Wang H, Liu L, *et al.* Application of modified retromandibular approach indirectly from the anterior edge of the parotid gland in the surgical treatment of condylar fracture. *J Oral Maxillofac Surg* 2009;67:552-8.
  44. Widmark G, Bågenholm T, Kahnberg KE, Lindahl L. Open reduction of subcondylar fractures. A study of functional rehabilitation. *Int J Oral Maxillofac Surg* 1996;25:107-11.
  45. Lachner J, Clanton JT, Waite PD. Open reduction and internal rigid fixation of subcondylar fractures via an intraoral approach. *Oral Surg Oral Med Oral Pathol* 1991;71:257-61.
  46. Handschel J, Rüggeberg T, Depprich R, Schwarz F, Meyer U, Kübler NR, *et al.* Comparison of various approaches for the treatment of fractures of the mandibular condylar process. *J Craniomaxillofac Surg* 2012;40:e397-401.
  47. Iizuka T, Lindqvist C, Hallikainen D, Mikkonen P, Pauku P. Severe bone resorption and osteoarthritis after miniplate fixation of high condylar fractures. A clinical and radiologic study of thirteen patients. *Oral Surg Oral Med Oral Pathol* 1991;72:400-7.
  48. Bhutia O, Kumar L, Jose A, Roychoudhury A, Trikha A. Evaluation of facial nerve following open reduction and internal fixation of subcondylar fracture through retromandibular transparotid approach. *Br J Oral Maxillofac Surg* 2014;52:236-40.
  49. Raveh J, Vuillemin T, Lädach K. Open reduction of the dislocated, fractured condylar process: Indications and surgical procedures. *J Oral Maxillofac Surg* 1989;47:120-7.
  50. Selesnick SH, Patwardhan A. Acute facial paralysis: Evaluation and early management. *Am J Otolaryngol* 1994;15:387-408.
  51. Neff A. Open reduction and internal fixation in temporomandibular joint traumatology: Current concepts and future perspectives. *Stomatological Dis Sci* 2019;3:2.
  52. Al-Moraissi EA, Louvrier A, Colletti G, Wolford LM, Biglioli F, Ragaey M, *et al.* Does the surgical approach for treating mandibular condylar fractures affect the rate of seventh cranial nerve injuries? A systematic review and meta-analysis based on a new classification for surgical approaches. *J Cranio Maxillofac Surg* 2018;46:398-412.