



CASE REPORT

# Thymoma with immunodeficiency with multiple recurrent oral herpetic infections



Yavuz Sinan Aydintug<sup>a</sup>, Gurkan Rasit Bayar<sup>a\*</sup>, Aydin Ozkan<sup>a</sup>,  
Omer Gunhan<sup>b</sup>, Ugur Musabak<sup>c†</sup>

<sup>a</sup> Department of Oral and Maxillofacial Surgery, Gulhane Military Medical Academy, Ankara, Turkey

<sup>b</sup> Department of Pathology, Gulhane Military Medical Academy, Ankara, Turkey

<sup>c</sup> Department of Immunology, Gulhane Military Medical Academy, Ankara, Turkey

Final revision received 7 October 2012; accepted 14 October 2012

Available online 17 December 2012

## KEYWORDS

herpes simplex virus;  
hypogammaglobulinemia;  
opportunistic infection;  
thymoma

**Abstract** Thymomas with immunodeficiency (formerly Good's syndrome) are a rare acquired disease of combined T- and B-cell immunodeficiency accompanying a thymoma. Recurrent opportunistic infections associated with disorders of both humoral and cell-mediated immunity frequently accompany this rare primary, adult-onset immunodeficiency. This is a report of a case of a thymoma with immunodeficiency in a 65-year-old male patient who developed recurrent oral herpetic infections. He consulted us about recurrent vesiculo-ulcerative lesions on his tongue, lower lip, and buccal mucosa. Results of laboratory examinations indicated hypogammaglobulinemia accompanied by diminished B cells in the peripheral blood, which is consistent with the characteristic features of a thymoma with immunodeficiency. After a diagnosis confirming herpes simplex virus infection, systemic antiviral therapy was administered, which was effective for his vesiculo-ulcerative lesions at follow-up. When an intractable infection accompanied by a thymoma is encountered, increased awareness about the clinical and immunological profiles of this primary immunodeficiency may help in its early diagnosis, thereby preventing mortality.

Copyright © 2012, Association for Dental Sciences of the Republic of China. Published by Elsevier Taiwan LLC. This is an open access article under the CC BY-NC-ND license (<http://creativecommons.org/licenses/by-nc-nd/4.0/>).

## Introduction

Although thymomas are the most frequently encountered primary neoplasm in the anterior mediastinum in adult patients, they are actually rare malignant neoplasms.<sup>1</sup> Immunodeficiency syndrome associated with a thymoma was first reported by Good and colleagues in 1954 and was

\* Corresponding author. Department of Oral and Maxillofacial Surgery, Gulhane Military Medical Academy, Etlük 06018, Ankara, Turkey.

E-mail address: [gurkanbayar@yahoo.com](mailto:gurkanbayar@yahoo.com) (G.R. Bayar).

† Declarations: Funding: None; Ethical Approval: Not required

1991-7902/\$36 Copyright © 2012, Association for Dental Sciences of the Republic of China. Published by Elsevier Taiwan LLC. This is an open access article under the CC BY-NC-ND license (<http://creativecommons.org/licenses/by-nc-nd/4.0/>).

<http://dx.doi.org/10.1016/j.jds.2012.10.005>

commonly referred to as Good's syndrome.<sup>2</sup> However, the current classification (2007) of the International Union of Immunological Societies replaced this old eponym with "thymoma with immunodeficiency" and lists it as a primary immunodeficiency.<sup>2</sup>

This syndrome is a rare acquired disease of combined T- and B-cell immunodeficiency accompanying a thymoma and has an incidence rate of approximately 6–11% in thymoma cases.<sup>3</sup> The affected patients are most commonly between 40 and 70 years of age and have a thymoma, fewer or no B cells in the peripheral blood, hypogammaglobulinemia, inversion of the CD4-to-CD8 ratio, and defects in cell-mediated immunity.<sup>1,4</sup> Patients with this primary immunodeficiency are at increased risk of developing severe opportunistic infections including herpes simplex virus (HSV)-related infections.<sup>2</sup>

HSV infections represent one of the most widespread infections of the orofacial region. HSV type 1 and type 2 (HSV-1 and HSV-2) are two strains of the herpes virus family, the Herpesviridae, which infect humans. These two viruses can infect the mouth or genitals; generally, HSV-1 is considered to infect the regions "above the waist", while HSV-2 is considered to infect the region "below the waist". Although most of the primary orofacial HSV infections are caused by HSV-1, infection by HSV-2 is increasingly common.<sup>5</sup> A primary HSV-1 infection in oral and perioral sites usually manifests as gingivostomatitis, whereas reactivation of the virus in the trigeminal sensory ganglion gives rise to mild cutaneous and mucocutaneous disease, which is often termed as recurrent herpes labialis. However, recurrent HSV-1 infection in the mouth is less common than herpes labialis and is unusual in otherwise healthy persons.<sup>6</sup> In immunocompromised patients, recurrent oral HSV infections are described as "atypical" and the lesions are more extensive and aggressive, slow or nonhealing, and extremely painful.<sup>7</sup> Recurrent herpetic infections of the tongue are exceptional and are only encountered in patients with immunodeficiency.<sup>8</sup>

Herein, we report a case of a thymoma with immunodeficiency in a patient who developed excessive recurrent oral herpetic infections.

## Case presentation

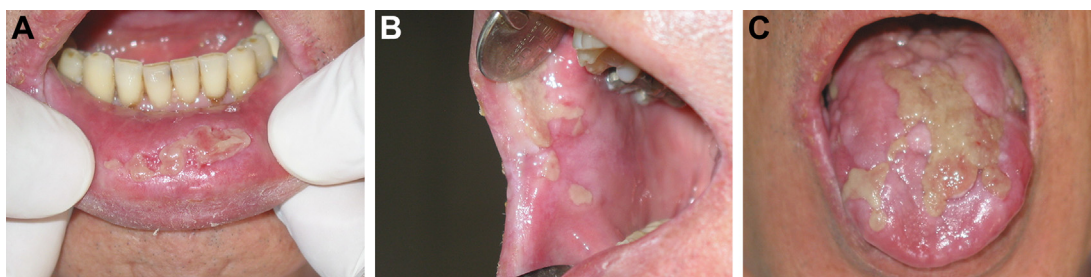In October 2009, a 65-year-old man consulted us because he had been suffering from recurrent vesiculo-ulcerative

lesions of his tongue, lower lip, and buccal mucosa for approximately 4 years; he had been treated for a clinical diagnosis of lichen planus and fungal infection. He had a history of a thymoma first identified by a computed tomography scan after a traffic accident in 2003 and of an extended thymectomy for the thymoma removal in March 2007. Results of a histopathological analysis revealed "type AB medullary thymoma" (according to the Masaoka system of staging, the tumor was at stage II due to microscopic invasion into the capsule). His medical history also showed that he had received adjuvant (preventive) radiation therapy as a microscopic monitoring of the invasion [5000 cGy in 25 sessions (1 session = 200 cGy administration)] in June 2007 and was treated for a prolonged fever of unknown origin with antibiotics and antipyretics in August and September 2007. In addition, he reported chronic diarrhea, which began about a year ago and is ongoing.

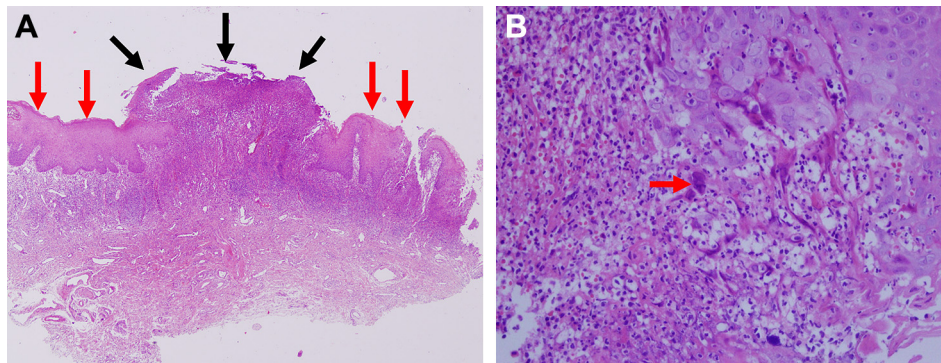
The patient was admitted to our hospital in October 2009. Upon admission, he had a discrete erosive lesion covered by a yellowish-white fibrinous exudate with surrounding mucosal erythema on the lower lip (Fig. 1A) and buccal mucosa (Fig. 1B), and the well-demarcated, indurated, and thickened yellowish-white plaques and nodules on the dorsal tongue (Fig. 1C). Regional lymphadenopathy was present. Written consent was obtained from the patient, and owing to the atypical clinical presentation, a biopsy was performed under local anesthesia. An oral biopsy specimen was taken from the tongue.

A histological analysis revealed the following marked hyperplastic changes in the mucosal epithelium: mainly irregular acanthosis, parakeratosis, edema, and lymphocyte exocytosis (Fig. 2A). In addition, there were ulcerated vesicles. Near the ulcerated areas, characteristic virus-infected keratinocytes were observed along the basal layer of the epithelium. They were large cells with homogenous eosinophilic cytoplasm and mummified chromatin with a thick nuclear membrane. Multinucleation and nuclear molding were frequent (Fig. 2B).

Blood samples were collected on the same day. Results of a laboratory examination revealed the following: white blood cell count, 4600/mm<sup>3</sup>; hemoglobin, 12.2 g/dL; platelet count, 152,000/mm<sup>3</sup>; C-reactive protein, 10.6 mg/L; total protein, 6.21 g/L; and albumin of 4.48 g/dL. Laboratory data included the following: low immunoglobulin G (IgG), 5.91 g/L (normal: 800–1600 mg/dL); IgA, 0.25 g/L (normal: 80–400 mg/dL); and IgM, 0.17 g/L (normal: 50–180 mg/dL). A lymphocyte subset analysis of



**Figure 1** (A) Discrete erosive lesion covered by a yellowish-white fibrinous exudate with surrounding mucosal erythema on the lower lip labial mucosa; (B) appearance of the right buccal mucosa before treatment; and (C) well-demarcated, indurated, and thickened yellowish-white plaques and nodules on the dorsal tongue.



**Figure 2** (A) Histological analysis revealed ulceration (black arrows) in the center of the sample due to a ruptured herpetic bullous lesion, and surrounding oral mucosal epithelium showing hyperplastic changes characterized by irregular acanthosis and parakeratosis (red arrows; hematoxylin and eosin (H&E), 40 $\times$ ). (B) In zones surrounding the ulcerated area, keratinocytes with viral cytopathic changes such as multinucleation, nuclear molding, and mummified chromatin (red arrow) can be seen (H&E, 200 $\times$ ).

the peripheral blood was performed using flow cytometry. The percentage of CD19<sup>+</sup> B cells (0.1%) was found to be lower than the normal range (7–23%). Although percentages of CD3<sup>+</sup> (60.7%; normal: 62.8–85.0%) and CD4<sup>+</sup> T cells (20.1%; normal: 34.0–63.8%) were low, the percentage of CD8<sup>+</sup> T cells (39.7%) was within the normal range (normal: 19–48%). As a result, a reduced CD4-to-CD8 ratio of 0.50 was found (normal: 0.67–3.11). Results of HIV1/2 serologic screening were negative. With regard to the type-specific HSV serologic screening, the HSV-1 IgG titer was 1.83 (normal: 0–1) sample/cutoff, and the HSV-2 IgG titer was 0.24 (normal: 0–1) sample/cutoff.

The final diagnosis was that of HSV-1 infection. Upon diagnosis, oral systemic antiviral therapy (200 mg acyclovir every 4 hours, 5 times daily) was administered for 10 days. After 2 weeks, complete healing of the lesions on the lower lip (Fig. 3A) and buccal mucosa (Fig. 3B) was observed, while there was a partial healing of the lesion on the tongue (Fig. 3C). Meanwhile, the patient consulted with the Department of Immunology. Immunodeficiency due to a thymoma with immunodeficiency explained why the recurrent oral HSV-1 infection had been intractable for several years. Thus, prophylactic intravenous immunoglobulin (IVIg) therapy and routine control of infections in the patient were initiated by the Department of Immunology.

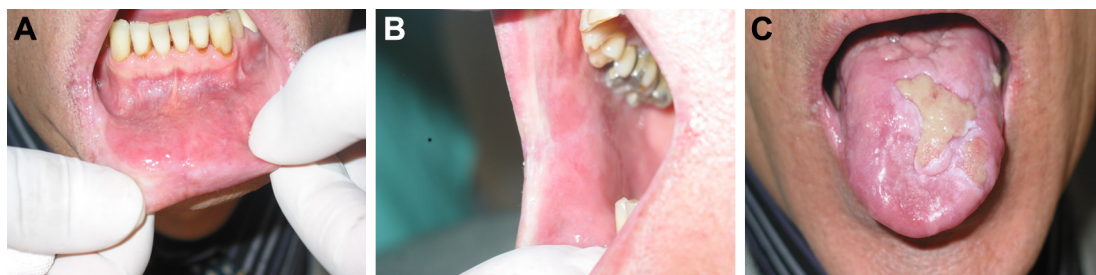## Discussion

In general, symptoms of Good's syndrome caused by humoral and cellular immunodeficiency are occasionally

complicated by leukopenia. Infections are one of the main characteristics of Good's syndrome.<sup>9</sup> The most commonly documented infectious complications in patients with a thymoma with immunodeficiency are recurrent upper and lower respiratory tract infections with encapsulated organisms.<sup>2,4</sup> Patients with a thymoma with immunodeficiency also have increased susceptibility to bacterial, fungal, viral, and opportunistic infections related to both humoral and cell-mediated immune deficiencies.<sup>4</sup> These infections may be severe or even fatal in patients with a thymoma with immunodeficiency.<sup>2</sup>

An extended thymectomy, radiation therapy, or chemotherapy are the available options for treating the thymoma in combination with Ig replacement therapy to maintain adequate IgG values to prevent opportunistic infections.<sup>3</sup> Unfortunately, there are no case reports of a thymectomy resolving the immunodeficient state associated with a thymoma with immunodeficiency.<sup>3</sup> Our patient had suffered from oral recurrent HSV infections for 2 years before the extended thymectomy. His thymoma with immunodeficiency had been diagnosed at least 4 years before the operation, and the thymectomy might not have resolved the immunodeficiency as previously reported.<sup>3</sup>

The prognosis of patients with a thymoma with immunodeficiency is thought to be worse than for those with other immunodeficiencies.<sup>4</sup> In contrast to a thymoma with immunodeficiency, the common variable immunodeficiency, which is also characterized by hypogammaglobulinemia, is associated with less frequent and less severe cellular immunodeficiency and fewer opportunistic



**Figure 3** (A and B) Complete healing of the lesions on the lower lip and buccal mucosa was observed. (C) Remarkable improvement in the lesion on the dorsal tongue was seen after treatment.

infections including HSV infection. In addition, the clinical presentation of HSV infection is usually atypical with a thymoma with immunodeficiency.<sup>2</sup> Immunological investigations, including quantitative Ig levels, B cells, and T-cell subsets, should be considered as a part of the routine diagnostic evaluation in patients with a thymoma and intractable infections. If immunologic test results are normal, testing should be performed periodically if the clinical suspicion of a thymoma with immunodeficiency persists, because there can be an interval between the diagnosis of immunodeficiency and/or a thymoma and development of infection.<sup>4</sup>

In immunocompromised patients, atypical clinical manifestations of HSV presenting as tumor-like nodules or condylomatous or hypertrophic lesions, rather than a classic ulcer may occur. Such unusual presentations increase the risk of a misdiagnosis and delays in appropriate treatment.<sup>10</sup> In this case report, we describe an immunocompromised patient with an unusual tumoral presentation of recurrent herpetic infections of the tongue. The predominant histopathological finding was marked hyperplastic changes with irregular acanthosis, parakeratosis, edema, and lymphocyte exocytosis. It is crucial to be aware of these unusual presentations to provide an early, correct diagnosis and effective treatment for HSV.

In immunocompromised groups, oral acyclovir seems to be the drug of choice for recurrent HSV-1 infections, but recently famciclovir was found to be effective and has the convenience of less frequent dosing than acyclovir.<sup>6</sup> Topical treatment for these patients is usually of little clinical benefit.<sup>6</sup> In our case, after the HSV infection was confirmed by histopathological, clinical, and laboratory examinations, considerable improvement with acyclovir therapy was seen in the intractable lesions. Furthermore, it was reported that IVIG substitution is indicated in all patients with a thymoma with immunodeficiency, as it may be associated with improved control of infections, decreased use of antibiotics, reduced hospitalizations, and perhaps improved survival in patients with a thymoma with

immunodeficiency and other hypogammaglobulinemic conditions.<sup>2</sup> For this reason, the patient was directed to the Department of Immunology for IVIG therapy and initiation of routine controls.

In conclusion, when an intractable infection accompanied by a thymoma is encountered, increased awareness about clinical and immunological profiles of this primary immunodeficiency may increase early diagnosis of this condition and prevent mortality.

## References

1. de Jesus NP, Carvalho PM, Dias FM, Gaspar EM, de Moura JJ. Dementia in a patient with thymoma and hypogammaglobulinaemia (Good's syndrome). *Cases J* 2008;1:90.
2. Méan M, Schaller MD, Asner S, et al. Thymoma, immunodeficiency, and herpes simplex virus infections. *Med Mal Infect* 2009;39:344–7.
3. Hanafusa T, Umegaki N, Yamaguchi Y, Katayama I. Good's syndrome (hypogammaglobulinemia with thymoma) presenting intractable opportunistic infections and hyperkeratotic lichen planus. *J Dermatol* 2010;37:171–4.
4. Kelesidis T, Yang O. Good's syndrome remains a mystery after 55 years: a systematic review of the scientific evidence. *Clin Immunol* 2010;135:347–63.
5. Arduino PG, Porter SR. Herpes simplex virus type 1 infection: overview on relevant clinico-pathological features. *J Oral Pathol Med* 2008;37:107–21.
6. Arduino PG, Porter SR. Oral and perioral herpes simplex virus type 1 (HSV-1) infection: review of its management. *Oral Dis* 2006;12:254–70.
7. Cohen SG, Greenberg MS. Chronic oral herpes simplex virus infection in immunocompromised patients. *Oral Surg Oral Med Oral Pathol* 1985;59:465–71.
8. Barrett AP. Chronic indolent orofacial herpes simplex virus infection in chronic leukemia: a report of three cases. *Oral Surg Oral Med Oral Pathol* 1988;66:387–90.
9. Ohuchi M, Inoue S, Hanaoka J, et al. Good syndrome coexisting with leukopenia. *Ann Thorac Surg* 2007;84:2095–7.
10. Mosunjac M, Park J, Wang W, et al. Genital and perianal herpes simplex simulating neoplasia in patients with AIDS. *AIDS Patient Care STDS* 2009;23:153–8.