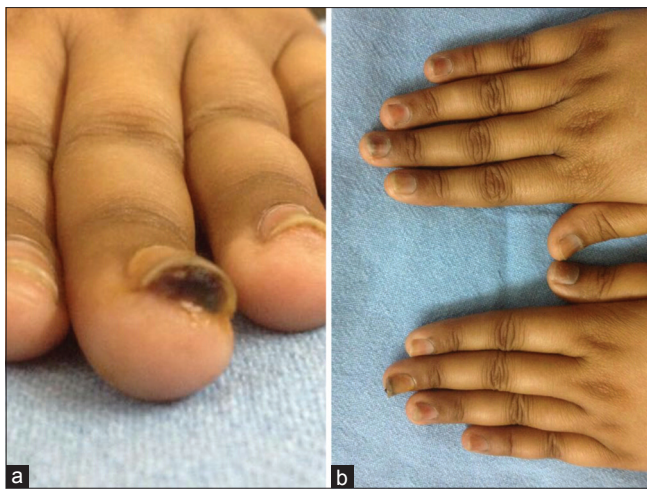

## Trastuzumab–Docetaxel Combination Chemotherapy Induced Severe Onychopathy

Sir,

Taxanes, which are inhibitors of tubulin function in mitosis and used as cancer chemotherapy, are well known to be associated with onychopathy. Trastuzumab, a recombinant DNA-derived humanized monoclonal antibody against the human epidermal growth factor receptor 2 protein (HER-2) is used in combination with taxanes in advanced stage HER-2 positive metastatic breast cancer.<sup>[1]</sup> We report the case of a 51-year-old post-menopausal Indian lady with metastatic carcinoma of the left breast (Estrogen/Progesterone receptor negative; HER2/Neu positive) who developed severe taxane–trastuzumab-induced onychopathy.

The lady, who was receiving adjuvant chemotherapy with trastuzumab–docetaxel combination (2 mg/kg and 70 mg/m<sup>2</sup>, respectively) presented with painful swelling of the digits with subungual deposition of blood and pus within a week of the 4<sup>th</sup> chemocycle. On examination, all nails revealed bulbous swellings with varying degrees of subungual hemorrhages and dystrophic changes [Figure 1a]. Nail changes included orange-brown discoloration of the nail plate, orange-red Beau's lines [Figure 1b], acute paronychia with subungual abscess formation, and varying degrees of hemorrhagic onycholysis [Figure 2a]. Fungal stains and fungal and bacterial cultures from the nail clippings and subungual pus were negative. Histopathology of the nail plate confirmed drug-induced acute inflammatory onychopathy. Docetaxel was stopped after the sixth cycle; oral antibiotics and anti-inflammatory drugs were prescribed, but trastuzumab was continued for the remaining 6 cycles.

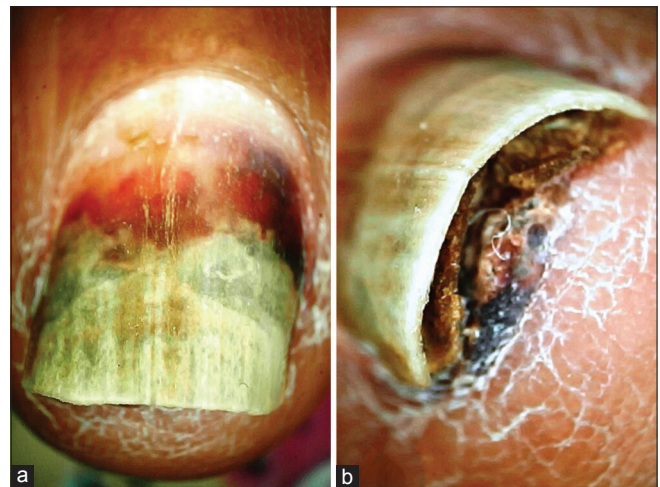


**Figure 1:** (a) Bulbous swellings of the finger tips with subungual hemorrhages. (b) Orange-brown discoloration of nail plate and orange-red Beau's line, with varying degrees of dystrophic changes and subungual abscess formation

However, her nails worsened, with formation of painful subungual hemorrhages and crusts [Figure 2b]. In view of the essentiality of chemotherapy, 6 more cycles of trastuzumab monotherapy were continued. Improvement in nails started only 6–8 weeks after the cessation of trastuzumab. It took 6 more months for complete recovery of the nails.

Cutaneous and nail toxicity constitute a well known adverse effect of all chemotherapeutic agents including taxanes, 5-fluorouracil, bleomycin, doxorubicin, etoposide, hydroxyurea, and vinca alkaloids, among others. Nail bed purpura, onycholysis, dyschromia, splinter hemorrhages, subungual abscess, Beau's lines, paronychia, hemorrhagic onycholysis, and the hand-and-foot syndrome constitute signs of drug-induced onychopathy.<sup>[2,3]</sup> Hemorrhagic onycholysis and subungual hematoma are rare but result in incapacitating functional disturbance, sometimes leading patients to withdraw from treatment.

Breast cancer expressing HER2/Neu receptor has a poor prognosis and a combination adjuvant chemotherapy with docetaxel and trastuzumab forms its first line of treatment.<sup>[1]</sup> Among chemotherapeutic agents, nail toxicity is strikingly more with docetaxel.<sup>[2,3]</sup> Docetaxel, which acts via inhibition of microtubule formation, can result in subungual hemorrhages, orange-brown discoloration, onycholysis, Beau's lines, acute paronychia, subungual abscess, and transverse loss of nail.<sup>[2,3]</sup> Trastuzumab also results in significant cutaneous adverse drug reactions. In a retrospective study of 51 cases who underwent trastuzumab-containing chemotherapy, 25 (49%) had skin toxicity, 14 (27.5%) had nail toxicity, and 12 (23.5%)



**Figure 2:** (a) Hemorrhagic onycholysis and paronychia of a finger nail. (b) Subungual hemorrhagic crust with onycholysis of finger nail despite cessation of docetaxel

had both.<sup>[4]</sup> Nail toxicity include softening, thinning or loss, paronychia, and discoloration. The nail changes in our patient are best explained by combined toxicity of docetaxel and trastuzumab. First, the constellation of Beau's lines, onycholysis, paronychia with subungual abscesses and hemorrhagic crusts, all occurring together in a single patient is rare with the use of single-agent taxane. Second, in the present case, florid nail changes surfaced within 4 chemocycles, even though the median onset of isolated taxane-induced nail changes is 12 weeks. Third, spontaneous resolution of nail changes despite continued treatment with taxanes was observed.<sup>[5]</sup> In the current case, the nail-related morbidity became worse even after stopping docetaxel, and improvement started only 6 weeks after cessation of trastuzumab. Thus, the contribution of trastuzumab to burden of nail dystrophy in addition to docetaxel is highly plausible.

Alexandrescu *et al.* first reported the trastuzumab/taxane combination-induced nail dystrophy and postulated a potential synergistic effect of the two drugs.<sup>[6]</sup> Nail matrix proliferation is disrupted (with resultant nail plate abnormalities) by drugs such as paclitaxel that arrest the cell cycle at the G2-M phase junction; whereas nail bed growth disruption (with resultant onycholysis) stems from the toxic effect of docetaxel that acts in different phases of the cell cycle. Alexandrescu *et al.* attributed the synergy of nail destruction with docetaxel–trastuzumab combination to trastuzumab-induced disturbed expression of Her-2/Neu proto-oncogene in normal human epithelial tissues resulting in disrupted keratinocyte differentiation and the overlapping cell growth inhibitory effect of both the drugs during the S-phase of cell cycle.<sup>[6]</sup> The antiangiogenic effect, common to both the drugs, adds on to the dystrophic changes.

Management/preventive measures in such cases include reducing the frequency of chemotherapy cycles, application of opaque nail hardeners (photoprotective effect), and the use of frozen hand glove or foot sleeper.<sup>[7]</sup> Care of already dystrophic nails remains conservative. Nail plate avulsion or decompression is required in severe cases. This report reiterates the propensity of the taxane–trastuzumab combination in producing such severe nail destruction, and emphasizes the importance of physician's awareness of this complication for early identification and patient counseling.

### Financial support and sponsorship

Nil.

### Conflicts of interest

There are no conflicts of interest.

Sidharth Sonthalia, Rahul Arora<sup>1</sup>,  
Ashu Abhishek<sup>2</sup>

Department of Dermatology, Skinnocence:  
The Skin Clinic and Research Centre, Gurgaon, Haryana, <sup>1</sup>Department of  
Dermatology, University  
College of Medical Sciences, Shahdara, New Delhi,  
<sup>2</sup>Department of Radiation Oncology, Medanta Medicity,  
Gurgaon, Haryana, India


### Address for correspondence:

Dr. Sidharth Sonthalia,  
Department of Dermatology, Skinnocence: The Skin Clinic and Research  
Centre, Gurgaon - 122 009, Haryana, India.  
E-mail: sidharth.sonthalia@gmail.com

### References

- Swain SM, Im YH, Im SA, Chan V, Miles D, Knott A, *et al.* Safety profile of Pertuzumab with Trastuzumab and Docetaxel in patients from Asia with human epidermal growth factor receptor 2-positive metastatic breast cancer: Results from the phase III trial CLEOPATRA. *Oncologist* 2014;19:693-701.
- Bonny M, Buyse V, Brochez L. Dermatological side effects of current and upcoming targeted therapies in oncology. *Acta Clin Belg* 2011;66:97-103.
- Minisini AM, Tosti A, Sobrero AF, Mansutti M, Piraccini BM, Sacco C, *et al.* Taxane-induced nail changes: Incidence, clinical presentation and outcome. *Ann Oncol* 2003;14:333-7.
- Adachi S, Yoshimura T, Matsuoka T, Okada K, Yasuda T, Kamei K. Appearance of skin and nail toxicity in patients with breast cancer who underwent trastuzumab-containing chemotherapy. *Gan To Kagaku Ryoho* 2011;38:1453-6.
- Flory SM, Solimando DA Jr, Webster GF, Dunton CJ, Neufeld JM, Haffey MB. Onycholysis associated with weekly administration of paclitaxel. *Ann Pharmacother* 1999;33:584-6.
- Alexandrescu DT, Vaillant J, Wiernik PH. Trastuzumab/docetaxel-induced nail dystrophy. *Int J Dermatol* 2006;45:1334-6.
- Scotté F, Tourani JM, Banu E, Peyromaure M, Levy E, Marsan S, *et al.* Multicenter study of a frozen glove to prevent docetaxel-induced onycholysis and cutaneous toxicity of the hand. *J Clin Oncol* 2005;23:4424-9.

This is an open access article distributed under the terms of the Creative Commons Attribution-NonCommercial-ShareAlike 3.0 License, which allows others to remix, tweak, and build upon the work non-commercially, as long as the author is credited and the new creations are licensed under the identical terms.

Access this article online	
<b>Website:</b> www.idoj.in	<b>Quick Response Code</b> 
<b>DOI:</b> 10.4103/idoj.IDOJ_485_15	

**How to cite this article:** Sonthalia S, Arora R, Abhishek A. Trastuzumab–Docetaxel combination chemotherapy induced severe onychopathy. *Indian Dermatol Online J* 2017;8:222-3.

**Received:** November, 2015. **Accepted:** November, 2016.

© 2017 Indian Dermatology Online Journal | Published by Wolters Kluwer - Medknow