

Received: 2016.06.29  
Accepted: 2016.08.26  
Published: 2017.03.21

# Three-Dimensional Evaluation of Maxillary Sinus Septa for Implant Placement

Authors' Contribution:  
Study Design A  
Data Collection B  
Statistical Analysis C  
Data Interpretation D  
Manuscript Preparation E  
Literature Search F  
Funds Collection G

ABCDEF 1 **Eliza Dragan**  
C 2 **Guillaume A. Odri**  
FG 3 **Gabriel Melian**  
AF 1 **Danisia Haba**  
ABDE 4 **Raphael Olszewski**

1 Department of Radiology, Grigore T. Popa University of Medicine and Pharmacy, Iasi, Romania  
2 Department of Orthopaedic Surgery and Traumatology, Regional Hospital of Orleans, Orleans, France  
3 Department of Oral and Maxillofacial Surgery, Grigore T. Popa University of Medicine and Pharmacy, Iasi, Romania  
4 Department of Oral and Maxillofacial Surgery, Catholic University of Louvain, Bruxelles, Belgium

**Corresponding Author:** Eliza Dragan, e-mail: [elizadragan@gmail.com](mailto:elizadragan@gmail.com)

**Source of support:** Departmental sources

**Background:** The aim of our study was to investigate, in 3 dimensions, the maxillary sinus septa as an alternative site for dental implant placement to avoid sinus lift procedures.





**Material/Methods:** We selected 100 dentate and 100 edentate patients with the presence of a maxillary sinus septum by reviewing a larger cone beam computer tomography (CBCT) database from the Department of Oral and Maxillofacial Surgery at Cliniques Universitaires Saint Luc in Bruxelles, Belgium. Three-dimensional reconstructions of 200 maxillary sinus septa were performed using Maxilim software. Ten measurements (length, lateral height, and thickness of the middle and medial region of the septum) were performed by 1 observer, 2 times, with an interval of 1 week between measurements. The angle between the septum and the maxillary plane was also measured. Finally, localization and orientation were assessed for each septum.

**Results:** There was no statistically significant difference between the 2 intraobserver measurements ( $p > 0.05$ ). Student's t-test was used to compare means. Middle height was the only measurement for which there was a difference between edentate and dentate patients ( $p = 0.0095$ , edentate mean < dentate mean). The location of the septa observed in our study groups demonstrated greater prevalence in the posterior region than in the anterior and middle regions. For the spatial orientation of the septum, we found that most septa (81.2% in dentate patients, 53% in edentate patients) were oblique.

**Conclusions:** Three-dimensional evaluation of maxillary sinus septa using 3D CBCT imaging showed that the sinus septum could offer an alternative site for implant placement in the maxillary sinus.

**MeSH Keywords:** **Cone-Beam Computed Tomography • Dental Implants • Sinus Floor Augmentation**

**Full-text PDF:** <http://www.medscimonit.com/abstract/index/idArt/900327>

 1954  3  2  44



## Background

Pre-implantological sinus floor augmentation serves to restore bony mass in the maxilla of partially or totally edentulous patients. There are various surgical techniques available for this procedure [1].

Although the complication rate is low, there are intraoperative risks, such as sinus membrane perforation and bleeding, and postoperative risks of wound infection and sinusitis, graft or barrier membrane exposure, graft infection (warranting its removal), cyst formation, and flap dehiscence [2–15].

The panoramic X-ray can provide a sufficient view of the residual crest height under the sinus floor. For anatomical features such as the anterior or posterior wall and the septa of the sinus, the palatal curvature, and the pterygoid process, it is important to consider that panoramic image quality is highly dependent on the radiologist's skill and is a 2-dimensional image of a 3-dimensional volume with the superimposition of anatomical structures. Fortin demonstrated that the use of a panoramic radiological exam for oral implant planning in severely resorbed maxillae overestimates the need for a sinus augmentation procedure compared with the use of both 3-dimensional planning software and strategic implant placement when there is little remaining bone volume. Furthermore, this technology allows the surgeon to take advantage of the septa and palatal curvature, an option that is not routinely described in conventional procedures [16].

To overcome the drawbacks of sinus lifting, some authors have suggested using alternative anatomic features to place the implant, such as the pterygoid process or tangential to the palatal curvature in the area of the first or second molar [17–20]. For the non-grafted maxilla, Krekmanov placed the implants into the pterygoid plate, palatally tilted, close to and parallel with the posterior sinus wall or close to and parallel with the anterior sinus wall. The most posterior implant was tilted distally, approximately 30 to 35 degrees [21].

However, some authors mentioned severe complications after inserting implants into the pterygoid process. Reychler and Olszewski reported a unique intracerebral penetration of a pterygoid implant inserted into the pterygoid region. An episode of acute left maxillary sinusitis, chronic fatigue, and severe headaches occurred shortly after insertion of the fixed denture. Cerebral magnetic resonance imaging (MRI) demonstrated the penetration of a pterygoid implant into the middle cranial fossa [22].

To avoid the sinus atrium and improve posterior prosthetic support in the resorbed posterior maxilla, the implant can be tilted to a 45° incline [23].

Fortin was the first to demonstrate that maxillary sinus septa could be a location of interest to place implants, avoiding the sinus lift technique in a severely resorbed maxilla, in a clinical case series study [17]. In completely edentulous patients, inserting implants into the sinus septa does not exclude the need for sinus grafting, but in partially edentulous patients, this minimally invasive technique is an alternative to subantral augmentation [24].

Maxillary sinus septa were first described by Underwood in 1910 as the walls of cortical bone within the maxillary sinus [25]. The shape has been described as an inverted gothic arch, arising from the inferior or lateral walls of the sinus, which may divide the sinus into 2 or more cavities.

Various studies were conducted on height, location, prevalence, and morphology of the maxillary sinus septa, in adult patients, using diverse medical imaging techniques such as cone beam computed tomography (CBCT) [26–34]. The measurements were performed in 2 dimensions (2D) in axial, sagittal, or panoramic images. The angle between the septum and the median palatine suture was also evaluated by several authors [27,29].

Unlike traditional 2D radiography, CBCT avoids structural superimposition and image enlargement and distortion, thus allowing precise 3-dimensional (3D) visualization and measurement of dental and maxillofacial structures, at a lower radiation dose than a multislice computed tomography (CT) [35,36]. To the best of our knowledge, there are still no 3D experimental studies in the literature that evaluated the thickness of the maxillary septa and the inclination of the maxillary septum plane toward the horizontal maxillary plane.

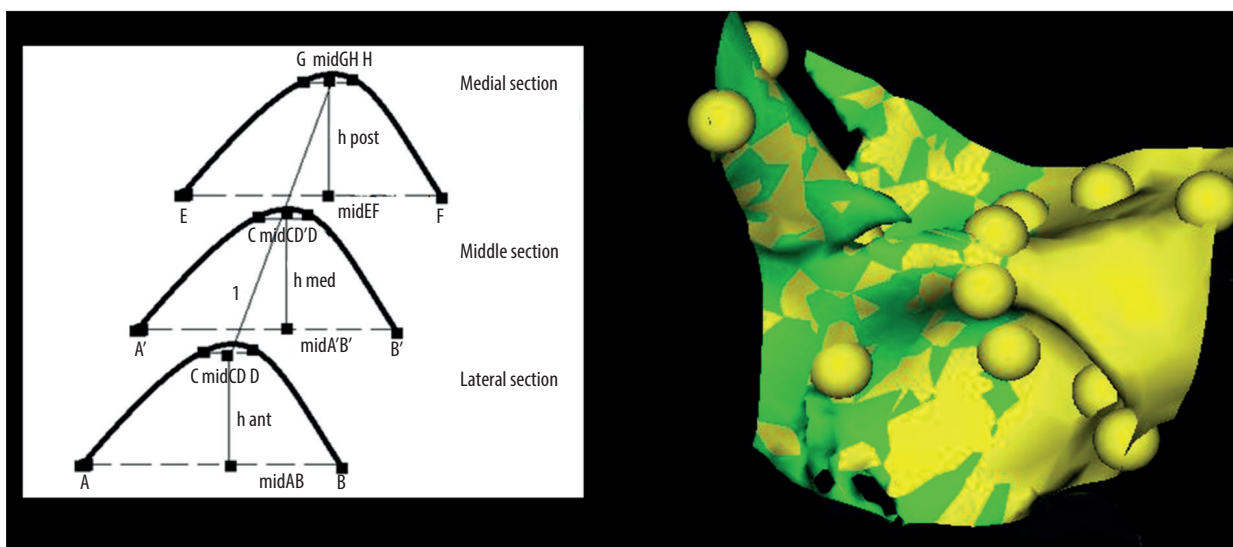
The aim of this investigation was therefore to evaluate, in 3D, the maxillary sinus septa as a potential site for implant placement.

Our second purpose was to compare the anatomy of the maxillary sinus septa in dentate and edentate patients to determine if immediate implant placement in maxillary sinus septa is more favorable than delayed implant placement.

## Material and Methods

We performed an experimental and retrospective study. We selected 200 patients with maxillary sinus septa from a 3000 patient database from the Department of Oral and Maxillofacial Surgery at Cliniques Universitaires Saint Luc in Bruxelles, Belgium.

The patients were divided into 2 groups: 100 dentate patients (group 1) and 100 edentate patients (group 2). In the first



**Figure 1.** The sections at the level of the maxillary sinus septum.

group, patients with the septum located in a dentated region were chosen. In the second group, patients with the septum located in an edentated region were included.

We did not have access to information related to sex and we were only able to obtain information related to age for the dentate group. The age range of the population was from 18 to 86 years, with a mean age of  $46.53 \pm 18.67$  years.

The study was retrospective, and the indication for CBCT was not considered as part of this study. Minors and pregnant women were excluded from the study. CBCT images with inadequate information or that showed signs of a previous maxillary sinus surgery were excluded.

The study received approval from the Comité d'éthique hospitalo-facultaire of the Université catholique de Louvain in Brussels, Belgium (2014/13MAR/104).

The Cone Beam CT (iCAT) protocol specified 120 kVp, 18 mas, 0.3 mm voxel size, 21 cm height, and a 16-cm diameter field of view.

The images were examined for the presence of antral septa first on the axial slices and then on the reconstructed sagittal and coronal slices.

We created maxillary sinus septa 3D reconstructions using Maxilim software (Medicim, Mechelen, Belgium). Three 3D reconstructions were prepared for each septum: 1) at the level of septum insertion on the lateral wall, 2) at the middle of the septum (green section in the middle), and 3) at the level of septum insertion on the medial wall (Figure 1). 3D reconstructions were performed for each maxillary sinus and for

each maxillary sinus septa when there were 2 septa present in the same maxillary sinus.

Twenty-one anatomic landmarks (Table 1) were identified by 1 observer twice, with a 1-week interval between identifications, on 3D reconstructions of the maxillary sinus septa to measure the septum angle, height, thickness, and length of the maxillary sinus septa (Table 2). The observer was not a trained radiologist, but he was a clinically experienced oral surgeon using CBCT as part of his clinical routine.

For each maxillary sinus septum, we also assessed localization (anterior, middle, or posterior third), orientation (sagittal, transverse, or oblique [buccopalatal]) and if it was complete or partial (incomplete septa on the sinus floor and on the medial or lateral sinus wall). We considered a septa complete when the bony crest was inserted both on the lateral wall and on the medial wall of the maxillary sinus.

The orientation was defined according to the angle between the septum plane and the median palatine suture and separated into 3 categories: 1) transverse if at  $90^\circ$  with the median palatine suture, 2) oblique if less or more than  $90^\circ$ , and 3) sagittal if parallel to the medial palatine suture.

The data were recorded and analyzed using SPSS software (IBM). Statistical analysis was performed using SPSS version 20 for Windows 7 (IBM).

## Results

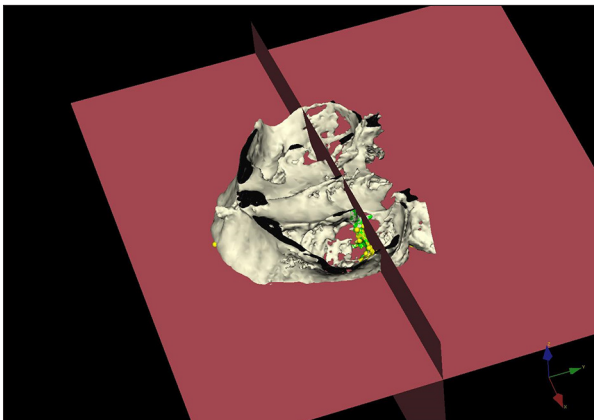
The Intraclass correlation coefficient (ICC) showed that there was no statistically significant difference between the 2 intraobserver measurements ( $p > 0.05$ ).

**Table 1.** Landmark definitions.

Type of landmark	Definition
Manually identified landmark	<p>A – section at the level of septum insertion on the lateral wall, anterior and inferior point;</p> <p>B – section at the level of septum insertion on the lateral wall, posterior and inferior point;</p> <p>C – section at the level of septum insertion on the lateral wall, anterior and superior point;</p> <p>D – section at the level of septum insertion on the lateral wall, posterior and superior point;</p> <p>A' – section at the middle of the septum, anterior and inferior point;</p> <p>B' – section at the middle of the septum, posterior and inferior point;</p> <p>C' – section at the middle of the septum, anterior and superior point;</p> <p>D' – section at the middle of the septum, posterior and superior point;</p> <p>E – section at the level of septum insertion on the medial wall, anterior and inferior point;</p> <p>F – section at the level of septum insertion on the medial wall, posterior and inferior point;</p> <p>G – section at the level of septum insertion on the medial wall, anterior and superior point;</p> <p>H – section at the level of septum insertion on the medial wall, posterior and superior point;</p> <ul style="list-style-type: none"> <li>• Maxillary median landmark – anterior and median landmark at the anterior edge of the maxillary alveolar crest between central incisors for dentate patients or at the anterior edge of the maxillary alveolar crest between alveolar sockets of extracted central incisors for edentate patients;</li> <li>• Pterygoid inferior right: junction between right lateral pterygoid plate and right maxillary tuberosity (approach from right lateral view of the skull)</li> <li>• Pterygoid inferior left: junction between left lateral pterygoid plate and left maxillary tuberosity (approach from left lateral view of the skull)</li> </ul>
Automatically identified landmark	<p>Mid AB – midway point between points A and B;</p> <p>Mid CD – midway point between points C and D;</p> <p>Mid A'B' – midway point between points A' and B';</p> <p>Mid C'D' – midway point between points C' and D';</p> <p>Mid EF – midway point between points E and F;</p> <p>Mid GH – midway point between points G and H</p>

**Table 2.** Measurements.

Septum angle	The angle between the maxillary plane and the maxillary sinus septum plane (midAB, midA'B', midEF, midCD, midC'D', midGH landmarks) was measured. The maxillary plane, was defined by 3 points: maxillary median landmark, pterygoid inferior right, pterygoid inferior left (Figure 2)
Thicknesses	<p>AB thickness (lateral) – Distance between points A and B;</p> <p>CD thickness (lateral) – Distance between points C and D;</p> <p>A'B' thickness (middle) – Distance between points A' and B';</p> <p>C'D' thickness (middle) – Distance between points C' and D';</p> <p>EF thickness (medial) – Distance between points E and F;</p> <p>GH thickness (medial) – Distance between points G and H</p>
Height	<p>Lateral height – distance between mid AB and mid CD;</p> <p>Middle height – distance between mid A'B' and Mid C'D';</p> <p>Medial height – distance between mid EF and mid GH</p>
Length	Distance between mid CD and mid GH



**Figure 2.** The angle formed by the septum plane and the maxillary plane.

Ninety-eight percent of the dentate patients and 96% of the edentate patients presented with complete septa. Two percent of the dentate patients and 4% of the edentate patients presented with incomplete septa.

The analysis of the anatomic location of the septa within the maxillary sinus was performed only in dentate patients and revealed that 55.4% were located in the posterior region, followed by the middle region (33.7%) and the anterior region (10.9%).

For dentate patients, the spatial orientation of the septum was transverse in 18.8% of patients and oblique in 81.2% of patients. For edentate patients, 53% of the septa were oblique and 47% were transverse. We did not identify sagittal septa in either of the 2 groups.

The range and mean values for septum angle, length, height, and thickness are shown in Table 3.

Student's t-test was used to compare means between the 2 groups. Middle height was the only distance that was different between edentate and dentate patients ( $p=0.0095$ , edentate mean < dentate mean).

### Discussion

There were no statistically significant differences among the 2 groups, except for the middle height. This is in agreement with Orhan [29]. Qian [33] observed a significantly ( $p<.05$ ) greater occurrence rate of 57.4% in the edentulous group compared with the rate of 39.7% observed in the dentulous group.

The results of our study concerning the morphology of the septa are different from those of other studies [34]. Bruno et al. confirmed that 40% of patients have bony septa that can partially separate the maxillary sinus [37]. In our study, 98% of the dentate patients and 96% of the edentate patients presented with complete septa. These differences may be because Bruno et al. excluded bony septa less than 4 mm in height or width.

As for the location of the septa, a greater number were found in the posterior regions (55.4%), but several studies observed them in the anterior [26,28,31,38] and in the middle regions [29,30,32]. Differences in localization may be because we did not exclude secondary septa such as bony crests on the maxillary sinus floor, also known as secondary septa, which can be considered a result of tooth loss and atrophy [39].

**Table 3.** The mean values and standard deviation for dentate and edentate patients and the intraclass correlation coefficient.

	Dentate			Edentate			p	ICC
	Range	Mean	SD	Range	Mean	SD		
Angle septum	35.7°– 140.9°	86.03	17.9672	53.8°–176.1°	89.38	18.2447	0.07	0.851
Length	3–16.5	9.53	2.5198	4.7–17.5	9.42	2.4385	0.69	0.879
Lateral height	0.5–10.3	3.68	1.7760	0.7–12.7	3.92	1.6991	0.16	0.698
Medial height	0.5–10.6	4.7	2.5474	0.2–7.7	5.02	2.6597	0.22	0.766
Middle height	0.6–12.2	2.8	1.7105	0.9–17.5	2.40	1.2982	0.01	0.932
Thickness lateral AB	0.9–10.9	5.05	1.8091	0.6–9.6	4.76	1.5681	0.09	0.61
Thickness lateral CD	0.6–7.8	2.45	1.3961	0.5–5.4	2.32	0.8224	0.26	0.641
Thickness middle A'B'	0.7–11.5	4.30	1.8416	0.5–8.2	4.13	1.5599	0.31	0.74
Thickness middle C'D'	0.5–7.2	1.24	0.7746	0.3–3.8	1.12	0.5311	0.07	0.659
Thickness medial EF	0.4–11.7	4.22	1.6428	1–8.7	4.28	1.4250	0.39	0.484
Thickness medial GH	0.5–7.9	2.06	1.1641	0.6–8	2.19	1.1972	0.3	0.654



To the best of our knowledge, there are no 3D studies that evaluated the inclination of the septum plane on the horizontal maxillary plane. The results of this study indicate that the angle formed by the septum plane and the horizontal maxillary plane is favorable for implant insertion ( $86.03^\circ$  for dentate patients and  $89.38^\circ$  for edentate patients). According to Malo, the implant can be placed from a vertical position in the canine/first premolar region to a tilted implant in the second premolar/first molar region, following the anterior sinus wall up to 45 degrees of inclination [40].

The reproducibility of the 3 landmarks that defined the maxillary horizontal plane was not evaluated.

Previous studies reported different heights for the septa, ranging from 1 to 42 mm [1,29,32,39,41,42]. The mean septum heights in our study groups were lower than those found in other studies [28,29,34,35]. In comparison with other studies [28,29,39], our measurements were performed on 3D reconstructions. 3D measurements are more reliable than 2-dimensional measurements.

CBCT is an alternative to conventional multislice CT, with a low radiation dose (4 to 10 times lower, depending on the volume scanned) [43].

## References:

1. Gosau M, Rink D, Driemel O, Draenert FG: Maxillary sinus anatomy: A cadaveric study with clinical implications. *Anat Rec (Hoboken)*, 2009; 292(3): 352–54
2. Barone A, Santini S, Sbordone L et al: A clinical study of the outcomes and complications associated with maxillary sinus augmentation. *Int J Oral Maxillofac Implants*, 2006; 21: 81–85
3. Jensen J, Sindet-Pedersen S, Oliver AJ: Varying treatment strategies for reconstruction of maxillary atrophy with implants: Results in 98 patients. *J Oral Maxillofac Surg*, 1994; 52: 210–16
4. Pikos MA: Maxillary sinus membrane repair: Report of a technique for large perforations. *Implant Dent*, 1999; 8: 29–34
5. Maksoud MA: Complications after maxillary sinus augmentation: A case report. *Implant Dent*, 2001; 10: 168–71
6. Schwartz-Arad D, Herzberg R, Dolev E: The prevalence of surgical complications of the sinus graft procedure and their impact on implant survival. *J Periodontol*, 2004; 75: 511–16
7. Flanagan D: Arterial supply of maxillary sinus and potential for bleeding complication during lateral approach sinus elevation. *Implant Dent*, 2005; 14: 336–38
8. Elian N, Wallace S, Cho SC et al: Distribution of maxillary artery as it relates to sinus floor augmentation. *J Oral Maxillofac Implants*, 2005; 20: 784–87
9. Ardekian L, Oved-Peleg E, Mactei EE, Peled M: The clinical significance of sinus membrane perforation during augmentation of the maxillary sinus. *J Oral Maxillofac Surg*, 2006; 64: 277–82
10. Ueda M, Kaneda T: Maxillary sinusitis caused by dental implants: Report of two cases. *J Oral Maxillofac Surg*, 1992; 50: 285–87
11. Timmenga NM, Raghoebar GM, Boering G, van Weissenbruch R: Maxillary sinus function after sinus lifts for the insertion of dental implants. *J Oral Maxillofac Surg*, 1997; 55: 936–39
12. Kretschmar DP, Kretschmar JL: Rhinosinusitis: review from a dental perspective. *Oral Surg Oral Med Oral Pathol Oral Radiol Endod*, 2003; 96: 128–35
13. Regev E, Smith RA, Perrott DH, Pogrel MA: Maxillary sinus complications related to endosseous implants. *Int J Oral Maxillofac Implants*, 1995; 10: 451–61
14. Goga D, Romieux G, Bonin B et al: [Pre-implantation iliac graft in the sinus. Retrospective study of the complications encountered in 100 cases.] *Rev Stomatol Chir Maxillofac*, 2000; 101: 303–8 [in French]
15. Lockhart R, Ceccaldi J, Bertrand JC: Postoperative maxillary cyst following sinus bone graft: report of a case. *Int J Oral Maxillofac Implants*, 2000; 15: 583–86
16. Fortin T, Camby E, Alik M et al: Panoramic images versus three-dimensional planning software for oralimplant planning in atrophied posterior maxillary: A clinical radiological study. *Clin Implant Dent Relat Res*, 2013; 15(2): 198–204
17. Fortin T, Isidori M, Bouchet H: Placement of posterior maxillary implants in partially edentulous patients with severe bone deficiency using CAD/CAM guidance to avoid sinus grafting: a clinical report of procedure. *Int J Oral Maxillofac Implants*, 2009; 24: 96–102
18. Krekmanov L, Kahn M, Rangert B, Lindström H: Tilting of posterior mandibular and maxillary implants for improved prosthesis support. *Int J Oral Maxillofac Implants*, 2000; 15(3): 405–14
19. Krekmanov L: A modified method of simultaneous bone grafting and placement of endosseous implants in the severely atrophic maxilla. *Int J Oral Maxillofac Implants*, 1995; 10(6): 682–88
20. Balshi TJ, Wolfinger GJ, Balshi SF 2<sup>nd</sup>: Analysis of 356 pterygomaxillary implants in edentulous arches for fixed prosthesis anchorage. *Int J Oral Maxillofac Implants*, 1999; 14(3): 398–406
21. Krekmanov L: Placement of posterior mandibular and maxillary implants in patients with severe bone deficiency: A clinical report of procedure. *Int J Oral Maxillofac Implants*, 2000; 15(5): 722–30
22. Reyehler H, Olszewski R: Intracerebral penetration of a zygomatic dental implant and consequent therapeutic dilemmas: Case report. *Int J Oral Maxillofac Implants*, 2010; 25(2): 416–18

23. Maló P, Nobre Mde A, Petersson U, Wigren S: A pilot study of complete edentulous rehabilitation with immediate function using a new implant design: Case series. *Clin Implant Dent Relat Res*, 2006; 8(4): 223–32
24. Dragan E, Guillaume OA, Haba D, Olszewski R: Three-dimensional evaluation of implant positioning in the maxillary sinus septum: A retrospective study. *Med Sci Monit*, 2015; 21: 2666–71
25. Underwood AS: An inquiry into the anatomy and pathology of the maxillary sinus. *J Anat Physiol*, 1910; 44: 354–69
26. Neugebauer J, Ritter L, Mischkowski RA et al: Evaluation of maxillary sinus anatomy by cone-beam CT prior to sinus floor elevation. *Int J Oral Maxillofac Implants*, 2010; 25: 258–65
27. Velasquez-Plata D, Hovey LR, Peach CC, Alder ME: Maxillary sinus septa: A 3-dimensional computerized tomographic scan analysis. *Int J Oral Maxillofac Implants*, 2002; 17: 854–60
28. Park YB, Jeon HS, Shim JS et al: Analysis of the anatomy of the maxillary sinus septum using 3-dimensional computed tomography. *J Oral Maxillofac Surg*, 2011; 69(4): 1070–78
29. Orhan K, Kusakci Seker B, Aksoy S et al: Cone beam CT evaluation of maxillary sinus septa prevalence, height, location and morphology in children and an adult population. *Med Princ Pract*, 2013; 22: 47–53
30. Chen MZ, Xie YF, Xie H et al: Cone-beam CT study of bone septa during maxillary sinus lift among Changzhou population. *Shanghai Kou Qiang Yi Xue*, 2016; 25(1): 77–81
31. Shahidi S, Zamiri B, Momeni Danaei S et al: Evaluation of anatomic variations in maxillary sinus with the aid of cone beam computed tomography (CBCT) in a population in South of Iran. *J Dent (Shiraz)*, 2016; 17(1): 7–15
32. Sakhdari S, Panjnoush M, Eyvazlou A, Niktash A: Determination of the prevalence, height, and location of the maxillary sinus septa using cone beam computed tomography. *Implant Dent*, 2016; 25(3): 335–40
33. Qian L, Tian XM, Zeng L et al: Analysis of the morphology of maxillary sinus septa on reconstructed cone-beam computed tomography images. *J Oral Maxillofac Surg*, 2016; 74(4): 729–37
34. Bornstein MM, Seiffert C, Maestre-Ferrín L et al: An analysis of frequency, morphology, and locations of maxillary sinus septa using cone beam computed tomography. *Int J Oral Maxillofac Implants*, 2016; 31(2): 280–87
35. Horner K, Islam M, Flygare L et al: Basic principles for use of dental cone beam computed tomography: Consensus guidelines of the European Academy of Dental and Maxillofacial Radiology. *Dentomaxillofac Radiol*, 2009; 38: 187–95
36. Carter L, Farman AG, Geist J et al: American Academy of Oral and Maxillofacial Radiology executive opinion statement on performing and interpreting diagnostic cone-beam computed tomography. *Oral Surg Oral Med Oral Pathol Oral Radiol Endod*, 2008; 106: 561–62
37. Ella B, Noble Rda C, Lauverjat Y et al: Septa within the sinus: effect on elevation of the sinus floor. *Br J Oral Maxillofac Surg*, 2008; 46(6): 464–67
38. Koymen R, Gocmen-Mas N, Karacayli U et al: Anatomic evaluation of maxillary sinus septa. *Surgery and Radiology Clin Anat*, 2009; 22: 563–70
39. Krennmair G, Ulm C, Lugmayr H: Maxillary sinus septa: Incidence, morphology and clinical implications. *J Craniomaxillofac Surg*, 1997; 25: 261–65
40. Malo P, Rangert B, Nobre M: All-on-4 immediate-function concept with Brånemark system implants for completely edentulous maxillae: A 1-year retrospective clinical study. *Clin Implant Dent Relat Res*, 2005; 7: S88–94
41. Koymen R, Gocmen-Mas N, Karacayli U et al: Anatomic evaluation of maxillary sinus septa: Surgery and radiology. *Clin Anat*, 2009; 22: 563–70
42. Pommer B, Ulm C, Lorenzoni M et al: Prevalence, location and morphology of maxillary sinus septa: Systematic review and meta-analysis. *J Clin Periodontol*, 2012; 39(8): 769–73
43. Carmeli G, Artzi Z, Kozlovsky A et al: Antral computerized tomography pre-operative evaluation: relationship between mucosal thickening and maxillary sinus function. *Clin Oral Impl Res*, 2011; 22: 78–82
44. Gülşen U, Mehdiyev İ, Üngör C et al: Horizontal maxillary sinus septa: An uncommon entity. *Int J Surg Case Rep*, 2015; 12: 67–70