



Case report

A child with Ewing's sarcoma in scapula: A rare case report

Mohammad Nour Shashaa^a, Amr Hamza^{a,*}, Mohamad AlHashemi^a, Rama Alyousfi^b,
Muhammad Abu Alkheer Deebo^c, Jamal Katnaji^c

^a Faculty of Medicine, University of Aleppo, Aleppo, Syria

^b Department of Pathology, Aleppo University Hospital, University of Aleppo, Aleppo, Syria

^c Department of Orthopedic Surgery, Aleppo University Hospital, University of Aleppo, Aleppo, Syria

ARTICLE INFO

Keywords:

Ewing's sarcoma
Scapula
Tumors
Children

ABSTRACT

Introduction: Ewing's sarcoma is considered to be the second most frequent primary sarcoma in children. It affects children and young adults with a male predominance. Ewing's sarcoma is usually found in the femur, humerus, ilium and tibia; and in extremely rare cases Ewing's sarcoma might affect the scapula. There are only 15 papers in PubMed database regarding scapular Ewing's sarcoma.

Case presentation: A 14-year-old male, with no significant medical or surgical history, presented with a swelling in the right scapular area for two months. The patient also experienced mild pain and fever. On physical examination, there was a tender mass and restriction in the right shoulder joint movements. MRI showed a large scapular mass with the characteristics of a sarcoma. The final diagnosis was made based on pathologic findings. Eventually, the patient was subjected to neoadjuvant chemotherapy.

Discussion: The most common tumors affecting scapula are chondrosarcoma and osteosarcoma. In a cohort study about patients diagnosed with ES between 1988 and 2018, only 29 cases were involved in the scapula. There are 12 cases of congenital ES have been reported in the medical literature, 3 of them were in the shoulder girdle. Surgery with neoadjuvant chemotherapy is considered better for total survival in ES of scapula in comparison with chemotherapy and/or radiotherapy alone.

Conclusion: Ewing sarcoma is extremely rare in the scapula and should be considered as a differential diagnosis for any patient with scapular tumor.

1. Introduction

Ewing's sarcoma (ES) is a malignant bone tumor that is mostly common among children and young adults between 10 and 20 years old with a male predominance [1]. ES was firstly described in 1921 by James Ewing as a tumor arising from undifferentiated osseous mesenchymal cells, and recent studies suggest that it may be originated from neuroectodermal cells which are derived from the primitive neural tissue [2]. ES is a member of the Ewing's sarcoma family of tumors (ESFT) that consists of 3 tumors: ES, primitive neuroectodermal tumor (PNET), and Askin tumor [1].

ES is considered to be the third most frequent primary sarcoma of bone and the second most common bone tumor occurring in children and young adults accounting for approximately 3% of all pediatric malignancies and approximately 10% of all primary malignant bone tumors [3].

The tumor may affect any bone, but it is frequently found in the femur, ilium and tibia. Otherwise, it is rarely found in the skull, vertebra, short tubular bones of hands and feet and scapula [4]. To our knowledge, there are no more than 15 papers regarding scapular ES were published in PubMed Database until May 2021, which makes ES a significantly rare tumor that needs to be studied further.

This paper reports a case of a scapular Ewing's sarcoma in a 14-years-old child presented with a painful swelling in the right scapula. This work was written in accordance with the SCARE criteria [5].

2. Case presentation

A 14-year-old male presented to the hospital complaining of progressively developing swelling on the dorsal aspect of the right scapula for two months. The swelling was accompanied by mild pain which was worsening during the night. In addition, the patient suffered from two

* Corresponding author.

E-mail address: Amr.f.hamza97@gmail.com (A. Hamza).

<https://doi.org/10.1016/j.ijscr.2021.106182>

Received 20 June 2021; Accepted 6 July 2021

Available online 7 July 2021

2210-2612/© 2021 The Authors. Published by Elsevier Ltd on behalf of IJS Publishing Group Ltd. This is an open access article under the CC BY-NC-ND license

(<http://creativecommons.org/licenses/by-nc-nd/4.0/>).

episodes of fever and both improved with antipyretics. Past medical and surgical history were unremarkable. He had no history of appetite loss, recent weight loss, or previous scapular injuries. A fourth-degree of consanguinity between the patient's parents was also mentioned.

The clinical examination revealed diffuse and firm swelling, tenderness over scapular area, and obvious restriction of the right shoulder joint movements (Fig. 1). Vital signs were within normal; otherwise, laboratory findings indicated anemia.

Computed Tomography (CT) scan showed a large heterogeneous mass including the right scapula, with necrotic parts of adjacent soft tissue (Fig. 2). Furthermore, magnetic resonance imaging (MRI) was highly suggestive of sarcoma arising from the scapula, as the mass measured approximately (9.2 × 7.7 × 7.6 cm) and showed a mixed signal intensity on T1 and T2, ill-defined margins, and infiltration into the surrounding muscles. Bone scintigraphy supported the previous findings and revealed increased metabolic activity in the right scapula (Fig. 3).

Based on these findings, a biopsy was performed and sent for microscopic examination. Hematoxylin and Eosin (H&E) stain showed malignant proliferation of uniform, small round blue cells, with scant and clear cytoplasm. There were also wide areas of hemorrhage and necrosis, and some fibrous strands. Immunohistochemical studies showed diffuse positive staining for CD99 and negative results for CD20 and LCA (Fig. 4). Therefore, the pathological report confirmed the diagnosis as Ewing sarcoma of the right scapula.

Eventually, the patient was referred to oncology department to receive neoadjuvant chemotherapy.

3. Discussion

ES is a highly malignant tumor with an incidence rate of 2 per million, and is considered the second most common primary bone tumor in children [6]. It usually affects males more than females, and mostly among young people in the first two decades [1]. Approximately 95% of ES expresses a translocation of EWS gene on chromosome 22 [7]. ES commonly involves femur, tibia, humerus, fibula and pelvis [4]. Scapula is a rare site for bone tumors (3%), and most scapular tumors are

malignant [8]. The most common tumors affecting scapula are chondrosarcoma and osteosarcoma. In a cohort study about patients diagnosed with ES between 1988 and 2018, only 29 cases were involved in the scapula [8]. There are 12 cases of congenital ES have been reported in the medical literature, 3 of them were in the shoulder girdle [9]. Symptoms commonly include pain, swelling, low-grade fever, malaise and weakness. About 26% of the patients with ES had metastasis at the time of diagnosis [10]. Moreover, within 2 years of the diagnosis, metastatic disease occurs in 85% of patients. However, the most common sites include lungs, bone, pleura, lymph nodes and meninges. Survival outcome for lung metastases is better than bone metastases [11]. Grossly, ES is often gray with necrotic and hemorrhagic areas. Surgeons might interpret the necrotic semifluid tissue of the lesion as pus [10]. By microscopic examination, ES tumors consist of monomorphic small global cells containing round nuclei which consequently containing fine chromatin and scarce cytoplasm. Tumor cells commonly show positivity for a cell surface glycoprotein called CD99, which is the product of the MIC-2 genes [10]. Radiography typically reveals a moth-eaten lesion, as well as, subperiosteal reaction imparting an onion skin appearance [10,12]. CT scan usually shows the extent of bone destruction, and concerning the detection of soft tissue extent and bone marrow involvement, MRI may be performed. Workup should include chest radiograph, chest CT, bone scan, and either bone marrow biopsy or Positron emission tomography-CT (PET-CT) [12]. Systematic and local therapy are important for ES treatment. Peri-operative heavy systemic chemotherapy including cyclophosphamide, adriamycin, vincristine, dactinomycin, ifosfamide, and etoposide represents are the mainstay treatment of ES [12]. However, preoperative radiation may be offered in case of proven difficult surgical excision by radiological imaging or if the patient is not a candidate for surgery [13]. Surgical resection of the shoulder girdle is divided into six types according to Malawer. Partial scapulectomy (type II Malawer resection) preserves part of the rotator cuff muscles including infraspinatus, subscapularis as well as serratus anterior muscle, so it has better results on the shoulder function. Despite abduction movement may be particularly affected in total scapulectomy (type IIIA or B), the procedure still has a satisfactory level of function [14]. Surgery with neoadjuvant chemotherapy is considered better for

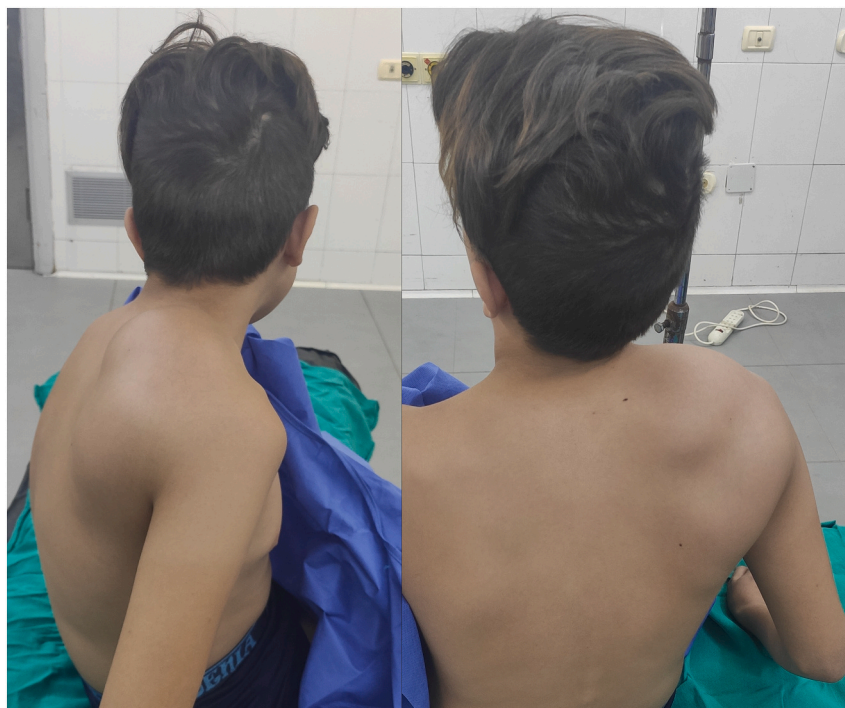

Fig. 1. Inspection upon clinical examination of the patient shows a large swelling in the right scapular region.

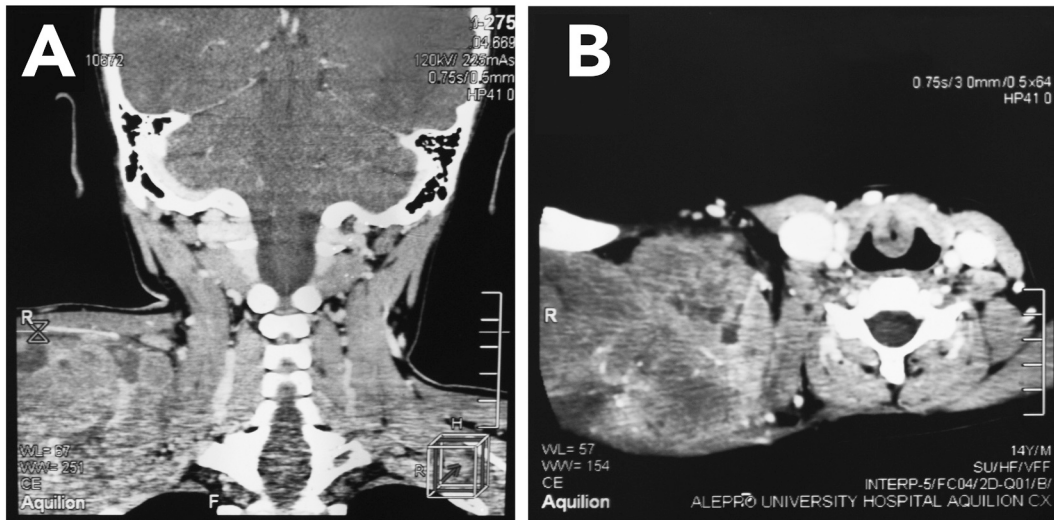


Fig. 2. (A) Coronal and (B) Axial CT scan show a large heterogeneous mass in the right scapula, with necrotic parts of adjacent soft tissue.

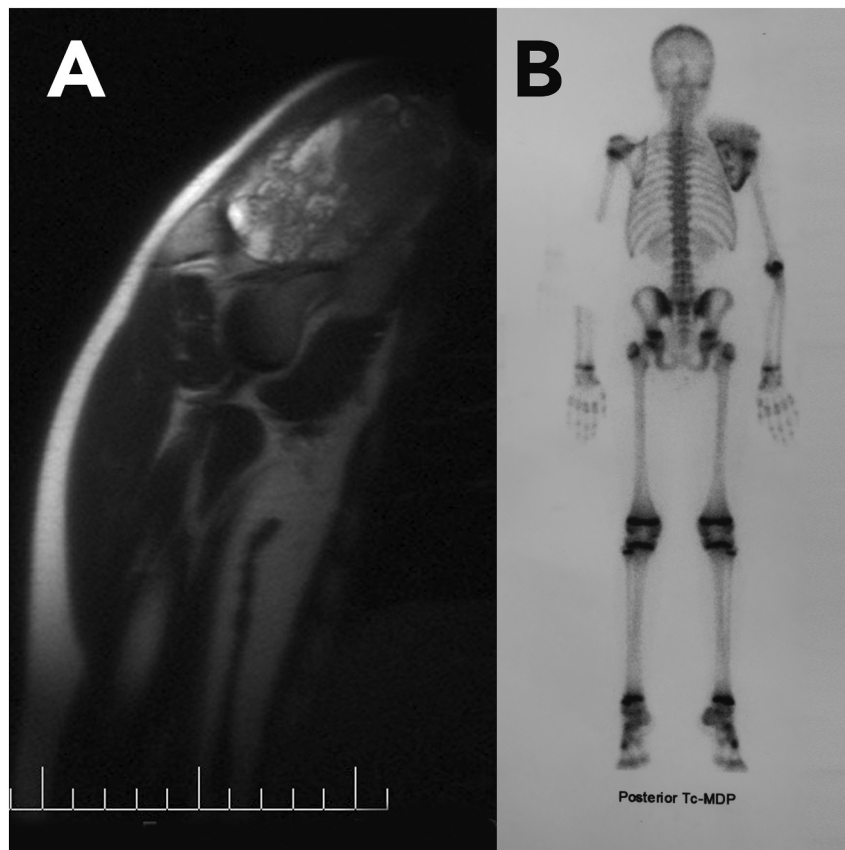


Fig. 3. (A) T2-weighted MRI of the right shoulder shows a mixed signal intensity mass measuring approximately $(9.2 \times 7.7 \times 7.6 \text{ cm})$ with ill-defined margins. (B) Bone scintigraphy with ^{99m}Tc MDP reveals increased metabolic activity in the right scapula.

total survival in ES of scapula in comparison with chemotherapy and/or radiotherapy alone. On the other hand, patients with marginal resection and a chemotherapy response of $<100\%$ had the worst outcome [8]. Local recurrence did not have significant effect on total survival [8]. Long term follow-up should be done after primary management in order to detect any secondary malignancies and growth-related musculoskeletal complications. The Musculoskeletal Tumor Society Score (MSTS) was used to assess the function of scapula, and according to Malik et al. the median MSTS score was 67.4% [8]. The prognosis of ES depends on

many factors: anatomic location, tumor stage and size, necrosis next to chemotherapy, presence or absence of metastases, raised serum LDH levels and older age (> 15 years old) [15]. The survival was 71.4% within five years and 63% within ten years for all patients, while the survival was 86.5% within five years and 81% within ten years for patients that underwent surgery [8]. Psychological counseling could be seriously necessary after operations, particularly in sarcoma patients, due to psychological effects and depression [16].

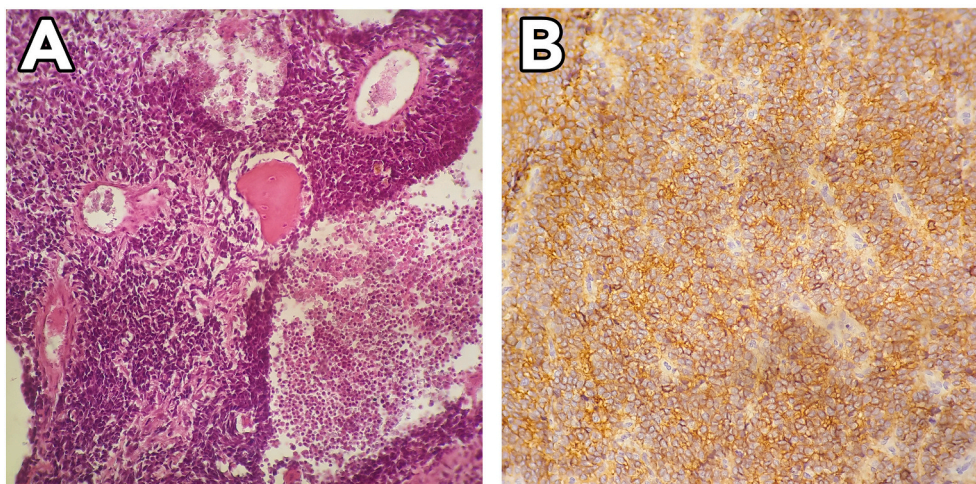


Fig. 4. (A) Hematoxylin and Eosin (H&E) stain shows malignant proliferation of uniform, small round blue cells, with scant and clear cytoplasm. There are also wide areas of hemorrhage and necrosis, and some fibrous strands. (B) Immunohistochemical study shows diffuse positive staining for CD99.

4. Conclusion

The scapula is a rare site for bone tumors, and the most common tumors affecting scapula are chondrosarcoma and osteosarcoma. Ewing's sarcoma is extremely rare in the scapula and should be considered as a differential diagnosis for any patient presents with a swelling over scapular region.

Abbreviations

| | |
|--------|----------------------------------|
| ES | Ewing's sarcoma |
| ESFT | Ewing's sarcoma family of tumors |
| PNET | primitive neuroectodermal tumor |
| CT | computed tomography |
| MRI | magnetic resonance imaging |
| PET-CT | positron emission tomography-CT |
| CD99 | cluster of differentiation 99 |
| CD20 | cluster of differentiation 20 |
| LCA | leukocyte common antigen |
| MSTS | musculoskeletal tumor society |
| LDH | lactate dehydrogenase |

Ethical approval

Not required for case reports at our hospital. Single case reports are exempt from ethical approval in our institution.

Consent

Written informed consent was obtained from the patient's legal guardian for publication of this case report and any accompanying images. A copy of the written consent is available for review by the Editor-in-Chief of this journal.

Sources of funding

No funding was received for the work involved in this article.

Author contribution

JK: Supervisor, Orthopedic surgeon, supervised and managed the patient.

RA: Supervisor, Pathologist, performed the histological examination.
MAAD: Data collection, Revision.

MNS, AH and MA: analyzed and interpreted the patient data, Wrote the manuscript.

AH: was the corresponding author.

All authors read and approved the final manuscript.

Declaration of competing interest

The authors report no conflicts of interests.

Acknowledgement

We would like to thank Mohamad Shadi Alkarrash for revision contribution.

References

- [1] N.J. Balamuth, R.B. Womer, Ewing's sarcoma, *Lancet Oncol.* 11 (2) (2010) 184–192. Feb 1.
- [2] S.H. Waqar, M.A. Zahid, Ewing's sarcoma in scapular region, *APSP J. Case Rep.* 2 (3) (2011) 22. Sep.
- [3] A.V. Maheshwari, E.Y. Cheng, Ewing sarcoma family of tumors, *J. Am. Acad. Orthop. Surg.* 18 (2) (2010) 94–107. Feb 1.
- [4] M. Shahid, M. Varshney, V. Maheshwari, A. Mubeen, M.A. Siddiqui, J. Julfiqar, K. Gaur, Ewing's sarcoma of scapula: a rare entity, *Case Reports 2011* (2011) bcr0220113810.
- [5] SCARE Group, R.A. Agha, T. Franchi, C. Sohrabi, G. Mathew, A. Kerwan, The SCARE 2020 guideline: updating consensus Surgical Case Report (SCARE) guidelines, *Int. J. Surg.* 84 (2020) 226–230.
- [6] H.E. Grier, The Ewing family of tumors: Ewing's sarcoma and primitive neuroectodermal tumors, *Pediatr. Clin. N. Am.* 44 (4) (1997) 991–1004. Aug 1.
- [7] O. Delattre, J. Zucman, B. Plougastel, C. Desmaze, T. Melot, M. Peter, H. Kovar, I. Joubert, P. De Jong, G. Rouleau, A. Aurias, Gene fusion with an ETS DNA-binding domain caused by chromosome translocation in human tumours, *Nature* 359 (6391) (1992) 162–165. Sep 10.
- [8] S.S. Malik, M. Tahir, U. Ahmed, S. Evans, L. Jeys, S. Abudu, Outcome of Ewing's sarcoma of the scapula—a long-term follow-up study, *Orthop. Traumatol. Surg. Res.* 106 (1) (2020 Feb 1) 25–30.
- [9] J. Schmalzl, M. Niks, M. Moursy, H.P. Scharf, L.J. Lehmann, Eight-year follow-up after scapulectomy in a neonate with congenital Ewing sarcoma of the scapula, *J. Shoulder Elb. Surg.* 27 (9) (2018) e288–e293. Sep 1.
- [10] R. Biswas, B. Krishnan, R.H. Phulwara, S.G. Roy, R. Kumar, A. Barwad, J.P. Meena, S.A. Khan, Ewing's sarcoma of scapula: a rare case report, *Indian J. Surg. Oncol.* 10 (1) (2019) 232–235. Mar.
- [11] T. Hattori, H. Yamakawa, N. Nakayama, T. Kuroda, T. Andoh, N. Sakai, T. Ohno, Y. Nishimoto, S. Takeuchi, K. Shimizu, Skull metastasis of Ewing's sarcoma—three case reports—, *Neurol. Med. Chir.* 39 (13) (1999) 946–949.
- [12] L.W. Brady, D.E. Wazer, C.A. Perez, in: Perez & Brady's Principles and Practice of Radiation Oncology, Lippincott Williams & Wilkins, 2013, p. 1689. May 6.
- [13] L.W. Brady, D.E. Wazer, C.A. Perez, in: Perez & Brady's Principles and Practice of Radiation Oncology, Lippincott Williams & Wilkins, 2013, p. 1691. May 6.

- [14] M.M. Malawer, Tumors of the shoulder girdle: technique of resection and description of a surgical classification, *Orthop. Clin. N. Am.* 22 (1) (1991) 7–35. Jan 1.
- [15] P. Picci, T. Böhling, G. Bacci, S. Ferrari, L. Sangiorgi, M. Mercuri, P. Ruggieri, M. Manfrini, A. Ferraro, R. Casadei, M.S. Benassi, A.F. Mancini, P. Rosito, A. Cazzola, E. Barbieri, A. Tienghi, A. Brach del Prever, A. Comandone, P. Bacchini, F. Bertoni, Chemotherapy-induced tumor necrosis as a prognostic factor in localized Ewing's sarcoma of the extremities, *J. Clin. Oncol.* 15 (4) (1997) 1553–1559. Apr.
- [16] J.N. Worcester Jr., Radical resection for tumors of the shoulder with preservation of a functional extremity, *J. Bone Joint Surg. (Am. Vol.)* 1 (44) (1962) 1423–1430. Oct.