



ELSEVIER

Contents lists available at ScienceDirect

JPRAS Open

journal homepage: [www.elsevier.com/locate/jpra](http://www.elsevier.com/locate/jpra)

## Original Article

## Pretibial hematomas – A real-world single-center study

T. Seppälä<sup>a,\*</sup>, V. Grünthal<sup>b</sup>, V. Koljonen<sup>a</sup><sup>a</sup> Department of Plastic Surgery, University of Helsinki and Helsinki University Hospital, Helsinki, Finland<sup>b</sup> Department of Surgery, Kymenlaakso Central Hospital, KYMSOTE, Kotka, Finland

## ARTICLE INFO

## Article history:

Received 9 November 2021

Accepted 5 January 2022

Available online 24 February 2022

## Keywords:

Plastic surgery

Pretibial hematoma

Dermatoporosis

Hematoma evacuation

Pretibial injury

## ABSTRACT

We analyzed treatment, outcome, and risk factors for skin necrosis of 60 patients aged  $\geq 65$  years treated for a pretibial hematoma in the province of Kymenlaakso, Finland, between 2015 and 2019. Reviewing patients' medical records revealed two cohorts with distinct trajectories in outcome. By comparing the cohorts, we were able to discover factors associated with the prognosis for generating skin necrosis and the need for operative treatment.

Thirty-five (58.3%) patients healed without any management, and 25 (41.7%) patients were treated with hematoma evacuation, mostly for having generated skin necrosis (72%). Among operatively treated patients' descriptions, such as "parchment skin" and "poor skin quality" were observed frequently (80%) in the medical records. This pathology, dermatoporosis, was statistically significant ( $p < 0.0001$ ) among patients with a complicated outcome of a pretibial hematoma. In addition to dermatoporosis, patients with hematoma evacuation were more fragile having a higher Charlson comorbidity index ( $p = 0.005$ ), a greater need for a walking aid ( $p = 0.0002$ ), and overall compromised independency ( $p = 0.033$ ). Hospitalization and rehabilitation were prolonged in the operatively treated cohort, 6.4 days vs. 2 days, respectively.

We recorded a delay in the diagnosis and hematoma evacuation (mean 6, range 0–51 days). In addition, six (10%) patients were misdiagnosed for having erysipelas or deep vein thrombosis indicating that pretibial hematomas are not recognized. Skin quality

\* Corresponding author at: Department of Plastic Surgery, HUS, Helsinki University Hospital, Stenbäckinkatu 11, 00290 Helsinki, Finland.

E-mail address: [toni.p.seppala@helsinki.fi](mailto:toni.p.seppala@helsinki.fi) (T. Seppälä).

should be documented, and prompt surgical hematoma evacuation should be executed in fragile patients with dermatoporosis. This could prevent skin necrosis and the further need of wound care or surgical care, long hospitalization, and rehabilitation periods.

© 2022 The Author(s). Published by Elsevier Ltd on behalf of British Association of Plastic, Reconstructive and Aesthetic Surgeons.

This is an open access article under the CC BY-NC-ND license (<http://creativecommons.org/licenses/by-nc-nd/4.0/>)

## Introduction

Pretibial hematomas are considered banal, although they can cause significant morbidity, complications and even mortality in the elderly population.<sup>1–3</sup> The patient population and trauma mechanisms relate closely to pretibial lacerations, a more commonly recognized medical entity.<sup>4–8</sup> Pretibial hematomas present among elderly, polymedicated, morbid patients with compromised independence.<sup>2,3,9</sup> The trauma mechanism is usually a low energy impact, such as falling on flat ground or hitting a household object, though pretibial hematomas are also described to form spontaneously without any recognized trauma.<sup>3,9,10</sup>

A common and severe complication of pretibial hematomas is the development of skin necrosis.<sup>3,11,12</sup> Minor shearing forces separate skin and subcutaneous tissue from muscle fascia, creating a cavity that is filled with blood.<sup>9</sup> The pressure in the blood accumulated cavity overcomes the blood pressure of dermal and subdermal capillaries, leading to skin necrosis.<sup>1,10</sup> The necrotic skin defect results in the need for surgical debridement, and in such cases, it is difficult to cover the exposed soft tissue primarily.<sup>1,9</sup>

Pretibial hematomas are a common cause of morbidity but are seldomly presented in literature as a distinct pathology. Rather, they are presented as a part of pretibial lacerations, case studies, descriptive studies, or systematic reviews.<sup>1,6,11–18</sup> The terminology is inconsistent, as some studies use terms such as deep dissecting hematomas, while other terminology varies between superficial hematomas, expanding spontaneous hematomas, tension subcutaneous hematomas, closed lower leg hematomas and chronic leg hematomas.<sup>3,9,10,16</sup>

The severity of pretibial hematomas vary,<sup>10</sup> which can be explained by differing properties of skin.<sup>3</sup> Some patients may only develop bruising, but especially in patients with dermatoporotic skin low energy traumas can result in large pretibial hematomas that cause skin necrosis.<sup>10</sup> Dermatoporosis, a term proposed by Saurat,<sup>1</sup> is a distinct medical entity that leads to chronic skin fragility.<sup>19–22</sup> The use of systemic and topical corticosteroids, genetic, and environmental factors, such as UV radiation all contribute to the development of dermatoporosis.<sup>19,20</sup> Dermatoporotic skin is characterized by atrophy of the epidermis and dermis, resulting in decreased viscoelastic properties.<sup>1</sup> This gives less support to the fragile blood vessels close to the skin surface, leading to easy bleeding<sup>1</sup> and formation of pretibial hematomas and skin necrosis. Clinical features of dermatoporosis include senile purpura, stellate pseudoscars, and skin atrophy.<sup>1</sup> Its prevalence is estimated to be around 30% in individuals aged over 60 years.<sup>19</sup>

Treatment of pretibial hematomas should be prompt to reduce the extent of potential skin loss.<sup>1,10</sup> Usually, patients are treated under general or regional anesthesia for hematoma evacuation and wound debridement, often leading to a need for a split thickness skin graft.<sup>17</sup> Compression therapy after using a large caliber Yankauer suction cannula has been reported as a successful treatment method for early hematoma evacuation.<sup>11,17</sup> Because of coagulation of the hematoma, traditional needle aspiration is usually unsuccessful.<sup>3</sup>

The aim of this study was to present a single-center experience on patients with pretibial hematomas during 2015–2019 treated at Kymenlaakso Central Hospital. Additional aims were to identify risk factors from our real-world data of skin necrosis and the need for surgical treatment.

**Table 1**

ICD-10 codes and procedural codes of surgical treatments used in patient database search.

ICD10 diagnosis codes	Procedural codes of surgical treatment
S80.1 Contusion of other and unspecified parts of lower leg	QDB00 Lower limb wound suturation
S81.8 Other superficial injuries of lower leg	QDB05 Lower limb wound revision
S81.9 Open wound of lower leg, part unspecified	QDB10 Lower limb wound dressing change
S85.8 Injury of other blood vessels at lower leg level	QDB99 Other lower limb wound suturation/dressing change
S85.9 Injury of unspecified blood vessel at lower leg level	QDG20 Lower limb chronic wound revision
S89.9 Unspecified injury of lower leg	QDA10 Lower limb skin incision
T14.0 Superficial injury of unspecified body region	QWD00 Skin/subcutis revision, haematoma
T14.5 Injury of blood vessel(s) of unspecified body region	ZZA00 Split skin graft, autograft
T14.9 Injury, unspecified	TQW11 Negative pressure wound therapy appliance

## Patients and methods

We performed an electronic search using the LifeCare® patient database of Kymenlaakso Central Hospital for all patients treated for a pretibial hematoma from January 1, 2015 to December 31, 2019 in the central hospital or the surrounding smaller health care centers. We searched for patients using the International Classification of Diseases (ICD)–10 diagnosis codes and procedural codes of surgical treatments presented in Table 1.

Patients included were aged  $\geq 65$  years and had a trauma-related or a spontaneous hematoma in the pretibial region with or without an accompanying skin necrosis. Patients presenting a pretibial laceration, for example, skin tear or wound were excluded from this study. The anatomical location was defined as being between the knee and ankle anteriorly, medially, or laterally. Only patients for whom survival and outcome data were available in the patient files of the Kymenlaakso Central Hospital and its surrounding smaller health care centers were included.

Computerized medical records of all included patients were reviewed in detail by one author (TS). Data reviewed for each study cohort patient included age, gender, independency, physical ability (use of walking aids), previous medical history, medication (especially anticoagulants, per oral cortisone, and immunosuppressants), mechanism of injury, development of skin necrosis, skin blistering, dermatoporosis, mortality, cause of death, treatment (no evacuation, evacuation, aspiration), and outcome. Dermatoporosis was confirmed based on patient photographs and descriptive text from medical history files. Terms, such as “paper-thin skin,” “parchment skin,” “very fragile skin,” or “cortisone-thinned skin” were indicators for severe skin atrophy, dermatoporosis.

Compartment syndrome, number of emergency room (ER) visits, time from injury to admission, and length of stay (LOS) were recorded. Trauma-related hematomas and spontaneous hematomas were distinguished from each other. Patients were classified treatment-wise into two groups: conservatively treated and evacuated hematomas. The groups were compared and reviewed independently.

With patients treated with hematoma evacuation, the time from injury to hematoma evacuation, time from evacuation to skin grafting (if done), defect size (cm<sup>2</sup>), LOS in the hospital plastic surgery ward, LOS in a health care center ward, and follow-up visits with a physician or nurse concerning skin defect or graft healing were recorded. If skin defect healing took over 3 months (90 days), the defect was deemed chronic.<sup>23,24</sup> Red blood cell (RBC) transfusions and hemoglobin surveillance were recorded during the first 7 days of hospitalization among patients who needed treatment for the hematoma.

Cause of death was determined from patients' death certificates. A 3-month mortality rate from hospital admission was calculated. The Charlson comorbidity index<sup>25</sup> (CCI) was calculated for each patient based on the diagnoses in the computerized medical records using the following internet calculator: <https://www.mdcalc.com/charlson-comorbidity-index-cci>.

## Statistical methods and analysis

Statistical analysis was conducted using the NCSS 12 Statistical Software (2018) (NCSS, LLC, Kaysville, UT, USA, [ncss.com/software/ncss](http://ncss.com/software/ncss)) and SPSS Statistics version 19.0 (IBM Corporation, New York, NY, USA). We considered p-values of less than 0.05 to be significant.

**Table 2**

Demographic data of patients with a pretibial hematoma. P-values denote the correlation between conservatively treated and evacuated hematoma patients.

	All patients	Conservative	Evacuated	P-values
<b>N (%)</b>	<b>60 (100)</b>	<b>35 (58.3)</b>	<b>25 (41.7)</b>	0.22602
Female, n (%)	43 (71.7)	23 (65.7)	20 (80)	
Male, n (%)	17 (28.3)	12 (34.3)	5 (20)	
<b>Mean age, years (range)</b>				
All	81.1 (67–99)	80.6 (67–99)	81.6 (68–92)	0.80425
Female	83.8 (67–99)	84.6 (67–99)	82.9 (68–92)	
Male	74.1 (68–84)	73 (68–84)	76.6 (74–84)	
<b>Charlson comorbidity index</b>				
Median (range)	6 (2–13)	5 (2–13)	7 (3–12)	0.005*
Mean	6.2	5.4	7.3	
<b>Dermatoporosis</b>				
Yes, n (%)	25 (41.7)	5 (14.3)	20 (84)	<0.0001*
No, n (%)	35 (58.3)	30 (85.7)	5 (16)	
<b>Anticoagulant medication</b>				
Yes, n (%)	51 (85)	29 (82.9)	22 (88)	0.72221
No, n (%)	9 (15)	6 (17.1)	3 (12)	
<b>Living independently</b>				
Yes, n (%)	36 (60)	25 (71.4)	11 (44)	0.033*
No, n (%)	24 (40)	10 (28.6)	14 (56)	
<b>Use of aiding equipment for walking</b>				
Yes, n (%)	36 (60)	14 (40)	22 (88)	0.0002*
No, n (%)	24 (40)	21 (60)	3 (12)	
<b>Trauma mechanism</b>				
Stumbling/falling on flat ground, n (%)	21 (35)	11 (31.4)	10 (40)	–
Hitting an object, e.g. walker-roller, n (%)	20 (33.3)	17 (48.6)	3 (12)	–
Stumble upon / falling from stairs, n (%)	5 (8.3)	3 (8.6)	2 (8)	–
Spontaneous (non-traumatic), n (%)	14 (23.3)	4 (11.4)	10 (40)	0.014*

\* Indicates a statistically significant finding.

The comparison between the conservatively treated and evacuated hematoma patients was made using Pearson's chi-square test for the following parameters: dermatoporosis, gender, and patient independency. Fisher's exact test was used for analyzing anticoagulant medication, use of walking aids, and spontaneous hematomas. For the comparison of continuous variables, the CCI and age, the Mann-Whitney *U* test was used.

## Results

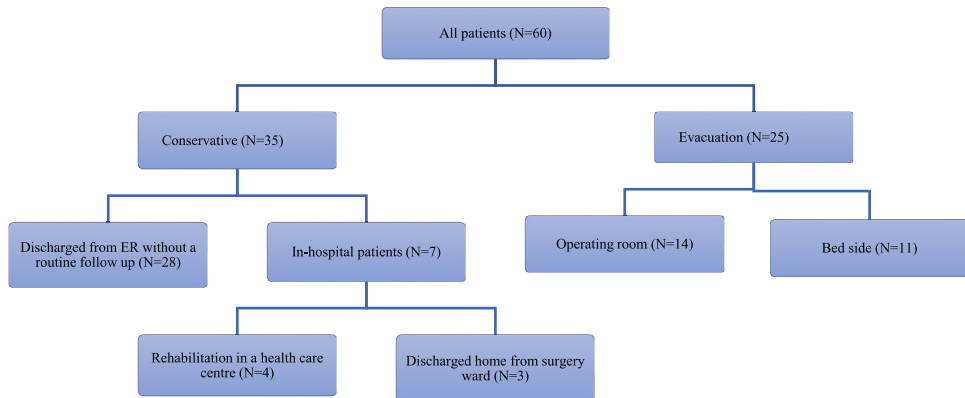
The specific inclusion criteria resulted in 60 patients. We recorded a female overrepresentation, with 71.7% women. A more detailed overview of our cohort's demographic data is given in Table 2 and the two treatment subgroups are illustrated in Fig. 1.

### Conservatively treated hematomas

This group comprised 35 (58.3%) patients. The mean age was 80.6 years and 65.7% were women. All 35 patients healed without hematoma evacuation, and none developed skin necrosis nor needed blood transfusions. One patient developed skin blistering. Hitting an object was the most common trauma mechanism concerning 17 (48.6%) patients. Spontaneous hematomas were reported in four (11.4%) patients.

### CCI and independency

CCI was calculable in all patients, the mean being 5.4 (range 2–13; median 5). Altogether, 25 (71.4%) were self-acting or independent and 14 (42.9%) used walking aids. Eight (22.9%) lived in a retirement home or in an assisted living facility.



**Fig. 1.** Treatments of patients with pretibial hematomas.

### *Anticoagulant medication*

Most of the patients, 29 (82.9%), used anticoagulant medication: 13 (37.1%) acetylsalicylic acid, 7 (20%) warfarin, 4 (11.4%) rivaroxaban, 3 (8.6%) apixaban, 3 (8.6%) clopidogrel, and 1 (2.9%) dabigatran. One patient used acetylsalicylic acid and clopidogrel simultaneously.

### *Dermatoporosis and corticosteroid medication*

Only five (14.3%) patients had dermatoporosis based on medical records. One patient was on systemic corticosteroid medication, and one received other immunosuppressant therapy.

### *ER visits, treatment, and diagnostic challenges*

Most of the patients, 24 (68.6%), needed only one ER visit. Seven (20%) had one, two (5.7%) had two, and two (5.7%) had three ER re-admissions concerning the hematoma.

One patient was primarily misdiagnosed as having erysipelas, and in four patients, deep vein thrombosis was falsely suspected. Needle aspiration was attempted in one patient, but was unsuccessful due to hematoma coagulation.

### *Seeking treatment and LOS*

The mean latency in seeking treatment from the accident was 4.8 days (range 0–16, median 2). Most patients, 28 (80%), were discharged from the ER, and only seven (20%) were treated as inpatients, five of whom needed further rehabilitative treatment. The mean LOS at the surgery ward was 2 days ( $N = 6$ , range 2, median 2). Further, five patients needed a rehabilitative treatment period in a health care center ward where the mean LOS was 36.4 days (range 7–137, median 10).

### *Operatively treated hematomas*

This group comprised 25 (41.7%) patients. Falling on flat ground was the most common trauma mechanism in 10 (40%) patients. Spontaneous hematomas were reported in 10 (40%) patients. For detailed data, see [Table 2](#) and [Fig. 2](#).

### *CCI and independency*

CCI was calculable in all patients, the mean being 7.3 (range 3–13, median 7). Only nine (36%) patients were self-acting or independent and 22 (88%) used walking aids. Sixteen (64%) patients lived in a retirement home or an assisted living facility.

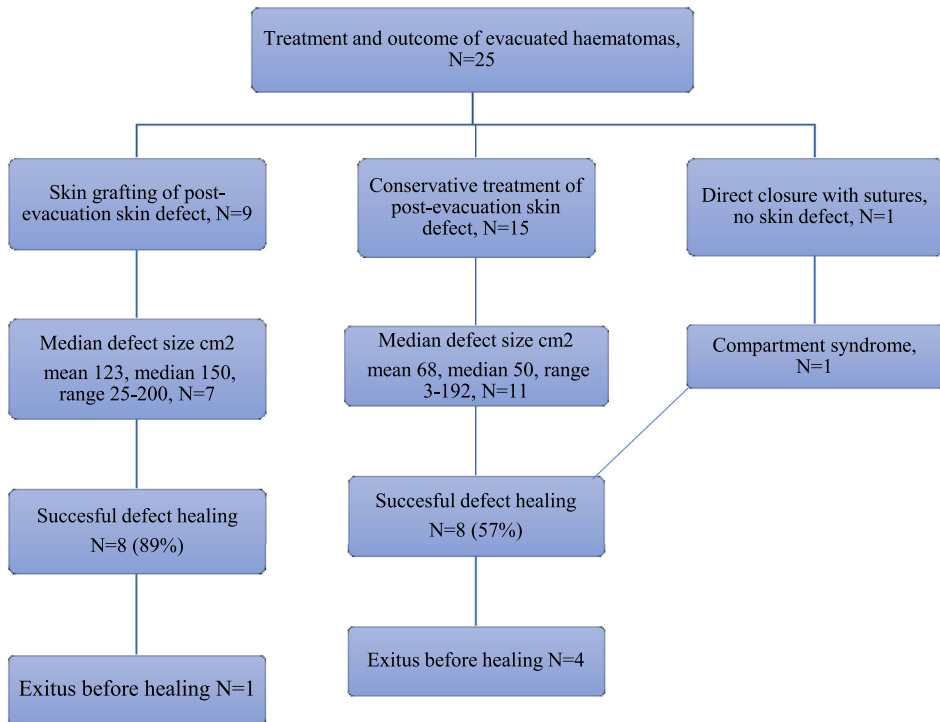


Fig. 2. Evacuated haematomas, further treatments, and outcome.

*Anticoagulant medication*

Most patients, 22 (88%), used anticoagulant medication: 13 (52%) LMWH, 11 (44%) warfarin, 7 (28%) acetylsalicylic acid, 3 (12%) apixaban, and 1 (4%) clopidogrel. Ten (40%) patients received two and one (4%) patient received three anticoagulants simultaneously at the time of the pretibial hematoma.

*Dermatoporosis and corticosteroid medication*

Most patients, 20 (80%), had dermatoporosis based on clinical files. Further, seven (28%) were on systemic corticosteroid medication and two (8%) had other immunosuppressant medication.

*Seeking treatment and LOS*

The mean latency in seeking treatment from the injury was 4.1 days (range 0–47, median 0). Most of the patients, 24 (96%), were treated as in-hospital patients, and only one was discharged from the ER after bedside evacuation. Two were mistakenly diagnosed with erysipelas, delaying treatment. One patient had a subfascial hematoma that caused compartment syndrome.

The mean LOS at the surgery ward was 6.4 days (range 0–30, median 4). Further, 15 patients needed a rehabilitative treatment period in a healthcare center ward, where the mean LOS was 13.6 days (range 0–99, median 8.5).

*Blood transfusions*

In 14 patients, RBC transfusions were given from one to five single-unit transfusions; the median was two units. One patient received a single unit, 10 patients two units, one patient three units, one patient four units, and one patient five units of RBCs. Hemoglobin decrease was noted to be significant in 2–7 days after hospital admittance, on average 26 g/dl (range 13–53, median 23).

### *Evacuations, skin grafting, and treatment*

Hematoma evacuation was done either in the operating room ( $N = 14$ , 56%) or bedside ( $N = 11$ , 44%). In nine (36%) cases, a split thickness skin graft was used in a second session after the evacuation, and 15 (60%) skin defects were left for conservative management. The mean time from injury to evacuation was 11 days (range 0–51, median 3). In 21 (84%) patients, evacuation was successful with primary evacuation, three needed one re-evacuation, and one needed two re-evacuations, all of which were bedside evacuations. Skin necrosis had developed before the hematoma evacuation in 18 (72%) cases. In 14 of these, skin blistering was also observed.

The mean time from hematoma evacuation to split thickness skin grafting was 32.9 days (range 8–121, median 24). In three patients, a split thickness skin graft operation was scheduled, but they died before the operation. One patient did not consent to elective skin grafting despite recommendations.

Needle aspiration was attempted in four patients; all were unsuccessful and hematoma evacuation was utilized. Negative pressure wound therapy was used for 14 (56%) patients after evacuation.

### *Follow-up of healing and outcome*

Wound healing was monitored in 23 (92%) patients. The mean number of physician visits/consultations after evacuation was 1.8 (median 1, range 0–11). The mean number of visits, including home care, by a wound care nurse was 14.8 (median 5.5, range 0–153). In 17 (68%) patients, the healing of the post-evacuation skin defect was successful. The mean time from injury to healing was 90.4 days (median 81.5, range 14–181). Four patients had to move to a nursing home after a long rehabilitative healthcare center ward period since patient independency became compromised permanently.

### *Mortality*

Of the 60 patients, five died during the first 3 months after hospital admission or ER visit, yielding a 90-day mortality of 7.9%. The mean age for deceased patients was 87.2 years (range 82–92). Three died in a health care center ward, one at a retirement home, and one at the Kymenlaakso Central Hospital plastic surgery ward. The cause of death was determined for all five patients; four died of heart disease and one of stroke. All five patients' death certificates included a description of a recent pretibial hematoma, which had been evacuated 4–51 days earlier. Healing was unsuccessful in these five patients.

### *Statistical comparison of conservatively and operatively treated hematomas*

Age, gender, or use of anticoagulant medication did not significantly differ between the two groups. However, among the evacuated hematoma patient group, the higher incidence of dermatoporosis was significantly higher ( $p < 0.0001$ ), as was the higher median of the CCI ( $p = 0.005$ ), the higher incidence of spontaneous hematoma formation ( $p = 0.014$ ), and the greater use walking aids ( $p = 0.0002$ ). Patient independency was significantly lower in the evacuated hematoma patient group ( $p = 0.033$ ). See [Table 2](#) for illustration.

## **Discussion**

We presented our real-world experience on 60 patients with a pretibial hematoma in a large central hospital setting during a 5-year period. Two distinct treatment paths were noted; hematomas were either conservatively treated and healed in 58.3% or evacuated in 41.7% of the patients. The groups differed from each other on several parameters; patients in the evacuated hematoma group had a higher CCI ( $p = 0.005$ ), more often compromised independency ( $p = 0.033$ ), used a walking aid more commonly ( $p = 0.0002$ ) and were more likely to have dermatoporosis ( $p < 0.0001$ ).

Our study revealed parameters and findings in line with the previous literature.<sup>2,3,9,21</sup> Patients were mostly female, elderly, very morbid, used anticoagulants, and had dermatoporosis. Pretibial hematomas were often misdiagnosed, and evacuation delayed. Thus, skin necrosis occurred and primary closure of the wound after evacuation was not possible. Wound dressings or negative pressure

wound therapy (NPWT) was applied to aid the formation of granulation tissue for secondary skin defect coverage. Long wound care, hospitalization, and repetitive surgery were often needed.

We recorded statistically significant findings that further highlight the importance of distinguishing pretibial hematomas as a distinct medical entity with repetitive findings. We were able to trace the patients accurately, revealing numerous in-hospital periods, ER visits, need for rehabilitation, and excessive need for wound care emphasizing the burden they cause in health care systems and providing indications that present treatment is suboptimal.

Diagnosing pretibial hematomas can be difficult. Hematomas are characterized by phases, including erythema, swelling, pain, and elevated temperature.<sup>3</sup> Because of these symptoms, in many cases, signs and symptoms of pretibial hematomas are confused with cellulitis or erysipelas, leading to unnecessary treatment with antibiotic therapy and delaying referral to surgical care.<sup>1,3</sup> In this study, most of the evacuated pretibial hematomas were diagnosed only when skin necrosis was apparent. This indicates that pretibial hematomas receive treatment far too late, either because of being misdiagnosed or due to not being recognized at all.

Pretibial hematomas are often included in pretibial lacerations, a more common and better described entity with a similar patient population and trauma mechanisms as pretibial hematomas. Pretibial lacerations are classified with the Modified Dunkin Classification for treatment decisions.<sup>6</sup> Our current study shows that pretibial hematomas are distinctly different from pretibial lacerations. No classification currently exists for pretibial hematomas and our study findings suggest diagnosing fragile skin conditions for pretibial hematoma patients until an approved classification system is established.

Our hypothesis is that hematoma evacuation should be done immediately after diagnosis among dermatoporotic patients even if the skin seems primarily vital. This could prevent skin necrosis and the need for further surgical revisions and skin grafting. The timing and threshold of when pretibial hematomas proceed to cause skin necrosis is unknown and useful clinical criteria for prompt hematoma evacuation to prevent skin necrosis have not been presented in the literature previously.

A Finnish prospective study and a French study showed that dermatoporosis has an overall prevalence of 30.7–37% among the elderly population.<sup>26</sup> Despite the high prevalence, dermatoporosis as well as pretibial hematomas are unrecognized pathologies for many clinicians and the terminology is unsettled. Populations throughout the world are aging and the incidence of pretibial injuries will surely rise. It is important to establish the terms and morbidities of dermatoporosis and pretibial hematomas in clinical practice.

Skin properties seem to affect the formation of pretibial hematomas and succeeding skin necrosis, and descriptions of atrophic or poor skin quality were frequent with patient history files. Thus, we strongly encourage to document skin quality even with healthy skin. This would help in conducting further retrospective and prospective studies. The main limitation of this study arises from its retrospective nature and the use of data recorded for purposes other than research. Thus, reviewing and analyzing clinical diagnostic impressions from medical records can be considered a drawback. Especially, the lack of describing clinical features of healthy skin in our other hematoma cohort limits our ability to draw accurate conclusions based on the data. On the other hand, previous knowledge on pretibial hematomas is minimal and prospective studies cannot be designed before proper hypotheses and retrospective studies are conducted.

To conclude, pretibial hematomas are a common yet underdiagnosed, and undervalued pathology in the elderly population. We found two different treatment paths, with clearly separate patient parameters providing valuable information and hypotheses on this acute and potentially life-threatening condition. Further prospective studies are needed to establish treatment guidelines and classifications that could help physicians standardize the management of pretibial hematomas, so that, the burden regarding patients and health care systems decrease. Studies on the financial impact of pretibial hematomas are needed as well.

## Funding

The funding of this article was from departmental sources only.



## Ethics

The Institutional Review Board of the hospital approved this retrospective chart review study and its protocol.

## Declaration of Competing Interest

Each author declares no financial conflict of interest regarding the data presented in this manuscript.

## References

1. Kaya G, Jacobs F, Prins C, Viero D, Kaya A, Saurat J-H. Deep dissecting hematoma: an emerging severe complication of dermatoporosis. *Arch Dermatol*. 2008;144(10). doi:10.1001/archderm.144.10.1303.
2. Thomson WL, Pujol-Nicolas A, Tahir A, Siddiqui H. A kick in the shins: the financial impact of uncontrolled warfarin use in pre-tibial haematomas. *Injury*. 2014;45(1):250–252. doi:10.1016/j.injury.2012.07.007.
3. Galán-Olleros M, Valle-Cruz JA, García-Coiradas J, et al. Tension subcutaneous haematomas associated with anticoagulants in the elderly: do they have earlier morbidity and mortality than hip fractures? *Rev Esp Cir Ortopédica Traumatol Engl Ed*. 2019;63(5):361–369. doi:10.1016/j.recote.2019.06.001.
4. Seppälä T, Grünthal V, Koljonen V. Pretibial lacerations among elderly patients: a province-wide study from Kymenlaakso, Finland, 2015–2019. *J Plast Reconstr Aesthet Surg*. January 2021:S1748681521000437 Published online. doi:10.1016/j.bjps.2020.12.107.
5. Dunkin CSJ, Elfleeth D, Ling C, Brown TPLH. A step-by-step guide to classifying and managing pretibial injuries. *J Wound Care*. 2003;12(3):109–111. doi:10.12968/jowc.2003.12.3.26473.
6. Lo S, Hallam MJ, Smith S, Cubison T. The tertiary management of pretibial lacerations. *J Plast Reconstr Aesthet Surg*. 2012;65(9):1143–1150. doi:10.1016/j.bjps.2011.12.036.
7. McClelland HM, Stephenson J, Ousey KJ, Gillibrand WP, Underwood P. Wound healing in pre-tibial injuries - an observation study. *Int Wound J*. 2012;9(3):303–310. doi:10.1111/j.1742-481X.2011.00884.x.
8. Cahill KC, Gillear D, Weir A, Cubison TCS. The epidemiology and mortality of pretibial lacerations. *J Plast Reconstr Aesthet Surg*. 2015;68(5):724–728. doi:10.1016/j.bjps.2015.01.011.
9. Pagan M. & Hunter J. Lower leg haematomas Potential for.pdf.
10. Wound Essentials 2015, Vol 10 No 1. haematomas-management-and-treatment (1).pdf.
11. Chami G, Chami B, Hatley E, Dabis H. Simple technique for evacuation of traumatic subcutaneous haematomas under tension. *BMC Emerg Med*. 2005;5(1):11. doi:10.1186/1471-227X-5-11.
12. De Souza B, Dey C, Ghataura A, Moir G. Calciphylaxis - a rare cause of pretibial hematoma. *Ann R Coll Surg Engl*. 2005;87(1):9–12. doi:10.1308/147870804894.
13. Teece S. Antibiotic prophylaxis for pretibial haematomas in the elderly population. *Emerg Med J*. 2004;21(4) 502-502. doi:10.1136/emj.2004.016568.
14. Suzuki H, Nobeyama Y, Sekiyama H, Kazama M, Tajima-Kondo S, Nakagawa H. Case of deep dissecting hematoma resulting in sepsis due to *Pseudomonas aeruginosa* infection. *J Dermatol*. 2018;45(3):e65–e66. doi:10.1111/1346-8138.14204.
15. Rafter L. Rafter - Debridement of a Traumatic Haematoma Using Larval Therapy.pdf.
16. Kindel N. Improved skin graft for a large superficial hematoma: a case study. *J Wound Ostomy Continence Nurs*. 2017;44(5):492–494. doi:10.1097/WON.0000000000000364.
17. Karthikeyan GS. Simple and safe treatment of pretibial haematoma in elderly patients. *Emerg Med J*. 2004;21(1):69–70. doi:10.1136/emj.2003.005801.
18. Beldon P. Beldon - Pretibial Injuries, Assessment and Management.pdf.
19. Wollina U, Lotti T, Vojvodic A, Nowak A. Dermatoporosis – the chronic cutaneous fragility syndrome. *Open Access Maced J Med Sci*. 2019;7(18):3046–3049. doi:10.3889/oamjms.2019.766.
20. Kaya G, Kaya A, Sorg O, Saurat J-H. Dermatoporosis: a further step to recognition. *J Eur Acad Dermatol Venereol*. 2018;32(2):189–191. doi:10.1111/jdv.14777.
21. Kaya G, Jacobs F, Prins C, Viero D, Kaya A, Saurat J-H. Deep dissecting hematoma: an emerging severe complication of dermatoporosis. *Arch Dermatol*. 2008;144(10). doi:10.1001/archderm.144.10.1303.
22. Kaya G, Kaya A, Sorg O, Saurat J-H. Dermatoporosis, a prevalent skin condition affecting the elderly: current situation and potential treatments. *Clin Dermatol*. 2019;37(4):346–350. doi:10.1016/j.clindermatol.2019.04.006.
23. Agale SV. Chronic leg ulcers: epidemiology, aetiopathogenesis, and management. *Ulcers*. 2013;2013:1–9. doi:10.1155/2013/413604.
24. Kahle B, Hermanns H-J, Gallenkemper G. Evidence-based treatment of chronic leg ulcers. *Dtsch Arzteblatt Online*. April 8, 2011 Published online. doi:10.3238/arztebl.2011.0231.
25. Quan H, Li B, Couris CM, et al. Updating and validating the charlson comorbidity index and score for risk adjustment in hospital discharge abstracts using data from 6 countries. *Am J Epidemiol*. 2011;173(6):676–682. doi:10.1093/aje/kwq433.
26. Kluger N, Impivaara S. Prevalence of and risk factors for dermatoporosis: a prospective observational study of dermatology outpatients in a Finnish tertiary care hospital. *J Eur Acad Dermatol Venereol*. 2019;33(2):447–450. doi:10.1111/jdv.15240.