

The Evaluation of Contrast-Enhancing Brain Lesions: Pitfalls in Current Practice

MARY PISZCZOR, D.O., GEORGE THORNTON, M.D.,
AND FRANK J. BIA, M.D., M.P.H.

*Infectious Disease Section, Department of Medicine, West Haven Veterans
Administration Medical Center, West Haven, Yale University School of Medicine,
New Haven, and Waterbury Hospital, Waterbury, Connecticut*

Received September 24, 1984

The definitive diagnosis of space-occupying brain lesions can be established more readily since the advent of computerized tomographic (CT) scanning. Some brain lesions are more clearly defined when contrast-enhancing agents are utilized; however, so-called ring-enhancing lesions are not pathognomonic for specific neurological entities. Review of the literature suggests that at least four disorders must be considered in the differential diagnosis of contrast-enhancing lesions. These include mature brain abscesses of any etiology, cerebrovascular accidents, and primary or metastatic brain tumors. Since the medical and surgical management of these conditions is quite different, it is critical to establish a diagnosis before therapy is instituted. In many instances the combination of history, physical examination, laboratory, and radiologic examination will enable physicians to correctly diagnose the etiology of such brain lesions.

However, we present two cases for which the above clinical and non-invasive parameters led to incorrect working diagnoses. Brain biopsy was required before appropriate management was eventually instituted. Potentially, such delays in diagnosis and institution of therapy can result in unnecessary morbidity and mortality. Each case illustrates the need to substantiate a presumptive diagnosis based on these clinical and radiographic criteria, regardless of how "typical" lesions may appear on CT scans.

CASE PRESENTATIONS AND DISCUSSIONS

DR. GEORGE THORNTON (*Clinical Professor of Medicine, Chief of Medicine, Waterbury Hospital*): The first patient is a 55-year-old black woman who was admitted to the Waterbury Hospital for the first time on July 30, 1982. On June 21 she had been referred to an ophthalmologist because she had experienced several weeks of blurred vision. She thought it had developed following extraction of an infected tooth. On physical examination by the ophthalmologist, a complete left VIth nerve palsy was found. Outpatient evaluation included a sedimentation rate of 66 mm/hour (nl < 20 mm/hour), negative VDRL (syphilis serology), and negative serum antinuclear antibodies. A left temporal artery biopsy did not show any granulomatous changes to suggest cranial arteritis and was nondiagnostic.

She was referred to Waterbury Hospital for a CT scan of her brain. Shortly after receiving the intravenous contrast media, she had a *grand mal* seizure and was admitted to the hospital. On physical examination she was well-developed, well-

This is the fourth of a series entitled, "Infectious Disease Rounds at Yale." Frank J. Bia, M.D., M.P.H., is guest editor.

Address reprint requests to: Frank J. Bia, M.D., Medical Service/111, West Haven VA Medical Center, West Haven, CT 06516

Copyright © 1985 by The Yale Journal of Biology and Medicine, Inc.
All rights of reproduction in any form reserved.

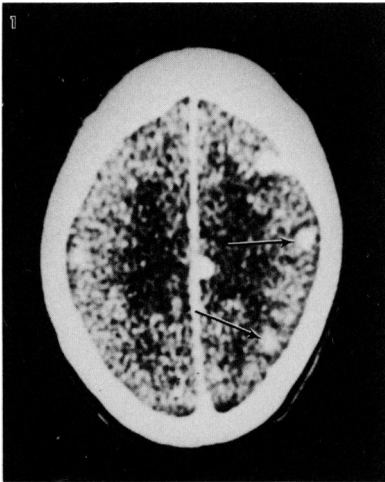

FIG. 1. CT scan of brain showing several discrete contrast-enhancing brain lesions (*arrows*) initially thought to represent tumor metastatic to brain. Subsequent pathological examination, however, showed them to be of infectious origin (patient No. 1).

nourished, and in no acute distress. Although she was drowsy, she was able to recount her history as noted. Her review of symptoms was otherwise negative. Physical examination revealed a right medial gaze palsy (III), a left lateral rectus palsy (VI), a right central facial nerve palsy (VII), and right hypoglossal (XII) nerve palsy. Her general physical examination was otherwise unremarkable.

On laboratory evaluation her hemoglobin (Hb) was 12.4 g per dl, white blood count was 3,000 cells/ μ l with 70 neutrophils, 1 band form, 27 lymphocytes, 1 monocyte, and 1 eosinophil. Her sedimentation rate was 37 mm/hour, serum transaminase (SGOT) was 19 U/ml (normal < 7), LDH was 249 U/ml (normal < 225), an alkaline phosphatase level was 167 IU/ml (normal < 100), and total bilirubin of 0.3 mg/dl (normal < 1 mg/dl).

Her CT scan (Fig. 1) shows multiple lesions within the CNS which enhance with injection and visualization of contrast media. The radiologist's interpretation of this scan was unequivocal. It showed the presence of metastatic tumor. Radiation therapy was begun (5,000 rads to the central nervous system). A subsequent lumbar puncture showed a normal opening pressure, a protein of 50 mg/dl, a cerebrospinal fluid (CSF) glucose of 60 mg/dl, and no cells. CSF bacterial and fungal cultures were all negative as was cytological examination for malignant cells. Cryptococcal antigen was not found in CSF. She underwent an extensive search for a primary tumor including mammography, full chest tomograms, a barium enema, colonoscopy, small bowel series, upper panendoscopy, intravenous pyelogram with tomography, bone scan, and renal, abdominal, and pelvic ultrasound examination. All were normal. She was discharged but continued to deteriorate, showing increasing difficulty with coordination, mild expressive aphasia, and with no reversal of her previously observed neurological findings.

The patient was readmitted with focal seizures. She had developed tinnitus, and her diplopia persisted, as did problems with coordination and expressive aphasia. Her physical examination was basically unchanged. Her Hb was 11.8 g/dl, white blood count 5,200 cells/ μ l with 34 neutrophils, 47 band forms, 15 lymphocytes, and 4 monocytes. Albumin was 3.6 g/dl, globulin 3.0 g/dl, SGOT had increased to 40 U/ml, LDH was 431 U/ml, and alkaline phosphatase was 362 IU/ml. A repeat CT scan of

the head was unchanged. A repeat pelvic sonogram suggested a pelvic mass, but on examination only a small cervical erosion was noted.

DR. VINCENT T. ANDRIOLE (*Chief, Infectious Disease Section, Yale Department of Medicine*): Was a liver biopsy performed? Was there any diagnostic consideration given to the possibility of multiple brain abscesses?

DR. GEORGE THORNTON: No, a liver biopsy was not performed. Brain abscess was considered, but because she had no fever, and everyone was convinced these were metastatic lesions, the diagnosis of brain abscess was not pursued, despite her history of a recent tooth extraction. In addition, her CSF was normal; i.e., normal protein, glucose, and neither inflammatory nor malignant cells were present.

DR. ANDRIOLE: What was the time interval from her dental procedure to the onset of symptoms?

DR. THORNTON: Two months.

DR. ANDRIOLE: This relatively young woman had multiple CNS lesions seen on a CT scan and focal neurologic lesions. She was initially leukopenic, had an elevated sedimentation rate, abnormal liver function tests, and an associated pelvic mass lesion. Looking at the initial CT scan, metastatic disease is not an unreasonable consideration, but the possibility of multiple brain abscesses is worrisome. There are diseases that involve the liver and the CNS, which, in their early phases, might not demonstrate an abnormal CSF. They include granulomatous diseases such as cryptococcal infection, histoplasmosis, and tuberculosis. Was her cell-mediated immunity tested?

DR. THORNTON: She was both tuberculin- and control antigen-negative on skin testing for delayed hypersensitivity.

DR. ANDRIOLE: Nocardial infections may also present like this. Actinomycosis should also be considered if you want to link the tooth extraction to the CNS lesions, but I have never seen that occur. Trying to tie together the pelvic findings also complicates matters, since pelvic involvement is atypical for most of the diseases mentioned, especially for cryptococcal infections. My approach would include an attempt to define the pelvic process. Also, was a liver biopsy performed at this time?

DR. THORNTON: A liver biopsy was not done. The general consensus was that this woman had a malignancy, and a pelvic mass. She was evaluated by members of the gynecology service who felt there was also a cervical lesion, which was subsequently biopsied.

A PHYSICIAN: Were dental X-rays or sinus films obtained?

DR. THORNTON: No, it was felt that CT scanning was adequate for ruling out pathology in these areas. The next procedure was a biopsy to evaluate the cervical lesion.

DR. ANDRIOLE: She was no longer in the childbearing years, so it would be unlikely for an intrauterine contraceptive device to be in place. Actinomycosis is a disease that has been frequently associated with these devices [1,2]. Was she ever febrile?

DR. THORNTON: No, she did not have any constitutional symptoms. The biopsy of her cervical lesion revealed granuloma formation. Subsequent liver biopsy showed a significant number of caseating granulomata. Acid-fast bacilli were seen in both pathological specimens (liver and cervix); urine and liver cultures also grew *Mycobacterium tuberculosis*, which was susceptible to all antituberculous drugs tested. She was started on three-drug antituberculous therapy with isoniazid, ethambutol, and rifam-

pin. She did terribly, and ultimately became so discouraged she went to a faith healer who recommended that she throw out her antituberculous medications. For the first time she developed fever; her mental status deteriorated; she was admitted to the hospital, and died. Postmortem examination of brain demonstrated multiple tuberculomas, including one in the pons, and several small lesions within the hypothalamus. The adrenal glands were not involved, nor was there any other evidence of genital tuberculosis besides the cervical lesion. The pelvic mass was actually a small ovarian cyst. The liver was massively involved with tuberculosis.

A PHYSICIAN: Perhaps the lesions found in the hypothalamus could help explain her lack of a febrile response to infection until immediately before her death.

DR. THORNTON: I think there are several important points to stress. First, without having a tissue diagnosis, there is always a risk in treating undiagnosed lesions with radiation. Second, tuberculomas usually occur as single lesions, and generally, no more than two are seen. Hence, this is a very unusual presentation.

DR. ANDRIOLE: It is worth noting that she did not experience much clinical deterioration while on steroid therapy for a month, even without receiving antituberculous therapy. In addition there was a complete lack of apparent constitutional symptoms despite her rather pronounced neurological findings. Was surgical resection of these lesions considered?

DR. THORNTON: Neurosurgical resection was considered, but given the locations of these lesions and the high probability of residual neurological deficits, it was not undertaken. Neurosurgical success with tuberculomas has been limited either to single lesions, or to single lesions which have an adjacent satellite lesion.

DR. ANDRIOLE: As the total number of reported cases of tuberculosis falls, the number presenting as pulmonary cases remains stable, so that one-sixth of all cases are now presenting with extrapulmonary foci [3]. In Connecticut, 20 percent of all recently reported cases had extrapulmonary involvement [4].

DR. THORNTON: Our ten-year experience at Waterbury Hospital has shown us a 35 percent incidence of extrapulmonary tuberculous disease. CNS tuberculosis is not the most common site for extrapulmonary foci; rather, it is tuberculous adenitis and pleurisy which account for 50 percent of these cases. Only 8–10 percent of extrapulmonary tuberculosis involves the CNS [3].

CASE 2

DR. MARY PISZCZOR (*Infectious Disease Fellow*): Our second case is that of a 61-year-old white male with a long history of alcohol abuse and of chronic obstructive pulmonary disease secondary to tobacco usage. He had recently been evaluated at Waterbury Hospital after being found unconscious on the street by the police. He was noted to be lethargic, but arousable. His neurological examination was grossly normal, and he subsequently signed out of the emergency room against medical advice. He was later found sleeping on the street and was brought to the West Haven VA Medical Center for evaluation.

In 1970 he had been diagnosed as having bladder carcinoma after an evaluation for persistent microscopic hematuria, but he had refused any therapy. He had also been hospitalized in 1975 for treatment of a right upper lobe lung abscess.

His neurologic examination showed no focal deficits and he was admitted to the neurology service for observation. His behavior was marked by episodes of inappro-

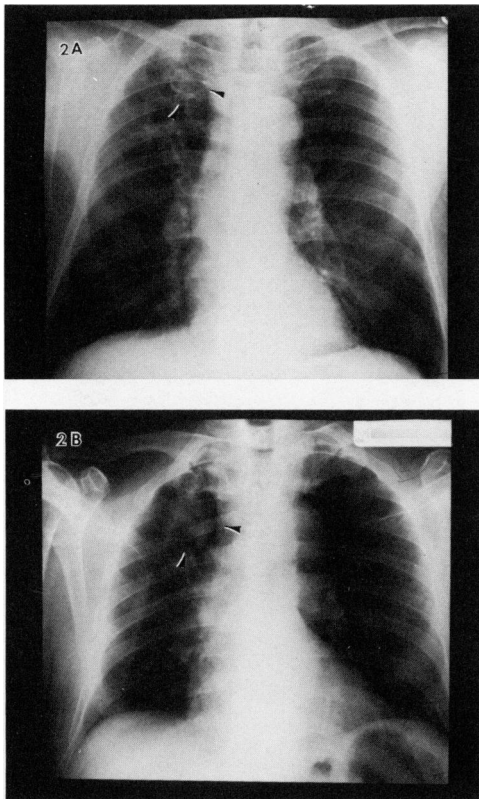


FIG. 2. A. Chest radiograph obtained in September 1978 showing a small right upper lobe cavitary lesion (*arrow*). B. Subsequent film obtained in August 1983 showing a large right upper lobe mass lesion (patient No. 2).

priate behavior, and he was noted to have poor short-term memory. Four days after admission he became much more lethargic and complained of mild right-sided headaches. He was afebrile, BP 100/70, pulse 60/minute, and respirations were regular, at a rate of 16/minute. Physical examination was remarkable for hepatomegaly and the presence of new neurological deficits which included mild left facial drooping, diffusely increased muscle tone, minimal weakness of his left lower extremity, and a positive Babinski reflex on the left. His laboratory parameters were normal, including complete blood count and blood chemistries.

Comparison of his previous chest X-rays with a new one showed progressive increase in the size of the infiltrate seen in the right upper lobe (Fig. 2A, B). The CT scan of his head revealed multiple parenchymal brain lesions that enhanced with injection of contrast dye (Fig. 3A, B), and a significant midline shift of brain from the right side. The largest lesion was located in the right frontal region. In all, 23 distinct lesions were identified.

DR. ANDRIOLE: The findings on CT scan are consistent with multiple brain abscesses. There are, however, a few other processes that can cause similar ring-enhancing lesions on CT scans. One of these is primary brain tumor, although usually single defects are seen. Metastatic lung tumor is always a possibility in a smoker, and, finally, cerebrovascular infarcts may also have such an appearance.

DR. PISZCZOR: The patient was started on parenteral chloramphenicol and the next morning was taken to surgery for a diagnostic neurosurgical procedure. An attempt

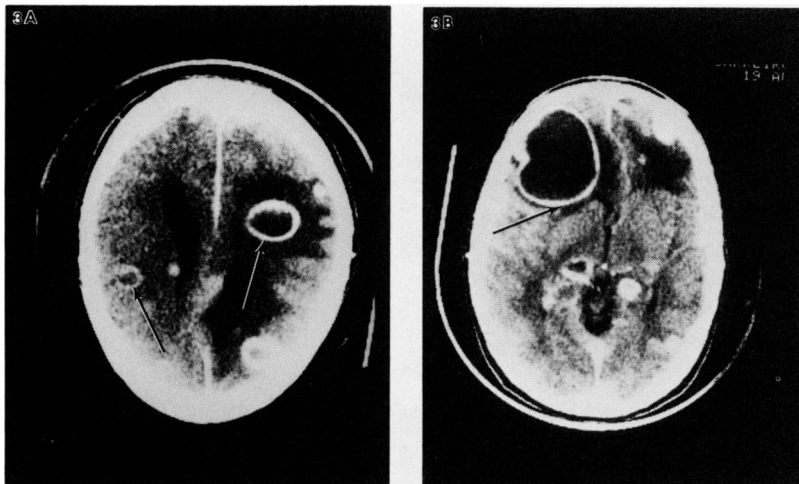

FIG. 3. CT scans obtained during evaluation of patient No. 2 for possible brain abscess. A. Ring-enhancing lesions (arrows) are clearly demonstrated. B. Large right-sided ring-enhancing lesion causing shift of brain contents leftward. At biopsy of this lesion infection was not encountered. Lesions proved to be metastatic in origin.

was made to aspirate the contents of the right frontal lesion; the material it contained was clear yellow fluid which had no foul odor. Gram stain showed only neutrophils and no organisms were seen.

DR. FRANK BIA (*Associate Professor of Medicine*): During surgery the neurosurgeon and I were amazed to see nonpurulent fluid aspirated from the lesion in the frontal lobe.

A PHYSICIAN: There was no history of neurological symptoms in the past, was there? Congenital cystic lesions of the nervous system might be a consideration if there had been such.

DR. BIA: The patient was a chronic alcoholic with very minimal neurological findings despite the fact that his head CT scan was so markedly abnormal.

DR. JAMES SABETTA (*Chief of Infectious Diseases, Greenwich Hospital*): How many of these lesions might be subdural hematomas?

DR. BIA: Certainly lesions similar to these have been seen following trauma, or with a frontal sinusitis which eroded through bone to cause a brain abscess. However, with such a large number of intraparenchymal lesions these diagnostic considerations appeared unlikely. At this point the neurosurgical procedure was extended.

DR. ANDRIOLE: In 1964 we actually inoculated mice intraperitoneally to recover *Nocardial* organisms. Is it possible that sampling one of 23 lesions in an alcoholic is not adequate for a definitive diagnosis?

DR. PISZCZOR: Possibly. A craniotomy was performed and the tissue was sent for frozen section. The biopsy of the lesion's capsule showed an undifferentiated carcinoma compatible with small cell carcinoma of the lung. The most likely source was his right upper lobe lung lesion.

DR. BIA: When they extended the surgical field and explored adjacent areas, there was no evidence of any purulent process.

DR. PISZCZOR: A follow-up CT after chemotherapy and radiation shows a decrease in the midline shift with complete resolution of some of the brain lesions.

DR. BIA: In the series entitled, "Current Clinical Topics in Infectious Diseases," there is an excellent review of the diagnosis of CNS lesions by CT scan. It points out that metastatic lung disease, brain abscesses, and primary glioblastomas may all have the same CT appearance [6].

DR. PISZCZOR: Since CT scanning of the brain has become available, mortality from brain abscess may have diminished considerably [7]. Factors that contribute to this are earlier diagnosis, accurate localization of abscesses pre-operatively, and rapid detection of post-operative complications. In the past, when arteriography and nuclear medicine scanning were our only available diagnostic modalities, localization of lesions was neither as efficient nor accurate. Although nuclear scans may be positive early in the course of brain abscess formation, arteriography tends to become positive later [8,9].

CT brain scanning also permits optimal timing of the operative procedure. The highest surgical success rates occur with lesions that are well encapsulated. The earliest manifestation of a brain abscess is cerebritis which appears as an irregular, poorly circumscribed area of low density. It may or may not enhance with contrast dye. If antibiotic treatment is not initiated at this point, a capsule will develop, usually within three weeks [10].

DR. BIA: The well-developed abscess is usually seen on CT scans as a regular, rounded, ring-shaped area of contrast enhancement. However, steroid therapy can significantly decrease the degree of ring enhancement [6,10].

A PHYSICIAN: Is it necessary to surgically drain all brain abscesses? Do all tuberculomas require surgical excision?

DR. THORNTON: Medical therapy of tuberculomas has been shown to be successful, as has antimicrobial therapy for brain abscess [11]. I think rather than emphasizing curative surgical therapy, these two cases emphasize the importance of surgery in making an accurate histopathological diagnosis.

DR. ANDRIOLE: Dr. Piszczor, would you care to comment on one aspect of arteriography which may be helpful in distinguishing brain abscess from metastatic disease or from primary brain tumors, and that is their vascular distribution? Arteriography does have a role since tumors may show neovascularity in their central portion, whereas an abscess cavity is nonvascular.

DR. JOHN RYAN (*Chief, Infectious Diseases, West Haven Veterans Administration Medical Center*): Tumors can outgrow their vascular supply.

DR. ANDRIOLE: Yes, they may have a small central necrotic area late in their course.

DR. PISZCZOR: The studies I reviewed did not compare the use of arteriography for differentiating tumor from brain abscess, but rather dealt with the arteriographic diagnosis of brain abscess. Findings include evidence of localized flow abnormalities from early venous drainage, delayed arterial emptying, and evidence of a mass defect [9].

COMMENTS

Prior to routine use of CT scans in the evaluation of neurological disease which began in the mid-1970s, the diagnosis of brain abscess was dependent upon electroen-

cephalography (EEG), technetium Te 99m brain scanning, cerebral angiography, and pneumoencephalography [12,13].

A brief review of the literature suggests there are inherent problems with each of these techniques. The technetium brain scan is often positive during early abscess formation, showing good resolution for lesions greater than one cm. The area of abnormality appears dense with activity, and in approximately 33 percent of scans, a "doughnut" or "halo sign" will be seen [8]. As we have noted with ring-enhancing CT lesions, this doughnut-shaped lesion has also been seen in association with tumor, cerebral infarction, or subdural hematoma [8]. In comparison to CT scanning, localization is not as accurate, posterior fossa lesions are more difficult to visualize, and post-operative uptake can obscure recognition of persistent or recurrent abscess [7].

Cerebral angiography was described by Beller et al. in 1978 as the safest and most accurate radiologic procedure to establish a diagnosis of brain abscess. With angiography the lesion could be localized in 90 percent of cases. Angiographic abnormalities included changes in circulation, such as early venous drainage or local slowing of circulation at the site of the inflammatory lesion. The avascular mass may be surrounded by ring-like staining in 20–48 percent of brain abscesses. Serial angiography may be more help in establishing the diagnosis, if there is a rapid change in the size or in the number of lesions. However, it should be noted that each of these angiographic findings are also consistent with tumor or infarction [12].

Pneumoencephalography now appears to be an outdated procedure. If performed in a patient with abscess and cerebral edema, one risks precipitating herniation [13]. Electroencephalography frequently demonstrates abnormalities, but lateralization and localization are not always apparent. In addition, the EEG pattern is often non-specific, and the differential diagnosis cannot be narrowed based on the results of this examination [7,12].

Computerized tomographic scanning of the brain heralded an era of improved diagnosis and prognosis for patients with brain abscess. CT scanning allows accurate staging of the infectious process, permitting surgical intervention under optimal conditions, i.e., when the abscess has encapsulated and is more easily enucleated. In addition, therapy of early cerebritis may be followed to resolution or to evolution of a mature abscess [14]. Post-operative complications such as bleeding or edema are more easily diagnosed, as is identification of recurrent abscess formation [7].

However, the differentiation of an underlying disease process based on its CT findings remains a difficult diagnostic and therapeutic problem. Coulam et al. have proposed the use of mathematical algorithms to address this difficulty [5]. Using Bayes' theorem and linear discriminant function analysis, they were able to select six parameters which could be used to partially separate these disease entities. The parameters included patient age, ring thickness variability, outside ring diameter, lesion-to-ring ratio, maximum ring thickness, and CT mean value in the ring center. Application of such algorithms has been limited, despite their acceptable accuracy in identifying abscess and tumor. The overall classification accuracy in Coulam et al.'s study was 86 percent (84 percent for abscess; 96 percent for tumor). Since 1974, several generations of CT scanners have been developed, and as CT resolution continues to improve, our ability to diagnose brain abscess accurately may also improve. Newer technology that is not yet available on a widespread scale, such as nuclear magnetic resonance scanning, still requires extensive clinical evaluation.

When questions persist with respect to the underlying pathology of intracerebral

ring-enhancing lesions, histopathological diagnosis by tissue biopsy still offers the definitive diagnosis. These two cases emphasize the need to define the nature of brain lesions in this manner. Using clinical and radiological findings alone, errors occurred in management and therapy of a woman with tuberculosis. A prompt surgical procedure avoided misdiagnosis in the alcoholic with metastatic disease. Despite the clear superiority of the CT scan over other radiologic procedures in defining intracerebral lesions, tissue biopsy remains the standard against which other techniques must be compared.

ACKNOWLEDGEMENT

The editor and authors express their gratitude to Eli Lilly and Co. for their generous support of this series and Mrs. Helen Losnes for expert word processing.

REFERENCES

1. Kelly J, Aaron J: Pelvic actinomycosis and usage of intrauterine contraceptive devices. *Yale J Biol Med* 55: 453–461, 1982
2. Schiffer MA, Elguezabal A, Munnaver S, et al: Actinomycosis infections associated with intrauterine contraceptive devices. *Obstet Gynecol* 45: 67–72, 1975
3. Farer LS, Lowell AM, Meador MP: Extrapulmonary tuberculosis in the United States. *Amer J Epidemiology* 109:205–217, 1979
4. Extrapulmonary tuberculosis in the United States. HEW Publication No. (CDC) 78-8360. U.S. Public Health Service, 1978
5. Coulam CM, Seshul M, Donaldson J: Intracranial ring lesions: Can we differentiate by computed tomography? *Investigative Radiol* 15: 103–112, 1980
6. New PFJ, Davis KR: The role of CT scanning in diagnosis of infections of the central nervous system. In *Current Clinical Topics in Infectious Diseases: 1*. Edited by JS Remington, MN Schwartz. New York, McGraw-Hill Book Company, 1980, pp 1–33
7. Rosenblum M, Hoff JT, Norman D, et al: Decreased mortality from brain abscesses since the advent of computerized tomography. *J Neurosurg* 49:658–668, 1978
8. Crocker EF, McLaughlin AF, Morris JG, et al: Technetium brain scanning in the diagnosis and management of cerebral abscess. *Am J Med* 56: 192–201, 1974
9. Jordan CE, James AE Jr, Hodges FJ: Comparison of the cerebral angiogram and the brain radionuclide image in brain abscess. *Radiology* 104: 327–331, 1972
10. Enzmann DR, Britt RH, Placone R: Staging of human brain abscess by computed tomography. *Radiology* 146: 703–708, 1983
11. Harder E, Al-Kawi MZ, Carney P: Intracranial tuberculoma: Conservative management. *Am J Med* 74: 570–576, 1983
12. Beller AJ, Sahar A, Praiss I: Brain Abscess: Review of 89 cases over a period of 30 years. *J Neurol Neurosurg Psychiatry* 36: 757–768, 1973
13. Segall HD, Rumbaugh CL, Bergeron RT, et al: Brain and meningeal infections in children. Radiologic considerations. *Neuroradiology* 6: 8–16, 1973
14. Zimmerman RA, Patel S, Bilaniuk LT: Demonstration of purulent bacterial intracranial infections by computed tomography. *Am J Roentgenol* 127: 155–165, 1976