

Eyelid Reconstruction

Mohammed S. Alghoul, MD*

Aaron M. Kearney, MD*

Salvatore J. Pacella, MD†

Chad A. Purnell, MD‡

Summary: *The goals of eyelid reconstruction are to provide adequate globe coverage, proper closing mechanics, preservation of tear film integrity, maintenance of an unobstructed visual field, and to recreate an aesthetically appealing eye. There are several requirements for an eyelid reconstruction to be considered “aesthetic.” Both lids have to be in proper position, with normal palpebral fissure width and height. The eyelid margin should be distinct from the preseptal segment. Tissues must be thin to blend seamlessly with local skin. Finally, the canthal angles must be sharp and crisp. In this paper, we provide a practical guide to simplify eyelid reconstruction. This is not an exhaustive review of all available reconstructive techniques; instead, this is a description of the techniques we have found effective that together can address many eyelid defects. (Plast Reconstr Surg Glob Open 2019;7:e2520; doi: 10.1097/GOX.0000000000002520; Published online 28 November 2019.)*

DESCRIPTION OF MOST EFFECTIVE PROCEDURES

It is helpful to conceptualize the periorbital region as a series of subunits (Fig. 1). Attention to reconstructive goals of each subunit is important to optimize outcomes.^{1,2} The lower eyelid has 3 subunits: pretarsal, preseptal, and lid–cheek junction. Reconstruction relies heavily on restoring structural support to prevent postoperative malposition. A recent study showed that in addition to size and width of the defect, the missing vertical subunit(s) plays an important role in predicting functional and aesthetic outcomes.³ The upper eyelid has 2 subunits with different requirements: the pretarsal and the upper lid fold or preseptal space. The main goal in upper eyelid repair is to prevent postoperative ptosis or lagophthalmos.

The medial and lateral canthal tendons, in continuity with the tarsus, form the tarsoligamentous sling (Fig. 2). Although the tarsus is considered in pretarsal segment reconstruction, canthal reconstruction requires special considerations. The lateral canthus is most often disturbed either as a result of lesion excision or with intentional canthotomy. The medial canthus is an anatomically complicated area containing the canthal tendon as well as the lacrimal drainage system. Defects involving the medial canthus should raise

suspicion for injury of the lacrimal apparatus.⁴ This area has a depressed contour that should be recreated with quilting sutures, particularly when using local flaps. The position and tension of medial canthal reconstruction is critical, in addition to restoring function to the lacrimal system.

The Lower Eyelid

Classification of lower eyelid defects has previously focused on the missing horizontal percentage of the lid.⁵ This is useful to guide pretarsal reconstruction, but is not as helpful when defects extend into other portions of the lid, nor does it predict postoperative lower lid malposition. We use a system of vertical subunits to classify defects and guide reconstruction.³ This section describes our reconstruction of choice in each subunit as well as pearls for management of large multi-subunit defects.

Pretarsal Defects

Defects of the pretarsal region require restoration of the bilamellar structure of the lid, resting tension of the tarsoligamentous sling, and positioning of the lateral canthus to create a crisp lateral canthal angle. These defects in isolation are at low risk for eyelid malposition. For isolated anterior lamellar defects, if the defect is small and the patient has preexisting skin or skin–muscle laxity in the lower lid, a blepharoplasty flap is ideal.⁶ The surrounding tissues are undermined in a subcutaneous or suborbicularis plane and closed (Fig. 3). Great care must be taken to avoid tension; only excess tissue that is readily apparent should be mobilized. For other wounds, full-thickness grafts can have good aesthetic results.⁷ Our primary choice for donor site is the upper eyelid, followed by the postauricular area. One area that is particularly amenable to skin

*From the *Division of Plastic and Reconstructive Surgery, Northwestern Memorial Hospital, Chicago, Ill.; †Plastic and Reconstructive Surgery, Scripps Clinic and Scripps Green Hospital, San Diego, Calif.; and ‡Department of Plastic Surgery, Shriners Hospitals for Children, Chicago, Ill.*

Received for publication July 2, 2019; accepted September 11, 2019.

Copyright © 2019 The Authors. Published by Wolters Kluwer Health, Inc. on behalf of The American Society of Plastic Surgeons. This is an open-access article distributed under the terms of the Creative Commons Attribution-Non Commercial-No Derivatives License 4.0 (CCBY-NC-ND), where it is permissible to download and share the work provided it is properly cited. The work cannot be changed in any way or used commercially without permission from the journal.

DOI: 10.1097/GOX.0000000000002520

Disclosure: *The authors have no financial interest to declare in relation to the content of this article.*

Related Digital Media are available in the full-text version of the article on www.PRSGlobalOpen.com

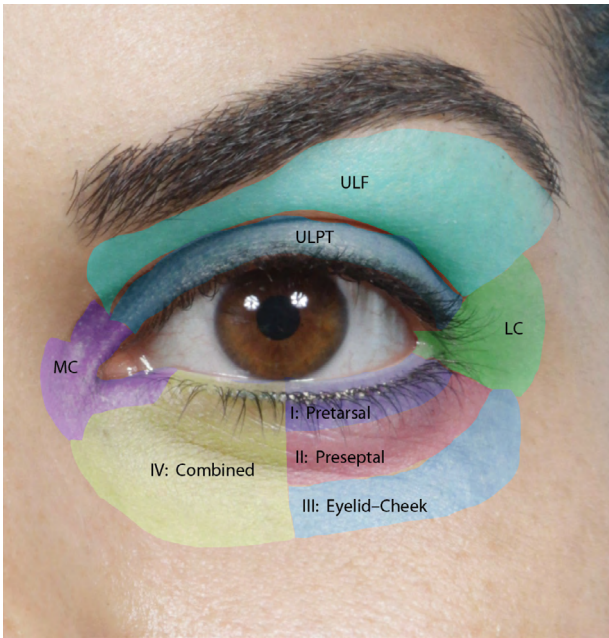


Fig. 1. The subunits of the periorbital region. LC, lateral canthus; MC, medial canthus; ULF, upper lid fold; ULPT, upper lid pretarsal.

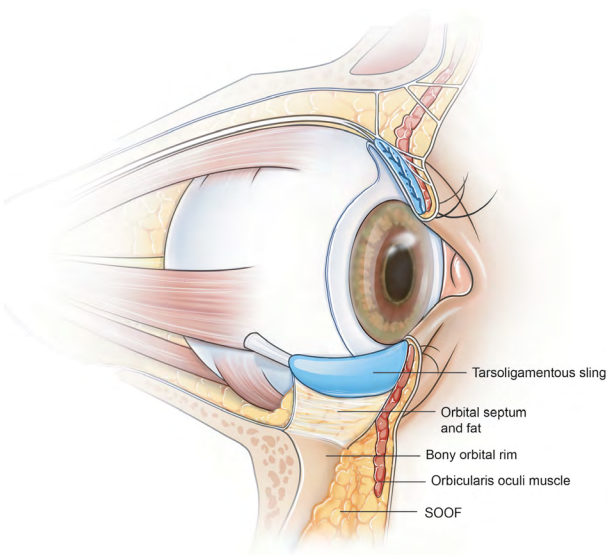


Fig. 2. The support structures of the eyelid that must be considered to maintain lower eyelid position. SOOF, sub-orbicularis oculi fat.

grafting is the medial canthal area. It does not tolerate bulk well, and the contraction of a skin graft actually improves contour with time.

For full-thickness pretarsal defects, reconstruction is guided by the percentage of lid width that requires excision. Irregular defects are converted to a full-thickness pentagon. For defects of <25% of the lid margin, primary closure is usually possible (See Video 1 [online], which displays primary closure of the lower lid.)

Defects between 25% and 50% of the lid margin can typically be closed with a Tenzel semicircular flap in combination with cantholysis.⁸ (See Video 2 [online], which displays Tenzel flap.) This flap is performed with a semicircular flap designed in the lateral orbital region. This is dissected deep to or superficial to the orbicularis muscle. The flap is undermined and rotated to close the defect after canthotomy and cantholysis are performed.⁹ The flap should be inset to reconstruct the lateral canthal attachment, using the dermis of the flap anchored to orbital periosteum. A periosteal flap can be elevated from the orbital rim for better fixation and to reestablish tension.¹ Once a defect approaches 50% of the lid, a Tenzel flap will result in notching or thinning of the suture line from excessive tension. For these defects, we perform a Hughes tarsoconjunctival flap for continuity of the posterior lamella and tarsus¹⁰ (Fig. 4). (See Video 3 [online], which displays Hughes tarsoconjunctival flap.) This flap is designed by everting the upper lid with a Desmarres retractor. A tarsal segment, the same width as the lower lid defect, is designed, beginning 3–4 mm from the upper lid margin to maintain structural integrity of the upper lid tarsal support. The flap is raised superiorly in the avascular plane between the levator palpebrae superioris and Mueller’s muscle, such that the flap is composed of the conjunctiva, tarsus, and Mueller’s muscle. Dissection is carried superiorly enough to facilitate tension-free inset of the flap into the lower lid. The flap is inset tarsus to tarsus, or incorporated into a canthoplasty in lateral defects. The anterior lamella is closed using a full-thickness skin graft or a blepharoplasty skin–muscle flap. Flap division occurs after 3–4 weeks.

Often, flap reconstruction in the pretarsal area requires lateral canthoplasty. A lateral orbital incision is made, and scissors are used to divide the appropriate limb of the tendon. An increase in laxity should be noted. The new canthal position is fixed with a double-armed suture with a circular needle. The suture is passed first through the lateral edge of the tarsus (if lid laxity is present, a strip of tarsus may need to be excised first), then through the orbital periosteum, with slight overcorrection in height. (See Video 4 [online], which displays lateral canthoplasty.) A drill hole is performed in cases where the periosteum is denuded or for more rigid fixation in complex cases. Tension should be adjusted to avoid laxity without creating a clothesline effect¹¹ or cheese wiring through the tissue. The lid margin between the 2 eyelids is reapproximated with a buried suture at the grey line to restore the lateral canthal angle.

Preseptal Defects

The key in reconstruction of preseptal defects is avoiding inferior vectors of pull. If a defect has healthy orbicularis at the base, a full-thickness skin graft is often adequate. For smaller defects that are deep to the orbicularis, we typically use a V–Y advancement flap or hatchet flap.^{12,13} Two key flap design tips improve cosmesis and minimize malposition. First, flaps should be designed within the boundaries of the preseptal orbicularis if possible. The septum should not be violated or mobilized along with the flap. Second, all flaps should be designed to pull in a horizontal vector. Closing the defect or the donor site with a downward pulling effect on the lid will

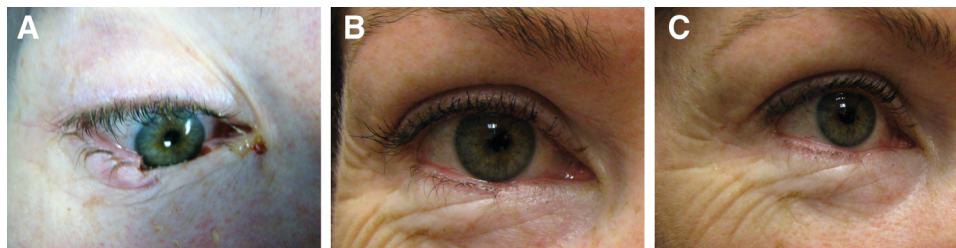


Fig. 3. Pretarsal lower lid defect (Type I) (figure courtesy of Dr. Salvatore Pacella). A, A woman with a defect of the pretarsal lower lid, approximately one-third of the lid width. B, One-year postoperative result following closure by primary closure and lateral cantholysis. C, Oblique view of one-year postoperative result.

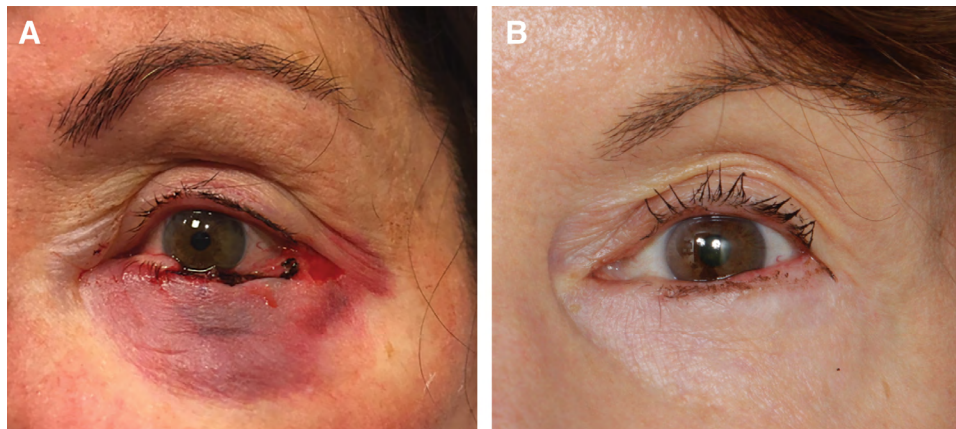


Fig. 4. Pretarsal lower lid defect > 50% of lid width (Type I). A, A 63-year-old woman with a large defect of the pretarsal lower lid. B, Six-month postoperative result following reconstruction with a Hughes tarsoconjunctival flap, blepharoplasty skin-muscle flap, and lateral canthoplasty.

result in postoperative malposition. This is particularly important in defects that are short vertically but wider horizontally, where the tendency is to close in the direction of shortest dimension. The Tripiet flap (unipedicle, or preferably bipedicle) can also be used to restore orbicularis muscle and skin. It is important to ensure the upper lid has adequate laxity before choosing this flap. Typically, unless defects are in close proximity to the lateral canthus or there is a preexisting lid laxity, a canthal resuspension procedure is not required in isolated preseptal defects.

Eyelid–cheek Junction

Defects of the eyelid–cheek junction are heterogeneous. The key reconstructive principle in this area is volume restoration to maintain structural support of the lower lid. Choices for reconstruction are similar to the preseptal area. We utilize full-thickness skin grafts, V–Y, or hatchet flaps for smaller defects (Fig. 5). For larger defects, this area is amenable to the deep-plane cervicofacial flap. Performing flap elevation deep to the superficial musculoaponeurotic system (SMAS) has been shown to result in less skin flap necrosis compared to subcutaneous flap elevation.¹⁴ We prefer to raise the cervicofacial flap in this plane for several reasons.^{15–17} The flap is thicker so it brings in more volume for deeper defects. Dissection in a sub-SMAS plane allows release of the zygomatic and masseteric retaining ligaments, which

provides complete release of the flap to facilitate tension-free medial mobilization. Also, the SMAS provides a strong fascial layer which can be anchored to orbital rim periosteum or bone to provide support for the flap. The flap is raised sharply in the sub-SMAS plane until the zygomaticus major origin is reached. At this point, the zygomatic retaining ligaments are released, taking care to avoid the zygomatic branch of the facial nerve.¹⁸ Medial to this point, the flap is dissected in the suborbicularis plane from the defect side to connect the flap to the defect. Additional mobilization is performed as needed. In the neck, we prefer to transition to a preplatysmal plane for dissection.

Another consideration at the lid–cheek junction is bony support. The orbital rim is a critical component of lid support and facial projection and should be reconstructed with titanium mesh, titanium plates, or bone grafts. Flaps should be suspended from the orbital rim periosteum, suture anchors, or drill holes through the bone to prevent tissue descent, which will create unaesthetic tissue contours and place tension on the lower lid.^{19,20}

Combined Defects of the Multiple Lower Lid Subunits

Combined defects have the highest risk of postoperative lid malposition.³ Large defects should be divided, and the pretarsal and preseptal/lid–cheek areas are addressed separately. In the pretarsal area, typically a Hughes flap is

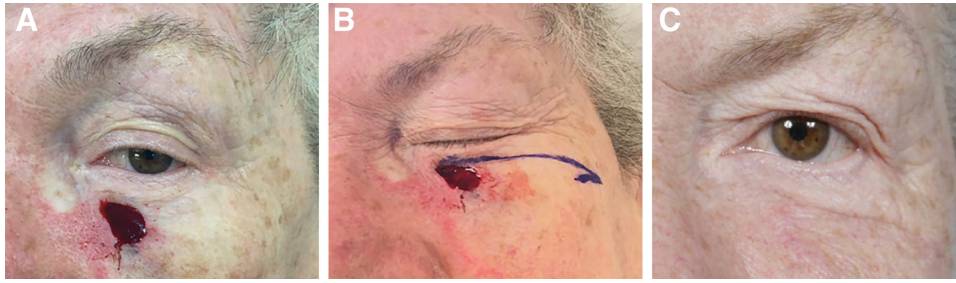

Fig. 5. Lid-cheek junction defect (Type III). A, A 74-year-old woman with a small defect involving the skin and muscle of the lid-cheek junction. B, Design of a hatchet flap. C, Three-month postoperative result following a "hatchet flap" advancement flap reconstruction from the lateral cheek.

used for the posterior lamella and to reconstitute the tarsoligamentous sling, with lateral canthal anchoring. This is covered with a full-thickness skin graft. In the preseptal/lid-cheek area, we use an anchored deep-plane cervicofacial flap for anterior lamella reconstruction, with a spacer of some type to support the tarsal reconstruction and to further decrease the risk of cicatricial retraction. If the conjunctiva inferior to the Hughes flap is missing, then the spacer is sutured to the Hughes flap tarsus superiorly and sutured into the conjunctiva of the fornix inferiorly. This will remucosalize with conjunctiva over time. If the conjunctiva is intact, the spacer is placed in the prior plane of the capsulopalpebral fascia. A stiff, well-supported graft is typically used, such as acellular porcine dermis, hard palate mucosa, or scapha cartilage.

UPPER LID

Upper eyelid defects can be divided into 2 separate subunits: pretarsal and the upper lid fold or preseptal space. The main goals in reconstruction are avoidance of postoperative malposition, that is, ptosis or lagophthalmos.

Pretarsal Defects

Pretarsal defects of the upper eyelid can be approached conceptually much like those of the lower lid. Defects of the anterior lamella are amenable to full-thickness skin grafting. Skin flaps should not be crossed over from the upper lid fold to the pretarsal space to maintain integrity of the crease. Full-thickness defects that are less than 25% of the lid width can be converted to a wedge and closed primarily. For defects of up to 50% of the lid, we utilize a Tenzel semicircular flap (oriented inferiorly) with division of the lateral canthal tendon to the upper lid to allow primary closure. Lateral canthoplasty should be performed in a similar fashion to the lower lid. If a lateral defect involves both eyelids, then a crisscross canthoplasty can be performed using drill holes (Fig. 6). For defects larger than 50% of the lid, just as in the lower lid, a lid switch flap (the Cutler-Beard flap) is used.²¹ This inferiorly pedicled, full-thickness flap of the lower lid is transposed under the lower eyelid margin and inset into the defect. (See Video 5 [online], which displays the Cutler-Beard flap.) The flap is designed the same width as the defect, with the transverse incision 5 mm below the lower lid margin, to preserve the inferior marginal arcade. Ear

cartilage or a contralateral upper lid tarsal graft (depending on height of defect) is used to reconstruct the tarsal defect. Closure is performed in 3 layers. The flap is left to heal for 4–8 weeks. At the second stage, the flap is divided at the margin of the upper lid. The remainder of the flap is sutured back into the lower lid donor site, with lateral canthal anchoring.²¹

Preseptal Defects

Repairing upper lid fold defects depends on the location and the presence of dermatochalasis. Medial defects are at higher risk for postoperative lagophthalmos and A-frame deformity. Therefore, unless the defect is small or excess skin is present, a local flap or skin graft should be used instead of primary closure. Lateral defects are more forgiving as there is usually excess skin in this area, particularly in the elderly. Principles of upper blepharoplasty incision design and execution should be followed to optimize cosmetic results and maintain the relationship of the 3 arcs of the upper eyelid-brow subunit.²² The crease should be marked, an upper blepharoplasty excision pattern is designed, and skin is removed in either direction as needed so that when the defect is closed primarily, the upper lid fold contour remains smooth. The skin can also be used as a rotation advancement flap, keeping the base attached at the eyelid crease.

Medial Canthal Defects

Defects of the medial canthus should prompt suspicion for lacrimal injury. For diagnosis, the puncta should be probed with a lacrimal probe. If 1 or both of the canaliculi have been damaged, reconstruction is performed. This can be done by feeding a lacrimal stent from the punctum (if present) into the remaining portion of the lacrimal system. (See Video 6 [online], which displays medial canthus reconstruction with canaliculostomy and medial canthoplasty.)

The stump of the canaliculus is sewn to the surrounding conjunctiva if the punctum has been lost. The stent is left in place for 3–6 months and then removed. This method of reconstruction results in little to no epiphora in most patients 3 months after stent removal.²³ More complicated reconstruction of the lacrimal system is possible secondarily, but is outside the scope of this review.^{5,23–25} For skin contouring, full-thickness skin grafts work well to reestablish the contour of the medial canthal region (Figs. 7 and 8). For smaller superficial defects, healing by secondary

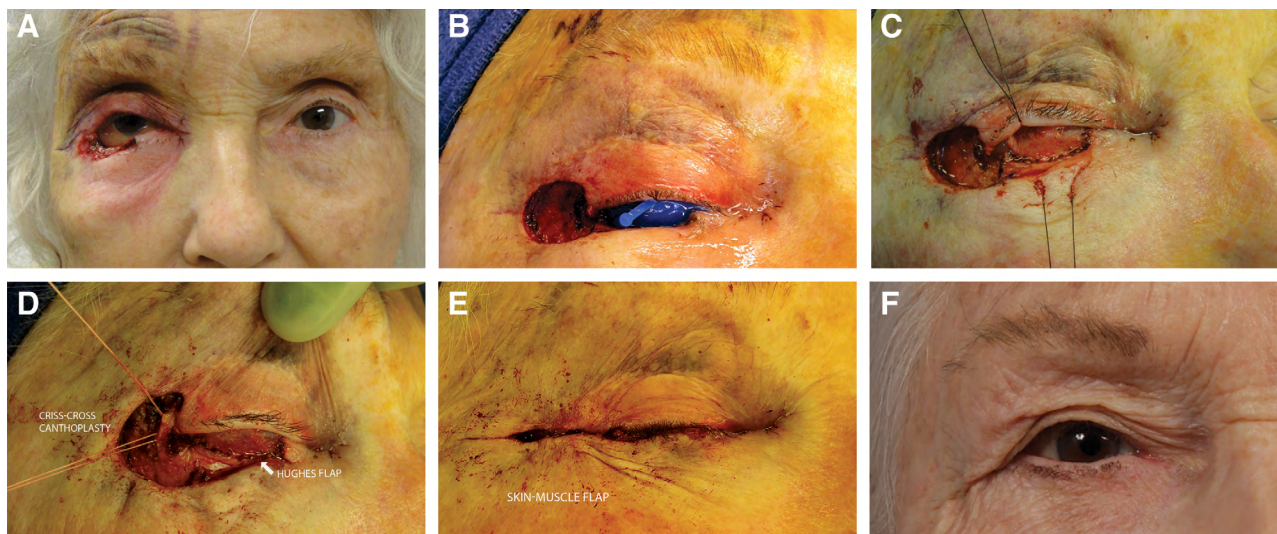


Fig. 6. Lateral canthus reconstruction with crisscross canthoplasty. A, 85-year-old woman with a full-thickness defect of the right lateral lower lid, full-thickness pretarsal defect comprising 75% of the width. B, Additional margins excised intraoperatively resulting in lateral orbital area and canthal defect with loss of upper lid lateral canthal attachment. C, Reconstruction of the lower lid defect with Hughes tarsoconjunctival flap. D, Crisscross lateral canthoplasty using the lateral edge of the Hughes flap and lateral edge of the upper lid. E, Reconstruction of the anterior lamella with a blepharoplasty skin-muscle flap. F, Postoperative result following division and inset of the Hughes flap.

intent can result in good cosmetic results.²⁶ If the medial canthal tendon support is lost, this can be resuspended to orbital periosteum (if present), or via transnasal wiring or plate techniques.^{4,27,28}

AVOIDING AND MANAGING COMPLICATIONS

Retrobulbar Hematoma

Bleeding within the orbit may compress the optic nerve, central retinal artery, and other critical structures, leading to loss of vision. A retrobulbar hematoma should be suspected in any postoperative patient with severe eye pain, edema, proptosis, decreased eye movement/reflexes, and visual changes. Treatment is release of sutures and prompt return to the operating room for hemostasis. If an operating room is not immediately available, the sutures may be released at the bedside with lateral canthotomy under local anesthesia.²⁹

Globe Perforation

Globe perforation is a rare but serious complication of periorbital surgery. Great care should be taken when injecting local anesthesia or using sharps around the eye. Perforation should prompt emergent ophthalmologic consultation. Broad-spectrum intravenous antibiotics should be given while awaiting evaluation.³⁰

Infection

Any infection around the eye should prompt a surgeon to rule out orbital cellulitis, which can progress to visual loss, cavernous sinus thrombosis, and meningitis. Orbital

cellulitis must be distinguished from the less serious preseptal cellulitis. The differentiation of these 2 entities on clinical examination alone is difficult. Orbital cellulitis should be suspected in a patient with decreased visual acuity, diminished pupillary reflexes, and restricted or painful extraocular movements. In equivocal cases, a contrast CT may help to clarify the diagnosis or reveal orbital abscess. Patients with suspected orbital cellulitis should be started on IV broad-spectrum antibiotics and monitored closely. Failure to improve or worsening of the infection mandates surgical irrigation and drainage.^{30,31}

Corneal Abrasion

Corneal abrasions can occur from mechanical trauma to the cornea intraoperatively or from suture irritation postoperatively. This may be avoided with the use of adequate lubrication and corneal shields. Any sutures placed facing the globe should be buried and covered by conjunctiva. Corneal abrasion is suggested by postoperative pain, sensitivity to light and foreign body sensation. If suture irritation is suspected, the surgical site should be inspected to ensure that the eye is protected.

Ophthalmologic consultation should be obtained if there is concern for abrasion. Fluorescein eyedrops may be used to confirm the diagnosis of corneal abrasion. Abrasions are treated with ophthalmic antibiotic ointment until symptoms have resolved and the cornea has reepithelialized, typically within 24 hours.³⁰

Dry Eye and Chemosis

Dry eye can develop after any eyelid reconstruction but is more likely to occur in complex repairs. Several factors are implicated, including impairment of the

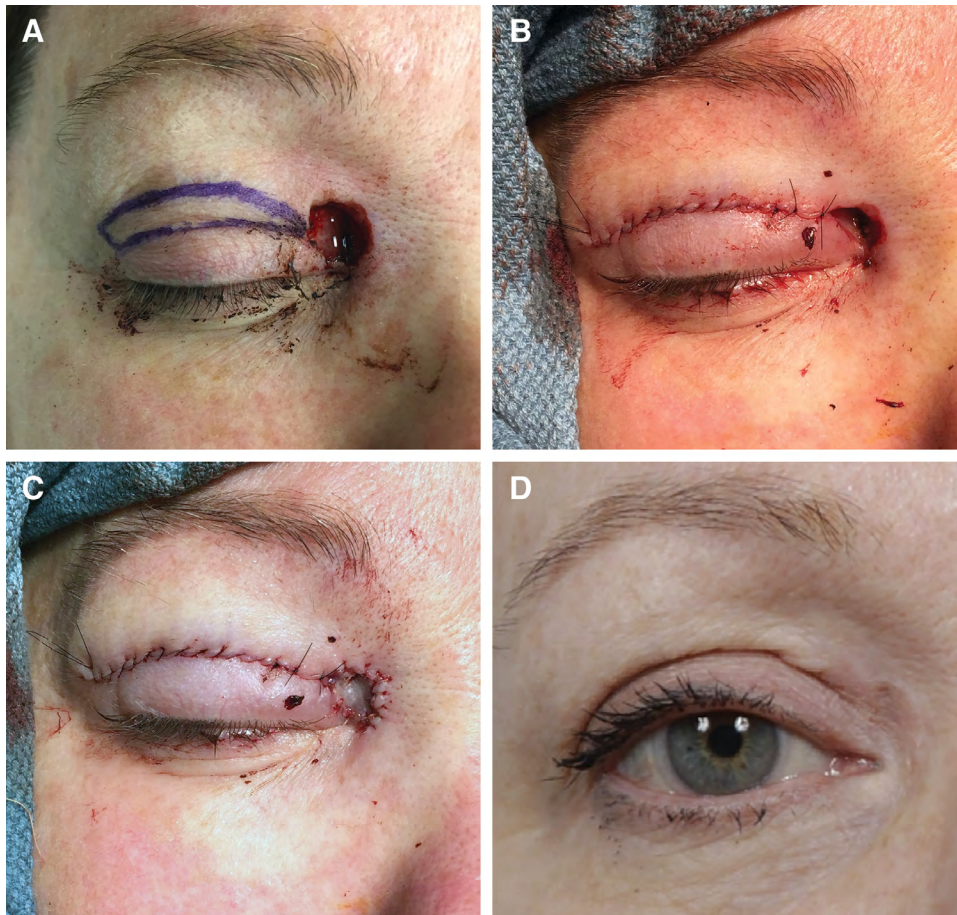


Fig. 7. Medial canthus defect. A, A 59-year-old woman with a defect involving the skin of the medial canthus. The orbicularis oculi was completely intact. The reconstructive plan was to use a full-thickness skin graft harvested from the right upper eyelid. B, Intraoperatively following skin graft harvest and donor site closure. C, Intraoperative photograph after skin graft inset. D, 5.5-month postoperative result. One triamcinolone and one 5-fluorouracil injection were given during postoperative follow-up visits when the graft appeared raised to prevent hypertrophic scarring and epicanthal fold formation.

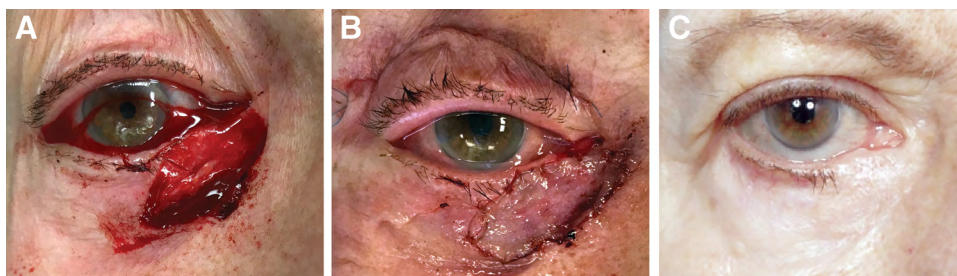


Fig. 8. Lower medial canthus defect. A, A 77-year-old woman with a skin defect of the medial canthus. The superior and inferior canaliculi were probed and found to be completely intact. B, On-table postoperative result following full-thickness skin graft harvested from bilateral upper eyelids. C, Seven-month postoperative result. The skin graft was injected with 5-fluorouracil twice during follow-up visits before the photograph when the graft appeared slightly raised.

blink reflex and increased evaporation due to decrease in production of the oil layer protecting the tear film. Chemosis is multifactorial and is caused by dryness, inflammation, venous congestion, and lymphatic disruption.³² Postoperative patients should be treated with preservative-free artificial tears and nighttime moisturizing

ointment. For chemosis, steroid-containing ointments help reduce inflammation. For moderate to severe chemosis, temporary closure of the eyes with a tarsorrhaphy suture and snip conjunctivotomy may be necessary. If lower lid malposition is present, it must be treated to resolve dry eye symptoms.

Lagophthalmos

Lagophthalmos is caused by skin deficiency of the upper lid. It is more commonly seen medially than laterally. It can also be caused by denervation of the orbicularis oculi muscle due to nerve injury from the resection or flap elevation. Lower lid malposition can also contribute. If present, skin deficiency or scar contracture in the upper lid should be treated with release and full-thickness skin grafting.

Lid Malposition, Entropion, and Ectropion

Lid malposition is a difficult complication after lower lid procedures. Excess skin resection (or inadequate replacement), scarring, or inadequate tension of the tarsoligamentous sling can result in malposition. In severe cases, this can result in exposure keratopathy. In the early postoperative period, mild lid malposition should be addressed with gentle upward massage of the lid. If this persists, the site of contracture should be identified and injected with 5-fluorouracil.³³ If lid malposition persists despite these treatments, surgical correction should be considered. Reoperation should be delayed until at least 3 months from the index procedure if possible. Diagnosis of the affected lamellae is important. Skin grafting can be used to correct anterior lamellar deficiency. Deficiency of the posterior lamella is suggested by failure of the lid to elevate with upward traction on the central lower lid. Deficiency can be addressed through a lysis of adhesions with or without spacer grafting.³⁰ Adjunct procedures such as midface lift and/or lateral canthoplasty may be necessary as well.

PEARLS AND PITFALLS

1. Maintain meticulous hemostasis, especially when dealing with the orbicularis and orbital fat. Use fine oculo-plastic instruments for gentle handling of tissue and appropriate suture.
2. Set the lateral canthal area under proper tension and in the proper position particularly in patients with preexisting risk factors (negative vector, lid laxity). Persistent lid malposition following eyelid reconstruction can be difficult to correct secondarily.
3. In multilevel lower eyelid defects, separate flap reconstruction of the pretarsal and preseptal/lid-cheek junction segments will result in better aesthetic and functional outcomes.
4. Always confirm the integrity of the lacrimal system in medial canthal defects.
5. Although the traditional reconstructive teaching for full-thickness eyelid defects is to use a graft for 1 lamella and a flap for the other, we often use flaps for both lamellae to improve aesthetic outcomes. When full-thickness skin grafts are used, they graft should be kept relatively loose during inset to account for postoperative contracture.

WHAT PATIENTS SHOULD KNOW BEFORE HAVING THIS PROCEDURE

The vast majority of eyelid reconstruction can be completed as outpatient surgery under local anesthesia, sometimes with the addition of intravenous sedation. Larger eyelid defects that involve multiple vertical subunits are more complex to repair, have worse aesthetic and functional outcomes, and are more likely to need multiple or secondary surgeries. Postoperative recovery can be prolonged with bruising and edema in the periorbital area. Gentle compression over the surgical site in the first 48 hours can help reduce swelling. Aggressive lubrication with preservative-free artificial tears and ointment at night is critical.

Mohammed S. Alghoul, MD

Division of Plastic and Reconstructive Surgery
Northwestern Memorial Hospital
675 N. Saint Clair St, Suite 19-250
Chicago, IL 60611
E-mail: mo.alghoul@gmail.com

REFERENCES

1. Alghoul M, Pacella SJ, McClellan WT, et al. Eyelid reconstruction. *Plast Reconstr Surg.* 2013;132:288e–302e.
2. Codner MA, McCord CD, Mejia JD, et al. Upper and lower eyelid reconstruction. *Plast Reconstr Surg.* 2010;126:231e–245e.
3. Alghoul MS, Bricker JT, Vaca EE, et al. Lower eyelid reconstruction: a new classification incorporating the vertical dimension. *Plast Reconstr Surg.* 2019;144:443–455.
4. Zide BM, McCarthy JG. The medial canthus revisited—an anatomical basis for canthopexy. *Ann Plast Surg.* 1983;11:1–9.
5. Spinelli HM, Jelks GW. Periocular reconstruction: a systematic approach. *Plast Reconstr Surg.* 1993;91:1017–24; discussion 1025.
6. McVeigh KA, Caesar R. Upper eyelid reconstruction using a blepharoplasty flap. *Ophthalmic Plast Reconstr Surg.* 2017;33:147–149.
7. Rathore DS, Chickadasarahilli S, Crossman R, et al. Full thickness skin grafts in periocular reconstructions: long-term outcomes. *Ophthalmic Plast Reconstr Surg.* 2014;30:517–520.
8. Tenzel RR, Stewart WB. Eyelid reconstruction by the semicircle flap technique. *Ophthalmology.* 1978;85:1164–1169.
9. Tenzel RR. Reconstruction of the central one half of an eyelid. *Arch Ophthalmol.* 1975;93:125–126.
10. Hishmi AM, Koch KR, Matthaei M, et al. Modified Hughes procedure for reconstruction of large full-thickness lower eyelid defects following tumor resection. *Eur J Med Res.* 2016;21:27.
11. McCord CD, Boswell CB, Hester TR. Lateral canthal anchoring. *Plast Reconstr Surg.* 2003;112:222–37; discussion 238.
12. Gurunluoglu R, Williams SA, Olsen A. Reconstructive outcomes analysis of lower eyelid and infraorbital skin defects using 2 hatchet flaps: a 6-year experience. *Ann Plast Surg.* 2014;72:657–662.
13. Marchac D, de Lange A, Bine-bine H. A horizontal V-Y advancement lower eyelid flap. *Plast Reconstr Surg.* 2009;124:1133–1141.
14. Jacono AA, Rousso JJ, Lavin TJ. Comparing rates of distal edge necrosis in deep-plane vs subcutaneous cervicofacial rotation-advancement flaps for facial cutaneous Mohs defects. *JAMA Facial Plast Surg.* 2014;16:31–35.
15. Becker FF, Langford FP. Deep-plane cervicofacial flap for reconstruction of large cheek defects. *Arch Otolaryngol Head Neck Surg.* 1996;122:997–999.
16. Kroll SS, Reece GP, Robb G, et al. Deep-plane cervicofacial rotation-advancement flap for reconstruction of large cheek defects. *Plast Reconstr Surg.* 1994;94:88–93.

17. Tan ST, MacKinnon CA. Deep plane cervicofacial flap: a useful and versatile technique in head and neck surgery. *Head Neck*. 2006;28:46–55.
18. Alghoul M, Bitik O, McBride J, et al. Relationship of the zygomatic facial nerve to the retaining ligaments of the face: the subSMAS danger zone. *Plast Reconstr Surg*. 2013;131:245e–252e.
19. Okazaki M, Haramoto U, Akizuki T, et al. Avoiding ectropion by using the Mitek anchor system for flap fixation to the facial bones. *Ann Plast Surg*. 1998;40:169–173.
20. Harris GJ, Perez N. Anchored flaps in post-Mohs reconstruction of the lower eyelid, cheek, and lateral canthus: avoiding eyelid distortion. *Ophthalmic Plast Reconstr Surg*. 2003;19:5–13.
21. Fischer T, Noever G, Langer M, et al. Experience in upper eyelid reconstruction with the cutler-beard technique. *Ann Plast Surg*. 2001;47:338–342.
22. Vaca EE, Bricker JT, Helenowski I, et al. Identifying aesthetically appealing upper eyelid topographic proportions. *Aesthet Surg J*. 2019;39:824–834.
23. van Burink MV, Rakhorst HA, van Couwelaar GM, et al. Postoncological lacrimal duct reconstruction: a practical classification system for reconstructive planning and short-term results of a case series. *J Plast Reconstr Aesthet Surg*. 2018;71:1796–1803.
24. McCord CD Jr. Canalicular resection and reconstruction by canaliculostomy. *Ophthalmic Surg*. 1980;11:440–445.
25. Weber R, Draf W. Reconstruction of lacrimal drainage after trauma or tumor surgery. *Am J Otolaryngol*. 1994;15:329–335.
26. Shafi F, Rathore D, Johnson A, et al. Medial canthal defects following tumour excision: to reconstruct or not to reconstruct? *Orbit*. 2017;36:64–68.
27. Kelly CP, Cohen AJ, Yavuzer R, et al. Medial canthopexy: a proven technique. *Ophthalmic Plast Reconstr Surg*. 2004;20:337–341.
28. Wittkamp AR, Mourits MP. A simple method for medial canthal reconstruction. *Int J Oral Maxillofac Surg*. 2001;30:342–343.
29. Trussler AP, Rohrich RJ. MOC-PSSM CME article: blepharoplasty. *Plast Reconstr Surg*. 2008;121(1 Suppl):1–10.
30. Lelli GJ Jr, Lisman RD. Blepharoplasty complications. *Plast Reconstr Surg*. 2010;125:1007–1017.
31. Vairaktaris E, Moschos MM, Vassiliou S, et al. Orbital cellulitis, orbital subperiosteal and intraorbital abscess: report of three cases and review of the literature. *J Craniomaxillofac Surg*. 2009;37:132–136.
32. McCord CD, Kreymerman P, Nahai F, et al. Management of post-blepharoplasty chemosis. *Aesthet Surg J*. 2013;33:654–661.
33. Yoo DB, Azizzadeh B, Massry GG. Injectable 5-FU with or without added steroid in periorbital skin grafting: initial observations. *Ophthalmic Plast Reconstr Surg*. 2015;31:122–126.