



Original Article

Endoscopic third ventriculostomy in the treatment of hydrocephalus: A 20-year retrospective analysis of 209 consecutive cases

Igor Vilela Faquini¹, Ricardo Brandão Fonseca², Alyne Oliveira Correia², Auricelio Batista Cezar Junior¹, Eduardo Vieira De Carvalho Junior³, Nivaldo Sena de Almeida³, Hildo Rocha Cirne Azevedo-Filho³

¹Department of Pediatric Neurosurgery, Instituto Materno Infantil Professor Fernando Figueira-IMIP and Department of Neurosurgery, Hospital da Restauracao, Recife, ²Department of Neurosurgery, HU-Univasf and IMIP-Petrolina, ³Department of Neurosurgery, Hospital da Restauracao, Recife, Pernambuco, Brazil.

E-mail: Igor Vilela Faquini - ifaquini@yahoo.com.br; *Ricardo Brandão Fonseca - ricardoneurocirurgia@uol.com.br; Alyne Oliveira Correia - alyne251@hotmail.com; Auricelio Batista Cezar Junior - auricelio_jr@hotmail.com; Eduardo Vieira De Carvalho Junior - evcj2005@gmail.com; Nivaldo Sena de Almeida - nivasena@globo.com; Hildo Rocha Cirne Azevedo-Filho - azevedoh@uol.com.br



***Corresponding author:**

Ricardo Brandão Fonseca,
Department of Neurosurgery,
HU-Univasf, Petrolina,
Pernambuco, Brazil.

ricardoneurocirurgia@uol.com.br

Received : 09 May 2021

Accepted : 02 July 2021

Published : 03 August 2021

DOI

10.25259/SNI_458_2021

Quick Response Code:



ABSTRACT

Background: Endoscopic third ventriculostomy (ETV) has been shown to be a sufficient alternative to shunts in surgical treatment of obstructive hydrocephalus. Long-term failure, age limitations, and outcome by cause are some of the issues debated in literature. The objective of this article is to analyze the clinical success and failure of ETV and its main complications.

Methods: A total of 209 patients with hydrocephalus were submitted to ETV, including a mixed population of children and adults (from 0 to 59 years). Patients were divided into five groups: A – tumors, B – aqueductal stenosis, C – myelomeningocele, D – infection and hemorrhage, and E – arachnoid cyst. Variables were analyzed: age, ETV success rate, cerebrospinal fluid (CSF) fistula, mortality, and complications.

Results: The two main causes of hydrocephalus were tumors (44.9%) and aqueductal stenosis (25.3%). The overall success rate was of 82.8%, and patients in Group E had the highest rate 90.9%. Group A had a success rate of 89.3%, and Group B had a rate of 88.6%. The ETV success rate was significantly higher in patients older than 1 year ($P < 0.001$); the former also had a lower risk of CSF fistula ($P < 0.0001$). The overall mortality rate was 2.8%.

Conclusion: Better results were observed in the groups of patients with tumors, aqueductal stenosis, and arachnoid cysts, while those whose primary causes of hydrocephalus were myelomeningocele, infections, or bleeding had higher rates of failure after the procedure. This study demonstrated that age under 1 year and hydrocephalus caused by myelomeningocele, bleeding, and infection were considered independent risk factors of poor prognosis in ETV.

Keywords: Endoscopic third ventriculostomy, Hydrocephalus, Posterior fossa tumor, Treatment outcome

INTRODUCTION

Hydrocephalus is a pathology caused by excessive increase in the amount of cerebrospinal fluid (CSF) in the brain ventricles, thus increasing intracranial pressure and injuring the brain. In

Brazil, the occurrence of hydrocephalus is reported in 1–3 of every 1000 live births. Moreover, approximately 60% of cases affect newborns, whereas approximately 40% of cases are in elderly patients, and it is more likely to develop in the male sex.^[17]

In pediatric patients, hydrocephalus continues to be one of the most recurrent causes of admission to pediatric neurosurgery units. In 1923, William Jason Mixter demonstrated that endoscopic fenestration of the floor of the third ventricle could successfully treat congenital hydrocephalus, thus giving rise to endoscopic third ventriculostomy (ETV) as a therapeutic approach to hydrocephalus, avoiding extracranial shunts.^[17] As the years passed, this technique has been enhanced and accepted as a frequently used tool in the treatment of hydrocephalus. The advantages of ETV with respect to extracranial shunts have been frequently reported, demonstrating better results regarding risk of infection and failure rate.^[5]

ETV is an intracerebral surgery performed by the neuroendoscopic approach, which makes it possible to divert the flow of CSF trapped in the ventricles to the subarachnoid cisterns. The efficiency of ETV has frequently been described in the literature, and it is dependent on correct surgical indication.^[23] There are, nonetheless, discrepancies regarding the efficacy rates, given that neurosurgery services report different results, especially in the pediatric population.^[2,17,23] One possible reason for this lack of data is related to failure to observe technical details, given that this procedure continues to be restricted among neurosurgery services.^[22,23]

In 1994, ETV was adopted as an important tool for the treatment of children and adults with hydrocephalus in two leading neurosurgical centers located in the Northeast Region of Brazil. The objective of this article is to analyze the clinical success and failure of ETV and its main complications.

MATERIALS AND METHODS

From April 1994 to June 2014, 209 patients with hydrocephalus (140 males, 66.9%, and 69 females, 33%) were submitted to ETV at the Hospital da Restauração and the Professor Fernando Figueira Integral Medicine Institute. All patients diagnosed with hydrocephalus operated by ETV in the mentioned period were included in the study. No patients were excluded from this study. We performed magnetic resonance imaging preoperatively in 60% of patients, and the remaining cases were diagnosed by computed tomography. Follow-up ranged from 1 to 98 months, with an average of 19.2 months. Postoperative control magnetic resonance imaging was performed in 80% of cases. Based on hydrocephalus etiology, patients were divided into the following five groups: Group A – tumors, Group B – aqueductal stenosis, Group C – myelomeningocele, Group D

– infection or hemorrhage, and Group E – arachnoid cysts (posterior cranial fossa cysts).

The patients included in this study had intracranial hypertension with Cushing’s triad (hypertension, bradycardia, and irregular breathing rhythm) and/or symptoms such as vomiting, headache, and altered level of consciousness, and, in children, aspects such as bulging of the anterior fontanelle, increased head circumference, engorgement of superficial veins, and other clinical signs. Choice of surgical treatment was discussed and evaluated on a case-by-case basis. The criteria used to evaluate success of treatment with ETV were clinical improvement and shunt independence (clinical success), with disappearance of initial symptoms, in conjunction with confirmation by imaging examination (magnetic resonance in 80% of cases), in accordance with the Canadian Pediatric Study Group.^[7] In the present study, we did not perform ventricular measurements after completing endoscopy.

Characteristics of patients

The main results are summarized in [Table 1]. In total, 209 patients were operated during the 20-year period.

Table 1: Characteristics of all the patients according to sex, age, and division of primary causes of hydrocephalus by group, according to clinical success or failure.

	n (%)	Clinical success of ETV, n (%)	Clinical failure of ETV, n (%)	P
Sex				
Female	69 (33)			
Male	140 (66.9)			
Age				
<1 year	17 (8.1)	2 (11.7)	15 (88.2)	<0.0001*
>1 year	192 (91.8)	171 (89)	21 (10.9)	
Groups				
A – Tumoral	94 (44.9)	84 (89.3)	10 (10.6)	
B – Aqueductal stenosis	53 (25.3)	47 (88.6)	6 (11.3)	
C – Myelomeningocele	10 (4.7)	5 (50)	5 (50)	
D – Postinfectious/hemorrhage	41 (19.6)	27 (65.8)	14 (34.1)	
E – Arachnoid cyst	11 (5.2)	10 (90.9)	1 (9)	
Total	209 (100)	173 (82.8)	36 (17.2)	

*P-value for age with clinical success or clinical failure. Significant P-values in bold. Chi-square test.

[Table 1] characterizes all patients by sex and age and shows percentages according to primary cause of hydrocephalus. Patients' ages ranged from 0 to 59 years, with an average of 21.2 years, and they were divided by age into two categories: younger than 1 year and older than 1 year.

Endoscopic technique

All surgeries were performed using a 0° rigid endoscope (Aesculap, 2.7 mm diameter). The head was flexed at 30° and trepanation was performed at Kocher's point. The puncture cannula was inserted by the freehand technique, and it was never fixed during the procedure.

The floor of the third ventricle was perforated and dilated with a 4 Fr Fogarty balloon catheter. Following dilation, the endoscope was advanced toward the opening to visualize structures of the prepontine cistern and to confirm perforation of the Liliequist membrane. Hemostasis of the puncture tunnel was obtained with Surgicel®. Surgery concluded with the closure of subcutaneous and epidermal layers.^[18]

It worth underscoring that perforation of the Liliequist membrane is considered essential to a successful procedure. In ETV, after opening the tuber cinereum, the underlying structure is the Liliequist membrane, which is the upper limit of the interpeduncular cistern. If the membrane is not opened, communication between the ventricular system and the subarachnoid system is not achieved, in which case, the operation is not completed and is ineffective.^[23]

Statistical analysis

All data were collected from patients' medical files in a retrospective cohort study. Statistical analysis was carried out using IBM SPSS version 20 (IBM Corp., Charlotte, NC, USA) and Prism 5.0 GraphPad (GraphPad Software Inc., La Jolla, CA, USA). Frequency tests were performed to determine percentages; Chi-square test (χ^2) was used to analyze categorical variables. Results were considered significant at $P < 0.05$.

RESULTS

Morbidity/Mortality

The main results are summarized in [Table 2]. The most common postoperative complication was subdural effusion (8.1%) followed by CSF leak (7.6%). We also observed meningitis in 4.3% of cases and transient third nerve palsy in 3.8% of cases [Table 2]. None of the patients who developed meningitis had received prior external ventricular drainage. The incidence of CSF leakage was closely related to age; 47% (8 cases) of patients younger than 1 year old had this complication, in comparison with only 4.1% (8 cases) of

those older than 1 year ($P < 0.0001$). Among patients who had CSF leak, 43.7% (7 cases) developed meningitis, in comparison with only 12.5% (2 cases) of those who had not presented this complication. Overall mortality was 2.8% (0.4% related to ETV and 2.3% unrelated to the procedure).

Prognosis after ETV

Average duration of follow-up was 19.2 months (ranging from 1 to 98 months).

During this period, overall success rate (clinical success) was 82.8% (173 patients). No procedure was aborted due to bleeding or anatomical variations. The method proved ineffective in 17.2% (36 patients) of cases, and all of those were submitted to a ventriculoperitoneal shunt.

Taken alone, patients in Group E (arachnoid cysts) had the highest success rate, namely, 90.9%. Patients in Group A had a success rate of 89.3%, and patients in Group B had a rate of 88.6%.

Patients older than 1 year had a significantly higher success rate in relation to those younger than 1 year of age ($P < 0.001$) [Figure 1], and they had a lower risk of CSF fistula ($P < 0.0001$) [Figure 2]. Overall mortality was 2.8%, and mortality due to causes unrelated to the procedure (clinical complications) was higher in relation to mortality due to causes directly related to the ETV ($P < 0.0001$).

DISCUSSION

ETV has been established as the treatment of choice for cases of obstructive hydrocephalus in recent years. The need for equipment and know-how makes its dissemination throughout multiple centers in developing countries

Table 2: Mortality and morbidity.

	n (%)	P
Mortality	6 (2.8)	
Related to ETV	1 (0.4)	<0.0001*
Unrelated to ETV	5 (2.3)	
Morbidity		
CSF leak	16 (7.6)	
<1 year	8 (47)	<0.0001†
>1 year	8 (4.1)	
Meningitis	9 (4.3)	
CSF leak+meningitis	7 (3.3)	
Transient third nerve palsy	8 (3.8)	
Subdural effusion	17 (8.1)	
Seizure	0	
Hemorrhage	0	

CSF: Cerebrospinal fluid, ETV: Endoscopic third ventriculostomy. *P-value for mortality related to ETV versus unrelated to ETV, †P-value for age with or without CSF leak. Significant P-values in bold. Chi-square test.

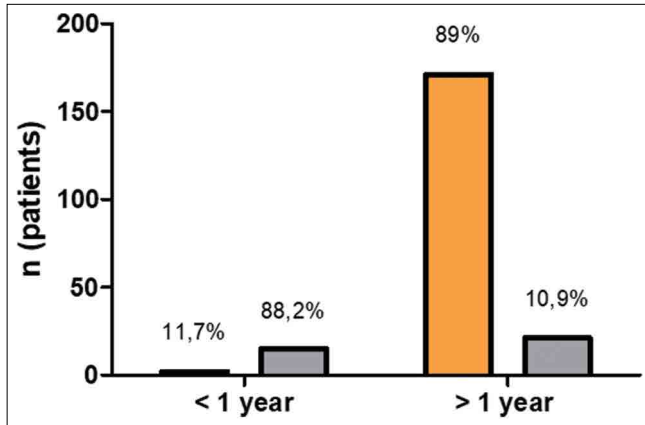


Figure 1: Number of patients (*n*) by age (younger and older than 1 year of age) with clinical success (orange bars) and clinical failure (gray bars) ($P < 0.0001$, chi-square test).

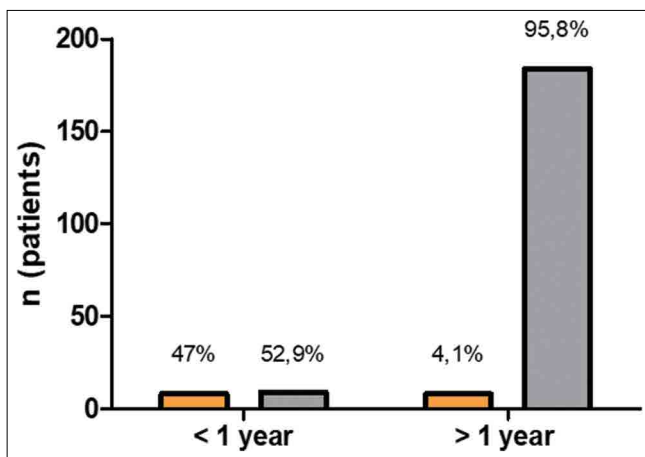


Figure 2: Number of patients (*n*) by age (younger and older than 1 year of age) with cerebrospinal fluid (CSF) leak (orange bars) or without CSF leak (gray bars) ($P < 0.0001$, chi-square test).

challenge that still needs to be overcome. It is worth emphasizing that the endoscopic technique reduces costs,^[19] given that it reduces length of hospital stay, as well as the number of complications or subsequent reoperations that are frequently seen with shunt procedures. After ETV, success can roughly be defined by two criteria: either the disappearance of symptoms after treatment or the lack of need for further procedures, such as CSF shunt surgery.^[7]

In the present study, we did not perform ventricular measurements after endoscopy; however, there are conflicts in the literature regarding the fact that no decrease in ventricular size after ETV may or may not affect patients' cognitive development. Sainte-Rose and Chumas^[20] showed no cognitive changes due to maintenance of ventriculomegaly after ETV. Another important point of conflict is whether the reduction in ventricular size could, in some cases, be used

as a criterion for evaluating the success of ETV. Once again, there are controversies within the neurosurgical literature regarding the clinical relevance of this statement. Using the above criterion of no new treatments or death after ETV to define success, we observed that clinical success was achieved in 82.8% of patients. Kadrian *et al.*^[12] demonstrated a success rate of 89% in 203 patients, and Hopf *et al.*^[11] showed 76% success rate in 100 patients submitted to ETV. Recently, Sacko *et al.*^[19] obtained 63% overall success rate, with 10% morbidity. In agreement with Drake's^[7] series, the majority of our patients belonged to the group with posterior fossa tumors (89.3% had clinical success after ETV) followed by aqueductal stenosis (88.6% had clinical success after ETV). These two groups showed better results, in agreement with other series.^[10] Hopf *et al.* published 79% success rate in patients treated with ETV for hydrocephalus secondary to tumors.^[11] Sainte-Rose *et al.*^[21] demonstrated that, when performed before posterior fossa surgery, ETV significantly reduces the incidence of postoperative hydrocephalus, and it provides a valid alternative to permanent shunt placement in cases where hydrocephalus develops following posterior fossa surgery.

It should be borne in mind that, in cases of hydrocephalus secondary to posterior fossa tumors, and some cases of secondary aqueductal stenosis, treatment of the primary cause can, by itself, lead to an improvement of hydrocephalus, and the ETV success rate may, therefore, be overestimated. The success of ETV depends on several factors, and the cause of hydrocephalus (obstructive or communicating) is only one among many. Age has also been identified as a watershed in indications for endoscopic treatment. In our study, we found better results in patients older than 1 year of age, with favorable prognosis occurring in 89% (171 cases), in comparison with only 11.7% (2 cases) among those under 1 year of age. These data corroborate those obtained by Kim *et al.*^[13] Beems and Grotenhuis had an overall success rate of 53% in children younger than 2 years of age,^[1] and they concluded that the success of ETV depends mainly on the etiology of hydrocephalus and not on the age of the patient alone. Another study by Gorayeb *et al.* demonstrated a success rate of 64% in children younger than 1 year of age, and new studies are still necessary before any definitive conclusions.^[8] In our series, the rate was lower than the literature average.

Kulkarni *et al.*^[15] analyzed differences in cognitive parameters in pediatric patients under 6 years of age with postinfection hydrocephalus, who underwent ETV and ventriculoperitoneal shunt in Uganda. Similarly to this study, they did not show significant differences with respect to the outcomes evaluated. In Kulkarni *et al.*,^[15] the proportion of children who had normal cerebral volume was numerically similar in both treatment groups, as was the incidence of

complications, including treatment-related infection and death. The treatment failure rate was numerically, but not significantly, higher in the ETV group.

Within this panorama, Gorgoglione *et al.*^[9] reported the case of a complication after performance of ETV in a pediatric patient, underscoring the need for additional evaluation and care from the neurosurgery team. They report a case that incorrect positioning of the ventricular catheter can lead to iatrogenic obstruction of the ventriculostomy and consequent failure of the ETV, which is a possible acute failure of the ETV. Fortunately, this did not happen in our case series.

In the present study, the incidence of CSF leakage was 47% (8 cases) of patients younger than 1 year old. Val (2009) published a study using minicraniotomy for ETV, minimizing the occurrence of CSF fistula and subgaleal collections in very young babes. This technique can be implemented in our future cases, without modifying the duration, safety, and efficacy of the procedure.^[4]

Texakalidis *et al.*^[22] conducted a meta-analysis of articles published until 2018 regarding the risks and benefits of ETV compared to shunting for hydrocephalus in pediatric patients. In this meta-analysis, ETV was associated with a statistically significantly lower risk of procedure-related infection when compared to shunting. Mortality, CSF leak, and reoperation rates were similar between the study groups. Subgroup evaluation based on geographical region showed that ETV was associated with statistically significantly lower odds of reoperation in Europe and Africa, but not in the United States and Canada. These results are in agreement with those of Kulkarni *et al.*^[14] who also did not find evidence of statistically significant differences between study groups in terms of all-cause mortality.

A substantial discussion has been raised by studies demonstrating that better prognosis is linked not to age *per se*, but rather to the cause of hydrocephalus. In our opinion, both factors seem to contribute significantly to the success or failure of endoscopy in this population. In children, the presence of immaturity in CSF absorption pathways and the emergence of new arachnoid membranes may contribute to the high rate of treatment failure.^[16]

Notwithstanding the potential occurrence of technical failures inherent to the method, endoscopy has accomplished its mission as an excellent alternative for keeping thousands of patients free from ventriculoperitoneal shunts, especially in the context of a developing nation like Brazil, where malnutrition, poor access to specialized neurosurgical services, and lack of health-care resources are still present in some regions.

Cinalli *et al.*^[3] highlighted that complication rate of neuroendoscopic procedures is not negligible, even in

experienced hands, and careful selection of patients with preoperative imaging studies and intensive training of surgeons are mandatory to improve results.

Procedure failures can be classified as early or late, according to time after endoscopy. Early failures are assessed when the patient continues to have intracranial hypertension, as the CSF absorption system is still in the adaptive period due to new drainage conditions, which can last weeks or possibly months. The use of serial lumbar punctures (up to 3 times weekly) and inhibitors of carbonic anhydrase for short periods seems to favor better outcome in cases with reabsorption difficulties (effusion in place of trepanation, low output fistulas, or even mildly symptomatic patients).^[3]

Late failures generally result from either scarification or gliosis in the area of the stoma or in the basal cisterns (most commonly in children), and the causes are still speculative (reduced CSF flow and/or change in differential pressure). As stated by Drake *et al.*,^[6] late rapid deterioration is a rare but lethal complication of ETV, and patients or caregivers should always be counseled regarding this potential complication.

CONCLUSION

Notwithstanding the need for a specific learning curve and materials with considerably high prices, the use of ETV has served to reduce the costs generated by numerous revision surgeries following shunt placement and also to lower average hospital stay. Age (<1 year) and the primary cause of hydrocephalus were isolated prognostic factors for the outcome of ETV.

Better results were observed in the groups of patients with tumors, aqueductal stenosis, and arachnoid cysts, while those whose primary causes of hydrocephalus were myelomeningocele, infections, or bleeding had higher rates of failure after the procedure.

Declaration of patient consent

Patient's consent not required as patients identity is not disclosed or compromised.

Financial support and sponsorship

Nil.

Conflicts of interest

There are no conflicts of interest.

REFERENCES

1. Beems T, Grotenhuis JA. Is the success rate of endoscopic third ventriculostomy age-dependent? An analysis of the results of

- endoscopic third ventriculostomy in young children. *Childs Nerv Syst* 2002;18:605-8.
2. César J, Ramos R, Ramos MR, Aparecido MM, Ramos GR. Hidrocefalia aguda: Uma revisão bibliográfica/Acute hydrocephalus: A bibliographic review. *Rev Salusvita* 2018;37:1019-28.
 3. Cinalli G, Spennato P, Ruggiero C, Aliberti F, Trischitta V, Buonocore MC, *et al.* Complications following endoscopic intracranial procedures in children. *Childs Nerv Syst* 2007;23:633-44.
 4. Costa Val JA. Minicraniotomy for endoscopic third ventriculostomy in babes: Technical note with a 7-year-segment analysis. *Childs Nerv Syst* 2009;25:357-9.
 5. Demerdash A, Rocque BG, Johnston J, Rozzelle CJ, Yalcin B, Oskouian R, *et al.* Endoscopic third ventriculostomy: A historical review. *Br J Neurosurg* 2017;31:28-32.
 6. Drake J, Chumas P, Kestle J, Pierre-Kahn A, Vinchon M, Brown J, *et al.* Late rapid deterioration after endoscopic third ventriculostomy: Additional cases and review of the literature. *J Neurosurg* 2006;105 Suppl 2:118-26.
 7. Drake JM, Canadian Pediatric Neurosurgery Study Group. Endoscopic third ventriculostomy in pediatric patients: The Canadian experience. *Neurosurgery* 2007;60:881-6; discussion 881-6.
 8. Gorayeb RP, Cavalheiro S, Zymberg ST. Endoscopic third ventriculostomy in children younger than 1 year of age. *J Neurosurg* 2004;100:427-9.
 9. Gorgoglione N, Fazzari E, Alafaci C, Vitulli F, Zaccaria R, Angileri FE, *et al.* An unusual but possible complication after endoscopic third ventriculostomy. *World Neurosurg* 2021;146:287-91.
 10. Grunert P, Charalampaki P, Hopf N, Filippi R. The role of third ventriculostomy in the management of obstructive hydrocephalus. *Minim Invasive Neurosurg* 2003;46:16-21.
 11. Hopf NJ, Grunert P, Fries G, Resch KD, Perneczky A. Endoscopic third ventriculostomy: Outcome analysis of 100 consecutive procedures. *Neurosurgery* 1999;44:795-804.
 12. Kadrian D, van Gelder J, Florida D, Jones R, Vonau M, Teo C, *et al.* Long-term reliability of endoscopic third ventriculostomy. *Neurosurgery* 2005;56:1271-8.
 13. Kim SK, Wang KC, Cho BK. Surgical outcome of pediatric hydrocephalus treated by endoscopic III ventriculostomy: Prognostic factors and interpretation of postoperative neuroimaging. *Childs Nerv Syst* 2000;16:161-8.
 14. Kulkarni AV, Riva-Cambrin J, Butler J, Browd SR, Drake JM, Holubkov R, *et al.* Outcomes of CSF shunting in children: Comparison of hydrocephalus clinical research network cohort with historical controls. *J Neurosurg Pediatr* 2013;12:334-8.
 15. Kulkarni AV, Schiff SJ, Mbabazi-Kabachelor E, Mugamba J, Ssenyonga P, Donnelly R, *et al.* Endoscopic treatment versus shunting for infant hydrocephalus in Uganda. *N Engl J Med* 2017;377:2456-64.
 16. Madsen PJ, Mallela AN, Hudgins ED, Storm PB, Heuer GG, Stein SC. The effect and evolution of patient selection on outcomes in endoscopic third ventriculostomy for hydrocephalus: A large-scale review of the literature. *J Neurol Sci* 2018;385:185-91.
 17. Martins FJ, Beserra NC, Barbosa LG. Clinical and epidemiological profile of children hospitalized by hydrocephalus in a municipal hospital of São Paulo in the period 2014 to 2016. *Rev Bras Neurol* 2018;54:25-31.
 18. McLaughlin MR, John BW, Kaufmann AM, Albright AL. Traumatic basilar aneurysm after endoscopic third ventriculostomy: Case report. *Neurosurgery* 1997;41:1400-3.
 19. Sacko O, Boetto S, Lauwers-Cances V, Dupuy M, Roux FE. Endoscopic third ventriculostomy: Outcome analysis in 368 procedures. *J Neurosurg Pediatr* 2010;5:68-74.
 20. Sainte-Rose C, Chumas P. Endoscopic third ventriculostomy. *Tech Neurosurg* 1995;1:176-84.
 21. Sainte-Rose C, Cinalli G, Roux FE, Maixner W, Chumas PD, Mansour M, *et al.* Management of hydrocephalus in pediatric patients with posterior fossa tumors: The role of endoscopic third ventriculostomy. *J Neurosurg* 2001;95:791-7.
 22. Texakalidis P, Tora MS, Wetzel JS, Chern JJ. Endoscopic third ventriculostomy versus shunt for pediatric hydrocephalus: A systematic literature review and meta-analysis. *Childs Nerv Syst* 2019;35:1283-93.
 23. Val Filho JA. O Papel da Membrana de “Liliequist” na Terceiro Ventriculostomia Endoscópica (Doctoral Dissertation). Brazil: Universidade Federal de Minas Gerais; 2018.

How to cite this article: Faquini IV, Fonseca RB, Correia AO, Cezar Junior AB, De Carvalho Junior EV, de Almeida NS, *et al.* Endoscopic third ventriculostomy in the treatment of hydrocephalus: A 20-year retrospective analysis of 209 consecutive cases. *Surg Neurol Int* 2021;12:383.