

High-Dose Fentanyl Patch for Cancer Pain of a Patient with Cholangiocarcinoma

Jung Han Kim, Mi Kim, Chong Won Sung, Hyeoung Su Kim, Hyun Joo Jang, Young Chul Shin, and Joo Young Jung

Department of Internal Medicine, Hallym University Medical Center, Hallym University College of Medicine, Seoul, Korea

We describe here a patient who obtained a good analgesic effect with high-dose fentanyl patches for controlling cancer pain. A 52-year-old man was referred to our hospital because of severe cancer pain that was 7/10 on a numeric rating scale (NRS). He had been diagnosed with locally advanced cholangiocarcinoma 3 months previously. We prescribed weak opioids and an antidepressant, but his pain was not relieved. We introduced strong opioids (transdermal fentanyl patches for the background pain and a short-acting opioid for the breakthrough pain) and his pain was tolerable on 250 µg/hr of fentanyl patches for 3 months. With time, however, his pain intensity became worse and this reached up to 8/10 to 9/10 on the NRS. Percutaneous transhepatic biliary drainage was performed, which did not relieve his pain. We increased gradually the dose of transdermal fentanyl to 1,050 µg/hr (20 patches). At this dose, the patient was mentally alert, with good pain control (NRS 2/10 to 3/10) and no exacerbation of side effects. To the best of our knowledge, we report here on the highest dose of transdermal fentanyl that has been successfully used for treating a patient suffering from visceral cancer pain. (*Korean J Intern Med* 2010;25:337-340)

Keywords: Fentanyl; Neoplasms; Pain; Cholangiocarcinoma

INTRODUCTION

The high prevalence of pain in patients suffering with terminal cancer is well documented. Management of cancer pain is one of the most important goals of palliative care. Opioid narcotics are the cornerstone drugs for managing severe cancer pain, with or without adjuvant drugs. Fentanyl is a synthetic opioid-agonist that primarily interacts with the mu-opioid receptor. Transdermal fentanyl patches are designed to deliver fentanyl at a constant rate from a reservoir [1]. There have been many studies on the efficacy and convenience of transdermal fentanyl patches for controlling both cancer pain and non-cancer pain [2-4]. Compared with other opioids, fentanyl patches have been associated with better pain relief, less constipation and they enhance the quality of life [4]. Especially, these patches are a good choice for patients with dysphagia,

changes of consciousness and those who need opioid rotation due to side effects [5].

Although it is well known that there is no upper dose limit when using opioids, high doses of opioids are commonly feared by physicians, patients and caregivers [6,7]. Therefore, treatment for the pain of patients with terminal cancer is often inadequate. We describe here a patient with advanced cholangiocarcinoma who obtained a good pain control with high doses of transdermal fentanyl for cancer pain.

CASE REPORT

A 52-year-old man was referred to our hospital because of cancer pain that was 4/10 to 5/10 on a numeric rating scale (NRS). Three months previously, he had been

Received: July 31, 2007

Revised : October 4, 2007

Accepted: October 16, 2007

Correspondence to Jung Han Kim, M.D.

Department of Internal Medicine, Kangnam Sacred-Heart Hospital, Hallym University Medical Center, Daerim 1-dong, Yeongdeungpo-gu, Seoul 150-950, Korea

Tel: 82-2-829-5414, Fax: 82-2-846-4669, E-mail: harricil@hotmail.com

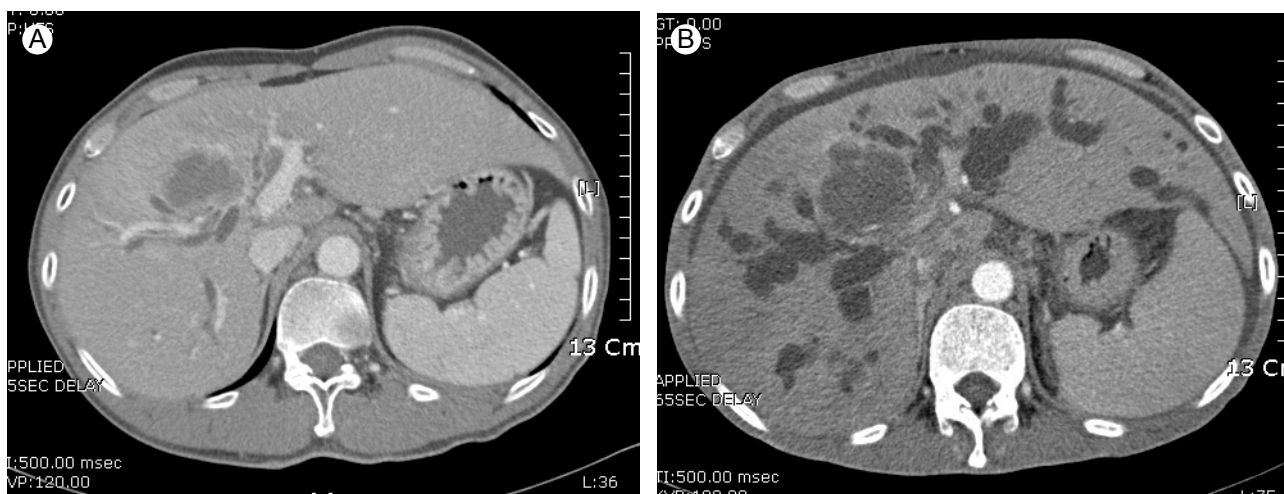


Figure 1. Abdominal computed tomography (CT) scans with contrast. (A) The initial CT scan revealed a mass with slightly dilated intrahepatic bile ducts in the right lobe of the liver. (B) Follow-up CT showed an increased size of the mass along with severe intrahepatic ductal dilatation.

diagnosed with locally advanced cholangiocarcinoma at other hospital (Fig. 1A) and he had been treated by concurrent chemoradiotherapy with no response. He was taking non-steroidal anti-inflammatory drugs due to his mild abdominal pain. However, the cancer pain was aggravated as his cancer progressed. His pain was mainly dull, being located in the right upper quadrant of the abdomen. The cancer pain diminished his appetite and it often woke him from sleeping at night. We initially prescribed tramadol (300 mg/day) and amitriptyline (10 mg/day), but his background pain was not effectively relieved. Thus, we administered transdermal fentanyl patches (12.5 µg/hr) for the background pain and oxycodone immediate release (OIR) tablets for the breakthrough pain, and this treatment brought a dramatic improvement of his pain. Yet after 10 days, the background pain was abruptly aggravated (6/10 on the NRS). The dose of fentanyl was gradually increased to 250 µg/hr over 2 months and his pain became tolerable (2/10 on NRS).

After about 4 weeks on this dose of fentanyl patch, his pain intensity became worse and it eventually reached up to 8/10 to 9/10 on NRS. On admission, we added oxycodone (20 to 200 mg/day) and increased the dose of amitriptyline to 40 mg/day, but the patient failed to obtain an analgesic effect. Abdominal CT was done to find any unknown pain-relieving factors at that time, and the CT showed a severe intrahepatic ductal dilatation (Fig. 1B). Percutaneous transhepatic biliary drainage was performed at once, which did not relieve his pain. Thereafter, he refused all invasive procedures, including celiac plexus block or epidural block. We discontinued oxycodone and increased

the dose of fentanyl patch over 3 weeks. In the 2 weeks before the patient's death, the dose of transdermal fentanyl reached 1,050 µg/hr (Fig. 2). At this dose level, the patient obtained a good pain control (NRS 2/10 to 3/10) with no exacerbation of side effects. He was able to walk independently and sleep well without interruption.

DISCUSSION

Cancer pain affects most patients with advanced malignant disease. The prompt recognition of cancer pain allows implementation of effective palliative care. Although most cancer pain can be relieved, effectively controlling the pain of cancer patients is often problematic. One of the reasons for this is related to the so-called opioidphobia by physicians, patients and caregivers [6,7]. Many clinicians are afraid that high-dose opioids may lead to respiratory depression and hasten the death of patients. However, studies describing the morphine dosage used for hospice patients demonstrated that high-dose morphine has a high safety profile and it doesn't adversely affect the survival of the patients [8,9].

For our case reported here, we mostly applied transdermal fentanyl patches for the cancer pain. We initially administered a 12.5 µg/hr fentanyl patch for background pain that was 4/10 to 5/10 on the NRS, which brought about dramatic pain control. With time, however, the patient's cancer pain was aggravated and the dose of transdermal fentanyl was gradually increased to 250 µg/hr. When the patient's pain intensity became worse (8/10 to 9/10 on NRS) in spite of

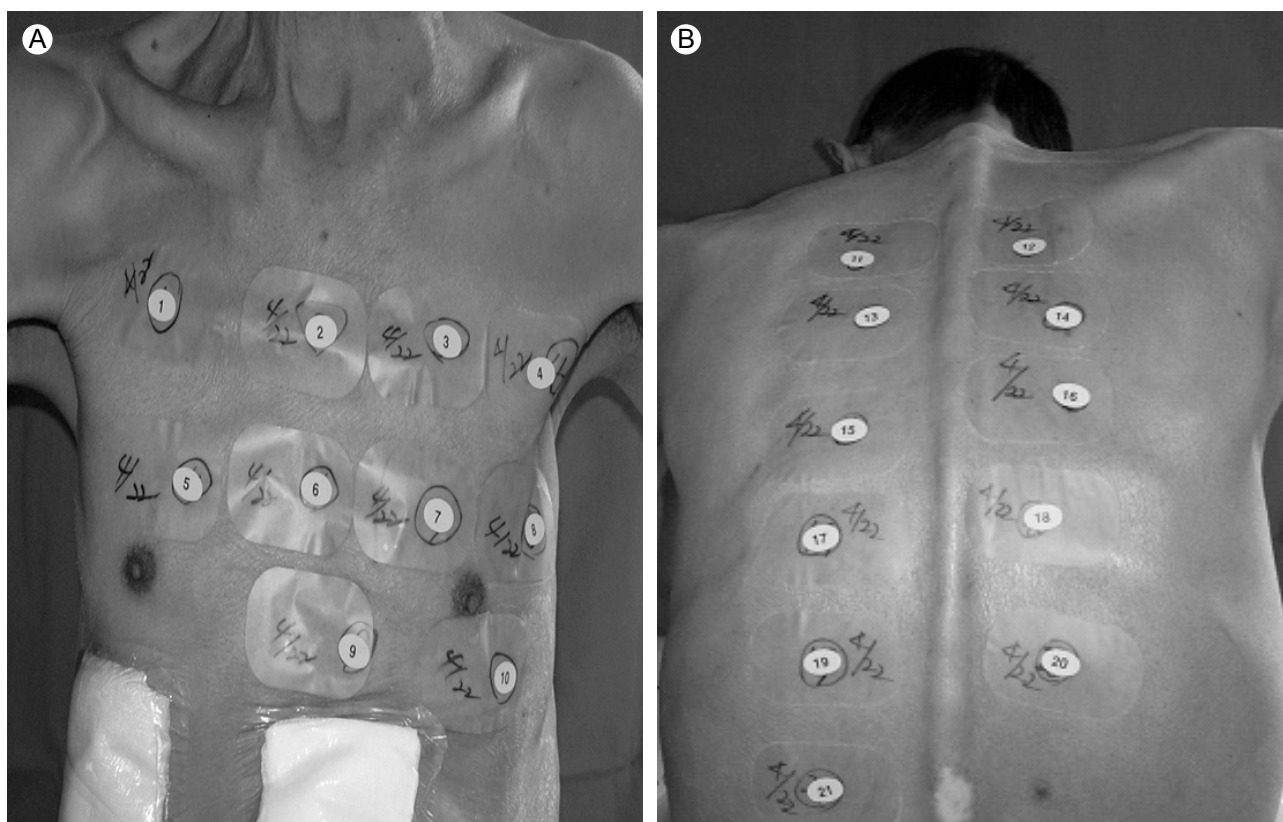


Figure 2. Twenty-one fentanyl patches of 50 µg/hr each were applied to the patient's chest (A) and back (B).

being on 250 µg/hr transdermal fentanyl, we added oxycodone tablets. Several preliminary data suggested that partial opioid rotation and opioid combinations may be beneficial for patients with a poor analgesic effect after dose escalation [10]. Yet for our patient, adding the second opioid failed to achieve a good analgesic effect.

The highest dose of transdermal fentanyl reported in the English medical literature was 3,400 µg/hr (34 patches of 100 µg/hr each), which was used for a 58-year-old woman with neuropathic pain due to a Pancoast tumor of the lung [11]. However, this huge dose had no effect for relieving her from neuropathic pain. In our patient, we increased the dose of transdermal fentanyl to 1,050 µg/hr (21 patches of 50 µg/hr each) over 3 weeks after discontinuing the oxycodone. At this dose, the patient could obtain good pain control during the last 2 weeks of his life, with no exacerbation of side effects.

To the best of our knowledge, we have reported here on the highest dose of transdermal fentanyl that was successfully used for a patient suffering from visceral cancer pain. The administered fentanyl dose was equianalgesic to about a 4,000 mg dose of oral morphine/24 hours. Our experience suggests that if it is needed for

controlling cancer pain, administering high-doses of opioids should not be feared. However, orally administering this dose of opioids inevitably requires a large amount of tablets to be taken daily, which may induce more side effects and make patients uncomfortable. Therefore, high doses of fentanyl patches may be a good choice for those patients who need a megadose of opioids to control their cancer pain.

Conflict of interest

No potential conflict of interest relevant to this article was reported.

REFERENCES

1. Muijsers RB, Wagstaff AJ. Transdermal fentanyl: an updated review of its pharmacological properties and therapeutic efficacy in chronic cancer pain control. *Drugs* 2001;61:2289-2307.
2. Donner B, Zenz M, Strumpf M, Raber M. Long-term treatment of cancer pain with transdermal fentanyl. *J Pain Symptom Manage* 1998;15:168-175.
3. Grond S, Zech D, Lehmann KA, Radbruch L, Breitenbach H, Hertel D. Transdermal fentanyl in the long-term treatment of

- cancer pain: a prospective study of 50 patients with advanced cancer of the gastrointestinal tract or the head and neck region. *Pain* 1997;69:191-198.
4. Allan L, Hays H, Jensen NH, et al. Randomised crossover trial of transdermal fentanyl and sustained release oral morphine for treating chronic non-cancer pain. *BMJ* 2001;322:1154-1158.
 5. Skaer TL. Management of pain in the cancer patient. *Clin Ther* 1993;15:638-649.
 6. Zenz M, Willweber-Strumpf A. Opiophobia and cancer pain in Europe. *Lancet* 1993;341:1075-1076.
 7. Ward SE, Goldberg N, Miller-McCauley V, et al. Patient-related barriers to management of cancer pain. *Pain* 1993;52:319-324.
 8. Bercovitch M, Waller A, Adunsky A. High dose morphine use in the hospice setting: a database survey of patient characteristics and effect on life expectancy. *Cancer* 1999;86:871-877.
 9. Bercovitch M, Adunsky A. Patterns of high-dose morphine use in a home-care hospice service: should we be afraid of it? *Cancer* 2004;101:1473-1477.
 10. Mercadante S, Villari P, Ferrera P, Casuccio A. Addition of a second opioid may improve opioid response in cancer pain: preliminary data. *Support Care Cancer* 2004;12:762-766.
 11. Bleeker CP, Bremer RC, Dongelmans DA, van Dongen RT, Crul BJ. Inefficacy of high-dose transdermal fentanyl in a patient with neuropathic pain: a case report. *Eur J Pain* 2001;5:325-329.