

# Negative Pressure Wound Therapy Reduces Wound Breakdown and Implant Loss in Prepectoral Breast Reconstruction

Gareth W. Irwin, PhD, FRCS\*  
 George Boundouki, PhD, FRCS\*  
 Bilal Fakim, MBChB\*  
 Richard Johnson, FRCS\*  
 Lyndsey Highton, FRCS(Plast)  
 Dave Myers, BSc†  
 Richard Searle, PhD†  
 John A. Murphy, PhD, FRCS\*

**Background:** Single-use negative pressure wound therapy (NPWT) has been shown to encourage wound healing. It is often used when patient factors impair wound healing, or in more complex wounds, such as in implant-based breast reconstruction. We report the findings of a prospective cohort study comparing the use of NPWT with standard dressings in prepectoral breast reconstruction.

**Methods:** A prospective database of implant-based reconstruction from a single institution was mined to identify patients who underwent prepectoral reconstruction. Patient demographics, operative data, surgical complications, and 90-day outcomes were compared between patients who had NPWT and those who had standard dressings.

**Results:** Prepectoral implant-based breast reconstruction was performed on 307 breasts. NPWT dressings were used in 126 cases, with standard dressings used in 181 cases. Wound breakdown occurred in 10 cases after standard dressings versus 1 where NPWT was utilized. Of the standard dressing cases, only 3 implants were salvaged, while 7 cases led to implant loss. The 1 case of wound breakdown in the NPWT cohort settled with conservative measures. The cost of a reconstructive failure was £14,902, and the use of NPWT resulted in a cost savings of £426 per patient.

**Conclusions:** The utilization of single-use NPWT reduces the rate of wound breakdown and implant loss in prepectoral implant-based reconstruction. In addition to the significant clinical benefits, this approach is cost-saving compared with standard dressings. These data suggest that prepectoral implant reconstruction should be considered as an indication for the use of NPWT. (*Plast Reconstr Surg Glob Open* 2020;8:e2667; doi: [10.1097/GOX.0000000000002667](https://doi.org/10.1097/GOX.0000000000002667); Published online 24 February 2020.)

## INTRODUCTION

Breast cancer affects approximately 55,000 women in the United Kingdom, and of these, approximately 40% will require a mastectomy.<sup>1,2</sup> A mastectomy can have a significant impact on a woman's psychological and social well-being; therefore, immediate breast reconstruction is offered in suitable cases.<sup>3</sup> Implant-based breast reconstruction (IBR) is the most common form of this, accounting

for 85% of immediate reconstruction following mastectomy in the United Kingdom.<sup>4</sup> IBR is popular because, in comparison to other methods of reconstruction, it has a relatively rapid recovery and lack of donor-site morbidity.

Historically, during subpectoral breast reconstruction, the pectoralis major, serratus anterior and rectus sheath were raised to allow full coverage of the implant. After the advent of acellular dermal matrices (ADMs) in 2001, lower pole coverage was provided by either an ADM or dermal sling.<sup>5,6</sup> More recently, prepectoral reconstructions have been developed. In this procedure, the implant is placed in front of the pectoralis muscles with total ADM coverage of both the superior and inferior pole.<sup>7</sup> This has been shown to provide a good cosmetic outcome for patients who want quicker recovery without the potential compromise of pectoral muscle function and its associated problems.<sup>8</sup> Indeed, this technique has been shown to have at

From the \*Nightingale Breast Centre, Wythenshawe Hospital, Manchester University NHS Foundation Trust, Manchester, United Kingdom; and †Smith & Nephew Medical Ltd, Hull, United Kingdom.

Received for publication November 8, 2019; accepted January 6, 2020.

Copyright © 2020 The Authors. Published by Wolters Kluwer Health, Inc. on behalf of The American Society of Plastic Surgeons. This is an open-access article distributed under the terms of the [Creative Commons Attribution-Non Commercial-No Derivatives License 4.0 \(CCBY-NC-ND\)](https://creativecommons.org/licenses/by-nc-nd/4.0/), where it is permissible to download and share the work provided it is properly cited. The work cannot be changed in any way or used commercially without permission from the journal.

DOI: [10.1097/GOX.0000000000002667](https://doi.org/10.1097/GOX.0000000000002667)

**Disclosure:** The authors have no financial interest to declare in relation to the content of this article. J.A.M. and G.W.I. have received remuneration from Smith & Nephew to speak at educational events.

least equivalence, with regards to pain scores, compared with the subpectoral standard of care.<sup>9</sup>

A key performance indicator for IBR is implant loss rate. A multicenter prospective cohort study of IBR in the United Kingdom has shown an implant loss rate of 9% at 3 months.<sup>10</sup> UK breast reconstruction best practice guidelines include an implant loss rate target of <5%.<sup>11</sup> This compares poorly with loss rates of other implanted medical devices, varying from 0.76% to 1.24% for hip and knee replacements<sup>12</sup> and 0.5% to 1.2% for cardiac devices.<sup>13</sup>

A proposed mechanism for improving implant reconstruction outcomes is the use of negative pressure wound therapy (NPWT). This has been introduced over the last decade as an adjunct in surgically closed wounds. These systems, including PICO (Smith & Nephew, London, UK), can deliver 80 mm Hg of suction to the wound in a sealed 4-layer system, allowing high moisture vapor transmission to transpire exudate.<sup>14</sup> Previous studies have demonstrated that the use of NPWT in cases of bilateral breast surgery results in less wound breakdown and fewer complications on the side with NPWT.<sup>14–16</sup> More recently, this has been confirmed in patients undergoing breast reconstruction.<sup>17,18</sup>

Given the high rate of IBR complications nationally, we proposed that the use of negative pressure dressing may have a beneficial impact in prepectoral breast reconstruction by reducing the rates of wound breakdown and implant loss. This is the first study evaluating NPWT exclusively in prepectoral implant reconstruction.

## PATIENTS AND METHODS

### Patients

Data for consecutive patients undergoing ADM-assisted prepectoral immediate breast reconstruction, with either complete ADM cover or a combination of ADM and dermal sling coverage, were extracted from the unit's prospectively collected implant database. Baseline demographics, indications for surgery, pathology, surgical outcomes, and complications were collected. Procedures were undertaken by 2 surgeons. A comparison was made between patients in whom closed incision NPWT therapy was used and those who had standard surgical dressings applied. Use of a NPWT dressing was based on availability.

### Surgical Technique

All patients underwent a skin-sparing or skin-reducing mastectomy with immediate prepectoral implant reconstruction. The incision depended on the patient's breast volume and degree of ptosis and included inframammary fold, Wise pattern, and periareolar incisions. The prepectoral implant was supported by one of a variety of ADMs including Strattice (Allergan, Ireland), Artia (Allergan, Ireland), and Surgimend (Integra LifeSciences) sutured to the anterior chest wall with 3-0 PDS (Polydioxanone) (Ethicon, UK). All incisions were closed with absorbable 3-0 Monocryl sutures (Ethicon, UK) for the dermis and 4-0 Monocryl for the subcuticular skin closure. The wounds were then glued with Dermabond skin adhesive (Ethicon, UK). NPWT was applied according to the manufacturer's

instructions (PICO, Smith & Nephew, UK), with size of dressing matched to wound size. Standard dressings were an Opsite (Smith & Nephew, UK) transparent waterproof dressing with an absorbent pad. [Figure 1](#) shows the application of the PICO dressing in theatre.

### Statistical Analysis

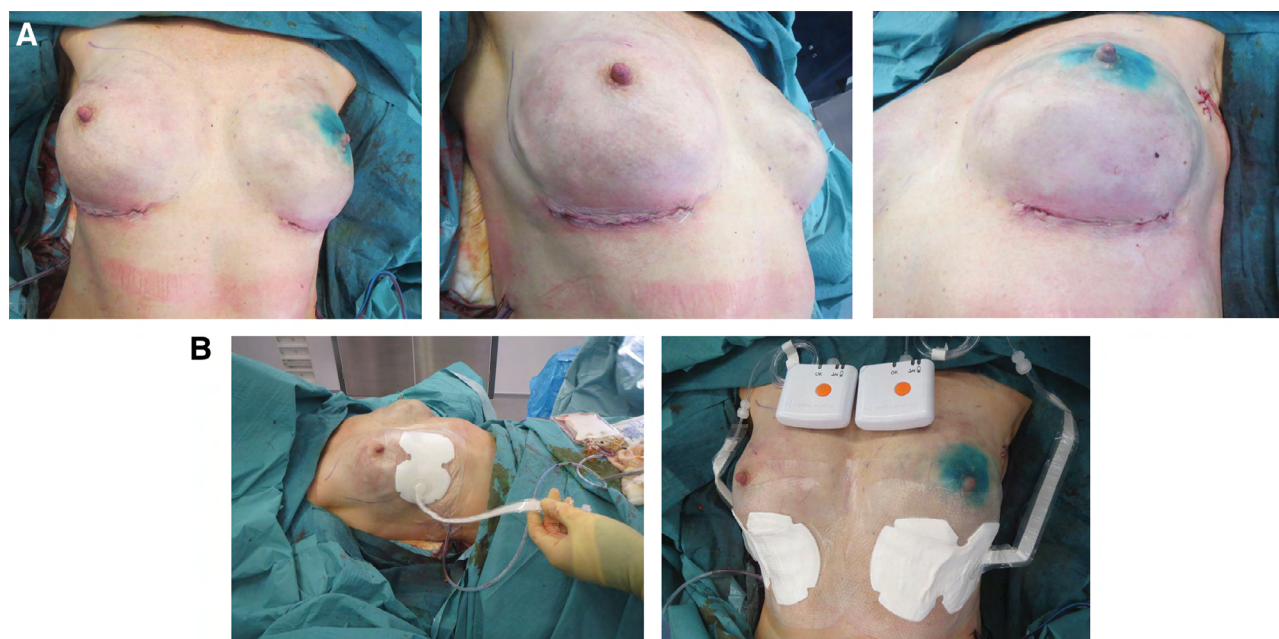Patient characteristics, comorbidities, systemic therapy, and surgical technique were recorded in an Excel (Microsoft) database. Patients were reviewed at 1 week postsurgery by a dedicated nurse and at 2 weeks postsurgery by the operating surgeon. Patients were then reviewed at 90 days postsurgery. Infection was defined as needing a prescription of antibiotics. Wound breakdown was defined as needing a change in their dressing management plan. Minor complications were judged as those that could be managed in the outpatient clinic such as seromas. Major complications included those that required a change in management such as the prescription of antibiotics, change in dressings, or prolonged wound healings. Analyses were performed using Fisher's exact *T* test.

### Cost Analysis

To determine the resources and cost associated with reconstruction failure, deidentified postdischarge resource data for 7 patients with reconstruction failure were analyzed using SAS 9.4 (SAS Institute Inc., Cary, NC). Resources included admissions, outpatient appointments, and accident and emergency (A&E) visits. An appropriate Hospital Resource Group code was attached to each item, and 2018–2019 Payment by Results tariffs (adjusted by Market Forces Factor) were used to assign costs. Implant removals were coded as JA43B/JA42Z (Unilateral or Bilateral Intermediate Breast Procedures with CC Score 0–2). Insertion of tissue expanders, exchange of implants, tissue lipomodelling, and tissue expander insertion or inflation were coded as JA20F/JA21B (Unilateral or Bilateral Major Breast Procedures with CC Score 0–2). For 1 emergency admission with antibiotics and seroma drainage, we assigned WH07G (Infections or Other Complications of Procedures, without Interventions, with complexity and comorbidity [CC] Score 0–1). Elective admissions used the combined day case/ordinary elective spell tariff, and emergency admissions used the nonelective spell tariff. The cost of 2 ADMs per breast reconstruction was added because these are not included in the tariff.

Outpatients visits were assigned as follows: (1) for dressing change, WF01A (Follow-Up Attendance—Single Professional) and (2) for consultant-led review visits, WF02A (Follow-Up Attendance—Multi-Professional). As a conservative approach, A&E visits were not costed because they all resulted in admission, and therefore, in each case, the assigned emergency admission cost was assumed to include any A&E costs.

To ensure that these costs reflect the additional cost related to reconstruction failure, for each patient, we subtracted the normal pattern of resource use from the above. This was assumed to be 3 outpatient visits for each patient: 1 for dressing change and 2 for review by the consultant. The unit cost of the PICO NPWT system was obtained



**Fig. 1.** Application of PICO dressing in theater. A, Immediately postoperatively. B, PICO application in theater.

from National Health Service Supply Chain; we averaged the unit cost across the sizes of PICO and assumed that 1 NPWT system was used per incision.

## RESULTS

### Baseline Characteristics

Prepectoral IBR was performed on 307 breasts (196 patients) between January 2013 and June 2018 under the care of 2 surgeons. NPWT dressings were used in 126 cases with standard dressings used in 181 cases. There was no significant difference between the 2 groups in terms of age, body mass index (BMI), diabetes, or smoking status. Systemic therapy use was also similar between the 2 groups (Table 1).

### Operative Data

There was no difference between the 2 groups in terms of mastectomy weight, implant size, or the need for lipomodelling. The majority of patients in both groups only needed 1 operation (Table 2).

**Table 1. Patient Demographic and Treatment Characteristics**

	NPWT Cohort (n = 126)	Standard Cohort (n = 181)	P
Age, y	43.7 (30–69)	44.2 (20–78)	0.47
BMI, kg/m <sup>2</sup>	26 (18.9–45)	24.8 (17.3–36.6)	0.21
Smoker	8 (6.4%)	16 (8.8%)	0.69
Diabetic	4 (3.2%)	4 (2.2%)	0.72
ASA	1.5 (1–3)	1.43 (1–2)	0.59
Previous radiotherapy	2 (1.6%)	2 (1.1%)	0.69
Adjuvant radiotherapy	4 (3.2%)	4 (2.2%)	0.72
Neoadjuvant chemotherapy	6 (4.8%)	9 (5.0%)	0.61
Adjuvant chemotherapy	8 (6.4%)	8 (4.4%)	0.53

ASA, American Society of Anesthesiologists Classification Score; BMI, body mass index.

### Postoperative Course

There was no difference in the length of stay or need for revision surgery between the 2 groups. There was a lower rate of wound breakdown in the NPWT group (0.8% versus 5.5%,  $P = 0.01$ ). There were no implants lost in the NPWT group compared with 7 in the standard group ( $P < 0.05$ ) (Table 3). There was no statistically significant difference in outcome between the 2 surgeons. There was no statistical difference in the rate of minor or major complications. Figure 2 shows examples of wound breakdown where PICO was not used, and Figure 3 shows long-term results following the use of PICO dressing.

### Additional Postdischarge Costs

Across the 5 patients with 7 reconstruction failures, there were 21 admissions subsequent to the original procedures, 57 additional outpatient visits for dressing change, and 83 additional consultant-led outpatient visits (after adjusting for the normal pattern of resource usage). Across these patients, the total cost associated with reconstruction failure was £104,311 (comprising £92,876 in-patient costs and £11,435 for outpatient attendances). The mean cost per reconstruction failure was £14,902. The cost for each patient ranged from £17,172 to £30,097; the 2 patients who had bilateral implant loss incurred costs of £17,745 and £30,097, respectively.

**Table 2. Operative Data**

	NPWT Cohort (n = 126)	Standard Cohort (n = 181)	P
Single operation	102 (81.0%)	127 (70.2%)	0.22
Mastectomy weight, g	575 (100–3,720)	429 (73–1,057)	0.09
Implant size, g	433 (180–685)	408 (120–620)	0.18
Lipomodelling	10 (7.9%)	21 (11.6%)	0.14

**Table 3. Postoperative Outcomes**

	NPWT Cohort (n = 126)	Standard Cohort (n = 181)	P
Length of stay, d	0.78 (0–2)	0.71 (0–3)	0.44
Implant revision	3 (2.4%)	3 (1.7%)	0.38
Minor complication (eg, seroma)	11 (8.7%)	11 (6.1%)	0.28
Major complication	5 (4.0%)	12 (6.6%)	0.14
Wound breakdown	1 (0.8%)	10 (5.5%)	0.01
Implant loss	0 (0%)	7 (3.9%)	<0.05

Standard dressings were used for 182 incisions. The cost of reconstruction failure for this cohort (£104,311) was averaged across these 182 incisions, giving an average cost attributed to reconstruction failure of £573.14 per incision. Because there were no implant failures in the NPWT cohort, no failure costs were attributed to this group. Table 4 shows the results of the cost analysis, which demonstrates a cost saving of £426.08 per patient for NPWT compared with standard dressings.

## DISCUSSION

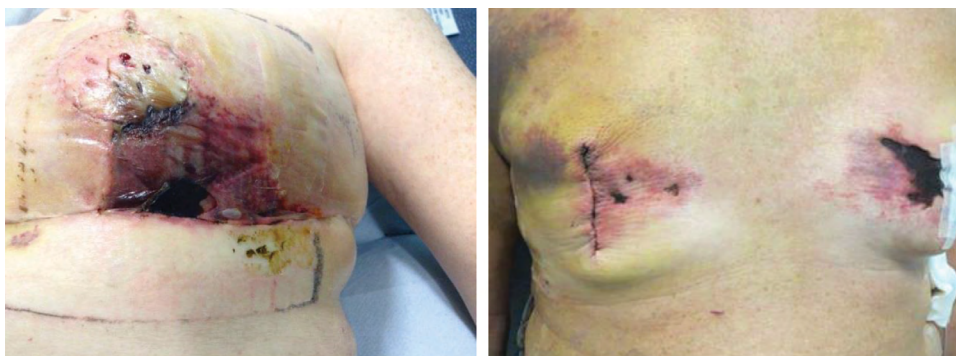This single-site prospective study is the first to demonstrate a reduction in wound breakdown and implant loss in prepectoral implant reconstruction with the use of NPWT. This is in keeping with other studies that have shown that the use of NPWT can improve wound healing. Indeed, an earlier study from our institution had shown a trend to improved wound healing in therapeutic mastoplasties with contralateral reductions.<sup>14</sup> That was corroborated in later studies in bilateral breast reductions, where one side used NPWT and the other side used routine dressings. Galiano et al<sup>15</sup> demonstrated, in 200 patients, a 5% reduction in wound complications on the side that used NPWT. In addition, when scar quality was assessed at 42 and 90 days postsurgery, the NPWT scar was felt to be significantly better when assessed by a visual analogue scale or the Patient and Observer Scar Assessment Scale.<sup>16</sup>

More recently, there have been reports of the use of NPWT in the context of implant reconstructions. Ferrando et al<sup>17</sup> showed that NPWT was well-tolerated and reduced complications in high-risk patients undergoing breast surgery. However, this study only included 6 cases of immediate implant-based reconstruction.<sup>17</sup> Gabriel et al<sup>18</sup> reported a reduction in infection, dehiscence, and seroma rates with

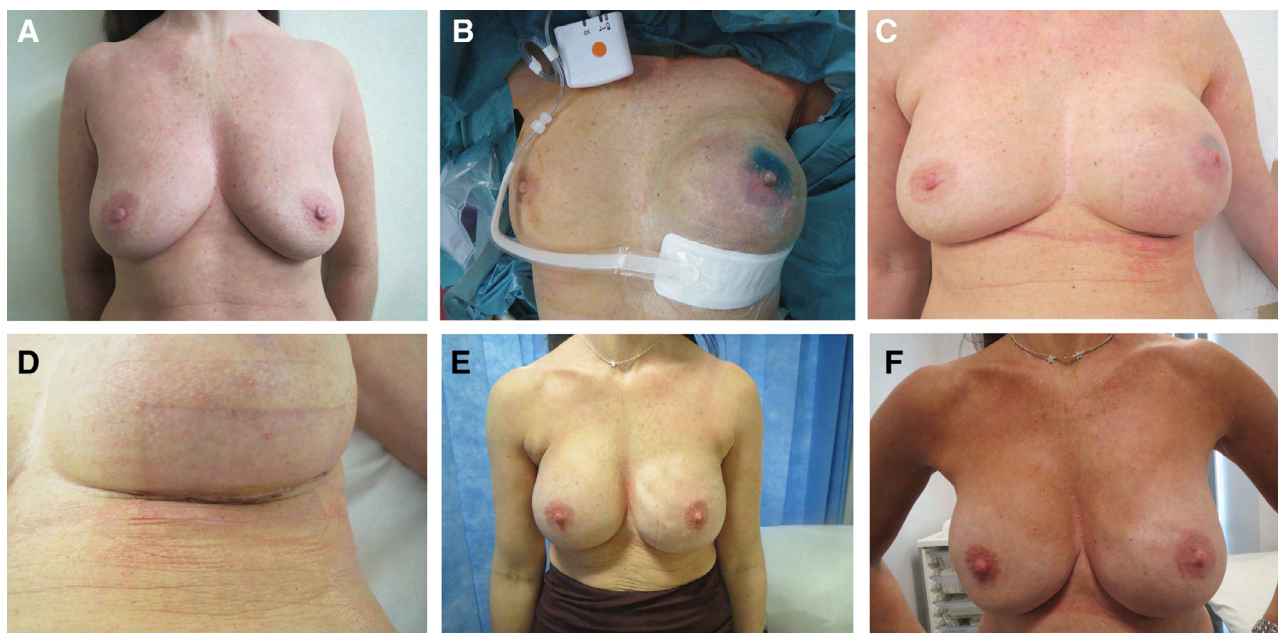
the use of NPWT; however, the difference in rates of device removal did not reach significance. Interestingly, this series had large numbers of patients (n = 177 NPWT, n = 179 standard care), but used implant/expanders instead of going direct to implant as in our series.<sup>18</sup> Furthermore, while it included a large number of prepectoral reconstructions, the NPWT devices were used predominantly in the prepectoral reconstructions, and standard dressings used in the subpectoral reconstructions, thus reducing the ability to evaluate the effect of NPWT in isolation. One major difference between these studies in breast reductions and breast reconstructions is the need for further postoperative oncological therapy. Wounds in the therapeutic setting have to be healed in a timely manner to allow the patient to progress to either radiotherapy or chemotherapy.

The exact mechanism of action of NPWT remains unclear, but several factors have been suggested to interplay to create a more positive wound healing environment. These include the presence of a permanent barrier for the first 7 days of wound closure, negative pressure reducing wound edema, the positive recruitment of wound healing factors, and the reduction in shearing forces in the wound. Early clinical studies suggested that the negative pressure resulted in increased blood flow, increased rates of granulation, and decreased bacterial counts.<sup>19,20</sup> More recently, a systematic review highlighted that NPWT may play a role at a molecular level by modulating cytokines to an anti-inflammatory profile, mechanoreceptor, and chemoreceptor cell signaling which promotes angiogenesis, extracellular matrix remodeling, and deposition of granulation tissue.<sup>21</sup>

As highlighted, IBR implant infection rates compare badly with other implanted medical devices. It should be noted that these are performed in slightly different contexts, with complete sterility in orthopedic or cardiac device implantation in contrast to reconstructive breast surgery, which involves dissection through bacterially contaminated ductal breast tissue. Thus, NPWT will have a significant role to play in reducing the rates of wound breakdown or skin flap necrosis that could provide a potential portal of entry for bacteria to colonize the implant and result in implant loss. However, NPWT will not have any impact on any source of infection happening at the time of placing of the implant. Indeed, a recent review highlighted the various techniques used in the United Kingdom to try and reduce the rates of implant loss and assessed the levels of



**Fig. 2.** Examples of wound breakdown where PICO was not used.



**Fig. 3.** Long-term results of the use of PICO dressing. A, Preoperatively (40-year-old, 80 mm Hg ductal carcinoma in situ); (B) PICO application in theater; (C) 1 week postoperatively; (D) 1 week postoperatively; (E) 12 months postoperatively; and (F) 4 years postoperatively.

**Table 4. Cost Analysis of Using NPWT**

Description of Cost	Cost per Patient (£)		
	Standard Cohort	NPWT Cohort	Difference
NPWT	£0	£147.06	£147.06
Reconstruction failure	£573.14	£0	-£573.14
Total	£573.14	£147.06	-£426.08

evidence for each of these interventions.<sup>22</sup> They proposed a Theatre Implant Checklist that would integrate those interventions with the best evidence in a bundle of care to be used in implant-based breast reconstruction. In view of this study, NPWT may be a further adjunct.

This study, as with the previous studies, has its limitations. The nature of the intervention means that a double-blind randomized controlled trial is not possible. The patient and assessor will be aware of the intervention. While in-patient studies are a pragmatic approach to try and ameliorate these effects, that method of study design is unable to control for different surgeons operating at different depths, simultaneously in the same patient and, indeed, even if the same operator performs the procedure in series, there still may be a difference in flap thickness and wound closure.<sup>23,24</sup>

As shown in this study, the 2 groups had very similar characteristics and no significant difference in systemic therapy. The decision to use NPWT was limited by its availability. However, the potential for unintentional bias cannot be excluded. If biased in any direction, it is more likely that NPWT would be used in higher-risk patients, thus making the subsequent reduction in implant loss even more impressive. Recent cost-effectiveness analyses have demonstrated that single-use NPWT can be a cost-saving intervention to reduce surgical site complications following hip and

knee replacement<sup>25</sup> and coronary artery bypass grafting surgery.<sup>26</sup> The costs of complications and their consequences can be substantial, as shown in our analysis, where the consequential cost for 1 implant loss was estimated to be £14,902. Given the reduction in reconstruction failure rate from 4% to zero, our analysis shows that the use of single-use NPWT in patients undergoing prepectoral reconstruction is cost-effective, compared with standard care. There is the additional benefit of the potential reduction in the psychological distress caused by implant failure. Following on from this study, we recommend that prepectoral reconstruction should be added to the list of high-risk factors that warrant the use of NPWT at the surgeon's discretion, while a multicenter randomized controlled trial is undertaken.

## CONCLUSIONS

This study has demonstrated that the use of single-use NPWT significantly reduces the rate of wound breakdown and implant loss in prepectoral implant-based reconstruction. In addition to the significant clinical benefits, this approach is cost-saving compared with standard dressings. These data suggest that, in addition to high-risk patient factors, prepectoral implant reconstruction should be considered an indication for the use of NPWT and this should inform national guidelines. A prospective randomized controlled trial is required to confirm these findings.

*John A. Murphy, PhD, FRCS*

Nightingale Breast Centre

Wythenshawe Hospital

Manchester University NHS Foundation Trust

Southmoor Road

Manchester M23 9LT, United Kingdom

E-mail: [john.murphy@mft.nhs.uk](mailto:john.murphy@mft.nhs.uk)

## REFERENCES

1. UK CR. CRUK. <http://www.cancerresearchuk.org/health-professional/cancer-statistics/statistics-by-cancer-type/breast-cancer>. Accessed June 26, 2018.
2. Malata CM, McIntosh SA, Purushotham AD. Immediate breast reconstruction after mastectomy for cancer. *Br J Surg*. 2000;87:1455–1472.
3. Fang SY, Shu BC, Chang YJ. The effect of breast reconstruction surgery on body image among women after mastectomy: a meta-analysis. *Breast Cancer Res Treat*. 2013;137:13–21.
4. Leff DR, Bottle A, Mayer E, et al. Trends in immediate post-mastectomy breast reconstruction in the united kingdom. *Plast Reconstr Surg Glob Open*. 2015;3:e507.
5. Duncan DI. Correction of implant rippling using allograft dermis. *Aesthet Surg J*. 2001;21:81–84.
6. Caputo GG, Marchetti A, Dalla Pozza E, et al. Skin-reduction breast reconstructions with prepectoral implant. *Plast Reconstr Surg*. 2016;137:1702–1705.
7. Highton L, Johnson R, Kirwan C, et al. Prepectoral implant-based breast reconstruction. *Plast Reconstr Surg Glob Open*. 2017;5:e1488.
8. Salibian AA, Frey JD, Choi M, et al. Subcutaneous implant-based breast reconstruction with acellular dermal matrix/mesh: a systematic review. *Plast Reconstr Surg Glob Open*. 2016;4:e1139.
9. Baker BG, Irri R, MacCallum V, et al. A prospective comparison of short-term outcomes of subpectoral and prepectoral stratic-based immediate breast reconstruction. *Plast Reconstr Surg*. 2018;141:1077–1084.
10. Potter S, Conroy EJ, Cutress RI, et al; iBRA Steering Group; Breast Reconstruction Research Collaborative. Short-term safety outcomes of mastectomy and immediate implant-based breast reconstruction with and without mesh (iBRA): a multicentre, prospective cohort study. *Lancet Oncol*. 2019;20:254–266.
11. Martin L, O'Donoghue JM, Horgan K, et al. Acellular Dermal Matrix (ADM) assisted breast reconstruction procedures: Joint guidelines from the Association of Breast Surgery and the British Association of Plastic, Reconstructive and Aesthetic Surgeons. *EJSO*. 2013;39:425–429.
12. Springer BD, Cahue S, Etkin CD, et al. Infection burden in total hip and knee arthroplasties: an international registry-based perspective. *Arthroplast Today*. 2017;3:137–140.
13. Kirkfeldt RE, Johansen JB, Nielsen JC. Management of cardiac electronic device infections: challenges and outcomes. *Arrhythm Electrophysiol Rev*. 2016;5:183–187.
14. Holt R, Murphy J. PICO incision closure in oncoplastic breast surgery: a case series. *Br J Hosp Med (Lond)*. 2015;76:217–223.
15. Galiano RD, Hudson D, Shin J, et al. Incisional negative pressure wound therapy for prevention of wound healing complications following reduction mammoplasty. *Plast Reconstr Surg Glob Open*. 2018;6:e1560.
16. Tanaydin V, Beugels J, Andriessen A, et al. Randomized controlled study comparing disposable negative-pressure wound therapy with standard care in bilateral breast reduction mamoplasty evaluating surgical site complications and scar quality. *Aesthetic Plast Surg*. 2018;42:927–935.
17. Ferrando PM, Ala A, Bussone R, et al. Closed incision negative pressure therapy in oncological breast surgery: comparison with standard care dressings. *Plast Reconstr Surg Glob Open*. 2018;6:e1732.
18. Gabriel A, Sigalove S, Sigalove N, et al. The impact of closed incision negative pressure therapy on postoperative breast reconstruction outcomes. *Plast Reconstr Surg Glob Open*. 2018;6:e1880.
19. Morykwas MJ, Argenta LC, Shelton-Brown EI, et al. Vacuum-assisted closure: a new method for wound control and treatment: animal studies and basic foundation. *Ann Plast Surg*. 1997;38:553–562.
20. Timmers MS, Le Cessie S, Banwell P, et al. The effects of varying degrees of pressure delivered by negative-pressure wound therapy on skin perfusion. *Ann Plast Surg*. 2005;55:665–671.
21. Glass GE, Murphy GF, Esmaceli A, et al. Systematic review of molecular mechanism of action of negative-pressure wound therapy. *Br J Surg*. 2014;101:1627–1636.
22. Barr SP, Topps AR, Barnes NL, et al; Northwest Breast Surgical Research Collaborative. Infection prevention in breast implant surgery - A review of the surgical evidence, guidelines and a checklist. *Eur J Surg Oncol*. 2016;42:591–603.
23. Giannotti DG, Hanna SA, Cerri GG, et al. Analysis of skin flap thickness and residual breast tissue after mastectomy. *Int J Radiat Oncol Biol Phys*. 2018;102:82–91.
24. Robertson SA, Rusby JE, Cutress RI. Determinants of optimal mastectomy skin flap thickness. *Br J Surg*. 2014;101:899–911.
25. Nherera LM, Trueman P, Karlakki SL. Cost-effectiveness analysis of single-use negative pressure wound therapy dressings (sNPWT) to reduce surgical site complications (SSC) in routine primary hip and knee replacements. *Wound Repair Regen*. 2017;25:474–482.
26. Nherera LM, Trueman P, Schmoeckel M, et al. Cost-effectiveness analysis of single use negative pressure wound therapy dressings (sNPWT) compared to standard of care in reducing surgical site complications (SSC) in patients undergoing coronary artery bypass grafting surgery. *J Cardiothorac Surg*. 2018;13:103.