

Diagnostic yield of EBUS-TBNA for lymphoma and review of the literature

Onur Fevzi Erer, Serhat Erol, Ceyda Anar, Zekiye Aydoğdu¹, Serir Aktoğu Özkan

Departments of Chest Diseases and ¹Pathology, İzmir Dr. Suat Seren Chest Diseases and Surgery Training Hospital, İzmir, Turkey

ABSTRACT

Aim: Endobronchial ultrasound-guided transbronchial needle aspiration (EBUS-TBNA), which enables cytological examination of mediastinal lymph node (LN) aspiration samples, is a safe and minimally invasive method for diagnosis and staging of lung cancer and diagnosis of diseases affecting mediastinal LNs. In this study, we investigated the yield of EBUS-TBNA for diagnosis of lymphoma and reviewed the literature since the British Thoracic Society (BTS) guidelines were published. **Materials and Methods:** We retrospectively evaluated our database for patients who underwent EBUS between March 2011 and December 2014. One hundred eighty-nine patients with isolated mediastinal lymphadenopathy were included in the study. Patients with other causes of lymphadenopathy, such as lung cancer or extrathoracic malignancy, and those with pulmonary lesions accompanying mediastinal lymphadenopathy were excluded from the study. Patients with final diagnosed lymphoma were included in the study on the basis of a history of lymphoma or newly evaluated mediastinal lymphadenopathy. The sensitivity and negative predictive value (NPV) of EBUS-TBNA were calculated. **Results:** There were 13 patients with the final diagnosis of lymphoma. Eleven of them were new diagnoses and 2 patients were known chronic lymphocytic leukemia (CLL), and underwent EBUS-TBNA for determination of recurrence. Twelve EBUS-TBNA procedures were performed for suspected new cases. Three (25%) were diagnostic, 2 (16.7%) were suspicious for lymphoma and underwent further interventions for definite diagnosis, and 7 (58.3%) were false negative. All 3 patients diagnosed with EBUS-TBNA were non-Hodgkin lymphoma (NHL). None of the Hodgkin lymphoma (HL) cases could be diagnosed with EBUS-TBNA. The overall diagnostic sensitivity and NPV of EBUS-TBNA in detecting lymphoma was 65% and 96.1%, respectively. For the newly diagnosed lymphoma cases, EBUS-TBNA had a sensitivity of 61.1%. **Conclusion:** In conclusion, we believe that since the publication of the BTS guidelines, the value of EBUS-TBNA in the diagnosis of lymphoma still remains controversial. EBUS-TBNA can be the first diagnostic modality in diagnosis of recurrent lymphomas. However, for suspected new cases, especially for HL, the diagnostic yield of EBUS-TBNA is low and negative results do not exclude lymphoma. Further interventions such as mediastinoscopy should be performed for high-suspicion patients.

Key words: Diagnosis, endobronchial ultrasound-guided transbronchial needle aspiration (EBUS-TBNA), lymphoma

INTRODUCTION

Lymphoma is one of the most common diseases in differential diagnosis of mediastinal masses.^[1,2] There

This is an open access article distributed under the terms of the Creative Commons Attribution-NonCommercial-ShareAlike 3.0 License, which allows others to remix, tweak, and build upon the work non-commercially, as long as the author is credited and the new creations are licensed under the identical terms.

For reprints contact: reprints@medknow.com

How to cite this article: Erer OF, Erol S, Anar C, Aydoğdu Z, Özkan SA. Diagnostic yield of EBUS-TBNA for lymphoma and review of the literature. *Endosc Ultrasound* 2017;6:317-22.

Access this article online

Quick Response Code:



Website:

www.eusjournal.com

DOI:

10.4103/2303-9027.180762

Address for correspondence

Dr. Ceyda Anar, İzmir Dr. Suat Seren Chest Diseases and Surgery Training Hospital, Gaziler Caddesi, Yenışehir, İzmir, Turkey.

E-mail: drceydaanar@hotmail.com

Received: 2015-05-19; **Accepted:** 2015-07-05

are numerous studies on the diagnostic reliability of fine-needle aspiration cytology (FNAC) for the diagnosis of lymphoma, but current guidelines still recommend excisional biopsy, as not only diagnosis but also subtyping is very important for treatment of lymphoma. If excisional biopsy is not possible, FNAC should be examined by an expert hematologist and cytopathologist with additional flow cytometry and immunohistochemistry studies.^[3-6]

Endobronchial ultrasound-guided transbronchial needle aspiration (EBUS-TBNA), which enables cytological examination of mediastinal LN aspiration samples, is a safe and minimally invasive method for diagnosis and staging of lung cancer and diagnosis of diseases affecting mediastinal LNs.^[7,8]

The British Thoracic Society (BTS) guidelines for advanced diagnostic and therapeutic flexible bronchoscopy in adults, published in 2011, cited a study done by Kennedy *et al.* and stated, “At present there is insufficient evidence to recommend EBUS-TBNA for routine use in the diagnosis of lymphoma.”^[9]

In this study, we investigated the yield of EBUS-TBNA for diagnosis of lymphoma and reviewed the literature since the BTS guidelines.

MATERIALS AND METHODS

Patients

We retrospectively evaluated our database for patients who underwent EBUS between March 2011 and December 2014. One hundred eighty-nine patients with isolated mediastinal lymphadenopathy were included in the study. Patients with other causes of lymphadenopathy such as lung cancer or extrathoracic malignancy were excluded from the study. Ninety-nine patients (52.3%) had sarcoidosis, 29 (15.3%) had tuberculosis, 20 (10.5%) had reactive lymphadenopathy, 18 (9.5%) had anthracosis, 10 (5.2%) had pneumoconiosis, and 13 (6.8%) patients had lymphoma. Patients with final diagnosed lymphoma were included in the study on the basis of a history of lymphoma, or newly evaluated mediastinal lymphadenopathy. The study was approved by the local Institutional Ethics Committee.

EBUS-TBNA and evaluation of specimens

The EBUS-TBNA procedure was performed by an EBUS-guided TBNA bronchoscope (7.5 MHz,

BF-UC160F; Olympus Optical Co., Tokyo, Japan) by the oral route under topical anesthesia and conscious sedation with midazolam. Mediastinal and hilar LNs were examined systematically. LNs were aspirated with dedicated 22-gauge needles (NA-201SX-4022-C; Olympus, Tokyo, Japan). At least three consecutive aspirates were obtained from each lymph node (LN) station. Some amount of the aspirate was smeared onto glass slides, air-dried, fixed immediately with 95% alcohol, and stained with hematoxylin and eosin (H&E). The rest of the aspirate was placed into a mixture of formalin and alcohol in order to obtain a cell block (for histological examination). Rapid onsite cytological examination (ROSE) was not available. Cell blocks were embedded in paraffin, and sections of 6 μ m thickness were obtained and stained with the requisite stains (H&E and further morphologic, histochemical, and immunohistochemical analysis) according to the decision of the histopathologist. In all patients, aspirates were also sent for acid-fast staining, mycobacterial cultures, and polymerase chain reaction (PCR) test.

Diagnosis of lymphoma

Lymphoma diagnosis was based on morphological characteristics. Ancillary diagnostic tests such as flow cytometry for lymphoma are not available in our institution. After diagnosis, the patients were referred to a hematology unit for further diagnosis and treatment.

Statistical analysis

The statistical analyses were performed using the Statistical Package for Social Sciences (SPSS) version 20. Descriptive statistics were expressed as mean \pm standard deviation for continuous variables and as frequency (percentage) for categorical variables. The sensitivity and negative predictive value (NPV) of EBUS-TBNA were calculated.

RESULTS

There were 13 patients with the final diagnosis of lymphoma. One patient underwent EBUS-TBNA twice. Eleven of them were new diagnoses, and 2 patients were known chronic lymphocytic leukemia (CLL) who underwent EBUS-TBNA for determination of recurrence. A total of 26 LNs with diameters 8-28 mm were sampled. The most frequently sampled LN stations were the right lower paratracheal LNs (4R) and subcarinal^[7] [Table 1]. Computed tomography (CT) of the thorax was obtained in all patients, whereas positron emission tomography (PET-CT) was applied in

4 patients. Mediastinal lymphadenopathies were detected in all patients with a diameter range of 18–35 mm. Three patients had pleural effusion and 1 patient had cavitary infiltration [Table 2, Figures 1 and 2]. Standard uptake value (SUV) max results of LNs were 5–28 on PET-CT. PET-CT evaluation also revealed 2 abdominal and 3 extrathoracic (cervical, axillary) LNs in addition to mediastinal LNs.

Table 1. The characteristics of patients and frequency of LNs diagnosed by EBUS-TBNA

Gender	N (%)
Male	7 (53.8)
Female	6 (46.2)
Age [median (min-max)]	65.5 (17-80)
Number of sampled LNs	N (%)
1	5 (35.7)
2	6 (42.9)
3	3 (21.4)
Most sampled LN stations	N (%)
4R	12 (85.7)
7	11 (78.6)
11R	3 (21.4)

Table 2. Computed tomography findings of patients

CT findings	N (%)
Mediastinal lymph adenopathy	13
Right paratracheal (2R-4R)	13 (100)
Subcarinal (7)	10 (76.9)
Aorticopulmonary (5-6)	9 (69.2)
Right hilar (10R)	5 (38.4)
Prevascular (3A)	3 (23.1)
Bilateral hilar	3 (23.1)
Left hilar (10L)	2 (15.3)
Pleural effusion	3
Consolidation	2
Cavity	1
Nodular lesion	1

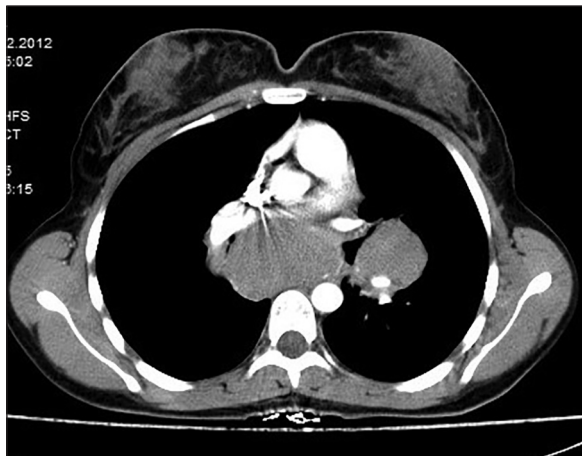


Figure 1. Mediastinal lymphadenopathy on thorax CT

Twelve EBUS-TBNA procedures were performed for suspected new cases. Three (25%) were diagnostic, 2 (16.7%) were suspicious for lymphoma and underwent further interventions for definite diagnosis, and 7 (58.3%) were false negative. All 3 patients diagnosed with EBUS-TBNA were non-Hodgkin lymphoma (NHL). None of the Hodgkin lymphoma (HL) cases could be diagnosed with EBUS-TBNA. Both EBUS-TBNA procedures performed for recurrent cases were diagnostic for lymphoma [Figures 3 and 4]. The overall diagnostic sensitivity and NPV of EBUS-TBNA in detecting lymphoma was 65% and 96.1% respectively. For the newly diagnosed lymphoma, EBUS-TBNA had a sensitivity of 61.1%.

Pleural fluid analysis of 3 patients did not reveal lymphoma. For the patient with mediastinal lymphadenopathy and accompanying cavitary lesions [Figure 2], the prediagnosis was tuberculosis, thus a bronchoscopic lavage was done; cytologic examination revealed Reed–Sternberg-like cells. This patient underwent EBUS-TBNA and was reported as reactive hyperplasia of the LN. For the definitive diagnosis, the patient underwent mediastinoscopy and the pathological examination reported lymphoma.

DISCUSSION

Studies regarding the position of EBUS-TBNA in the diagnosis of lymphoma are limited in number^[10-16] [Table 3]. The first report is a study of Kennedy *et al.*,^[10] which gives the sensitivity of EBUS-TBNA as 90.9%. However, 7 out of 9 of the patients in the study had recurrent disease. In addition, 1 of 2 HL patients who were accepted as diagnosed by EBUS-TBNA, required confirmation of the diagnosis by mediastinoscopy.

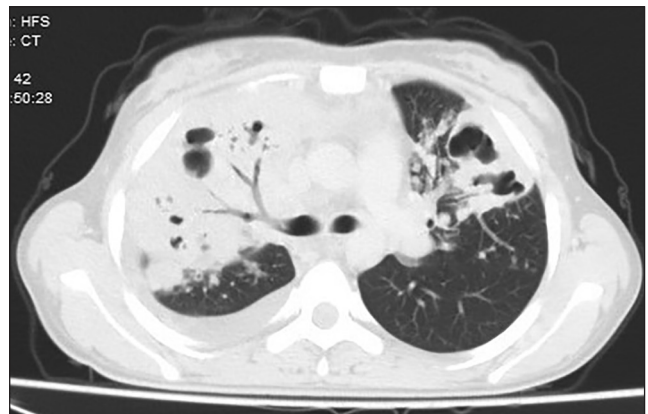

Figure 2. Cavitary infiltration on thorax CT

Table 3. Results of previous studies

Studies	Number of cases	EBUS-TBNA results						Sens %	Spes %	PPV %	NPV %	DA %
		Diagnostic		Suspicious		Nondiagnostic						
		HL	NHL	HL	NHL	HL	NHL					
Kennedy et al. ^[10]	11	1 (N) 1 (R)	7 (R)	1 (N)			1 (N)	90.9	100	100	92.6	96
Steinfors et al. ^[11]	21	2	10	1	3	3	2	57	100	100	87	
Marshall et al. ^[12]		1 (N) 1 (R)	1 (N) 5 (R)	3								
Iqbal et al. ^[13]	62	1 (N)	18 (R) 6 (N)	2 (N)	2 (R) 2 (N)	3(R) 8(N)	8 (R) 12 (N)	G:38 N:22 R:55				
Moomin et al. ^[14]	65	13	10 (HgL) 30 (LgL)	11	1		1	89	97	98	83	91
Ko et al. ^[15]	10	1(N)	6	1(N) 1(R)	1(R)							
Şentürk et al. ^[16]	15	9 (N)	2 (N) 2 (R)				2 (N)	86.7	100	100	96.4	97

HL: Hodgkin lymphoma, NHL: Non-Hodgkin lymphoma, Sens: Sensitivity, Spes: Specificity, PPV: Positive predictive value, NPV: Negative predictive value, DA: Diagnostic accuracy, N: New diagnosis, R: Recurrent, G: General, HgL: High-grade lymphoma, LgL: Low-grade lymphoma

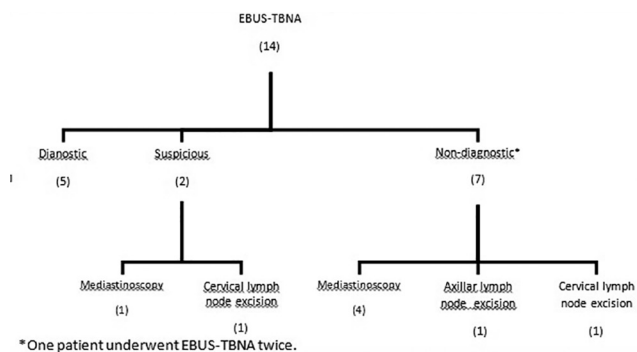
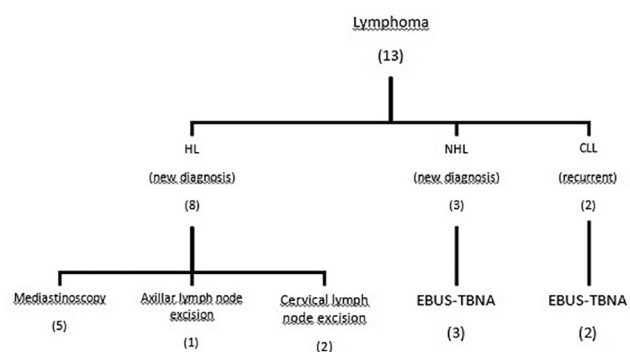


Figure 3. Results of EBUS-TBNA and confirmation method

The study of Steinfors et al.^[11] included 19 lymphoma patients with two recurrences. In this study, of 13 definitively diagnosed patients (via EBUS), 11 had NHL. Only 2 of the 6 HL patients could be diagnosed with EBUS-TBNA. The majority of the patients had recurrent disease in the study of Marshall et al.,^[12] and they had diagnosis by EBUS-TBNA. It is interesting that the NPV of EBUS-TBNA was 100% in this study. There were no false negative patients.

The lowest diagnostic sensitivity (like our study) was reported in the study of Iqbal et al.^[12] It was noteworthy that only 1 out of 14 HL patients was diagnosed with EBUS-TBNA.

In the study of Moomin et al.,^[14] EBUS-TBNA yielded diagnostic results in all 30 patients with low-grade NHL. Surgical biopsy confirmation of the diagnosis was required in 6 of 19 HL patients who were reported to be diagnosed by EBUS-TBNA. One patient was diagnosed as HL after EBUS-TBNA, but the surgical



HL: Hodgkin lymphoma, NHL: non-hodgkin lymphoma, CLL: chronic lymphocytic leukemia

Figure 4. Diagnostic methods according to lymphoma type

biopsy documented NHL. Thus the specificity of the study was low.

Ko et al.^[15] also reported that EBUS-TBNA was more effective in diagnosis of NHL when compared with HL.

The most interesting results emerged from the study of Senturk et al.^[16] EBUS-TBNA was diagnostic in 13 of 15 lymphoma patients, and all of the 11 HL cases had diagnosis with EBUS-TBNA.

The studies in the literature differ when comparing the sample size, recurrent case ratio, and differences between HL and NHL rates. Thus we think that comparing their diagnostic sensitivities is insignificant. However, the results in common were high diagnostic sensitivity in NHL type and in recurrent disease, and low diagnostic sensitivity in HL type (except in the study of Senturk et al.).

It is important to view the morphology of LN in the diagnosis of lymphoma. It is difficult to diagnose HL when the Reed–Sternberg cells are not documented in the specimen. In addition, fibrosis in the LN (sclerosing HL) or the proportion of underlying granulomatous components affects the diagnosis. It is difficult to assess the LN morphology by fine-needle aspiration (FNA) biopsies. In addition, enough material should be obtained for additional diagnostic tests such as flow cytometry and immunohistochemical staining.^[17,18]

As we know, the treatment of lymphoma relies on knowing the specific subtype and histological grade, and although this may be apparently achievable with EBUS-TBNA samples, concern exists that there is a high rate of discordance between cytologic and histologic specimens. In a lung cancer study,^[19] it was found that the diagnostic concordance rate between the histology and cytology of EBUS-TBNA was as high as 90% and also that no difference was detected in the concordance rate regardless of LN size and subtype. Moonim *et al.* found that there was discordance between EBUS-TBNA and tissue diagnoses only in cases where EBUS-TBNA was suspicious, but not definite, for the diagnosis of lymphoma.

In our study, similar to the study of Iqbal *et al.*, diagnostic sensitivity is low for suspected new cases and 100% of the procedures performed for determination of recurrent disease were diagnostic. For the newly diagnosed lymphoma, EBUS-TBNA had a low sensitivity of 61.1%.

We have some explanations for the low diagnostic and high false negative rates. First, the ratios of newly diagnosed and HL patients were high. As previous studies have shown, the diagnostic accuracy of EBUS-TBNA is low, especially for HL. Second, our institution is a chest disease and thoracic surgery hospital and our cytopathologists are more experienced in thoracic cancers than lymphoproliferative diseases. Additionally, flow cytometry and immunohistochemical staining for lymphoma are not available in our hospital. As mentioned before,^[20] we also do not think that ROSE will increase the diagnostic yield of EBUS for lymphoma because the problem is not the quality of specimens.

We agree with Frederiksen *et al.*^[21] that the definition of “diagnostic accuracy” varies between studies. For example, some authors have accepted EBUS as diagnostic despite the necessity of surgical confirmation.

We believe that “diagnostic” means no need for further interventions such as mediastinoscopy.

Similar problems exist with endoscopic ultrasound (EUS)-guided FNA (i.e., EUS-FNA). Large-size and Tru-Cut needles may be option for EBUS-TBNA, as with EUS-FNA.^[20] In another study,^[22] it was shown that necrosis of cancerous tissue, rare types of malignancy (such as lymphoma), and inadequacy of specimens contributed to the false negative results of EBUS-TBNA. Improvement of EBUS-TBNA skills and using larger needles (21-gauge) may increase the yield of the biopsy.

In our study, consistent with previous articles,^[23] the most enlarged LNs at thorax CT were the right paratracheal and subcarinal stations. There were accompanying pulmonary findings, possibly due to direct extension of the disease. Bilateral hilar enlargement was rare. This can help to distinguish lymphoma from sarcoidosis. PET-CT can be advantageous for documenting the extent of the disease and determining the surgical biopsy sites.

The main limitations of our study are its retrospective design and the low number of patients.

CONCLUSION

In conclusion, we believe that since the publication of the BTS guidelines,^[9] the value of EBUS-TBNA in the diagnosis of lymphoma still remains controversial. EBUS-TBNA can be the first diagnostic modality in diagnosis of recurrent lymphomas. However, for suspected new cases, especially for HL, the diagnostic yield of EBUS-TBNA is low and negative results do not exclude lymphoma. Further interventions such as mediastinoscopy should be performed for high-suspicion patients.

Financial support and sponsorship

Nil.

Conflicts of interest

There are no conflicts of interest.

REFERENCES

- Whitten CR, Khan S, Munneke GJ, *et al.* A diagnostic approach to mediastinal abnormalities. *Radiographics* 2007;27:657-71.
- Carter BW, Marom EM, Detterbeck FC. Approaching the patient with an anterior mediastinal mass: A guide for clinicians. *J Thorac Oncol* 2014;9(Suppl 2):S102-9.
- Dreyling M, Ghielmini M, Marcus R, *et al.*; ESMO Guidelines Working Group. Newly diagnosed and relapsed follicular lymphoma: ESMO

- Clinical Practice Guidelines for diagnosis, treatment and follow-up. *Ann Oncol* 2014;25(Suppl 3):iii76-82.
4. Eichenauer DA, Engert A, André M, et al.; ESMO Guidelines Working Group. Hodgkin's lymphoma: ESMO Clinical Practice Guidelines for diagnosis, treatment and follow-up. *Ann Oncol* 2014;25(Suppl 3):iii70-5.
 5. Cheson BD, Fisher RI, Barrington SF, et al. Alliance, Australasian Leukaemia and Lymphoma Group; Eastern Cooperative Oncology Group; European Mantle Cell Lymphoma Consortium; et al. Recommendations for initial evaluation, staging, and response assessment of hodgkin and non-Hodgkin lymphoma: The Lugano classification. *J Clin Oncol* 2014;32:3059-68.
 6. National Comprehensive Cancer Network. NCCN Clinical Practice Guidelines in Oncology for Non-Hodgkin's Lymphomas. Available from: http://www.nccn.org/professionals/physician_gls/pdf/nhl.pdf. [Last accessed on 2013 Oct 1].
 7. De Leyn P, Dooms C, Kuzdzal J, et al. Revised ESTS guidelines for preoperative mediastinal lymph node staging for non-small-cell lung cancer. *Eur J Cardiothorac Surg* 2014;45:787-98.
 8. VanderLaan PA, Wang HH, Majid A, et al. Endobronchial ultrasound-guided transbronchial needle aspiration (EBUS-TBNA): An overview and update for the cytopathologist. *Cancer Cytopathol* 2014;122:561-76.
 9. Du Rand IA, Barber PV, Goldring J, et al.; British Thoracic Society Interventional Bronchoscopy Guideline Group. British Thoracic Society guideline for advanced diagnostic and therapeutic flexible bronchoscopy in adults. *Thorax* 2011;66(Suppl 3):iii1-21.
 10. Kennedy MP, Jimenez CA, Bruzzi CF, et al. Endobronchial ultrasound-guided transbronchial needle aspiration in the diagnosis of lymphoma. *Thorax* 2008;63:360-5.
 11. Steinfort DP, Conron M, Tsui A, et al. Endobronchial ultrasound-guided transbronchial needle aspiration for the evaluation of suspected lymphoma. *J Thorac Oncol* 2010;5:804-9.
 12. Marshall CB, Jacob B, Patel S, et al. The utility of endobronchial ultrasound-guided transbronchial needle aspiration biopsy in the diagnosis of mediastinal lymphoproliferative disorders. *Cancer Cytopathol* 2011;119:118-26.
 13. Iqbal S, DePew ZS, Kurtin PJ, et al. Endobronchial ultrasound and lymphoproliferative disorders: A retrospective study. *Ann Thorac Surg* 2012;94:1830-4.
 14. Moonim MT, Bren R, Fields PA, et al. Diagnosis and subtyping of *de novo* and relapsed mediastinal lymphomas by endobronchial ultrasound needle aspiration. *Am J Respir Crit Care Med* 2013;188:1216-23.
 15. Ko HM, da Cunha Santos G, Darling G, et al. Diagnosis and subclassification of lymphomas and non-neoplastic lesions involving mediastinal lymph nodes using endobronchial ultrasound-guided transbronchial needle aspiration. *Diagn Cytopathol* 2013;41:1023-30.
 16. Senturk A, Babaoglu E, Kilic H, et al. Endobronchial ultrasound-guided transbronchial needle aspiration in the diagnosis of lymphoma. *Asian Pac J Cancer Prev* 2014;15:4169-73.
 17. Chheng DC, Cangiarella JF, Symmans WF, et al. Fine-needle aspiration cytology of Hodgkin disease: A study of 89 cases with emphasis on false-negative cases. *Cancer* 2001;93:52-9.
 18. Moreland WS, Geisinger KR. Utility and outcomes of fine-needle aspiration biopsy in Hodgkin's disease. *Diagn Cytopathol* 2002;26:278-82.
 19. Bae W, Kim H, Kim YA, et al. Diagnostic Concordance rate between histologic and cytologic specimens of endobronchial ultrasound-guided transbronchial needle aspiration in lung cancer: A single institution experience. *Thoracic Cancer* 2014;5:174-8.
 20. Gimeno-García AZ, Elwassief A, Paquin SC, et al. Endoscopic ultrasound-guided fine needle aspiration cytology and biopsy in the evaluation of lymphoma. *Endosc Ultrasound* 2012;1:17-22.
 21. Frederiksen JK, Sharma M, Casulo C, et al. Systematic review of the effectiveness of fine-needle aspiration and/or core needle biopsy for subclassifying lymphoma. *Arch Pathol Lab Med* 2015;139:245-51.
 22. Tian Q, Chen LA, Wang RT, et al. The reasons of false negative results of endobronchial ultrasound-guided transbronchial needle aspiration in the diagnosis of intrapulmonary and mediastinal malignancy. *Thoracic Cancer* 2013;4:186-90.
 23. Bae YA, Lee KS. Cross-sectional evaluation of thoracic lymphoma. *Thorac Surg Clin* 2010;20:175-86.