

Long Biceps Subpectoral Tenodesis With Suspensory Button and Bicortical Fixation



Nuno Gomes, M.D., Manuel Ribeiro da Silva, M.D., Helder Pereira, M.D.,
Ricardo Aido, M.D., and Ricardo Sampaio, M.D.

Abstract: Tenodesis of the long head of the biceps (LHB) tendon has long been recognized as a valid alternative to address pathologic conditions of this tendon. However, the location and type of fixation is still a matter of discussion, because common complications associated with this procedure include failure of the repair, persistent pain, reaction to the fixation device, cosmetic deformity, and fracture. The authors describe a method of subpectoral LHB tenodesis that aims to preserve bone stock and allows a strong, easy, and reproducible type of fixation with a minimal approach. LHB tenotomy is performed arthroscopically in a standard fashion, and the tenodesis is completed with bicortical fixation in the humerus using a knotless suspensory button with an appropriate pusher originally developed for another purpose. Magnetic resonance imaging showed a safe distance between the implant and important vasculonervous structures. In the cases where subpectoral fixation is chosen, this method seems to offer additional safety as a result of the minimal amount of bone removed and the very small size of the implant.

Tenodesis of the long head of the biceps (LHB) tendon has long been recognized as a valid alternative to address pathologic conditions of this tendon such as partial tears, subluxations, pulley lesions, or SLAP lesions, which are frequently associated with repair failures that are still unclear and likely multifactorial.¹

Various techniques for that purpose have been proposed. However, the location and type of fixation is still a matter of discussion, because common complications associated with this procedure include failure of the repair, persistent pain, reaction to the fixation device, cosmetic deformity, and fracture.²⁻⁵

Among those several techniques, the interference screw and anchor techniques are widely used, both

open and arthroscopically, for either proximal or distal fixation in the gutter. In spite of this, limited clinical data are available regarding the best method in terms of clinical and anatomic outcomes.⁶

We describe a subpectoral LHB tenodesis that aims to preserve bone stock and allows a strong, easy, and reproducible type of fixation with a minimal approach. The procedure consists of a classical diagnostic arthroscopy with an LHB tenotomy and an open subpectoral bicortical fixation of the LHB tendon, using a knotless suspensory button with an appropriate pusher originally developed for another purpose.

Surgical Technique

Patient Positioning and Preparation

The patient is positioned on a beach chair position and draped with a free upper limb (**Video 1**). After the arthroscopic stage of the procedure, the back of the table is leaned back closer to horizontal to about 30° of inclination. An armrest is then placed at the side of the table to allow proper rest of the elbow while the assistant helps in keeping the arm in external rotation. Traction to the forearm during arthroscopy is optional but unnecessary, namely when the arthroscopic gesture is reduced to a simple LHB tenotomy, as it will add dispensable time for the preparation of the field for the subpectoral approach later on. For this reason, an articulated support arm with simple locking/unlocking

From Hospital das Forças Armadas—Pólo do Porto (N.G.), Porto; Centro Hospitalar Póvoa de Varzim—Vila do Conde (N.G., H.P., R.A.), Póvoa de Varzim; Centro Hospitalar S. João. Alameda Prof. Hernâni Monteiro (M.R.d.S.), Porto; and Hospital Lusitadas Porto (R.S.), Porto, Portugal.

The authors report the following potential conflicts of interest or sources of funding: N.G. receives consultancy fees from Zimmer Biomet (no fixed amount, only for work as faculty per action), and payment for lectures including service on speakers bureaus from Zimmer Biomet.

Received December 14, 2016; accepted March 14, 2017.

Address correspondence to Nuno Gomes, M.D., Hospital das Forças Armadas, Pólo do Porto. Av. da Boavista, 4050-113 Porto, Portugal. E-mail: andresampaio@yahoo.com

© 2017 by the Arthroscopy Association of North America

2212-6287/161257/\$36.00

<http://dx.doi.org/10.1016/j.eats.2017.03.021>

features with a handle (similar to the Trimano 3D, Maquet, Wayne, NJ), if available, to hold and position the upper limb as desired through the different stages of the procedure may therefore be useful.

The inferior border of the pectoralis major tendon is palpated with the arm in slight abduction and neutral rotation, and its location is noted on the skin with an appropriate marker (Fig 1). This step may be very useful considering that swelling of the subcutaneous tissue may impair the identification of musculotendinous structures by palpation after an arthroscopy.

Arthroscopy and LHB Tenotomy

A classical intra-articular diagnostic arthroscopy is performed from a standard posterior viewing portal and the LHB is tenotomized at its origin from a rotator interval working portal. Associated arthroscopic gestures in the joint, such as labral or cuff repairs, can be performed at this stage.

LHB Tendon Harvest

On the anterior aspect of the axilla, a 3-cm incision is made perpendicular to the inferior border of the pectoralis major. Blunt dissection with Farabeuf retractors and the surgeon's finger will clear the subcutaneous fatty tissue until the fascia overlying the pectoralis major, coracobrachialis, and biceps is visualized and each muscle is identified.

An important landmark is the inferior edge of the pectoralis major, easily palpated with external and internal rotation of the arm in slight abduction. This gesture will put the muscle under tension and trap the surgeon's finger under its insertion on the humerus, just lateral to the LHB groove. Two pointed Hohmann retractors are placed on each side of the humerus: one over the lateral humerus into the pectoralis major tendon to retract the muscle proximally and laterally and another one gently around the medial humerus, with care to avoid risk of injury of the musculocutaneous nerve when retracting the coracobrachialis and short head of the biceps. The longitudinal, fusiform structure of the LHB musculotendinous portion should then be visualized.

LHB Tendon Preparation

Once the LHB tendon has been identified it is pulled outside the wound and cleaned from synovial tissue. A sterile pen is used to mark the musculotendinous junction (A) and 15 to 20 mm above (B) (Fig 2A). Point B will be the tendon end after it is cut and where the loop strands of the suspensory button construct (ToggleLoc; Zimmer Biomet, Warsaw, IN) should be attached. For that purpose, roughly 2 cm of the LHB tendon are tagstitched from point B to point A and the musculotendinous area using no. 2 ExpressBraid suture

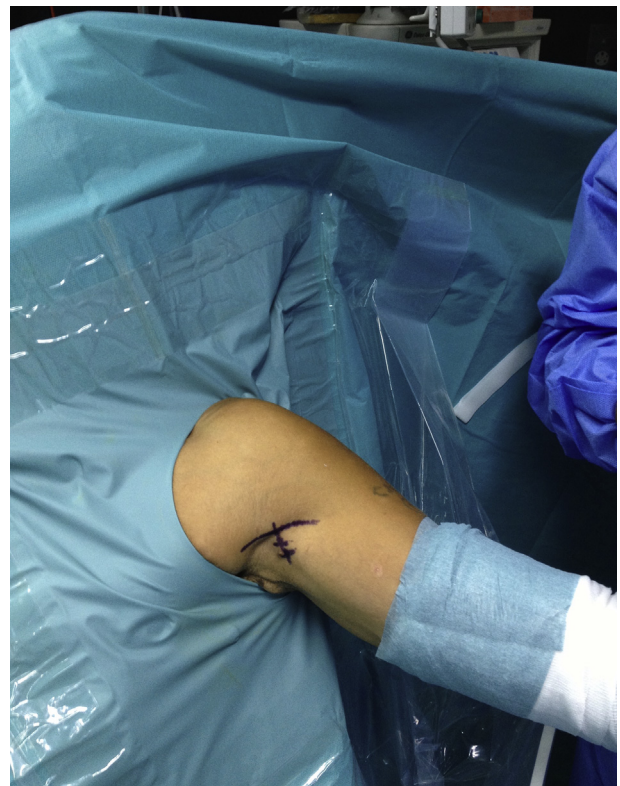

Fig 1. Left shoulder of a patient in beach chair position. The inferior border of the pectoralis major tendon is palpated and marked on the skin. A 3-cm incision is done perpendicular to it.

(Zimmer Biomet), while the assistant holds the tip of the tendon with an Allis grasper (Fig 2B). This whipstitch technique is relatively easy to perform with minimal assistance and reduces the number of needle passes and trauma to the tendon. The suture is tensioned after each pass and is not interlocked, eliminating the risk of cutting previously placed suture with the needle. The size of the tendon is measured with a ruler or a drill tip and the drill size, 4.5 or above, is estimated. The tendon stump proximal to point B is then cut close to the tagstitched section.

Bone Tunnel Preparation

The LHB humeral groove is palpated and cleaned from the periosteum proximal to the inferior border of the pectoralis major. The spot for the fixation of the LHB tendon is chosen at least 1 cm proximal to the inferior border of the pectoralis major, underneath which the musculotendinous portion of the LHB should be positioned.⁷ This is critical for the proper tensioning of the muscle-tendon unit as well as for cosmesis.

A 2.4-mm guidewire is power drilled through the humerus to the far cortex, while maintaining the 2 Hohmann retractors on each side of the humerus (Fig 3). This will help to estimate the proper centering

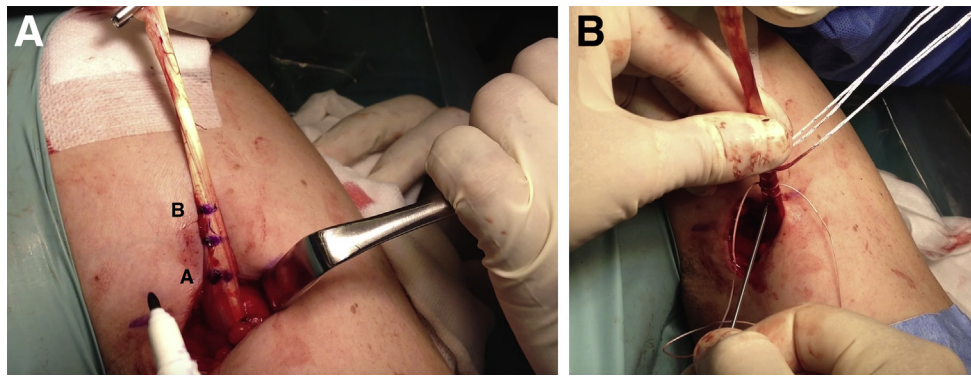


Fig 2. Left shoulder. (A) The LHBT is pulled outside the wound and cleaned from synovial tissue. A sterile pen is used to mark the musculotendinous junction (A) and 15-20 mm above (B). (B) Roughly 2 cm of the LHBT are tagstitched from point B to point A and the musculotendinous area using no. 2 ExpressBraid suture (Zimmer Biomet), fixing the loop strands of the suspensory button construct (ToggleLoc, Zimmer Biomet) close to point B, where the tendon stump is then cut. (LHBT, long head of the biceps tendon.)

and orthogonal placement of the hole in the humerus, to avoid marginal drilling, associated with higher risks of postoperative failure or humeral fracture.²⁻⁴ Slowly drill a cannulated 4.5-mm reamer (ToggleLoc Device Reamer, Zimmer Biomet) over the guide pin to make a bicortical bone tunnel. In the case of a thick tendon stump, the first cortical hole can be enlarged, either with the same drill, in oscillating movements, or with a larger one.

LHB Tendon Fixation

Insert the ToggleLoc implant in the bone tunnel using the ZipTight pusher (for the AC Joint repair by Zimmer Biomet) while keeping traction on the wire loops sutured to the tendon end, preventing the titanium button from being dropped from the pusher tip (Fig 4). As passage of the far cortex is perceived, the surgeon deploys the titanium button behind the cortical bone by using an appropriate obturator through the pusher. Then by pulling on the remaining free loop of the implant, the so-called *ziploop* strand, the tendon end will migrate into the bone tunnel until it is locked. That same free loop suture strand is cut flush and the wound is closed with subcutaneous and skin stitches. A drain is optional but usually not necessary.

Postoperative Management

The arm is kept in a sling for 4 weeks for comfort and avoidance of resisted flexion of the elbow. However, active assisted elbow flexion and performing basic activities such as writing, working on the computer, using utilities for eating, and personal hygiene are allowed as long as the LHB tendon insertion is not put under major stress. The sling is discontinued after this period, and active range of motion with passive stretching at end ranges to maintain or increase

flexibility is encouraged. Strengthening of the deltoid and cuff is gradually increased from isometrics to elastic bands as tolerated, followed by elbow strengthening at about 3 months.

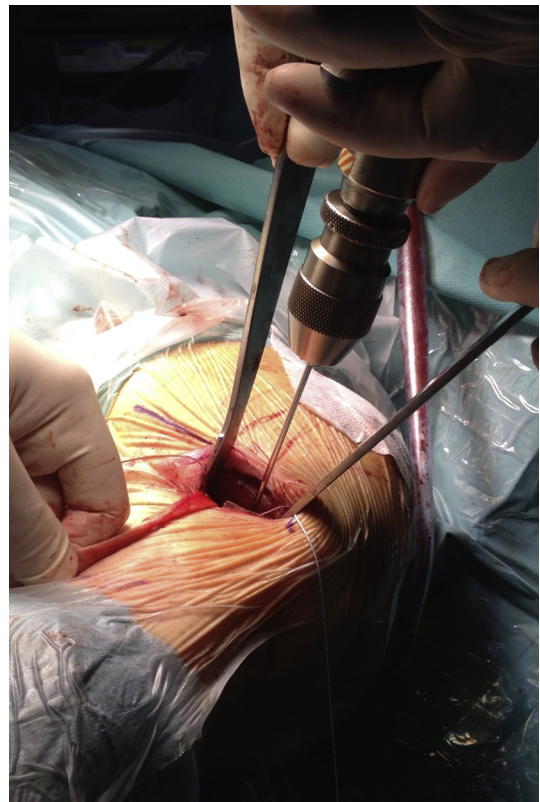

Fig 3. Left shoulder. A 2.4-mm guidewire is power drilled through the humerus to the far cortex, while maintaining the 2 Hohmann retractors on each side of the humerus to ensure proper centering and orthogonal placement of the hole, avoiding marginal drilling. Slowly drill a cannulated 4.5-mm reamer (ToggleLoc Device Reamer, Zimmer Biomet) over the guide pin to make a bicortical bone tunnel.

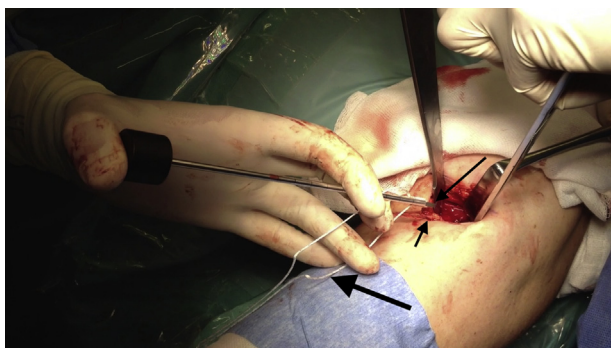


Fig 4. Left shoulder. Insert the ToggleLoc implant in the bone tunnel using the ToggleLoc pusher (Zimmer Biomet) while keeping traction on the wire loops sutured to the tendon end (short arrow) with the middle finger, to prevent the titanium button (long arrow) from being dropped from the pusher tip. As passage of the far cortex is perceived, the surgeon deploys the titanium button behind the cortical bone using an appropriate obturator through the cannulated pusher (see [Video 1](#)). By pulling on the remaining free loop of the implant, the so-called *ziploop* strand (thick arrow), the tendon end will then migrate into the bone tunnel until it is locked.

Discussion

The LHB tenodesis has become a popular procedure in the past few years, namely, as an alternative to the repair of SLAP lesions in sportsmen.^{8,9} Nevertheless, specific treatment guidelines for SLAP lesions are currently the subject of much debate. Older age, workers compensation status, sport demands and associated lesions, which can be present in up to 88% of patients,¹⁰ may all be related to a greater risk of failure after repair, confounding our understanding of the factors associated with failure of those repairs. Despite the overall good to excellent outcomes and high patient satisfaction, found in up to 83% of SLAP II repairs,¹ challenges remain in the care of these lesions. Recently, several authors have confirmed the findings of Boileau et al.⁹ in the first of the few reports that directly compared tenodesis with SLAP repair, suggesting tenodesis as an alternative to SLAP repair,^{11,12} with evidence of a shorter postoperative recovery, a more predictable outcome, and a higher rate of satisfaction and return to activity with a biceps tenodesis when compared with a repair.^{1,13}

In fact, a recent report¹⁰ identified a 10% incidence of subsequent surgery after isolated SLAP repair and a trend toward the decrease of repairs over time. Likewise, management of failed SLAP repairs has shifted toward biceps tenodesis or tenotomy over revision SLAP repairs in more recent years. This is particularly true in the case of overhead athletes, whose functional results of SLAP repairs are inferior to those of the general population. On average, one-third are unable to return to their previous level of function.^{1,9}

Postoperative stiffness with pain is the most common complication. Inadvertent restriction of physiologic

biceps excursion from overtensioning the repair or from nonanatomic biceps anchor reduction can contribute to this.

Other causes of failure include complications from using hardware such as osteolysis and cysts, foreign body reaction, or migration, but may also be related to failure of the labrum to heal or due to pain generating from the proximal portion of the LHB, which is also a reason for discussion on the best location for the tenodesis.

LHB tenodesis can be positioned on the bicipital groove, the “supraperectoral” position below the bicipital groove at the superior border of the pectoralis major tendon, the subpectoral position, or on others such as the conjoint tendon, cuff or soft tissue by means of suture fixation.¹⁴ It can be performed under arthroscopy proximally on the groove but several authors report residual pain from the so-called “hidden lesions,” or pathologic LHB that is left in the gutter unreleased from its sheath, which turn the subpectoral fixation an attractive option.¹⁵⁻¹⁷ Likewise, a subpectoral fixation eliminates any further sawing of the LHB tendon through the rotator cuff tendons.¹⁸

The technique that we describe offers the advantages of a subpectoral fixation and seems to avoid the risks associated with other types of fixation commonly used with this approach, such as osteolysis and humerus fractures with interference screws or tendon pull-out from using weaker constructs.²⁻⁵

Some laboratorial studies report on objective comparisons between different methods of fixation, but high level clinical evaluations still lack. Park et al.,⁶ in a prospective study, conclude that fixation with an interference screw (IS) appears to pose a higher risk in terms of the anatomic failure of tenodesis than suture anchor fixation, although functional outcomes were not different. Others conclude that both open subpectoral and all-arthroscopic supraperectoral tenodesis without IS fixation yield durable and reliable results.¹⁹

The most recent biomechanical studies use the IS as a reference for comparison to other methods of fixation, considering its highest biomechanical stability, namely when compared with suture anchors.^{18,20} Still, when comparing the performance between the IS and the intramedullary cortical button fixations, results seem to be somehow inconsistent, particularly because the methods used are not exactly the same. Some intramedullary suspensory fixations are bicortical whereas others are unicortical or complemented with additional tendon suture—with further tendon trauma—since they are not knotless devices. Although some authors found the cortical button to yield a lower ultimate load to failure compared with IS,²¹ others found no major differences in load to failure but a 30% failure rate during cyclic testing for the IS and no failure with the intramedullary cortical button.¹⁸

Table 1. Advantages and Disadvantages of the Technique

Advantages	Disadvantages
<ul style="list-style-type: none"> - Subpectoral location eliminates potential pain from LHB tendinopathy in the gutter - Tagstitching technique is quick and avoids bulky tendon stump, enabling a smaller drill hole than with other intraosseous fixation methods such as interference screw and therefore less bony weakening - Knotless suspensory construct avoids the bulky and painful knot stack that can be present with other suspensory devices, anchors, or soft tissue fixation - Tendon stump dips into the humeral tunnel, increasing the area of contact with bone and the healing potential - Presence of foreign body in the humerus is minimal (only sutures), minimizing the risk of osteolysis and subsequent weakening of bone as described with interference screws 	<ul style="list-style-type: none"> - Proximity to neurovascular structures is a concern but the risk is minimal and not greater than with other methods if care is taken with retraction, drill orientation, and depth - Open approach; however, incision is small (3 cm) and cosmetically acceptable as it is hidden close to the axillary fold

LHB, long head of the biceps.

These conclusions stress the importance of powerful bias such as the strength of the tendon stump whipstitch, the quality of the tendon itself—most of the failures are through the tendon and under loads not necessarily met under a biological environment—and especially the fact that studies on cadaver specimens are not clinical and do not consider tendon integration into bone, expected in the technique we describe.

Tables 1 and 2 summarize the advantages and disadvantages of this technique, as well as some pearls and pitfalls. The need to perforate to the far cortex

implied making sure all the important neurovascular structures are at a safe distance from the drilling axis. There is concern that bicortical button fixation may result in injury to the neurovascular structures—axillary nerve, posterior circumflex humeral artery or radial nerve lesions—because of their proximity to the drill and the button when drilling through the posterior cortex and with manipulation with retractors.

Anatomic studies have shown the relative safety of the procedure. The circumflex humeral artery and the axillary nerve were at a mean distance of 18.17 mm

Table 2. Pearls and Pitfalls of the Technique

Pearls	Pitfalls
<ul style="list-style-type: none"> - Beach chair position eases transition between arthroscopic and open stages - Using an articulated support arm like the Trimano 3D (Maquet) facilitates arm positioning as it dispenses fixing an arm holder to the table after the arthroscopic procedure - Two Hohmann retractors on each side of the humerus are invaluable to estimate the orthogonal placement of the drill - Gently drill through the far cortex, avoiding deep progression of the K-wire and drill, to prevent neurovascular injury from soft tissue retraction - Using the pusher permits direct placement of the button behind the far cortex, without the need to shuttle it with an accessory suture through the skin posteriorly - Marking the anatomic landmarks on the skin should be done at the beginning of the surgery: palpating the LHB tendon and a taut pectoralis major is easier with no swelling from the arthroscopy and with free mobilization of the arm before putting traction to the limb - Enlargement and/or smoothing of the proximal hole in the humerus can be done effectively with the 4.5-mm drill in oscillating movements, usually with no need to use a larger drill to allow the tendon to fit in the tunnel 	<ul style="list-style-type: none"> - Conversion from the arthroscopic to the mini-open step may be cumbersome if the patient is positioned in lateral decubitus - The classical case of the unstable shoulder in need of both labral repair and LHB tenodesis may pose an issue if the surgeon feels more comfortable with lateral decubitus - Wrong estimation of where to tagstitch the LHB stump may result in a slack biceps and the need to redo the whole construct or the tagstitching if identified before reduction and fixation; bringing the tendon close to the drilled hole beforehand to check the biceps tension may help to prevent this

LHB, long head of the biceps.

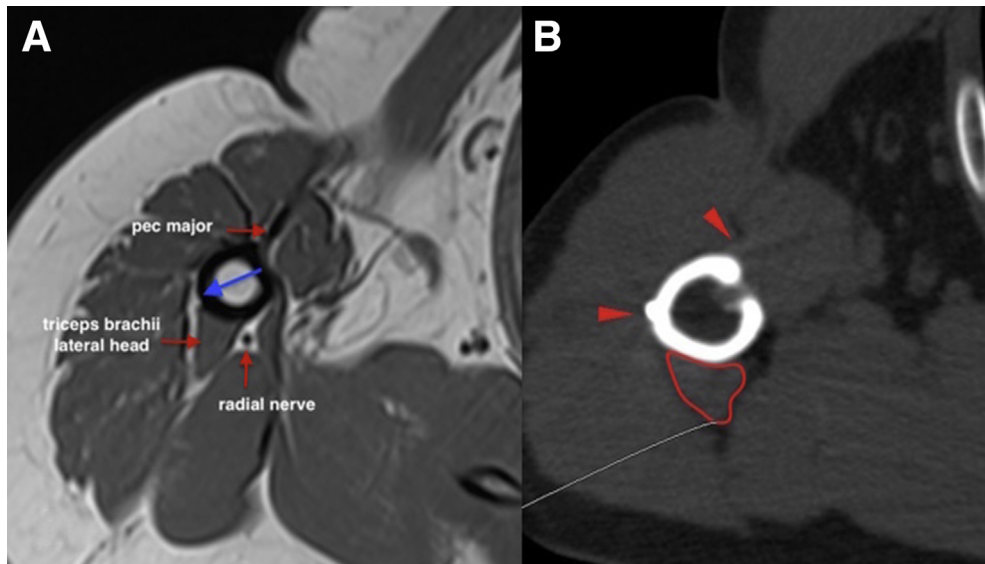


Fig 5. Axial cuts of a right shoulder. (A) Preoperative magnetic resonance image: a drilling axis (blue long arrow) performed orthogonally on the LHBT groove at 1 cm proximal to the inferior border of the pectoralis major tendon insertion will perforate the far cortex at least 2 cm away from the radial nerve. (B) Postoperative CT scan shows LHBT inside the bone tunnel and metallic button (arrow on left) lateral to the triceps brachii lateral head (outlined). The pectoralis major insertion (arrow on top) is visible just lateral to the humeral hole. (LHBT, long head of the biceps tendon.)

from the posterior cortical button in a sonographic evaluation of 18 patients.²² In 2 studies of bicortical drilling in cadavers, the axillary nerves were 25.1 mm and 36.7 mm from the posterior drill hole.^{23,24} Another

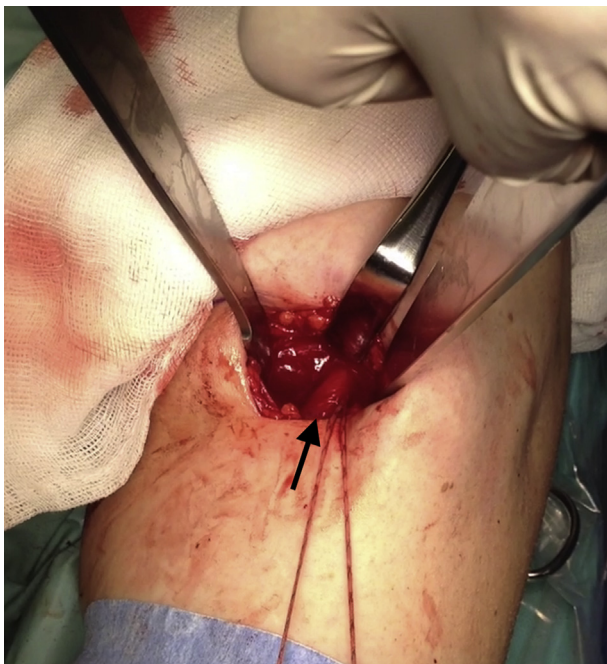

Fig 6. Final aspect of the fixation on a left shoulder with the entire tendon inside the hole, leaving only the musculotendinous thickened portion (arrow) visible. The visible suture strand of the implant that was used for the reduction is then cut flush.

cadaveric study highlighted a greater risk though, demonstrating a mean distance to the axillary nerve of 2.14 mm.²⁵ In all 6 specimens, the nerve was less than 3 mm away from the button and lying directly on it in 3 cases. However, the entry point for the tunnel in this study was 4 cm distal from the greater tuberosity, in a location that looks closer to a “supraperacoral” than to a subpectoral fixation, assuming all entry points were similar to the one presented in a figure of a specimen.

Furthermore, the musculocutaneous nerve, radial nerve, and deep brachial artery course in close proximity to the operative field and may therefore be at risk during open subpectoral tenodesis.²⁶ Limiting the use of medial retraction and placement of the arm in external rotation will minimize that risk.

An anatomic study with magnetic resonance images of 10 nonoperated shoulders clearly showed that the closest important structure is the radial nerve, but consistently at a reasonable distance from the far cortical hole. In a still unpublished report, we concluded that a drilling axis performed orthogonally on the LHB groove at 1 cm proximal to the inferior border of the pectoralis major tendon insertion will perforate the far cortex at least 2 cm away from the radial nerve (Fig 5).

Restoring the appropriate length-tension relationship of the biceps muscle is one of the main concerns during this procedure, to offer the best cosmesis and avoid cramping. Reports on the location of the musculotendinous junction vary a lot, from close to the inferior border of the pectoralis major²⁷ to 3.1 cm proximal

to it.⁷ In fact, the transition from the tendon to the muscle is gradual, and therefore there is no sharp separation between both structures. Considering these evidences, our option is to perforate the humerus at about 1 cm proximal to the pectoralis major inferior border and have the entire tendon inside the hole, leaving only the musculotendinous thickened portion visible (Fig 6, Video 1).

The simplicity of the technique along with the promising results allows us to accept it as a valid option for LHB tenodesis.

References

- McCormick F, Bhatia S, Chalmers P, Gupta A, Verma N, Romeo AA. The management of type II superior labral anterior to posterior injuries. *Orthop Clin N Am* 2014;45:121-128.
- Euler SA, Smith SD, Williams BT, Dornan GJ, Millett PJ, Wijdicks CA. Biomechanical analysis of subpectoral biceps tenodesis: Effect of screw malpositioning on proximal humeral strength. *Am J Sports Med* 2015;43:69-74.
- Beason DP, Shah JP, Duckett JW, Jost PW, Fleisig GS, Cain EL Jr. Torsional fracture of the humerus after subpectoral biceps tenodesis with an interference screw: A biomechanical cadaveric study. *Clin Biomech (Bristol, Avon)* 2015;30:915-920.
- Sears BW, Spencer EE, Getz CL. Humeral fracture following subpectoral biceps tenodesis in 2 active, healthy patients. *J Shoulder Elbow Surg* 2011;20:e7-e11.
- Nho SJ, Reiff SN, Verma NN, Slabaugh MA, Mazzocca AD, Romeo AA. Complications associated with subpectoral biceps tenodesis: Low rates of incidence following surgery. *J Shoulder Elbow Surg* 2010;19:764-768.
- Park JS, Kim SH, Jung HJ, Lee YH, Oh JH. A prospective randomized study comparing the interference screw and suture anchor techniques for biceps tenodesis. *Am J Sports Med* 2017;45:440-448.
- Jarrett CD, McClelland WB Jr, Xerogeanes JW. Minimally invasive proximal biceps tenodesis: An anatomical study for optimal placement and safe surgical technique. *J Shoulder Elbow Surg* 2011;20:477-480.
- Vellios EE, Nazemi AK, Yeraniosian MG, et al. Demographic trends in arthroscopic and open biceps tenodesis across the United States. *J Shoulder Elbow Surg* 2015;24:e279-e285.
- Boileau P, Parratte S, Chuinard C, Roussanne Y, Shia D, Bicknell R. Arthroscopic treatment of isolated type II SLAP lesions: Biceps tenodesis as an alternative to reinsertion. *Am J Sports Med* 2009;37:929-936.
- Mollon B, Mahure SA, Ensor KL, Zuckerman JD, Kwon YW, Rokito AS. Subsequent shoulder surgery after isolated arthroscopic SLAP repair. *Arthroscopy* 2016;32:1954.e1-1962.e1.
- Chalmers PN, Monson B, Frank RM, et al. Combined SLAP repair and biceps tenodesis for superior labral anterior-posterior tears. *Knee Surg Sports Traumatol Arthrosc* 2016;24:3870-3876.
- Ek ETH, Shi LL, Tompson JD, Freehill MT, Warner JJP. Surgical treatment of isolated type II superior labrum anterior-posterior (SLAP) lesions: repair versus biceps tenodesis. *J Shoulder Elbow Surg* 2014;23:1059-1065.
- Denard PJ, Lädermann A, Parsley BK, Burkhart SS. Arthroscopic biceps tenodesis compared with repair of isolated type II SLAP lesions in patients older than 35 years. *Orthopedics* 2014;37:e292-e297.
- Werner BC, Evans CL, Holzgrefe RE, et al. Arthroscopic suprapectoral and open subpectoral biceps tenodesis: A comparison of minimum 2-year clinical outcomes. *Am J Sports Med* 2014;42:2583-2590.
- Moon SC, Cho NS, Rhee YG. Analysis of 'hidden lesions' of the extra-articular biceps after subpectoral biceps tenodesis: The subpectoral portion as the optimal tenodesis site. *Am J Sports Med* 2015;43:63-68.
- Sanders B, Lavery KP, Pennington S, Warner JP. Clinical success of biceps tenodesis with and without release of the transverse humeral ligament. *J Shoulder Elbow Surg* 2012;21:66-71.
- Gausden EB, Taylor SA, Ramkumar P, et al. Tenotomy, tenodesis, transfer: A review of treatment options for biceps-labrum complex disease. *Am J Orthop (Belle Mead NJ)* 2016;45:E503-E511.
- Buchholz A, Martetschläger F, Siebenlist S, et al. Biomechanical comparison of intramedullary cortical button fixation and interference screw technique for subpectoral biceps tenodesis. *Arthroscopy* 2013;29:845-853.
- Green JM, Getelman MH, Snyder SJ, Burns JP. All-arthroscopic suprapectoral versus open subpectoral tenodesis of the long head of the biceps brachii without the use of interference screws. *Arthroscopy* 2017;33:19-25.
- Ramos CH, Coelho JC. Biomechanical evaluation of the long head of the biceps brachii tendon fixed by three techniques: A sheep model [in Portuguese]. *Rev Bras Ortop* 2016;52:52-60.
- Sethi PM, Rajaram A, Beitzel K, Hackett TR, Chowanec DM, Mazzocca AD. Biomechanical performance of subpectoral biceps tenodesis: A comparison of interference screw fixation, cortical button fixation, and interference screw diameter. *J Shoulder Elbow Surg* 2013;22:451-457.
- Meadows JR, Diesselhorst MM, Finnoff JT, Swanson BL, Swanson KE. Clinical and sonographic evaluation of bicortical button for proximal biceps tenodesis. *Am J Orthop (Belle Mead NJ)* 2016;45:E283-E289.
- Ding DY, Gupta A, Snir N, Wolfson T, Meislin RJ. Nerve proximity during bicortical drilling for subpectoral biceps tenodesis: A cadaveric study. *Arthroscopy* 2014;30:942-946.
- Sethi PM, Vadasdi K, Greene RT, Vitale MA, Duong M, Miller SR. Safety of open suprapectoral and subpectoral biceps tenodesis: An anatomic assessment of risk for neurologic injury. *J Shoulder Elbow Surg* 2015;24:138-142.
- Aroora AS, Singh A, Koonce RC. Biomechanical evaluation of a unicortical button versus interference screw for subpectoral biceps tenodesis. *Arthroscopy* 2013;29:638-644.
- Dickens JF, Kilcoyne KG, Tintle SM, Giuliani J, Schaefer RA, Rue JP. Subpectoral biceps tenodesis—An anatomic study and evaluation of at-risk structures. *Am J Sports Med* 2012;40:2337-2341.
- Mazzocca AD, Noerdlinger MA, Romeo AA. Mini open and subpectoral biceps tenodesis. *Oper Tech Sports Med* 2003;11:24-31.